Reconstruction of a Below-the-Knee Amputation Stump in the Setting of Popliteal Transection: Supercharging an Anterolateral Thigh Free Flap for Vein Graft Coverage

Samuel R. Skovgaard, BA[1] Frederic W.B. Deleyiannis, MD, MPhil, MPH, FACS[1]

[1] Division of Plastic Surgery, Department of Surgery, University of Colorado School of Medicine, Aurora, Colorado

J Reconstr Microsurg Open 2016;1:36–38.

Address for correspondence Frederic W.B. Deleyiannis, MD, MPhil, MPH, FACS, Department of Surgery, University of Colorado School of Medicine, 13123 East 16th Avenue, B467, Aurora, CO 80045 (e-mail: Frederic.Deleyiannis@childrenscolorado.org).

Abstract

We present the first case of a super charged/venous augmented anterolateral thigh (ALT) free flap used for below-the-knee stump reconstruction. Due to medical knee tissue loss, tunneled vein grafts could have been at risk for exposure. The inclusion of a second pedicle allowed reliable soft tissue coverage of the vein grafts, while the ALT component of the flap covered the exposed tibia.

Keywords
- amputation
- reconstruction
- supercharge
- anterolateral thigh free flap

Amputation height in the lower extremity influences a patient's likelihood of achieving ambulation, ability to use a prosthetic device, energy expenditure while walking, and overall quality of life, with a below-the-knee amputation (BKA) being superior to an above-the-knee amputation (AKA) in all these regards.[1,2] Salvage of a threatened BKA should be attempted rather than conversion to AKA when possible. Here, we present a patient with a BKA wound breakdown whose reconstruction was made challenging by transection of the popliteal artery. In this context, we present the first case of a supercharged/venous augmented anterolateral thigh (ALT) free flap used for BKA stump reconstruction.

Case Presentation

A 25-year-old man with a BKA performed after a gunshot wound to the knee presented with extensive wound breakdown and 12 cm of residual tibia (►**Fig. 1**). Primary closure would have required excessive tibial shortening, so free tissue transfer was planned. An angiogram revealed the popliteal artery ending 6 cm above the joint line. The descending geniculate artery was intact.

For recipient vessels, the superficial femoral artery (SFA) and superficial femoral vein (SFV) as well as the descending geniculate vessels were exposed at the anterior margin of the adductor hiatus. The ALT flap was marked on the ipsilateral thigh and measured 32 by 8 cm (matching the size of the defect). During harvest, an unusual pedicle was encountered as described by Tamimy and O'Boyle.[3] It arose from the proximal SFA/SFV, coursed medial and then anterior to the rectus femoris, supplying the upper half of our proposed flap. The perforators from the descending branch of the lateral femoral circumflex artery (DLFC) were then dissected back to the profunda femoral artery. The superior half of the flap was supplied by the SFA, which is more typical of the blood supply of the anteromedial thigh (AMT) flap, and the lower half by the DLFC. This large AMT/ALT free flap was then harvested with both pedicles (►**Fig. 2**). The AMT pedicle was anastomosed to the descending geniculate vessels. Two 15-cm saphenous interposition grafts were required to connect the DLFC pedicle to the SFA/SFV. The flap was inset and the donor site was closed primarily (►**Fig. 3**).

Discussion

A tibial length of 15 cm is classically considered to be ideal,[4] with many considering 8 cm to be the minimum for optimal prosthetic fitting.[5] Using special fitting techniques, some

received
September 22, 2015
accepted after revision
December 21, 2015
published online
February 3, 2016

DOI http://dx.doi.org/10.1055/s-0036-1571846.
ISSN 2377-0813.

Copyright © 2016 by Thieme Medical Publishers, Inc., 333 Seventh Avenue, New York, NY 10001, USA. Tel: +1(212) 584-4662.

License terms

Fig. 1 Below-the-knee stump with exposed tibia.

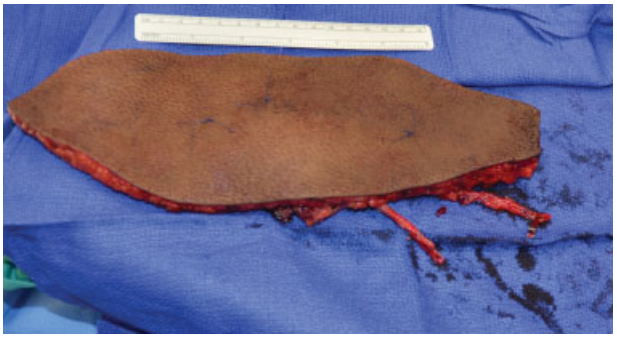

Fig. 2 Combined anteromedial thigh/anterolateral thigh free flap with two separate pedicles.

Fig. 3 Inset with anteromedial thigh component of the free flap covering the vein grafts to the superficial femoral artery and superficial femoral vein.

have reported successful prosthetic use with tibial stumps as short as 4 cm,[4] but short BKA stumps are less efficient during ambulation.[6] In order to optimize the patient's chances of efficient ambulation with a prosthetic, free tissue transfer was chosen.

Vein grafts from the SFA and SFV would have allowed either an ALT free flap or latissimus free flap to be transferred to the defect. However, due to medial knee tissue loss, tunneled vein grafts would have been at risk for exposure and/or thrombosis. The inclusion of the AMT component of the flap allowed reliable soft tissue coverage of the vein grafts, while the ALT component covered the exposed tibia.

The ALT flap can be harvested very long; several have described lengths greater than 30 cm.[7] Our case illustrates that even with a very long skin paddle, vein grafts may be needed to reach the vascular pedicle originating from the DFLC. Perhaps, this very large AMT/ALT flap could have been reliably perfused by only one of its pedicles. However, it is our opinion that supercharging and venous augmenting such a large flap should be considered to avoid ischemia or venous congestion. The descending geniculate vessels and SFA/SFV would be our two preferred recipient vessels in the setting of a popliteal transection.

Donor-site morbidity in the amputee deserves special attention. Latissimus harvest could cause significant difficulty in ambulation with crutches in the amputee.[8] With the ALT flap, Kuo et al demonstrated that quadriceps strength is diminished in the donor leg with no significant functional consequences.[9] However, the muscle use patterns in BKA prosthetic ambulation are different than that of a normal leg, with vastus lateralis forces roughly double those of the nonamputee.[10] These altered biomechanics could potentially be expected to magnify the ALT's otherwise benign donor-site morbidity. We chose to harvest the ALT flap from the injured leg to avoid any morbidity in the uninjured leg. Our patient has been fitted with a prosthetic and does not report any decreased thigh strength.

References

1 Penn-Barwell JG. Outcomes in lower limb amputation following trauma: a systematic review and meta-analysis. Injury 2011; 42(12):1474–1479

2 Waters RL, Perry J, Antonelli D, Hislop H. Energy cost of walking of amputees: the influence of level of amputation. J Bone Joint Surg Am 1976;58(1):42–46

3 Tamimy MS, O'Boyle CP. But is it an ALT flap? Previously-unreported anomalous medially-based vascular supply to anterolateral thigh flap. J Plast Reconstr Aesthet Surg 2014;67(10):1447–1448

4 Carvalho JA, Mongon MD, Belangero WD, Livani B. A case series featuring extremely short below-knee stumps. Prosthet Orthot Int 2012;36(2):236–238

5 Brigham and Women's Hospital, Department of Rehabilitation Services. Standard of care: lower extremity amputation. 2011. Available at: http://www.brighamandwomens.org. Accessed August 22, 2015

6 Majumdar K, Lenka PK, Mondal RK, Kumar R, Triberwala DN. Relation of stump length with various gait parameters in transtibial amputees. Online J Health Allied Sci 2008;7(2):2

7 Park JE, Rodriguez ED, Bluebond-Langer R, et al. The anterolateral thigh flap is highly effective for reconstruction of complex lower extremity trauma. J Trauma 2007;62(1):162–165
8 Ellur S, Bharath SP. Considerations in the choice of side in a free latissimus dorsi flap to determine expendability in extensive lower extremity defects. Indian J Plast Surg 2010;43(1): 114–116
9 Kuo YR, Yeh MC, Shih HS, et al. Versatility of the anterolateral thigh flap with vascularized fascia lata for reconstruction of complex soft-tissue defects: clinical experience and functional assessment of the donor site. Plast Reconstr Surg 2009;124(1):171–180
10 Voinescu M, Soares DP, Natal Jorge RM, Davidescu A, Machado LJ. Estimation of the forces generated by the thigh muscles for transtibial amputee gait. J Biomech 2012;45(6):972–977