

Mycotic Aneurysm of the Posterior Cerebral Artery

Sushil Kumar¹ Ravi Kumar Tiwary¹ Lalit Kumar Bhatia¹

¹Department of Neurosurgery, St. Stephen's Hospital, Tis Hazari, Delhi, India

Address for correspondence Dr. Sushil Kumar, MS, MCh, Department of Neurosurgery, St. Stephen's Hospital, Tis Hazari, Delhi 110035, India (e-mail: sushilneuro@rediffmail.com).

Indian J Neurosurg 2016;5:193–195.

Abstract

Keywords

- ▶ mycotic aneurysm
- ▶ posterior cerebral artery
- ▶ digital subtraction angiography
- ▶ infective endocarditis

A 31-year-old male patient who presented with headache, chest uneasiness, and blurring of vision in the left eye. A computed tomographic scan revealed a large hematoma in the left occipital lobe. Echocardiogram showed mitral valve vegetations. Digital subtraction angiography revealed a fusiform aneurysm of the distal posterior cerebral artery. Subsequent angiogram revealed enlargement of the aneurysm. The patient was subjected to craniotomy with evacuation of the hematoma and excision of the aneurysm. Histopathology confirmed it to be a mycotic aneurysm.

Introduction

Mycotic aneurysms are rare types of intracranial aneurysms that develop in the presence of infections such as infective endocarditis. They account for 0.7 to 6.5% of all intracranial aneurysms.¹ They can give rise to subarachnoid and intracerebral hemorrhage. They are associated with significant morbidity and mortality as high as 60 to 90% in earlier case studies and 12 to 32% in more recent literature.^{1,2} Recently, we came across a ruptured intracranial mycotic aneurysm on the distal posterior cerebral artery and because of the rarity of involvement of this vessel, the present case is being reported.^{3,4}

Case Report

A 31-year-old policeman presented with holocranial headache of 1 week duration along with irrelevant talking, uneasiness in the chest and fever for 3 days, one episode of vomiting, and blurring of vision in the left eye of 1 day duration. He also complained of palpitation. There was no history of loss of weight.

On examination he was afebrile, blood pressure was 110/70 mm Hg, and pulse rate was 78/minute. There was a pansystolic murmur heard at the apex and axilla. He was fully conscious. There was right homonymous hemianopia.

There was no motor or sensory deficit. Echocardiography demonstrated thick mitral valves with vegetations. The mitral valves had restricted movements and there was mild regurgitation. Ejection fraction was 60%. Investigations showed hemoglobin of 11.3 g/dL, white blood cell count of 8,900 μ L, with 84% neutrophils. Erythrocyte sedimentation rate was 54 mm in the 1st hour. Blood coagulation parameters were normal. Serum urea nitrogen, creatinine, and electrolytes were normal. Blood culture grew *Streptococcus anginosus*. Antistreptolysin O titers were negative.

Computed tomography revealed a large hematoma in the left occipital lobe measuring 4.8 \times 4.6 \times 3 cm with perilesional edema effacing the ventricle and producing midline shift to the right (**Fig. 1**). Digital subtraction angiography (DSA) revealed a 3 \times 4-mm-sized fusiform aneurysm without an identifiable neck on the distal posterior cerebral artery (**Fig. 2A**). Cardiologist advised benzathine penicillin prophylaxis every 3 weeks. He was put on antiedema, antiepileptic, antibiotics, and nimodipin. DSA repeated after 18 days showed enlargement of the aneurysm (**Fig. 2B**). In view of the enlargement of the aneurysm, he was subjected to craniotomy. Hematoma was evacuated and the aneurysm was excised. It was thick walled and involved the entire thickness of the involved vessel. Histopathologic

received
April 9, 2015
accepted
January 18, 2016
published online
June 8, 2016

DOI <http://dx.doi.org/10.1055/s-0036-1581982>.
ISSN 2277-954X.

© 2016 Neurological Surgeons' Society of India

License terms



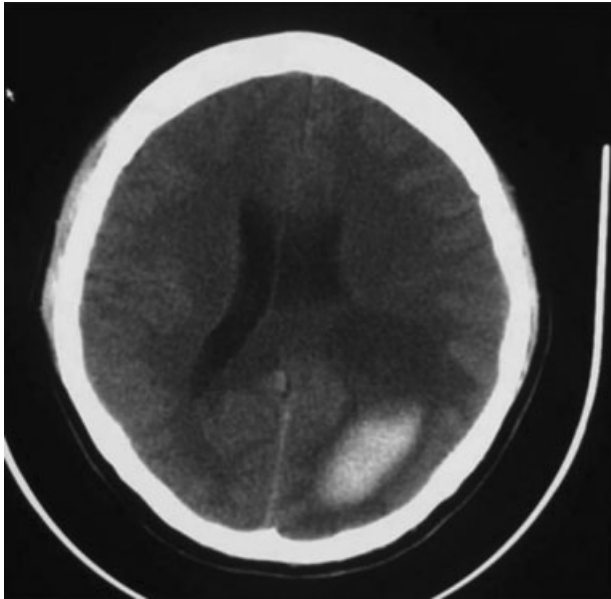


Fig. 1 Computed tomographic scan showing a large left occipital intracerebral bleed.

examination showed a thick-walled aneurysm with the disorganization of the wall and focal destruction and loss of elastic lamina (→**Fig. 3**). Surrounding glial tissue showed inflammation, gliosis, and old hemorrhage and hemosiderophages.

The postoperative period was uneventful. His sensorium improved and he was discharged with advice to continue penicillin prophylaxis every 3 weeks. Postoperative DSA done 5.5 months after surgery did not reveal any aneurysm (→**Fig. 2C**).

Discussion

Mycotic aneurysms represent an uncommon but dangerous embolic complication. They occur in the intracranial arteries and have a predilection for the middle cerebral artery and its branches.⁵ Regelsberger et al (2011) reported it to have a

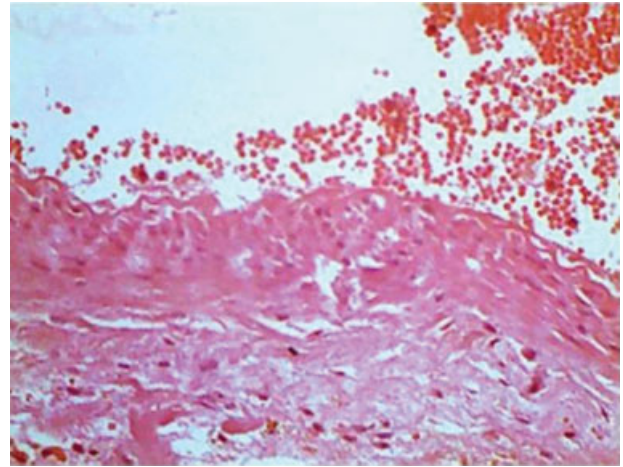


Fig. 3 Histopathology showing disorganization of the wall and focal destruction and loss of elastic lamina. The lumen contains organizing thrombus.

fatal clinical course in 90% of the cases.⁶ Mycotic aneurysm usually presents with headache, fever, vomiting, ocular palsy, seizures, behavioral changes, hemiparesis, drowsiness, and loss of consciousness.⁷ Rheumatic or congenital heart disease history is present in 50% of the cases.

Vasa vasorum theory is the widely accepted mechanism for pathogenesis. According to this theory, bacteria from septic emboli migrate through the vasa vasorum and cause severe inflammation of the adventitia. The infection then spreads inwards.^{8,9} The arterial pulsations against the weakened wall eventually results in aneurysm formation and its enlargement.

Aneurysms so formed are usually fusiform and eccentric. These aneurysms are more common in the anterior circulation and posterior cerebral artery is involved rarely. Histologically, mycotic aneurysms are characterized by acute neutrophilic infiltration, marked intimal proliferation, and internal elastic lamina destruction which were seen in our case as well. Bacteria, mycobacteria, and fungi can cause

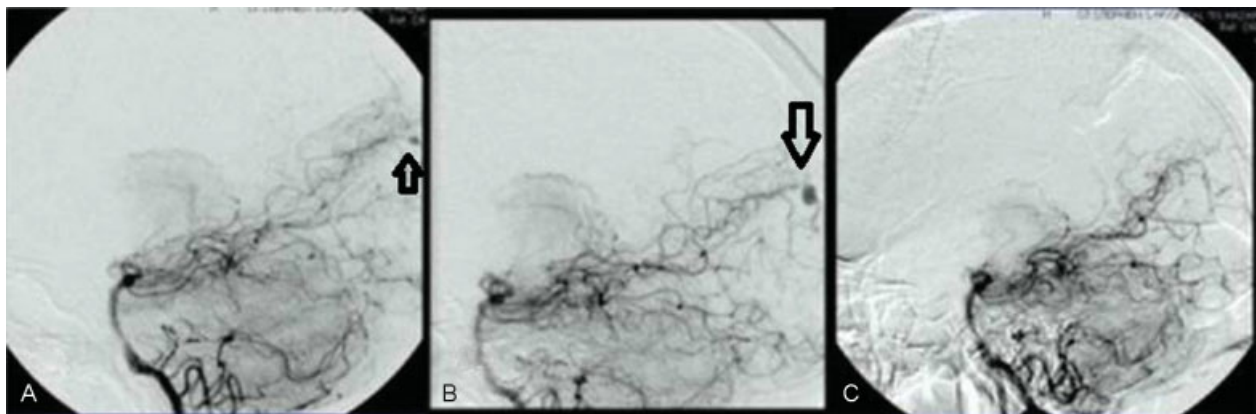


Fig. 2 (A) Angiogram showing the irregular mycotic aneurysm in the distal branch of the left posterior cerebral artery. (B) Repeat angiogram 18 days later showing enlarged aneurysm. (C) Angiogram 5.5 months later showing no aneurysm.

mycotic aneurysms. *Streptococcus viridians* and *Staphylococcus aureus* are the most common etiologic organisms.¹ But, in our case the offending organism was *Streptococcus anginosus*.

Computed tomographic angiography, magnetic resonance angiography, and DSA may demonstrate these aneurysms, but the gold standard is DSA as it demonstrates even the most distal aneurysms clearly, as shown by our case as well.

Treatment of infective aneurysms is controversial and has been divided into medical, endovascular, and surgical. Unruptured aneurysms should receive antibiotic therapy with serial angiograms at an interval of 7 to 14 days to document improvement or resolution.¹⁰

Resolution of mycotic aneurysms with medical therapy alone has been reported.¹¹⁻¹³ If the aneurysm is large, not resolving or enlarging despite antibiotics the patient will require surgery or endovascular therapy. Corr et al (1995) reported resolution in four out of five patients with unruptured aneurysm and one patient required surgery.¹⁴

Ruptured aneurysms have worst prognosis. Patients treated with combined surgery and antibiotics have a better prognosis than those treated with antibiotics alone. Surgical clipping is reserved for patients with associated intraparenchymal hemorrhage, which requires evacuation to relieve the raised intracranial pressure. We continued our patient on antibiotic therapy even in the presence of a hematoma expecting the hematoma to resolve as there was no raised intracranial pressure.

Repeat angiogram revealed enlargement of the aneurysm necessitating the surgical excision. In P6-located aneurysms (aneurysms located in calcarine/parietooccipital arteries), sacrificing the parent vessel is less hazardous with respect to postoperative neurological deficits, mainly due to the rich blood supply of the area for which the posterior cerebral artery is the principle feeder. Our patient's clinical course confirms this as there was improvement in the visual fields in the follow-up period.

Surgery carries a risk of intraoperative rupture and erosion of the parent artery due to clip which has been attributed to irregular fusiform morphology and acutely inflamed, friable vessel wall. We did not face the difficulty in excision of the lesion as it was on a terminal portion of the artery and had become less friable.

Endovascular therapy is advancement in the management of these friable aneurysms requiring little manipulation and less risk of hemorrhage. Chapot et al (2002) reported successful occlusion of 18 infective aneurysm in 14 patients with endovascular therapy using cyanoacrylate and coils without any risk of rupture.¹⁵ Recently, Zhao et al (2010) have reported successful occlusion of mycotic aneurysms using a liquid embolic agent called onyx (ethylene vinyl alcohol copolymer).¹⁶

Ducruet et al (2010) in a review of 287 cases of mycotic aneurysms diagnosed between 1950 and 2009 and treated with all available modalities concluded that 62% had positive outcome, 20% deteriorated neurologically, 5% died before

intervention, and 12% died immediately after intervention was performed whether surgical or endovascular.¹⁷

Financial Support

None.

Conflict of Interest

None.

References

- 1 Kannoth S, Thomas SV. Intracranial microbial aneurysm (infectious aneurysm): current options for diagnosis and management. *Neurocrit Care* 2009;11(1):120-129
- 2 Watanabe A, Hirano K, Ishii R. Cerebral mycotic aneurysm treated with endovascular occlusion—case report. *Neurol Med Chir (Tokyo)* 1998;38(10):657-660
- 3 Pia HW, Fontana H. Aneurysms of the posterior cerebral artery. Locations and clinical pictures. *Acta Neurochir (Wien)* 1977; 38(1-2):13-35
- 4 Pia HW. Classification of vertebro-basilar aneurysms. *Acta Neurochir (Wien)* 1979;47(1-2):3-30
- 5 Allen B, Desai B, Falgiani M. Endocarditis induced mycotic brain aneurysm following right MCA stroke. *Case Rep Emerg Med* 2012;2012:606921
- 6 Regelsberger J, Elsayed A, Matschke J, et al. Diagnostic and therapeutic considerations for "mycotic" cerebral aneurysms: 2 case reports and review of the literature. *Cent Eur Neurosurg* 2011;72(3):138-143
- 7 Kannoth S, Thomas SV, Nair S, Sarma PS. Proposed diagnostic criteria for intracranial infectious aneurysms. *J Neurol Neurosurg Psychiatry* 2008;79(8):943-946
- 8 Nakata Y, Shionoya S, Kamiya K. Pathogenesis of mycotic aneurysm. *Angiology* 1968;19(10):593-601
- 9 Bohmfalk GL, Story JL, Wissinger JP, Brown WE Jr. Bacterial intracranial aneurysm. *J Neurosurg* 1978;48(3):369-382
- 10 Cavassini M, Meuli R, Francioli P. Complications of infectious endocarditis. In: Scheld WM, Whitley RJ, Marra CM eds. *Infections of the Central Nervous System*. 3rd ed. Philadelphia, PA: Lippincott, Williams, & Wilkins; 2004:537-568
- 11 Ahmadi J, Tung H, Giannotta SL, Destian S. Monitoring of infectious intracranial aneurysms by sequential computed tomographic/magnetic resonance imaging studies. *Neurosurgery* 1993;32(1):45-49, discussion 49-50
- 12 Morawetz RB, Karp RB. Evolution and resolution of intracranial bacterial (mycotic) aneurysms. *Neurosurgery* 1984;15(1):43-49
- 13 Kovoor JM, Jayakumar PN, Srikanth SG, Sampath S. Intracranial infective aneurysms: angiographic evaluation with treatment. *Neurol India* 2001;49(3):262-266
- 14 Corr P, Wright M, Handler LC. Endocarditis-related cerebral aneurysms: radiologic changes with treatment. *AJNR Am J Neuroradiol* 1995;16(4):745-748
- 15 Chapot R, Houdart E, Saint-Maurice JP, et al. Endovascular treatment of cerebral mycotic aneurysms. *Radiology* 2002; 222(2):389-396
- 16 Zhao PC, Li J, He M, You C. Infectious intracranial aneurysm: endovascular treatment with onyx case report and review of the literature. *Neurol India* 2010;58(1):131-134
- 17 Ducruet AF, Hickman ZL, Zacharia BE, et al. Intracranial infectious aneurysms: a comprehensive review. *Neurosurg Rev* 2010;33(1): 37-46