

# Apoplexy in Optochiasmatic Cavernous Hemangioma Causing Visual Diminution: A Case Report

Sumit Bansal<sup>1</sup> Ashish Suri<sup>2</sup> Vaishali Suri<sup>3</sup> Aanchal Kakkar<sup>3</sup>

<sup>1</sup>Department of Neurosurgery, All India Institute of Medical Sciences, Bhubaneswar, Odisha, India

<sup>2</sup>Department of Neurosurgery, All India Institute of Medical Sciences, New Delhi, India

<sup>3</sup>Department of Neuropathology, All India Institute of Medical Sciences, New Delhi, India

**Address for correspondence** Sumit Bansal, MCh, Department of Neurosurgery, All India Institute of Medical Sciences, Room No. 419, Bhubaneswar, Odisha 751019, India (e-mail: drsumitbansal@gmail.com).

Indian J Neurosurg 2016;5:185–188.

## Abstract

### Keywords

- ▶ cavernous hemangioma
- ▶ optic chiasm apoplexy
- ▶ suprasellar lesion

This report concerns a woman who presented with abrupt onset of monocular visual symptoms accompanied by an intense holocranial headache, diagnosed as optic chiasm apoplexy caused by a cavernous hemangioma of the optic chiasm. The surgical and histologic findings demonstrated a cavernous hemangioma. The lesion was removed completely without any noticeable bleeding. The preoperative visual deficit improved after surgery.

## Introduction

Cavernous hemangioma of the optic chiasm is extremely rare, representing 1% or less of all cavernous hemangioma.<sup>1</sup> Klein et al described the earliest reported lesion in 1979.<sup>2</sup> Patients typically present with chiasmal apoplexy, characterized by sudden visual disturbance, headache, retro-orbital pain, and nausea.<sup>3</sup> Acute dysfunction of the chiasm and/or optic nerve has been called *chiasmatic apoplexy*<sup>3</sup> and/or *optic nerve apoplexy*.<sup>4</sup> Both are rare events.<sup>5</sup> Authors report here a rare patient who presented with optic chiasm apoplexy caused by a cavernous hemangioma of the optic chiasm.

## Case Report

### Presentation

A 40-year-old woman presented with sudden-onset right-sided visual diminution up to hand movement close to the face. Motor or sensory deficit was not associated. There were no symptoms suggestive of hypothalamic involvement.

### Imaging

On contrast-enhanced magnetic resonance imaging (MRI), heterogeneous enlargement of right half of chiasm was seen. The mass presented with central hypointensity on both T1- and T2-weighted images, without enhancement after gadolinium-DTPA injection. Preoperative diagnosis was chiasmatic cavernoma with apoplexy (▶ Fig. 1). Possibility of glioma also kept in differential diagnosis.

### Operative Procedure

The patient underwent a right pterional craniotomy. After elevation of the right frontal lobe and the removal of the arachnoid that covers the nerves and optic chiasm, a wine-colored, encapsulated mass was identified, located above the right optic chiasm. Surrounding hemosiderin staining was also seen in brain parenchyma. Capsule tissue was removed carefully without bleeding, preserving the contiguous anatomical structures. The postoperative course was uneventful.

### Follow-Up

The patient improved in right-sided vision up to finger counting to 2 ft after surgery. Immediate postoperative computed

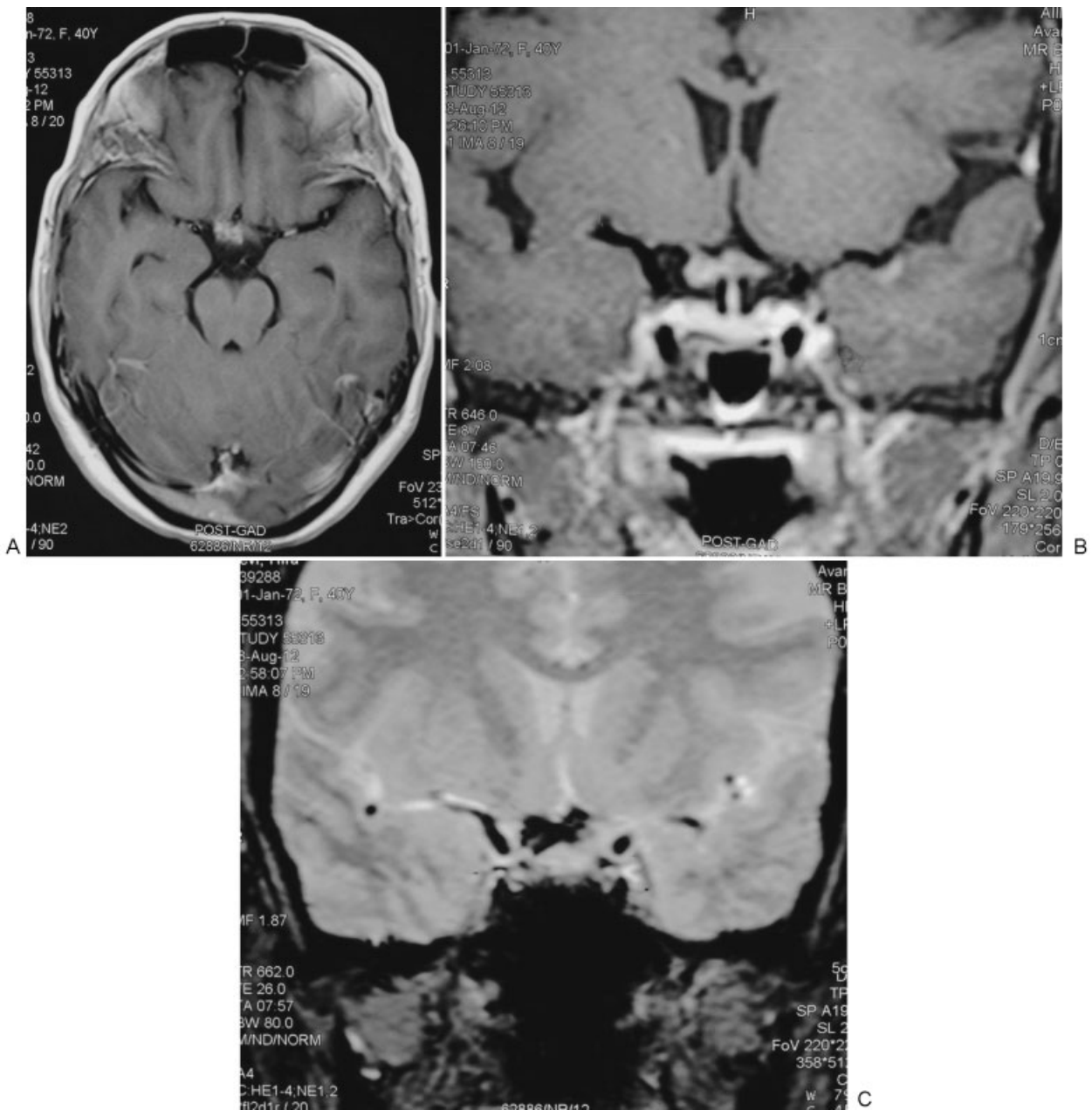
received  
December 15, 2015  
accepted  
January 14, 2016  
published online  
July 14, 2016

DOI <http://dx.doi.org/10.1055/s-0036-1584592>.  
ISSN 2277-954X.

© 2016 Neurological Surgeons' Society of India

License terms





**Fig. 1** Preoperative axial (A) and coronal (B), post-Gd T1-weighted and coronal gradient-echo (C) Magnetic resonance images demonstrating a hyperintense lesion located within the optic chiasm, with minimal enhancement. Blooming consistent with hemosiderin deposition is also seen (C).

tomographic (CT) scan showed complete excision of the lesion (→ Fig. 2). Postoperative MRI could not be done because patient lost to follow-up.

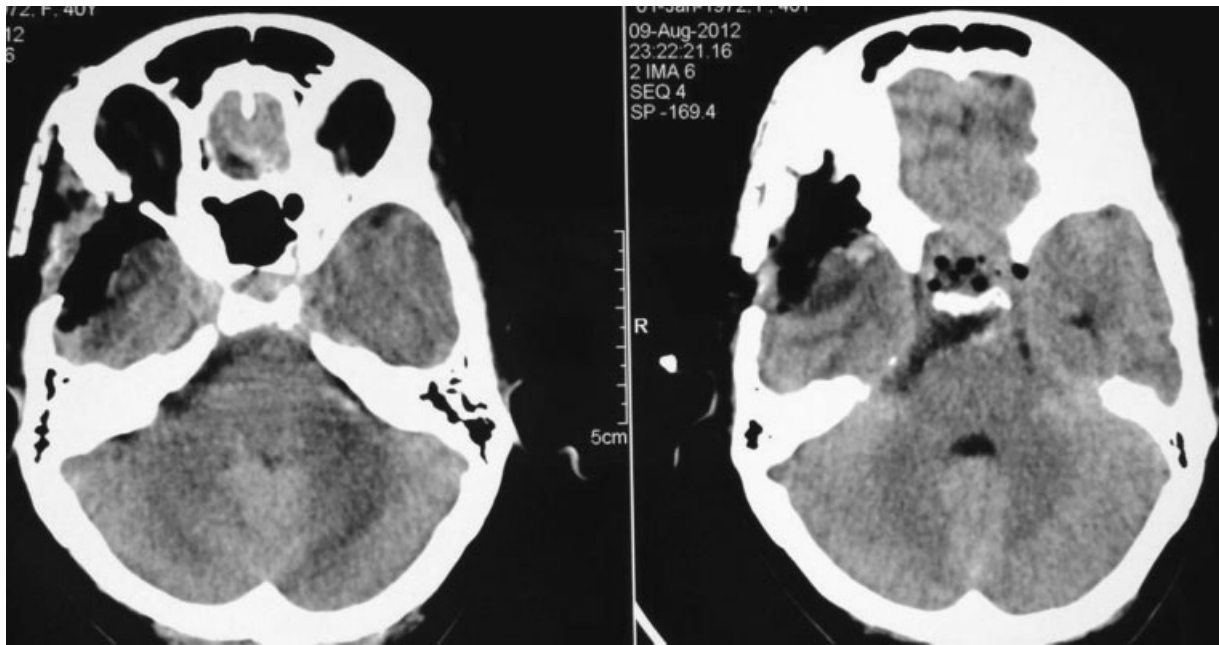
### Histopathologic Examination

Hematoxylin and eosin-stained sections examined from the mass showed a tumor composed of many interconnecting endothelium-lined vascular channels of irregular shape and varying size within a loose connective tissue stroma (→ Fig. 3A). These vascular channels were thin-walled, with little or no smooth muscle. Occasional vessel walls appeared thickened and hyalinized (→ Fig. 3B). Adjacent to these vessels, many hemosiderin-laden macrophages were seen.

A diagnosis of cavernous hemangioma was done on the basis of these features.

### Discussion

Optochiasmatic apoplexy is characterized by the abrupt onset of symptoms with loss of vision and reduction in the visual field associated with a predominantly retro-orbital headache.<sup>3</sup> They may be a result of an intratumoral hemorrhage such as occurs in hypophyseal tumors and gliomas.<sup>3</sup> Cases have been reported in which apoplexy is caused by arteriovenous malformations (AVMs) and optochiasmatic cavernomas.<sup>4,6-8</sup> Maitland et al used the



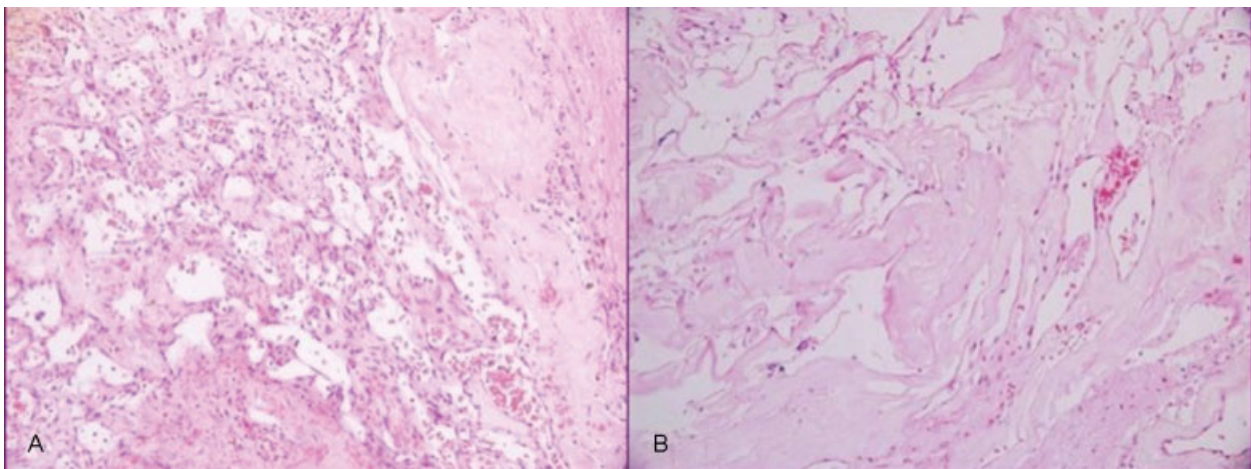
**Fig. 2** Postoperative images demonstrating complete resection of the optic chiasm cavernous hemangioma.

term “chiasmatic apoplexy” initially<sup>3</sup> and reported four cases with three AVMs and one glioma of the optic chiasm. Reilly and Oatey<sup>4</sup> introduced the term—“optic nerve apoplexy” and described two cases of a hematoma in the optic nerve; an AVM was identified in one case. The occurrence of optochiasmatic apoplexy caused by a histologically demonstrated cavernous angioma has been described but rarely. Lejeune et al,<sup>5</sup> in a review of the literature, found only seven reported cases. Most of the patients were between 20 and 40 years of age. In all of them, the cavernoma affected the optic nerve and chiasm. In our patient, the clinical syndrome was monocular on the right side, coinciding with the location of the cavernoma in the right optic chiasm. Other cases of cavernous angioma in the

optic nerve, in which no apoplexy occurred, have been reported.<sup>7,9</sup>

Typically, MRI scans demonstrate focal suprasellar lesions, with heterogeneous signal intensity, involving the optic pathways. Hyperintense areas suggest recent hemorrhage. If present, postcontrast enhancement should be minimal. Angiogram shows mass effect and, rarely, abnormal circulation.<sup>10</sup> At present, MRI offers the best possibility of describing the pathologic features.<sup>8</sup>

Apoplectic symptoms are frequently preceded by transient blurred vision and headache weeks or months beforehand. Surgical removal is the recommended treatment to restore or preserve vision, to decompress the visual apparatus, and to eliminate the risk of future hemorrhages.<sup>4,8,9</sup>



**Fig. 3** (A) Photomicrograph showing a cavernous hemangioma with variably sized communicating vascular channels (HE:  $\times 100$ ). (B) Higher-magnification view of the same lesion, with focal hyalinization of the vessel walls (HE:  $\times 200$ ).

The preferred surgical approach is a pterional craniotomy to provide adequate exposure of the optic apparatus and minimize brain retraction. After completion of the craniotomy, the optic apparatus appears edematous, with evidence of hemosiderin staining. This area of staining should be the point of entry and may be entered sharply with micro-scissors. The removal of the hematoma alone often leads to significant decompression. The cavernous hemangioma must be completely resected, however, because residual cavernous hemangioma can recur and lead to progressive symptoms. The resection should be performed sharply, with micro-dissectors. Traction on the cranial nerves must be limited, to avoid injuring normal tissue. The hemosiderin-stained tissue should not be resected, because it is not part of the cavernous hemangioma; its resection would injure eloquent tissue. There are reports of improved visual function after surgical treatment as in our case, and some advise immediate surgery.<sup>8</sup>

## Conclusion

All symptomatic lesions might be treated; surgical excision is the standard of care. Subtotal resection can lead to recurrence of the lesion, and gross total resection is thus crucial.

### Financial Support

None.

### Conflict of Interest

None.

## References

- 1 Hassler W, Zentner J, Wilhelm H. Cavernous angiomas of the anterior visual pathways. *J Clin Neuroophthalmol* 1989;9(3): 160–164
- 2 Klein LH, Fermaglich J, Kattah J, Luessenhop AJ. Cavernous hemangioma of optic chiasm, optic nerves and right optic tract. Case report and review of literature. *Virchows Arch A Pathol Anat Histol* 1979;383(2):225–231
- 3 Maitland CG, Abiko S, Hoyt WF, Wilson CB, Okamura T. Chiasmal apoplexy. Report of four cases. *J Neurosurg* 1982;56(1):118–122
- 4 Reilly PL, Oatey PE. Optic nerve apoplexy. Report of two cases. *J Neurosurg* 1986;64(2):313–316
- 5 Lejeune JP, Hladky JP, Dupard T, Parent M, Hache JC, Christiaens JL. Apoplexie opto-chiasmatic. *Neurochirurgie* 1990;36(5):303–307
- 6 Lavin PJM, McCrary JA III, Roessmann U, Ellenberger C Jr. Chiasmal apoplexy: hemorrhage from a cryptic vascular malformation in the optic chiasm. *Neurology* 1984;34(8):1007–1011
- 7 Maruoka N, Yamakawa Y, Shimauchi M. Cavernous hemangioma of the optic nerve. Case report. *J Neurosurg* 1988;69(2): 292–294
- 8 Mohr G, Hardy J, Gauvin P. Chiasmal apoplexy due to ruptured cavernous hemangioma of the optic chiasm. *Surg Neurol* 1985; 24(6):636–640
- 9 Costa e Silva I, Symon L. Cavernous hemangioma of the optic canal. Report of two cases. *J Neurosurg* 1984;60(4):838–841
- 10 Simard JM, Garcia-Bengochea F, Ballinger WE Jr, Mickle JP, Quisling RG. Cavernous angioma: a review of 126 collected and 12 new clinical cases. *Neurosurgery* 1986;18(2):162–172