

# Rhinoplasty: The Asymmetric Crooked Nose— An Overview

Aaron M. Kosins, MD<sup>1</sup> Rollin K. Daniel, MD<sup>1</sup> Dananh P. Nguyen, BS<sup>1</sup>

<sup>1</sup>Department of Plastic Surgery, University of California, Irvine Medical Center, Orange, California

Address for correspondence Aaron M. Kosins, MD, 1441 Avocado Ave., Suite 308, Newport Beach, CA 92660 (e-mail: aaronkosins@gmail.com).

Facial Plast Surg 2016;32:361–373.

## Abstract

There are three reasons why the asymmetric crooked nose is one of the greatest challenges in rhinoplasty surgery. First, the complexity of the problem is not appreciated by the patient nor understood by the surgeon. Patients often see the obvious deviation of the nose, but not the distinct differences between the right and left sides. Surgeons fail to understand and to emphasize to the patient that each component of the nose is asymmetric. Second, these deformities can be improved, but rarely made flawless. For this reason, patients are told that the result will be all “-er words,” better, straighter, cuter, but no “-t-words,” there is no perfect nor straight. Most surgeons fail to realize that these cases represent asymmetric noses on asymmetric faces with the variable of ipsilateral and contralateral deviations. Third, these cases demand a wide range of sophisticated surgical techniques, some of which have a minimal margin of error. This article offers an in-depth look at analysis, preoperative planning, and surgical techniques available for dealing with the asymmetric crooked nose.

## Keywords

- ▶ crooked nose
- ▶ rhinoplasty
- ▶ septoplasty
- ▶ asymmetric nose
- ▶ osteotomies

There are three reasons why the asymmetric crooked nose is one of the greatest challenges in rhinoplasty surgery. First, the complexity of the problem is not appreciated by the patient nor understood by the surgeon. Patients often see the obvious deviation of the nose, but not the distinct differences between the right and left sides. Surgeons fail to understand and to emphasize to the patient that each component of the nose is asymmetric. Second, these deformities can be improved, but rarely made flawless. For this reason, patients are told that the result will be all “-er words,” better, straighter, cuter, but no “-t-words,” there is no perfect nor straight. Most surgeons fail to realize that these cases represent asymmetric noses on asymmetric faces with the variable of ipsilateral and contralateral deviations. Third, these cases demand a wide range of sophisticated surgical techniques, some of which have a minimal margin of error. This article offers an in-depth look at analysis, preoperative planning, and surgical techniques available for dealing with the asymmetric crooked nose.

## Review of Literature

The initial description of the crooked nose and its surgical management were linked to posttraumatic and congenital deformities.<sup>1–6</sup> Converse stated that “the deviated or twisted nose is most often of traumatic origin.”<sup>3</sup> With time, surgeons began to emphasize the importance of correcting inherent septal deviations while maintaining septal support.<sup>3–5</sup> Surgeons combined these septal concepts with treatment algorithms for the bony vault to obtain a more comprehensive approach.<sup>4,6</sup> To treat the upper third of the nose, medial and lateral osteotomies were used to allow total movement of the bony walls, thus avoiding postoperative relapse.<sup>2</sup> Asymmetric and multiple osteotomies were employed compared with the standard aesthetic rhinoplasties.<sup>6</sup> Internal, external, and double-level osteotomies can be done to achieve greater symmetry of the nasal bones. Regarding the middle third, it has long been recognized that intrinsic and extrinsic cartilaginous forces are responsible for the crooked nose.<sup>2,4</sup> The extrinsic deforming forces must be released and has been done in the following

manner: (1) the cartilaginous vault is split by detaching the upper lateral cartilages from the dorsal septum, (2) the septum is exposed by elevating the restrictive perichondrium, and (3) the lower lateral cartilages are separated from the upper lateral cartilages at the scroll region either directly or by cephalic trim. Once this has been completed, the intrinsic septal deformities can be assessed. Correcting septal deformities is critical to treating the crooked nose. Maintenance of a 10- to 15-mm L-strut of cartilage is essential to support the cartilaginous dorsum. Methods of scoring, excision, spreader grafts, spreader flaps, and extramucosal replacement of the septum have been used to straighten the dorsum.<sup>3,4,6</sup> Treatment of internal valve collapse and inferior turbinate hypertrophy is paramount to correct the functionally compromised airway of a crooked nose. Caudal nasal deviation has been treated with scoring, excision, excision and replacement, and repositioning of the septum on the anterior nasal spine (ANS).<sup>5</sup> Fracture of the ANS has also been described if this bony structure is deviated.<sup>6</sup>

Intrinsic deformities of the lower lateral cartilages can also cause nasal deviation.<sup>7</sup> These asymmetries can result in different lengths of the medial and middle crura, as well as concavity and convexity differences in both the vertical and horizontal axes of the lateral crura.<sup>8</sup> This asymmetry can be subtle or extreme in the form of congenital deficiencies of alar cartilage viewed as divisions, gaps, and segmental loss.<sup>9</sup> Columellar struts, tip suturing techniques, and excision of both medial and lateral crura have been used to correct these deviations.<sup>10,11</sup>

It is only recently that surgeons have emphasized the dominant role of inherent asymmetry as the critical factor in managing the nontraumatic crooked nose. Daniel coined the term the “asymmetric developmentally deviated nose” (ADDN) to emphasize the role of asymmetry and development in the etiology of the problem.<sup>12</sup> Vuyk pointed out that the crooked nose often exists on the asymmetric face, and these asymmetries can come in multiple patterns.<sup>13</sup> Based on this review, it is obvious that there is a distinct continuum between the crooked and the asymmetric nose. The term *crooked* is defined as bent, curved, or twisted out of shape or out of place. In contrast, the term *asymmetric* refers to having two sides or halves that are not the same. Thus, the surgeon approaches the crooked nose with a goal of restoring the nose to its original shape and position. In contrast, the surgeon must approach the asymmetric nose with the understanding that the problem is even more complex and that two sides of the nose have never been symmetrical. Thus, the surgical objective is not restoration, but rather creation of a more attractive, symmetrical nose. Essentially, everything that contributes to the crooked nose—osseocartilaginous vaults, septal deviation, etc.—is further compounded in ADDN by asymmetry in all components of the nose and even the face. This article approaches the problem of the asymmetric nose from the perspective of the patient seeking a cosmetic rhinoplasty.

## Patient Analysis

A thorough nasal history is important with emphasis on prior trauma, medical conditions, and previous surgical treatment.

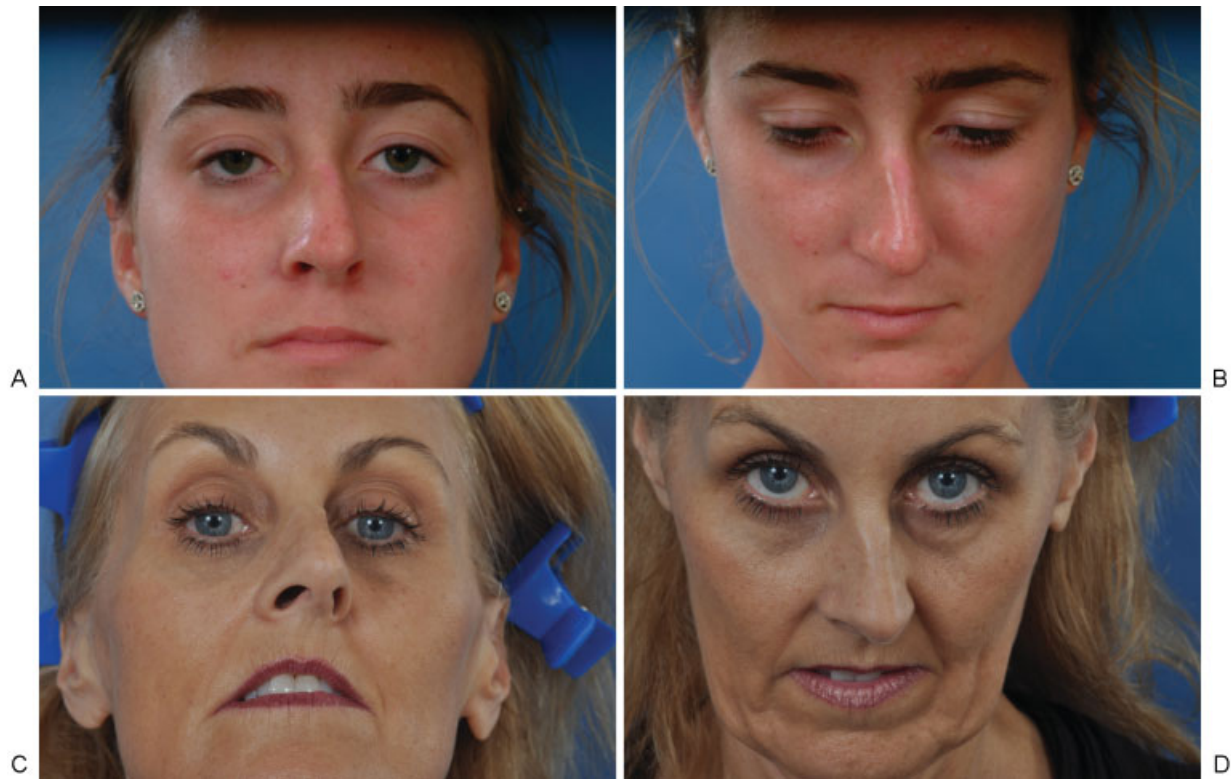A standard consultation sequence is as follows: (1) the patient is asked what three things bother him or her the most about his or her nose, (2) the external nose is examined from all four views, (3) the internal nose is examined before and after decongestant spray, including air flow through each nostril on deep inspiration, and (4) the findings are recorded and explained to the patient. Endoscopy can be added as necessary. Photographs are taken in four standard views plus additional partial head-up, partial head-down, and top-down (helicopter) views. The reality of nasal and facial asymmetry within the context of embryology and development is explained to the patient.

In our practice, the extent of asymmetry is recorded on the consent page. It is our conclusion that more than 98% of patients have a face with a strong right side and weak left side, with the right nasal bone being convex and the left nasal bone being concave. In the majority of cases, the facial midline is deviated to the right. As regards the nasal and facial deviations, there are two possible deformities: the nasal and facial midlines are deviated to the same side (ipsilateral) or to opposite sides (contralateral). We have found that the partial head-down view best illustrates the severity of septal deviation, while the partial head-up view best illustrates asymmetry of the bony vault and that of the maxilla (►Fig. 1). The top-down or “helicopter” view reveals the complexity of the problem, especially if the forehead is used as a horizontal and midline reference.

The more severe the asymmetry, the more valuable a computed tomography (CT) scan of the face with three-dimensional reformation becomes.<sup>14</sup> With these scans, several measurements can be taken to measure the finite asymmetries from the midline, including upper and lower width of the pyriform aperture, differences in height of the maxillae, ANS deviation, and dental deviation. The analyze tool is used to measure linear and angular distance. In addition, bony and soft tissue landmarks can be evaluated.<sup>15</sup> CT scans allow the surgeon to define the preexisting nasal and facial midlines as well as to decide where the postoperative midline should be. For example, in certain cases, the asymmetry of the nose can be complicated by rotational deformities of the maxilla with the ANS deviated 10 mm and the caudal septum deviated 14 mm from the desired facial midline (►Fig. 2). Operative planning is recorded throughout the examination process.

## Components

The following is our comprehensive approach and treatment plan for managing a patient with ADDN. In general, one can set an intercanthal or intraeyebrow midline and draw a vertical through this point to serve as the theoretical midline for the face and nose. Frequently, the lower two-third of the face is deviated significantly to one side. The nasal midline and dorsal aesthetic lines are most easily marked using a top-down view and palpating the structures followed by photographs. The height of the dorsum and the need for reduction is carefully assessed, particularly as regards asymmetric reduction. Next, the shape, height, and position of each lateral bony wall are assessed. The shape ranges from concave to



**Fig. 1** (A) Partial head-up view in a 26-year-old patient with asymmetric developmentally deviated nose (ADDN). (B) Partial head-down view in a 26-year-old patient with ADDN. (C) Partial head-up view in a 51-year-old patient with ADDN. (D) Partial head-down view in a 51-year-old patient with ADDN.

straight to convex, which will affect the choice of osteotomies, including intermediate osteotomies, which become very important. The height of each wall is measured from the anterior border of the maxilla to the aesthetic dorsal line. The position of the widest point of the bony vault (x-point) is marked as it is a key determinant of the lateral osteotomies. Key photographs are repeated (► **Fig. 3**).

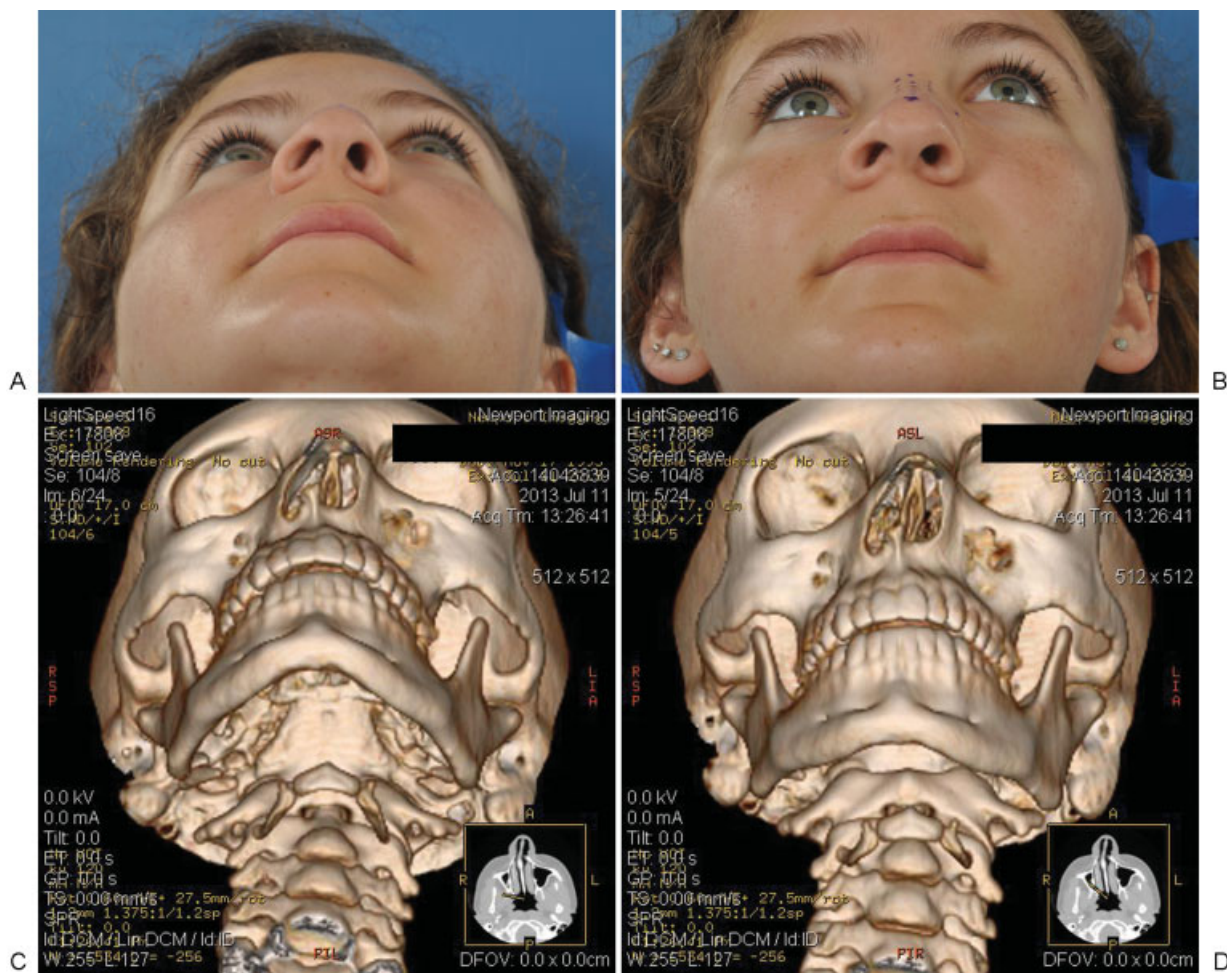### Exposure

An open approach is favored as it permits complete visualization. Once the skin has been elevated over the alar cartilages, the soft tissue of the dorsum is elevated in a continuous subperichondrial–subperiosteal plane rather than a sub-superficial musculoaponeurotic system plane. This deeper dissection facilitates preservation of the upper lateral cartilages and utilization of power tools and piezosurgery. Next, a unilateral right transfixion incision is used for exposure of the septum and the ANS. If additional septal exposure is required, then the upper lateral cartilages can be split off from the septum, which creates a *bidirectional approach* to the entire septum. Extramucosal tunnels are dissected under the upper lateral cartilages on either side in preparation for a split hump reduction.

### Dorsal Reduction

The extent and method of dorsal reduction must be carefully considered. The authors recommend the following approach: (1) incremental reduction of the dorsum in two stages—an

initial significant reduction followed by fine-tuning once the osteotomies and septal relocation have been completed, (2) rasp or piezoreduction of the bony cap initially,<sup>16</sup> (3) cartilage vault split with preservation of the upper lateral cartilages, and (4) reduction of the dorsal septum. It is almost universally agreed that an angled reduction of the bony vault should be done when asymmetrically oriented nasal bones are present.<sup>3</sup> Yet, is this concept correct? Virtually all rhinoplasty textbooks show a variation of the Converse triangle diagram emphasizing that the reduction should be lower on the longer angled concave side and higher on the shorter vertical convex side (► **Fig. 4**).<sup>17</sup> The rationale is that as the bones are medialized following the lateral osteotomies, their heights will be correct. In contrast, if a straight horizontal resection was done, then the vertical side would end up too short. This dictum can be misleading *in ADDN* for the following three reasons: (1) the triangular concept assumes that the bases are at the same level, thus discounting significant differences in the level of the maxilla, (2) shortening can be done at the base of the lateral wall and not just at the top, and (3) an incremental bony vault reduction using rasps is advocated rather than the classic en bloc osseocartilaginous excision employing an osteotome. In contrast to geometry where the hypotenuse of a triangle is always longer than the sidewall, the vertical concave wall resting on a retruded maxilla can be longer than the angled straight wall resting on a prominent maxilla. Thus, it is critical to measure the relative height of each lateral bony wall. In significant length discrepancies, it is simpler to create



**Fig. 2** A 16-year-old patient with severe asymmetric developmentally deviated nose showing (A) basilar, (B) partial head up, and (C, D) computed tomography (CT) scan views of her face. The CT scan confirms more than 10-mm displacement of her anterior nasal spine and caudal septum. It also demonstrates the height discrepancy of her nasal bases and maxillae.

lateral walls of equal height by combining a low-to-low and a low-intermediate osteotomy on the longer side placing the latter at the same point as the length of the shorter side (→ Fig. 5). Rasping the bony vault first minimizes the chances of excessive excision common with an osteotome. The upper lateral cartilages are not excised as they are often used for spreader flaps. As emphasized by Cerkes, the dorsal cartilaginous septum is excised with a no. 11 blade incrementally leaving slight excess until the septal work is completed.<sup>16</sup>

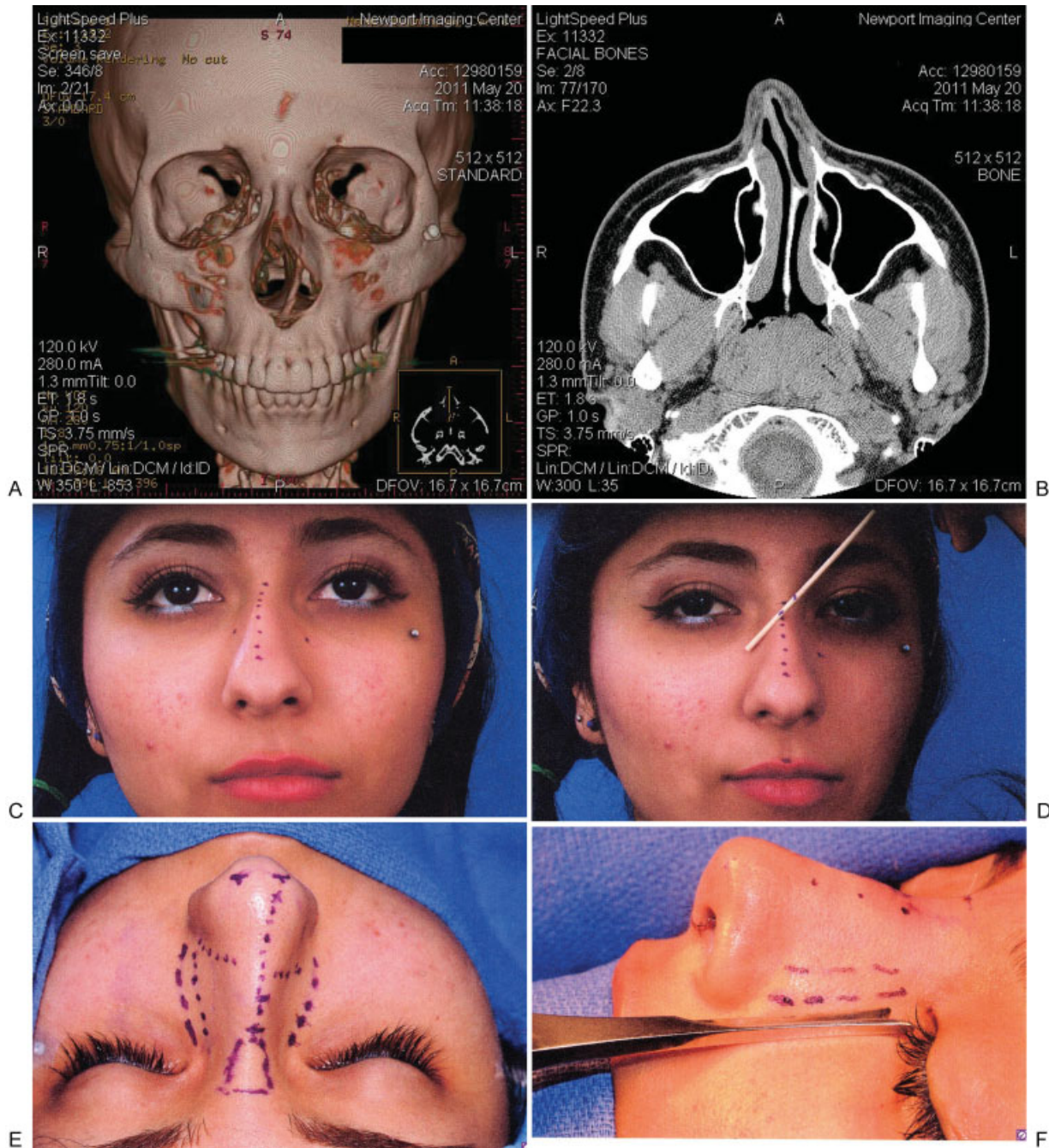
### Septum and Turbinates

As previously reviewed, the vast majority of recent publications on the crooked nose have concentrated on diagnosis, classification, and management of the deviated septum. From our experience, we would recommend a bidirectional approach to septal exposure using an inferior exposure via an extended unilateral transfixion incision plus a dorsal split via the open approach.<sup>17</sup> In general, we do not advocate scoring or multiple incisions of deviated cartilage to straighten it. These procedures inherently weaken the cartilage and their long-term efficacy is questionable. One can summarize the principles of septal surgery in primary rhinoplasty cases as

follows: (1) maintain a 10- to 12-mm L-shape strut; (2) the deviated body of the septum can be resected and used for grafts; (3) the caudal septum must be brought to the midline preferably with suture fixation through a drill hole in the ANS; (4) if the caudal portion is deformed, it can be splinted or replaced as necessary; (5) the deviated dorsal limb is incised or excised, but always splinted with spreader grafts; and (6) if the structural integrity of the L-shape strut is lost, then a subtotal or total septoplasty is done.<sup>18</sup> In its fullest expression, we have found the following four problems to be associated with ADDN: (1) severe caudal septal deviation of 8 to 14 mm, (2) deviation of the body of the septum up against the convex bony wall, (3) deviation within the dorsal segment, and (4) large concha bullosa of the middle turbinate and/or compensatory hypertrophy of the inferior turbinate on the side opposite to the septal body deviation.

### Osteotomies

The osteotomies are always done following dorsal reduction and septal surgery. Selection of osteotomies is the most challenging aspect of operative planning for managing the asymmetric nose as the combination is virtually limitless. The



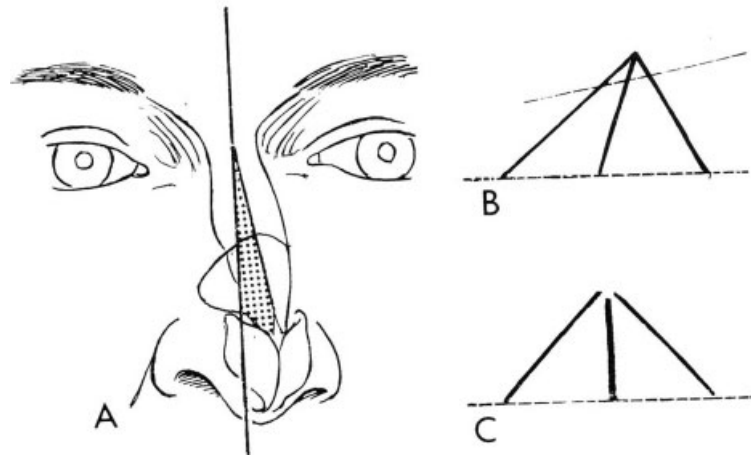
**Fig. 3** (A, B) Computed tomography scan reformatting of a 26-year-old patient. Note the septal deviation, right nasal bone convexity, and left nasal bone concavity. This will affect the choice of osteotomies, including intermediate osteotomies. (C, D) The height of each wall is measured from the anterior border of the maxilla to the aesthetic dorsal line. (E, F) The dorsal deviation is marked as well as osteotomies to equalize the bony wall heights and x-points. This patient received bilateral medial oblique osteotomies, a right low-to-low osteotomy, a left low-intermediate osteotomy (to equalize the lateral wall heights), and a left low-to-low osteotomy via an intraoral approach to equalize the x-points.

decision process must answer the following questions before the osteotomies are selected: (1) Is the radix deviated and are transcutaneous root osteotomies necessary? (2) On the dorsum, is there a midline deviation of the osseocartilaginous vault and are each of the dorsal lines deviated? (3) What is the shape (convex, straight, or concave) and height of each lateral wall? and (4) What is the base bony width (x-point) on each side? For the majority of cases, the osteotomies are done as a progression: dorsum, then lateral wall, and finally lateral

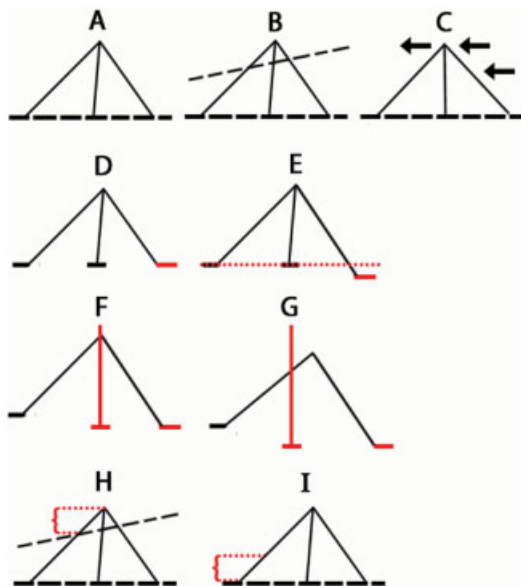
base. With our recent progression to piezoelectric instrumentation, the operative exposure and control of the bony vault has been significantly improved.<sup>19</sup>

**Radix/nasion deviation:** The term “nasion” can have two distinctly different meanings: the bony anthropometric nasion occurring at the nasofrontal suture line, and the soft tissue clinical nasion occurring at the deepest point of the nasofrontal angle, which often corresponds to the bony sellion.<sup>20</sup> This distinction becomes critical in understanding Ellis

This document was downloaded for personal use only. Unauthorized distribution is strictly prohibited.



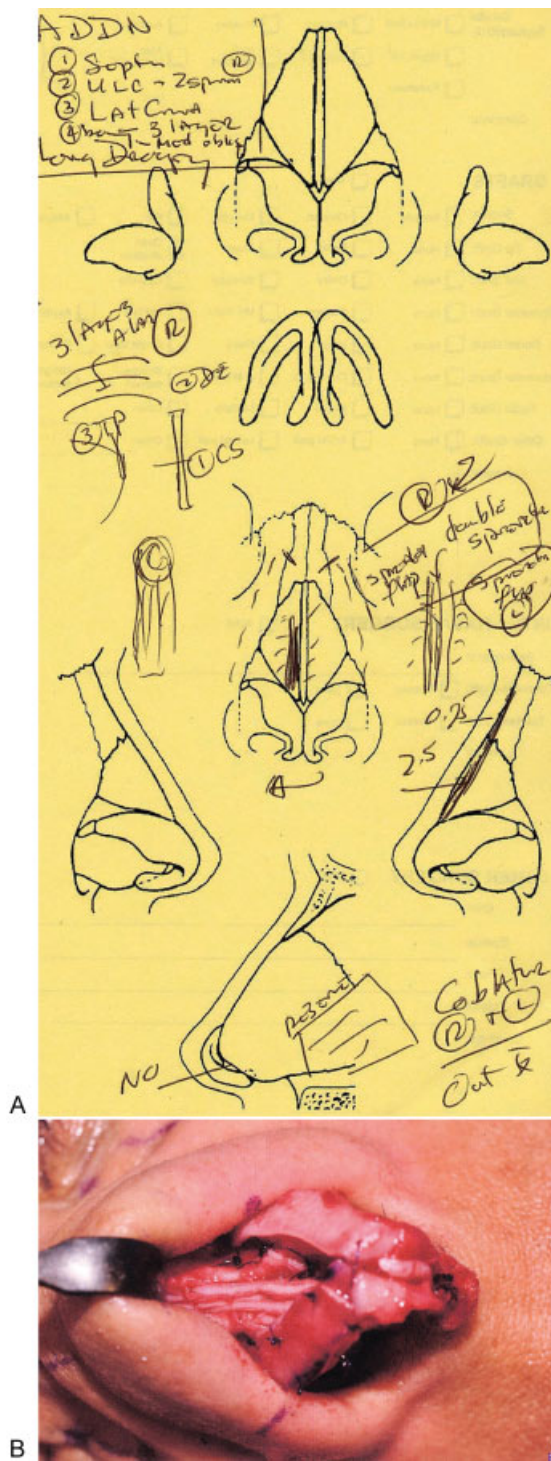
**Fig. 4** (A–C) A rendering of the Converse original diagram visualizing the nasal bony pyramid as a triangle. This way, when osteotomies were used to straighten the nose, the nasal heights would be similar.



**Fig. 5** Unlike the Converse original diagram, the presence of dorsal asymmetry, maxillary asymmetry, and ipsilateral versus contralateral deviations require careful analysis for planning of osteotomies. (A–C) Illustration of the Converse sequence. Converse recommended an asymmetric dorsal reduction (usually with an osteotome) so that when osteotomies were used to straighten the nose, the nasal bones would be of equal height. (D) In this rendering, the nose deviates to the left, and the Converse sequence makes sense because the maxilla are equal in height and the right nasal bone is longer than the left. (E) However, in the asymmetric developmentally deviated nose (ADDN), the nose can deviate and the maxilla is more hypoplastic on the side of the deviation. Now the left nasal bone is longer than the right and usually much more concave. Dorsal modification alone will not equalize the heights of the nasal bones. (F, G) This becomes even more complex when looking at ipsilateral and contralateral deviations. In (F), the deviation of the nose is ipsilateral to the facial deviation (illustrated by the red midline), whereas in (G) they are contralateral. It is these variables of dorsal asymmetry, maxillary asymmetry, and ipsilateral versus contralateral deviations that required multiple, asymmetric osteotomies to treat the ADDN and to set the new dorsal aesthetic lines cephalically. (H, I) The final complicating factor is whether or not a hump is present. In (H), there is a dorsal hump, and equalization of the lateral height can be done at the dorsum. However, if no hump is present, the equalization can only be done at the level of the maxilla. In summary, the ADDN requires careful analysis of the nasal bones and maxilla independently. Equalization can be done dorsally, at the maxillary base, or both, depending on the case.

and Shaikh's "open book" concept for correcting the crooked nose.<sup>21</sup> Ellis and Shaikh discuss their approach to noses in which the nasion is deviated off the facial midline and those where the nasion is in the midline, but the rhinion is deviated. For simplicity and clarity, we will define bony vault deviation using the following terminology: (1) nasion will refer to the soft tissue nasion, (2) deviation above this point will be considered a radix deviation as it is solid bone, (3) deviation below this point will be considered bony deviation and osseocartilaginous vault deviation where one must consider the bony midline and each dorsal line. Based on our clinical CT scan analysis, we have found radix deviation above the nasion relatively rare, which is fortunate as its surgical correction is demanding. Ellis and Shaikh use multiple osteotomies in the solid bone of the radix, including two transverse obliques, two medial, and one transverse root osteotomy. The transverse root osteotomy is done with a 2-mm osteotome, which essentially crosses the nasofrontal suture line, thereby connecting the two medial osteotomies and partially osteotomizing the vertical plate of the ethmoid.

**Dorsal bony deviation:** The bony portion of the *postreduction* dorsal lines determines the dorsal osteotomies.<sup>16</sup> After piezo rasp removal of the bony cap and reduction of the dorsal cartilaginous septum, the nasal bones appear wider as the medial, cartilaginous portion has been removed. The cephalic portion of the *postreduction* dorsal lines is created with dorsal osteotomies, and the options include medial, paramedian, and medial oblique. True medial osteotomies are made parallel and adjacent to the septum and are almost never done in our practice. Paramedian osteotomies are made parallel to the septum, but several millimeters from center. Medial oblique osteotomies begin in the open roof and then fade from the midline 15 to 25 degrees. The purpose of medial osteotomies is to narrow the dorsum and to facilitate medial movement of the bone once the lateral osteotomies are completed, and are most frequently used for deviations extending above the nasion. Most paramedian osteotomies are done in wide noses with a profile that does not require reduction but the walls need mobilizing to narrow the nose. Medial oblique osteotomies can be done at various angles,



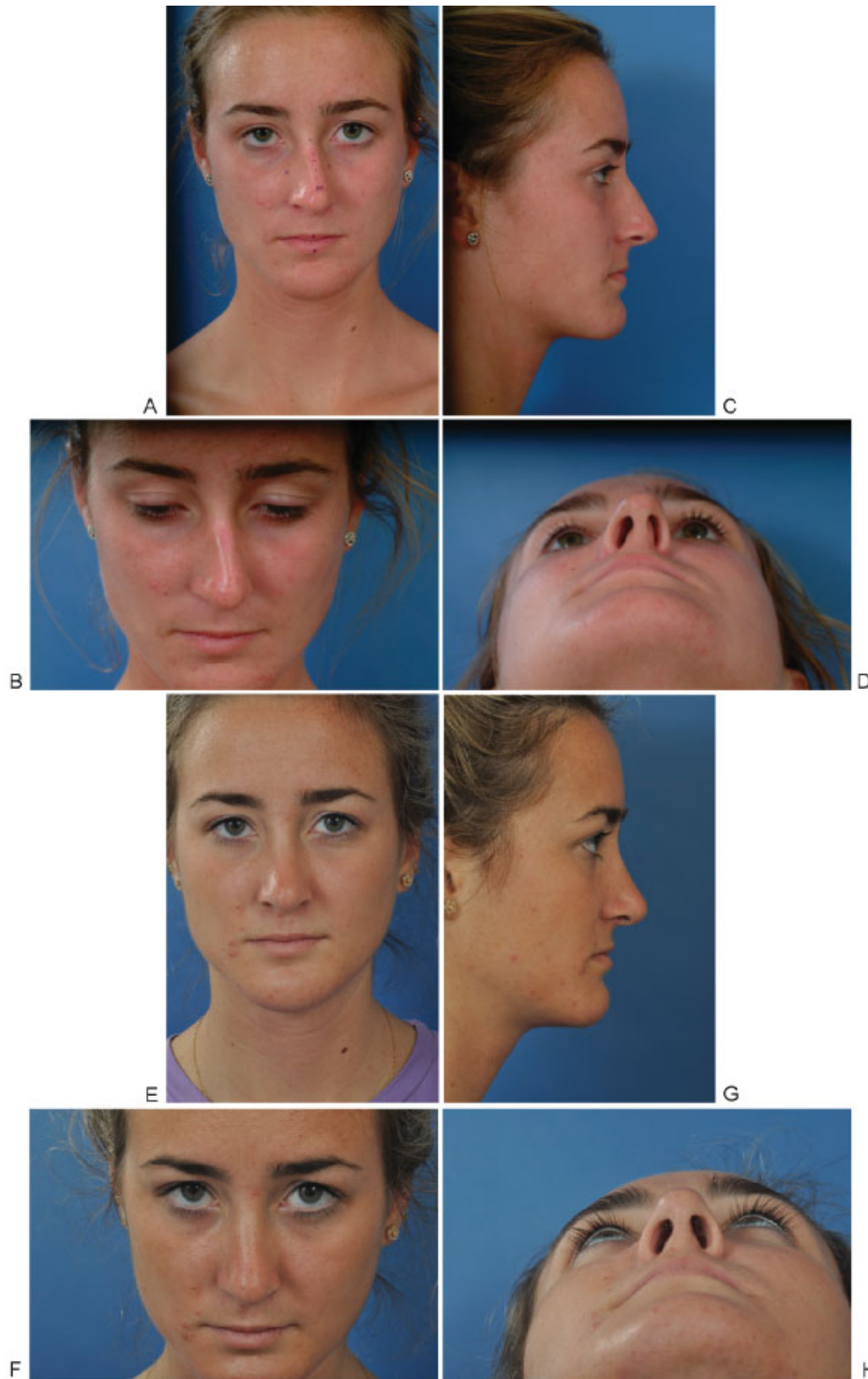**Fig. 6** (A) Operative plan including reconstruction of cartilaginous vault in a patient with asymmetric developmentally deviated nose. (B) Cartilaginous vault reconstruction includes a spreader flap on the left, and a spreader flap, full length spreader graft, and “doorstop” spreader graft caudally on the right.

ranging from the traditional 10 to 15 degrees off center to a more fading 25 to 35 degrees, as recommended by Gruber et al.<sup>22</sup> Our preference is to determine where the dorsal line starts to deviate from the desired line and fracture the bone with a medial oblique osteotomy at that point.

**Lateral wall:** Changes in the shape of the lateral wall were first championed by Parkes et al<sup>23</sup> with their concept of a double-level osteotomy to correct the convex lateral wall. They called it an intermediate osteotomy because it was in between the standard medial and lateral osteotomies. Anatomically, it fell approximately on the suture line between the nasal bone and the frontal process of the maxilla. Due to the complexity of the asymmetric noses, we have expanded this concept to three types of intermediate osteotomies: high, midlevel, and low.<sup>18</sup> The intermediate osteotomy is always done after any medial osteotomy, but before the lateral osteotomy. It is essentially straight and is done with a straight V-shaped 3-mm osteotome. The *high intermediate* osteotomy is 3 to 5 mm below and parallel to the dorsal bony edge. The goal is to narrow the dorsal lines. The *midlevel intermediate* osteotomy is placed at the point of maximum convexity of the lateral bony wall, which often corresponds to the suture line between nasal bone and frontal process of maxilla, and the goal is to decrease the convexity of the bony wall. The *low intermediate osteotomy* is used to shorten the long nasal bone (in height) and is thus placed to match the opposite shorter bone. It is essentially straight like a low-to-low osteotomy and passes across the frontal process of the maxilla. With piezosurgery, we have found less and less need for intermediate osteotomies as the bones can be sculpted to remove convexities and to smooth asymmetries, that is, ultrasonic rhinosculpture.

**Base bony width:** The ideal base bony width has been defined as being 1 to 2 mm narrower than the medial canthus. Due to the significant asymmetry, the width of each lateral wall must be assessed separately. Ellis and Shaikh emphasized that there is often no need to do a lateral osteotomy on the concave side of the deviation as medial and transverse osteotomies would suffice to “open the book.” We have also found that a lateral osteotomy is not necessary in many asymmetric noses. We continue to use both low-to-high and low-to-low continuous osteotomies for less severe cases. However, we prefer a percutaneous osteotomy using a 2-mm osteotome for markedly asymmetric bones and a transgingival approach using a power saw for severe height discrepancies. Continuous osteotomies using a straight osteotome are essentially the same on the two sides with their vertical level being the only variation. In contrast, the percutaneous osteotomy is easily modified to fit the intrinsic asymmetry of the lateral bony walls. Frequently, the location of the widest base bony point of the lateral nasal wall (x-point) varies as regard to both width and height relative to the medial canthus. Technically, one can pass beneath the x-point, thereby insuring the desired narrowing followed by ascending and descending appropriately to complete the lateral osteotomy. The intraoral approach for lateral osteotomies is advocated by numerous surgeons to achieve a truly low position on the face of the maxilla.<sup>24</sup>

**Movement:** Surgeons have long considered the only movement of the lateral wall following osteotomy to be medial. However, in the asymmetric nose, the bone is often moved medially on the convex lateral wall, whereas the concave lateral bony wall must move laterally. Unlike the bone that is



**Fig. 7** A 26-year-old female with grade 1 asymmetric developmentally deviated nose. The treatment involved an open approach as well as septoplasty. After a 2- to 3-mm dorsal reduction (more reduction done on the right side), the left side of the anterior nasal spine (ANS) was removed, and the caudal septum was relocated and secured to the right side via a drill hole in the ANS. The nose was then straightened from the top down. The nasal bones required asymmetric, medial oblique osteotomies to medialize and to straighten the nasal bones. Next, a right midlevel intermediate osteotomy was done to remove the convexity from the right nasal bone. Finally, low-to-low osteotomies were performed bilaterally to narrow the base bony width. Asymmetric spreader grafts (2.2 mm right and 1.2 mm left) were then placed to treat the open roof and to straighten the osseocartilaginous vault. The tip was considered nearly ideal and domal equalization sutures were placed bilaterally for symmetry. No alar base reductions or grafts of the nostril rims were required. (A) Preoperative anteroposterior (AP) view. (B) Preoperative partial head-down view. (C) Preoperative lateral view. (D) Preoperative basilar view. (E) Postoperative AP view at 14 months. (F) Postoperative partial head-down view at 14 months. (G) Postoperative lateral view at 14 months. (H) Postoperative basilar view at 14 months.

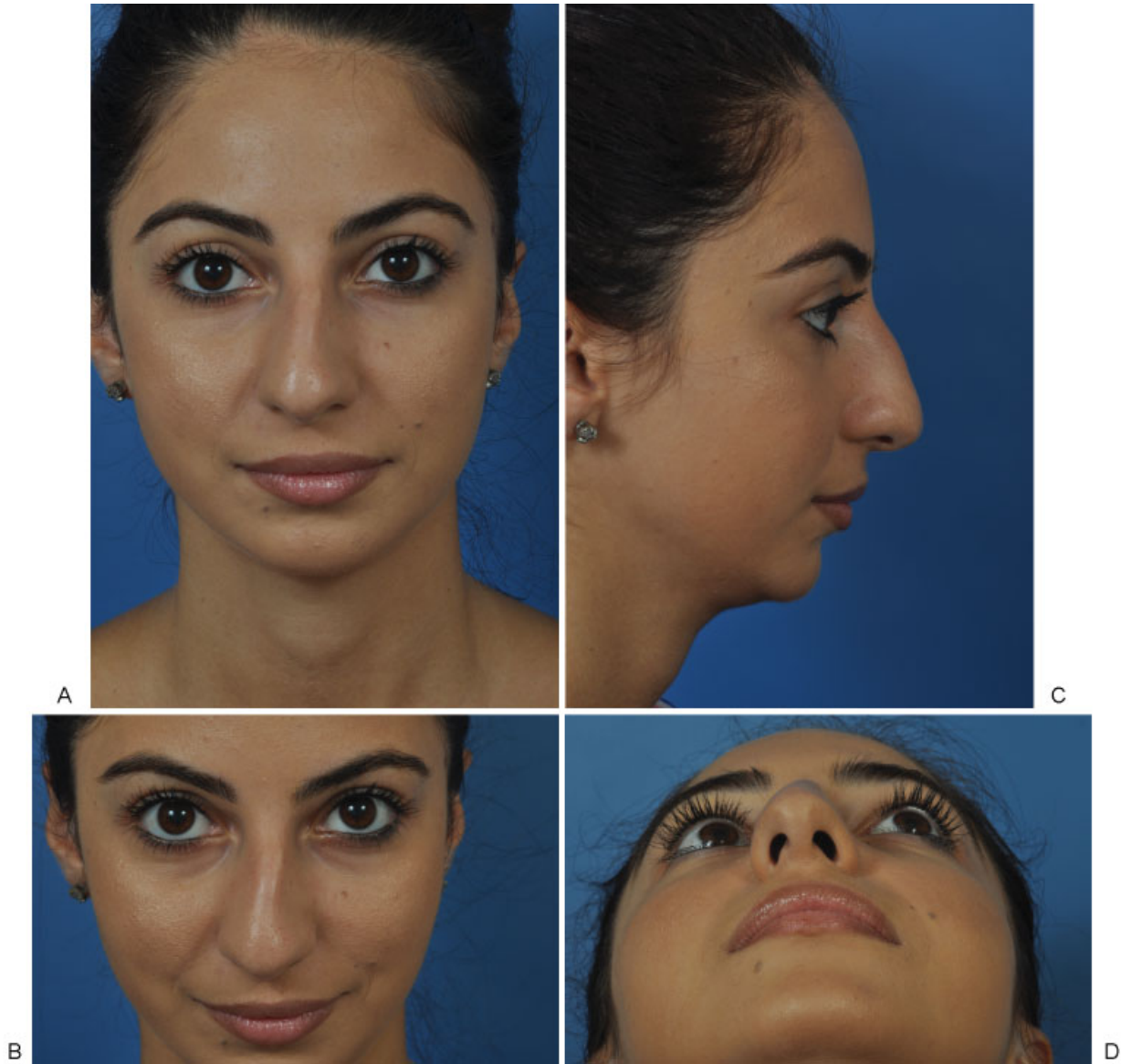

moved medially, the bone moved laterally must be braced by a long spreader graft extending into the bony vault to stent the bone out after osteotomy.

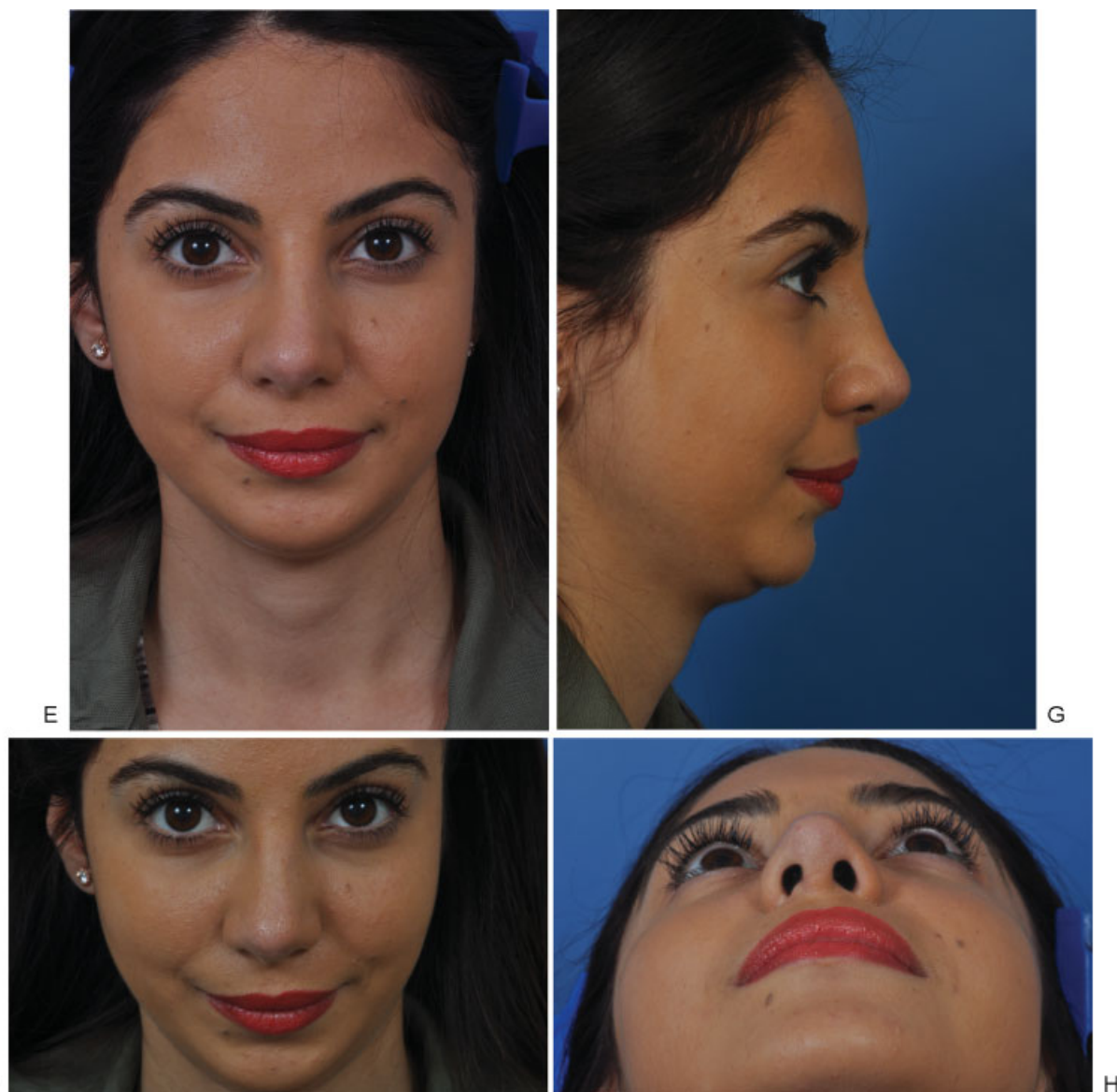### Cartilage Vault

Dorsal septal deviation is readily apparent on inspection, whereas asymmetry and deformity intrinsic to the upper

lateral cartilages is more difficult to appreciate. Spreader grafts were originally devised by Sheen<sup>25</sup> to treat midvault collapse, thereby preventing the external visible inverted-V deformity and functional internal valve collapse. If one focuses on the *prereduction* dorsal aesthetic lines, the upper portions are expressed by the cartilaginous vault under a thin bony cap, whereas the lower portion is determined solely



**Fig. 8** A 31-year-old female with grade 2 asymmetric developmentally deviated nose. The treatment of this patient involved an open approach. After rasping of the bony cap, a hump reduction with scissors (4 mm) was performed. The lateral wall heights were asymmetric. The left nasal wall height was 7 mm longer than the right; however, the maxillary heights were symmetric. To account for the difference in height, the hump reduction was done with asymmetric rasping and dorsal reduction (more reduction done on the left). A septoplasty was then completed and the caudal septum was relocated to the left side and secured via a drill hole in the anterior nasal spine. The nose was then straightened from the top down. Even with asymmetric reduction of the nasal hump, the nasal bones required asymmetric medial oblique osteotomies not only to medialize and straighten the dorsal nasal bones, but also to equalize the lateral wall heights. Bilateral low-to-low osteotomies were done last to move the right nasal bone medially (inward displacement) and the left nasal bone laterally (outward displacement). To straighten the osseocartilaginous vault, a spreader flap was placed on the right, and a full-length spreader graft (2 mm width) and partial length spreader (4 mm width) were placed on the left. The left full-length spreader graft was placed high in the open roof to reconstruct the middle vault and also to stent out the left nasal bone. The tip was completed with a columellar strut, as well as tip suturing with bilateral domal creation, and intradomal and domal equalization sutures. No alar base reductions or grafts of the nostril rims were required. (A) Preoperative anteroposterior (AP) view. (B) Preoperative partial head-down view. (C) Preoperative lateral view. (D) Preoperative basilar view. (E) Postoperative AP view at 12 months. (F) Postoperative partial head-down view at 12 months. (G) Postoperative lateral view at 12 months. (H) Postoperative basilar view at 12 months.



**Fig. 8** (Continued)

by the cartilaginous vault.<sup>16</sup> Following hump reduction, there is a tripartite separation consisting of right lateral wall, central septum, and left lateral wall. The *postreduction* upper dorsal lines are determined by the bony vault and their position following osteotomy. In contrast, the lower dorsal lines are often collapsed due to both resection of the wide cartilaginous vault and the narrowing effect of the osteotomies. Thus, the cartilage vault must be reconstructed following hump reduction, both for aesthetic and functional reasons.

*Spreader grafts* consist of small pieces of cartilage (20 mm in length, 2 mm in height, and variable width) that are sutured between the upper lateral cartilages and dorsal septum to recreate the ideal dorsal width and to open the internal valve. In asymmetric cases, these grafts are rarely symmetrical. Rather, they vary dramatically in number and width. Frequently, a unilateral graft is placed on the concave side. When bilateral grafts are inserted, a wide graft (2–3.5

mm) is inserted on the concave side, and a narrow graft (1–1.5 mm) is placed on the convex side. In severe asymmetries, a full length spreader graft is placed first on the concave side followed by another tapered “door stop” spreader graft caudally. In certain cases, the width at the caudal border of these combined spreader grafts measures 5 to 7 mm in width (►Fig. 6).

*Spreader flaps* comprise retained upper lateral cartilages that are turned over to create a dorsum of a desired width. They are then sutured to the dorsal septum, thereby reconstructing the cartilaginous dorsum and spreading out the internal valve angle. As described by Gruber et al, these flaps can be augmented in their distal portion with minispreader grafts.<sup>26</sup> Their role in major asymmetries can be limited as the upper lateral cartilage is either asymmetric or deficient, thereby limiting their application. It is not unusual for the authors to do a combination of spreader grafts and spreader flaps. Bilateral spreader flaps will be created, then spreader

grafts can be inserted on the concave side, and, finally, the cartilaginous dorsum sutured together.

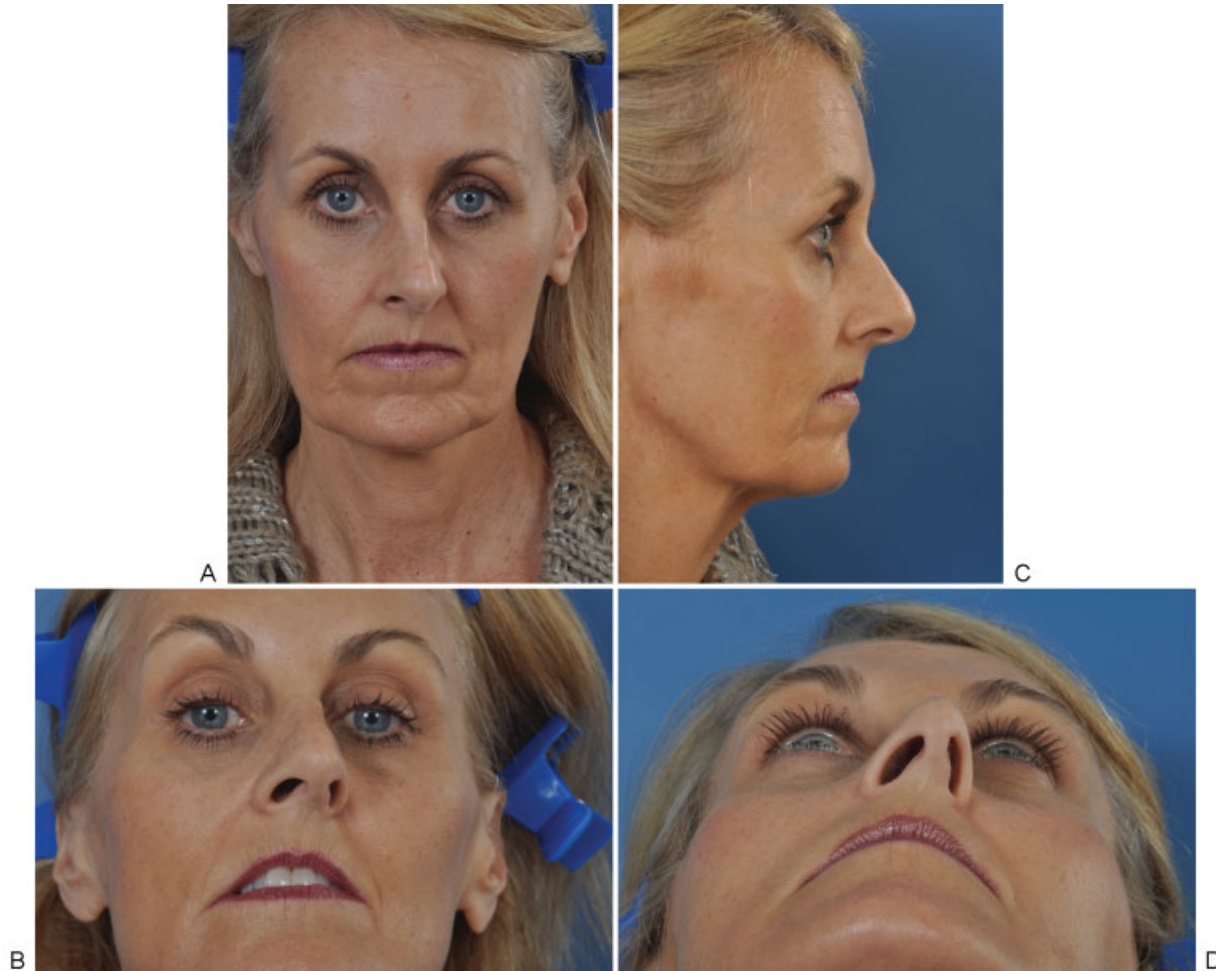### Tip

Numerous articles have been written on the asymmetric tip and its alar cartilages.<sup>7,9</sup> We will emphasize the surgical sequence followed by our approach to each of the three alar crus. Tip surgery is done only after the septal straighten-

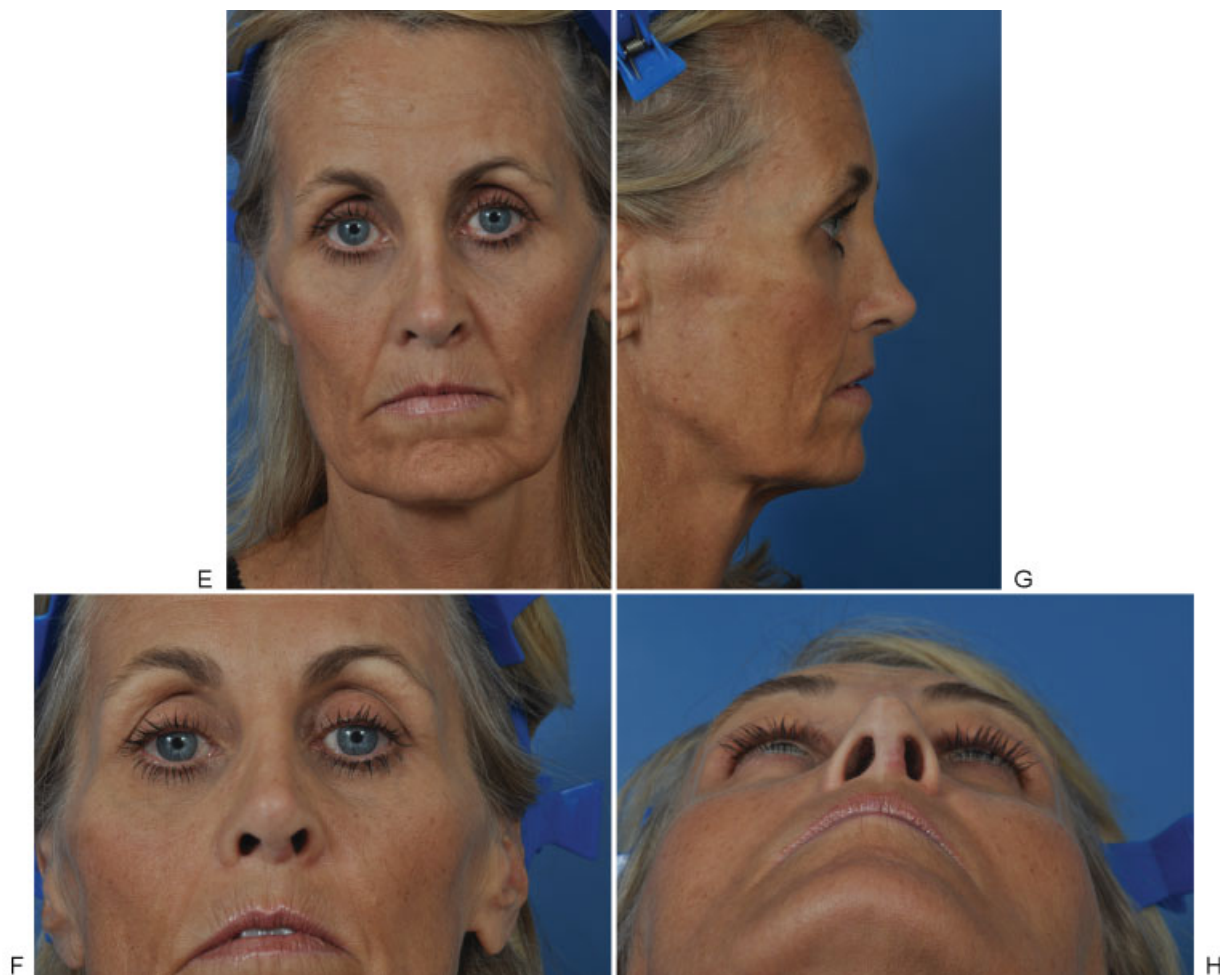ing (especially the caudal septum), osteotomies, and reconstruction of the osseocartilaginous vault are completed.

**Analysis:** In contrast to surgeons who base their analysis solely on the basilar view, we view the alar cartilages from basilar, oblique, lateral, and top down views. Each view reveals deformities of different parts of the alar cartilages.

**Medial crus:** The medial crus is defined anatomically as beginning at the crural footplates (footplate segment) and terminating at the columellar-lobular junction (columellar



**Fig. 9** A 51-year-old female with grade 3 asymmetric developmentally deviated nose (ADDN). The treatment of this patient with grade 3 ADDN involved an open approach. Following symmetric rasping of the bony cap and cartilaginous reduction with scissors (4.5 mm of dorsum and 5 mm of caudal septum), septoplasty was completed removing the posteroinferior spur. The anterior nasal spine (ANS) was severely displaced and was therefore fractured with an osteotome and moved back to the dental midline. The caudal septum was then relocated to the right side and secured via a drill hole in the ANS. The nose was then straightened from the top down, starting with the upper third. Unlike the patient in ► **Fig. 8**, the difference in lateral wall heights was contributed to by a retracted left maxilla. The osteotomy sequence began medially and moved laterally by first performing asymmetric, medial oblique osteotomies to centralize the dorsal lines. A left midlevel intermediate osteotomy was done to remove the convexity of the left nasal bone. Given the difference in lateral wall heights (right: 30 mm; left: 20 mm), the correct nasal midline was marked (using the dental midline and brows as reference points) at the osseocartilaginous junction. A right low-intermediate osteotomy measured at 20 mm was done to equalize the lateral wall heights. Then, a gingivobuccal sulcus incision was made on the right and a power saw was used to complete a low-to-low osteotomy at the base of the frontal process of the maxilla to equalize the base width. A spreader graft (2 mm wide) was placed on the right side, high in the open roof to reconstruct the middle vault and to stent out the right nasal bone. No spreader graft or flap was placed on the left. The tip was completed with a columellar strut as well as tip suturing with bilateral domal creation, and intradomal and domal equalization sutures. A turn under of cephalic trim was done on the right to minimize the weakness of the lateral crura, and two lateral crural convexity sutures were placed on the left to reduce convexity. A tip refinement graft of cephalic trim was placed as a folded shield over the domes to conceal asymmetry. A nostril sill excision of 3 mm was performed on the right as the right nostril base was wider. Two milliliters of diced cartilage was placed on the left maxilla and peri-pyriform in a subperiosteal pocket to correct retrusion. (A) Preoperative anteroposterior (AP) view. (B) Preoperative partial head-down view. (C) Preoperative lateral view. (D) Preoperative basilar view. (E) Postoperative AP view at 18 months. (F) Postoperative partial head-down view at 18 months. (G) Postoperative lateral view at 18 months. (H) Postoperative basilar view at 18 months.



**Fig. 9** (Continued)

segment).<sup>24</sup> The vast majority of visually displaced medial crura are caused by deviation of the caudal septum/ANS. True asymmetries of the medial crus are infrequent and rarely require surgical treatment. Insertion of a columellar strut adds support to the medial crura and acts a jig to support and to verticalize the nasal tip.

**Middle crus:** The middle crus is defined anatomically by Sheen as beginning at the columellar-lobular junction and terminating at the lateral crura.<sup>25</sup> It can be further subdivided into a lobular segment and a domal segment.<sup>24</sup> The domal segment extends from the medial genu, which marks the transition from the lobular segment, to the lateral genu, which marks the transition to the lateral crura. In contrast to the medial crus, the middle crus is virtually always asymmetric and must be treated surgically. On basilar view, it is wise to remember Natvig classification of the columellar segment, which was confirmed by Daniel and Lessard<sup>27</sup>: asymmetric reciprocal (75%), flared symmetric (12.5%), and straight (12.5%). Symmetry can be gained in the majority of tips using the standard tip sequence of (1) insertion of a columellar strut, (2) domal creation sutures, (3) intradomal suture, (4) domal equalization suture, and (5) tip position suture. Add-on tip grafts can be included to camouflage residual asymmetries. In severe cases, excision of the middle crura followed by an integrated tip graft can be done.<sup>24</sup> We prefer a columellar strut

for support as opposed to a septal extension graft or tongue-in-groove technique as the nasal tip is effectively separated from any ongoing asymmetries of the septum.

**Lateral crus:** The lateral crus is defined anatomically as beginning at the lateral genu and extending laterally to the accessory cartilage ring.<sup>28</sup> We have found major asymmetries of the lateral crus, which, in association with the adjacent nostril deformity, may prove to be a major limiting factor in how much improvement is possible. Analysis and surgical treatment of the lateral crura has been reviewed elsewhere. Useful techniques include lateral crus turn over or turn under flaps, lateral crural strut grafts, and alar battens. The problem is similar to a cleft nasal deformity where one tries to “match” the severely deformed lateral crus to the more normal side. Frequently, the lateral crura does not support the nostril rim, and one is required to use an alar rim structure graft rather than an alar rim support graft. Although the grafts are often of the same dimension, the difference is that an alar rim structure graft is placed in a true rim incision 2 mm back and parallel to the nostril rim. The graft is then sutured into the incision at multiple points, which controls the shape and provides support for the rim.

#### **Alar Base/Maxilla**

Asymmetry of the alar base and nostril aperture is rarely discussed. Preoperative evaluation indicates that the right

and left nostril shapes are distinctly different in virtually every patient, and it is important to show this to the patient before surgery. On anterior view, the alar base, upper lip junction, is also asymmetric as regards height and width. This junction tends to be higher and wider on the stronger side of the face while lower and narrower on the weaker side of the face (►Fig. 1C, D). In addition, one must pay close attention to the tip lobule, alar base junction, along the nostril rim as differential weaknesses are visible. Surgical correction of these asymmetries is limited and usually involves some variation of an extended nostril sill excision. As a general rule, it is best to do the same type of excision, but quantitatively different on the two sides. Alar rim grafts are often essential to overcome any nostril rim weakness. If the level of the alar bases is markedly different in anterior–posterior dimension, then a small amount of diced cartilage (0.6–10 mL) can be placed subperiosteally on the pyriform aperture through a vestibular incision.

Imbalances may be corrected using both autogenous and alloplastic materials. In our practice, both diced cartilage and hydroxyapatite are used for facial augmentation. After evaluation of facial imbalance, the decision is made regarding how much augmentation and the location of the augmentation. Through a pyriform incision or a gingivobuccal sulcus approach, a subperiosteal pocket is created for injection of augmentation material. We find diced cartilage to be the optimal material for augmentation, as it is autogenous, relatively abundant, moldable in the perioperative period, becomes form stable, and allows for tissue ingrowth. When autogenous cartilage is not available in sufficient quantity, we use hydroxyapatite as it has proven to be form stable and allows for tissue ingrowth. This technique was first reported in 1993 for successful augmentation of the facial skeleton by mixing hydroxyapatite granules with blood. No infections were reported and the authors updated their experience in 1996 with more than 200 patients treated.<sup>29,30</sup>

## Case Studies

Three case studies (►Figs. 7–9) are included. In our practice, each component of the nose (septum, tip, etc.) is given a score from 1 to 3 in terms of asymmetry and the complexity of surgical techniques required during rhinoplasty. The components are added and a composite total score allows us to grade the patients from 1 to 3 with grade 3 being the most difficult.

### Disclosure

Dr. Daniel receives royalties from Springer Publishing. Dr. Kosins is a consultant for ZO Skin Health. There are no financial disclosures, and no financial assistance was received in the preparation of this article.

## References

- Seltzer A. *Plastic Surgery of the Nose*. Philadelphia, PA: JB Lippincott; 1949
- Toriumi DM, Watson D. Innovative surgical management of the crooked nose in rhinoplasty. In: *The Dallas Rhinoplasty Symposium Text*. St. Louis, MO: Quality Medical Publishing; 2001
- Converse JM. Corrective surgery of nasal deviations. *AMA Arch Otolaryngol* 1950;52(5):671–708
- Gubisch W. The extracorporeal septum plasty: a technique to correct difficult nasal deformities. *Plast Reconstr Surg* 1995;95(4):672–682
- Guyuron B, Behmand RA. Caudal nasal deviation. *Plast Reconstr Surg* 2003;111(7):2449–2457, discussion 2458–2459
- Gubisch W, Constantinescu MA. Refinements in extracorporeal septoplasty. *Plast Reconstr Surg* 1999;104(4):1131–1139, discussion 1140–1142
- Daniel RK. The nasal tip: anatomy and aesthetics. *Plast Reconstr Surg* 1992;89(2):216–224
- Johnson CN, Toriumi DM. *Open Structure Rhinoplasty*. Philadelphia, PA: W. B. Saunders; 1990
- Kosins AM, Daniel RK, Sajjadian A, Helms J. Rhinoplasty: congenital deficiencies of the alar cartilage. *Aesthet Surg J* 2013;33(6):799–808
- Daniel RK, Ed. *Aesthetic Plastic Surgery: Rhinoplasty*. Boston, MA: Little, Brown; 1991
- Gruber RP, Nahai F, Bogdan MA, Friedman GD. Changing the convexity and concavity of nasal cartilages and cartilage grafts with horizontal mattress sutures: part II. Clinical results. *Plast Reconstr Surg* 2005;115(2):595–606, discussion 607–608
- Daniel RK. *Mastering Rhinoplasty*. New York, NY: Springer; 2011
- Vuyk HD. A review of practical guidelines for correction of the deviated, asymmetric nose. *Rhinology* 2000;38(2):72–78
- Daniel RK, Ethier R. Rhinoplasty: a CT-scan analysis. *Plast Reconstr Surg* 1987;80(2):175–184
- Fisher DM, Lo LJ, Chen YR, Noordhoff MS. Three-dimensional computed tomographic analysis of the primary nasal deformity in 3-month-old infants with complete unilateral cleft lip and palate. *Plast Reconstr Surg* 1999;103(7):1826–1834
- Cerkes N. The crooked nose: principles of treatment. *Aesthet Surg J* 2011;31(2):241–257
- Converse JM, Horowitz SL, Valauri AJ, Montandon D. The treatment of nasomaxillary hypoplasia. A new pyramidal naso-orbital maxillary osteotomy. *Plast Reconstr Surg* 1970;45(6):527–535
- Kosins AM, Daniel RK. The new approach to the nasal dorsum and selection of osteotomies. Paper presented at the Fourth Bergamo Open Rhinoplasty Course, March 14, 2014, Bergamo, Italy
- Gerbault O, Daniel RK, Kosins AM. The role of piezoelectric instrumentation in rhinoplasty. *Aesthet Surg J* 2016;36(1):21–34
- Lazovic GD, Daniel RK, Janosevic LB, Kosanovic RM, Colic MM, Kosins AM. Rhinoplasty: the nasal bones - anatomy and analysis. *Aesthet Surg J* 2015;35(3):255–263
- Ellis DAF, Shaikh AJ. The twisted nose. In: Krause M, ed. *Aesthetic Facial Surgery*. Philadelphia, PA: Lippincott; 1991:313–325
- Gruber R, Chang TN, Kahn D, Sullivan P. Broad nasal bone reduction: an algorithm for osteotomies. *Plast Reconstr Surg* 2007;119(3):1044–1053
- Parkes ML, Kamer F, Morgan WR. Double lateral osteotomy in rhinoplasty. *Arch Otolaryngol* 1977;103(6):344–348
- Gruber R. Selection of osteotomies. Paper presented at the Fourth Bergamo Open Rhinoplasty Course, March 13, 2014, Bergamo, Italy
- Sheen JH. Spreader graft: a method of reconstructing the roof of the middle nasal vault following rhinoplasty. *Plast Reconstr Surg* 1984;73(2):230–239
- Gruber RP, Park E, Newman J, Berkowitz L, Oneal R. The spreader flap in primary rhinoplasty. *Plast Reconstr Surg* 2007;119(6):1903–1910
- Daniel RK, Lessard ML. Rhinoplasty: a graded aesthetic-anatomical approach. *Ann Plast Surg* 1984;13(5):436–451
- Daniel RK, Palhazi P, Gerbault O, Kosins AM. Rhinoplasty: the lateral crura-alar ring. *Aesthet Surg J* 2014;34(4):526–537
- Rosen HM. Facial skeletal expansion: treatment strategies and rationale. *Plast Reconstr Surg* 1992;89(5):798–808
- Adams JS. Grafts and implants in nasal and chin augmentation. A rational approach to material selection. *Otolaryngol Clin North Am* 1987;20(4):913–930