

# Transcranial Approach versus Endoscopic Transsphenoidal Approach during Midline Suprasellar Meningioma Resection—A Complication and Outcome-Based Study: A Meta-Analysis

Mohan Karki<sup>1</sup> Chandra Prakash Yadav<sup>1</sup> Bing Zhao<sup>1</sup>

<sup>1</sup>Department of Neurosurgery, The Second Affiliated Hospital of Anhui Medical University, Skull Base Tumor Research Center, Anhui Medical University, Anhui Province, China

Indian J Neurosurg 2016;5:145–158.

Address for correspondence Prof. Bing Zhao, MD, Department of Neurosurgery, The Second Affiliated Hospital of Anhui Medical University, Skull Base Tumor Research Center, Anhui Medical University, 678 Fu Road, Hefei, Anhui Province 230601, China (e-mail: -zhaopumcmd@yeah.net).

## Abstract

**Background and Purpose** The choice of surgical approach for the removal of midline suprasellar meningiomas (MSM) has long remained inconclusive among neurosurgeons. While some neurosurgeons prefer transcranial approach (TCA), others favor the use of endoscopic transsphenoidal approach (ETSA). Retrospectively, we assessed the effectiveness of TCA and ETSA on the basis of postoperative outcome and complications to inform future clinical decision making on MSMs.

**Materials and Methods** A retrospective systematic review and meta-analysis was performed on published case series in PubMed from the year 2000 to 2014. Demographic data, clinical variables, and outcome measures of patients who had their MSMs surgically removed via TCA or ETSA were subjected to rigorous statistical analysis.

**Results** There were 48 studies with 1,466 patients who underwent TCA (32 studies) and ETSA (16 studies). TCA had a statistically significant rate of tumor recurrence ( $p = 0.02$ ; odds ratio [OR], 1.8; 95% confidence interval [CI], 1.1–6.39) while ETSA had a high rate of CSF leakage ( $p = 0.04$ ; OR, 25; 95% CI, 1.78–11.56). Both TCA and ETSA did not improve visual recovery and gross total resection, but only minimally influenced total clinical outcome.

**Conclusion** Put together, ETSA and TCA did not improve CSF leakage rate and tumor recurrence respectively, but in the absence of a surgical approach that could maximize the advantages of both TCA and ETSA, it is advisable that neurosurgeons take an informed clinical decision reflective of patient peculiar clinical presentations as well as risk/benefit profile of surgical technique.

## Keywords

- ▶ midline suprasellar meningiomas
- ▶ transcranial and endoscopic transsphenoidal approach
- ▶ outcomes and meta-analysis

## Introduction

Approximately, 5 to 10% of all intracranial meningiomas are midline suprasellar meningiomas (MSMs)<sup>1</sup> that normally originate from tuberculum sellae (TS), diaphragm sellae (DS),

and planum sphenoidale (PS).<sup>2–9</sup> MSMs are benign, slow growing, encapsulated, and normally attached to a part of the dura, falx, or tentorium.<sup>2,10</sup> MSMs exhibit complex symptoms such as adhering to vascular walls or completely engulfing them, however, they typically do not invade blood

received  
April 21, 2016  
accepted  
June 1, 2016  
published online  
October 25, 2016

DOI <http://dx.doi.org/10.1055/s-0036-1588035>.  
ISSN 2277-954X.

© 2016 Neurological Surgeons' Society of India

License terms



vessels. In view of the delicate anatomic location and proximity of MSMs to neurovascular structures (internal carotid artery and its branches, mainly anterior cerebral artery and anterior communicating artery, optic apparatus) and the pituitary gland,<sup>11</sup> they represent a major problem for surgical removal by neurosurgeons. In most cases, visual disturbances secondary to displaced optic apparatus is the main clinical presentation.<sup>12-16</sup> A successful surgical removal of MSM is normally characterized by removal of the tumor along with surrounding dura and associated hyperostotic bone while preserving vision. Postoperation visual recovery or preservation of vision is the gold standard for assessing surgical approaches for MSMs.<sup>7,13,17,18</sup>

Two most commonly used surgical approaches for MSM are the traditional transcranial approach (TCA) or microscopic/modern endoscopic transsphenoidal approach (ETSA). Neurosurgeons are divided when it comes to the choice of surgical approach for the removal of MSMs. Although some studies have investigated the choice of TCA and TSA for surgical removal of suprasellar meningiomas on the basis of some postoperative outcome measures including visual improvement, cerebrospinal fluid (CSF) leakage, tumor recurrence, and gross total resection (GTR),<sup>19-21</sup> yet the choice problem remains unsolved. This problem has been attributed to many factors including limited studies on the topic, methodological heterogeneity, and small patient numbers as well as biased reporting. For example, case series on meningiomas removed by ETSA series were shown to be small lesions,<sup>22</sup> this gives biased impression of ETSA compared with TCA.

To contribute, the present systematic review retrospectively analyzed published case series on MSMs independently removed by TCA or ETSA. Importantly, this review subjected the data captured in these published studies to rigorous meta-analysis as a means to provide rationale for the choice of surgical techniques for MSM management.

## Methods

### Search Methodology

We searched for data on case series published in PubMed from the year 2000 to 2014. Regarding study design, 32 articles were under transcranial group<sup>5-9,11,13-16,18-21,23-40</sup> and 16 articles were under endoscopic group.<sup>19-22,41-52</sup> The following search terms: meningioma, tuberculum sellae, diaphragm sellae, planum sphenoidale, transcranial, resection, and outcomes were used either singly or in combination. The following approaches: frontotemporal/pterional, unilateral subfrontal, bilateral subfrontal, supraorbital, and interhemispheric were collectively designated as TCA. For the purpose of comparison, similar searches were performed using the terms; endoscopy, endonasal, transsphenoidal, midline suprasellar, tuberculum sellae, diaphragm sellae, and planum sphenoidale meningiomas. Likewise, only endoscope-assisted or microscope- and endoscopic-assisted approaches were collectively designated as ETSA. Data reported in aggregated form were included to report overall pooled rates. The assessment of efficacy of the procedures was based on

surgical outcomes: visual improvement, GTR, and perioperative complications. There was disparity on visual functioning among the case series, mostly between formal visual field testing and subjective patient assessment method; however, both were used as a means to assess visual field in this study. Also, strength of evidence score (SOES) was designed based on a criteria (►Table 1).

### Inclusion and Exclusion Criteria

Only patients with tumor specifically located in the TS, DS, or PS were included in this study. The studies were reviewed and observations were made regarding study design, methodology, and patient characteristics (►Table 2). The cases for each study were extracted and the cohorts assessed based on preoperative clinical features (visual deficits, headache, and endocrinopathy) and postoperative outcomes (visual function, GTR, occurrence of CSF leakage, and tumor recurrence). Similarly, morbidity assessment was based on frequency of infection (pneumonia, meningitis, and wound/bone flap infection), seizure, hemorrhage, visual worsening, endocrinopathy, and anosmia. Information on mortality, if available, was captured. Age was categorized into  $\leq 50$  or  $> 50$  years. Tumor size was categorized into  $\leq 2.4$  or  $> 2.4$  cm. Also, duration of symptoms was categorized into  $\leq 12$  or  $> 12$  months. The  $p$ -values  $\leq 0.05$  were considered statistically significant in all analysis. Duplication of patients was eliminated in case series where multiple papers were published by the same authors or the same institution. In such situations, only reports with the largest sample size and relevant data were selected.

**Table 1** Strength of evidence scoring (SOES) system demonstrating the assignment of scores based on visual assessment, demographic variables (sex, mean age, size, and volume of tumor, and volume of tumor resection) in patients that were operated for MSM

Included variable	SOES
10 or more patients Postoperative vision assessment Nonvisual complication Reported age, sex, size, or volume or extent of resection	1
10 or more patients Postoperative vision assessment OR Nonvisual complication Reported age, sex, size, or volume or extent of resection	2
10 or more patients Postoperative vision assessment OR Nonvisual complication OR 2 of 3 (reported age sex, size, or volume or extent of resection)	3
Either 10 or more patients OR Postoperative vision assessment OR Nonvisual complication OR 1 of 3 (reported age, sex, size, or volume or extent of resection)	4

Abbreviation: MSM, midline suprasellar meningioma; OR, odds ratio.

**Table 2** Extracted articles with their demographic variables

Author/year	Study location	Surgery	Year of surgery	Total no. of cases	Mean age in years (range)	No. of females (%)	Mean tumor diameter in cm (range)	Mean tumor volume in cm <sup>3</sup> (range)	SOES
Arai et al (2000) <sup>26</sup>	Tokyo, Japan	TCA	NA	21	49	9 (43%)	NA	NA	1
Ciric and Rosenblatt (2001) <sup>6</sup>	NA	TCA	NA	24	40	18 (75%)	NA	NA	2
Ohta et al (2001) <sup>32</sup>	Kobe city, Japan	TCA	1980–2000	33	46.7 (15–69)	29 (88%)	NA	NA	2
Zevgaridis et al (2001) <sup>16</sup>	Munich, Germany	TCA	1990–1996	34	54.9 (38–80)	27 (79%)	2.8 (1.5–6)	NA	2
Fahlbusch and Scott (2002) <sup>13</sup>	Erlangen, Germany	TCA	1983–1998	47	54.9 (28–74)	39 (83%)	NA	NA	2
Goel et al (2002) <sup>7</sup>	Bombay, India	TCA	1991–2001	70	NA	42 (60%)	NA	NA	3
Jallo and Benjamin (2002) <sup>14</sup>	New York, USA	TCA	1983–2001	23	57.7 (4–73)	15 (65%)	3.3 (2–5)	23.4 (8–60)	1
Chi and McDermott (2003) <sup>5</sup>	California, USA	TCA	1992–2002	21	52.3	7 (33%)	NA	NA	2
Schick and Hassler (2005) <sup>15</sup>	Duisburg, Germany	TCA	1991–2002	53	53 (27–78)	13 (25%)	1–5	NA	1
Pamir et al (2005) <sup>29</sup>	Istanbul, Turkey	TCA	1987–2004	42	24–79	28 (67%)	NA	7.5–21	1
Mathiesen (2005) <sup>33</sup>	Stockholm, Sweden	TCA	NA	29	58.3	23 (79%)	2.3	NA	1
Park et al (2006) <sup>18</sup>	Seoul, Korea	TCA	NA	30	45	24 (80%)	2.6 (1.6–6.3)	12.4 (2.3–125.6)	2
Bassiouni et al (2006) <sup>23</sup>	Essen, Germany	TCA	1990–2003	62	53 (29–81)	46 (73%)	3.4 (2–6)	NA	1
Nakamura et al (2006) <sup>25</sup>	Hanover, Germany	TCA	1978–2002	72	54.3 (30–86)	54 (75%)	2.8	NA	1
Otani et al (2006) <sup>36</sup>	Zurich, Switzerland	TCA	NA	32	53.5	21 (66%)	2.3	NA	2
Kitano et al (2007) <sup>21</sup>	Osaka, Japan	TCA	1994–2006	12	61.4	10 (83%)	NA	NA	3
Li X et al (2007) <sup>35</sup>	Jinan, China	TCA	1989–2003	43	53.8 (24–68)	31 (72%)	1.8–5.4	NA	1
De Divitiis et al (2008) <sup>19</sup>	Naples, Italy	TCA	1983–2006	44	NA	NA	NA	NA	4
Kim et al (2008) <sup>27</sup>	Gwangju, Korea	TCA	1998–2006	27	53.8 (36–73)	22 (80%)	3	NA	2
Mehrazin and Mirfalah. (2008) <sup>38</sup>	Tehran, Iran	TCA	1997–2006	45	45.7 (22–75)	35 (78%)	2.6 (1.4–5.2)	NA	1
Nozaki et al (2008) <sup>31</sup>	Kyoto, Japan	TCA	1999–2007	22	52.9 (27–73)	18 (81%)	2.3 (1.5–3.5)	NA	2
Fatemi et al (2009) <sup>20</sup>	California, USA	TCA	2000–2008	9	49 (37–57)	6 (73%)	3.3 (2.2–5.5)	NA	4
Ganna et al (2009) <sup>8</sup>	Toronto, Canada	TCA	2000–2007	24	53.8	20 (83%)	2.6	NA	1
Sade and Lee (2009) <sup>30</sup>	Ohio, USA	TCA	1994–2006	31	NA	NA	2.3 (1.1–3.8)	NA	3
Galal et al (2010) <sup>9</sup>	Cairo, Egypt	TCA	2000–2006	21	43 (27–65)	14 (67%)	NA	NA	1
Landeiro et al (2010) <sup>28</sup>	Rio de Janeiro RJ, Brazil	TCA	1997–2008	23	56.2 (38–77)	15 (65%)	NA	NA	1
Palani et al (2012) <sup>34</sup>	Hyderabad, India	TCA	2004–2011	41	NA	26 (63%)	NA	NA	4
Jang et al (2012) <sup>37</sup>	Gwangju, Korea	TCA	2005–2011	24	49.5 (25–70)	19 (79%)	2 (0.7–3.3)	NA	1
Nanda et al (2013) <sup>11</sup>	Louisiana, USA	TCA	1990–2013	30	NA	NA	NA	NA	4

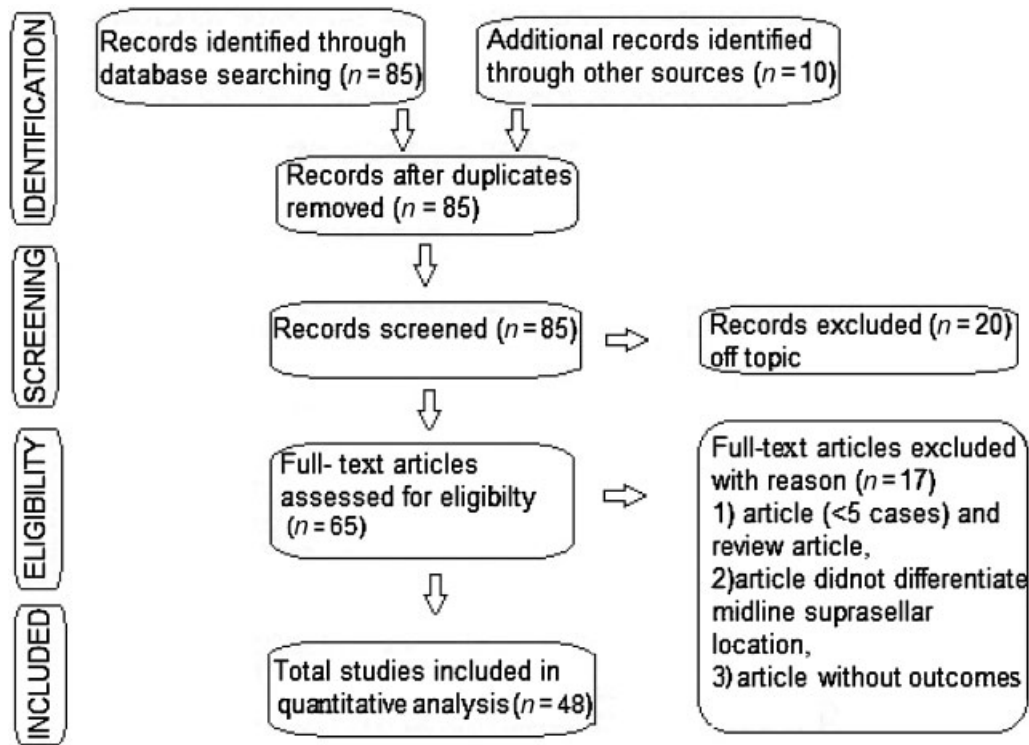
(Continued)

Table 2 (Continued)

Author/year	Study location	Surgery	Year of surgery	Total no. of cases	Mean age in years (range)	No. of females (%)	Mean tumor diameter in cm (range)	Mean tumor volume in cm <sup>3</sup> (range)	SOES
Lu Z et al (2012) <sup>40</sup>	Henan, China	TCA	2005–2009	29	47 (25–69)	19 (66%)	NA	NA	3
Soel HJ et al (2013) <sup>39</sup>	Seoul, Korea	TCA	1994–2001	86	49 (24–75)	66 (76%)	2.4 (1–5.9)	7.3 (1.1–64.1)	1
Yi et al (2014) <sup>24</sup>	Guangzhou, China	TCA	2000–2008	106	48.5 (20–78)	74 (70%)	2.9 (0.8–4.9)	NA	1
Couldwell et al (2004) <sup>52</sup>	Salt Lake city, Utah	ETSA <sup>a</sup>	1982–2003	11	NA	NA	NA	NA	4
Kitano et al (2007) <sup>21</sup>	Osaka, Japan	ETSA	1994–2006	16	53.8	14 (87%)	NA	NA	3
Laufer et al (2007) <sup>47</sup>	New York, USA	ETSA	NA	5	55.6 (4–73)	NA	2.6 (1.2–3.7)	NA	4
De Divitiis et al (2008) <sup>19</sup>	Naples, Italy	ETSA	2000–2007	7	58.7 (47–80)	4 (57%)	2.5 (1.3–3.2)	15.3 (3.2–24.1)	4
Gardner et al (2008) <sup>48</sup>	Pennsylvania, USA	ETSA	2002–2005	13	52.2 (39–72)	12 (92%)	NA	7.5 (2.1–16.2)	2
Fatemi et al (2009) <sup>20</sup>	California, USA	ETSA <sup>a</sup>	2000–2008	14	51 (31–77)	10 (71%)	2.5 (1.5–5.5)	NA	2
Wang et al (2010) <sup>51</sup>	Wuxi, China	ETSA	2002–2007	12	56.7 (26–67)	8 (67%)	3.1 (2.5–4)	15.4 (8.1–26)	1
Van Gompel et al (2011) <sup>22</sup>	Bologna, Italy	ETSA	2003–2010	8	31–37	NA	NA	NA	4
Ceylan et al (2011) <sup>41</sup>	Kocaeli, Turkey	ETSA	2007–2010	9	52 (32–78)	7 (78%)	2.8 (1.6–4.5)	NA	4
Ogawa and Tominaga (2012) <sup>45</sup>	Sendai, Japan	ETSA	2006–2011	19	58.9 (43–79)	14 (74%)	2 (0.9–2.9)	NA	1
Choudhury et al (2012) <sup>42</sup>	Dhaka, Bangladesh	ETSA	NA	6	39.5 (29–52)	4 (67%)	3.5 (2–4)	NA	4
Bohman et al (2012) <sup>50</sup>	Philadelphia, USA	ETSA	NA	5	53.2 (25–77)	3 (60%)	1.4–3	NA	4
Attia et al (2012) <sup>49</sup>	NA	ETSA	NA	6	56.5 (31–74)	6 (100%)	1–4	NA	4
Gadgil et al (2013) <sup>43</sup>	Texas, USA	ETSA	2009–2011	5	51 (31–66)	3 (60%)	2 (0.9–2.5)	6.3 (2.3–11.9)	4
Khan et al (2014) <sup>46</sup>	Toronto, Canada	ETSA	2006–2013	17	63.8 (37–86)	13 (76%)	2.3 91–3.3)	10.1 (0.72–29)	1
Koutourousiou et al (2014) <sup>44</sup>	Pennsylvania, USA	ETSA	2002–2011	75	57.3 (36–88)	NA	0.5–5.2	NA	1

Abbreviations: ETSA, endoscopic transsphenoidal approach; SOES, strength of evidence score; TCA, transcranial approach.

<sup>a</sup>Endoscopic assisted microscopic transsphenoidal approach.



**Fig. 1** Flow diagram showing systemic analysis process (PRISMA flow diagram).

### Overcoming Bias

Only disaggregated data were included for analysis of predictive factors. An assessment of bias was made only on the outcome measures but not on individual studies because only case series and case reports were included in this study. Publication bias was assessed by using funnel plots on natural logarithmic scale followed by Egger's linear regression. The study design is presented in a flow diagram (► **Fig. 1**).

### Statistical Analysis

Statistical analysis was done by using SPSS software (version 17.0; Chicago, Illinois, United States) and Stata (version 11.0; college station, Texas, United States). Meta-analysis on calculated pooled proportion of individual outcomes for TCA and ETSA groups was independently performed. The disaggregated individual patient data from studies were summarized for the purpose of statistical analysis. Results were designated as proportions (%) and 95% confidence intervals (CI) were resolved using the exact binomial method. Heterogeneity was estimated using Cochran Q statistic, and random effect models were used to correlate the heterogeneity between proportions as previously described<sup>53-56</sup>. Each individual study was weighted by using the inverse variance method at 95% CIs and each pooled effect size proportion was estimated by using inverse Zr transformation of the proportion generated from random effects model.<sup>53-56</sup> Between the groups, hypothesis testing was performed on calculated 95% CIs of the pooled proportions. Odds ratio (OR) was calculated by dividing the pooled TCA proportion by the pooled ETSA proportion for the specific outcome of interest.

## Results

### Preoperative Assessments

Out of a total of 1,466 patients who were admitted for MSM surgery involving TCA and ETSA, females were in the majority for both approaches (► **Table 3**). There was a significant difference between the two approaches with regard to mean patient age, visual impairment, mean length of follow-up, and headache, but not tumor size and volume (► **Table 3**).

### Postoperative Assessment of Outcome Measures

For both approaches, worsening of visual impairment, visual improvement, and GTR numerically differed; however, the differences were statistically insignificant except in the case of CSF leakage (► **Table 4**, ► **Fig. 2, 3 and 4**). Comparing various overall perioperative complications with respect to the two approaches, it was found that both procedures had association with some complications (seizure, CSF leakage, hemorrhage, and mortality), while there was no association for others (visual worse, infections, endocrinopathy, and anosmia) (► **Fig. 6**). TCA was associated with decreased CSF leakage but increased recurrence rate, while ETSA showed decreased recurrence rate but increased CSF leakage, and the differences between the two approaches were statistically significant (► **Table 4**).

### Publication Bias for Pooled Proportion

Finally, we investigated publication bias of case series for significant and nonsignificant pooled proportions with Begg's funnel plot, and it showed similar asymmetry. Only

**Table 3** Comparison of clinical characteristics of patients who underwent TCA and ETSA for resection of midline suprasellar meningiomas, from studies in which patient data were reported in disaggregated form

Preoperative variables	No. of studies	TCA	No. of studies	ETSA	p-Value
Age (y)					
<50 y (%)	11	428(44)	1	6(3)	0.001
>50 y (%)	15	524(55)	13	203(97)	
Sex					
Male (%)	29	336(30)	12	39(28)	0.776
Female (%)	29	782(70)	12	98(71)	
Presenting symptoms					
Headache (%)	12	244(42)	10	30(20)	0.001
Endocrine abnormalities (%)	7	34(13)	4	10(9)	0.362
Preoperative visual deficits (%)	31	1,075(91)	15	175(81)	0.001
Tumor characteristics					
Mean tumor diameter, cm (range)	18	3(0.8–63)	12	2.5(0.5–5.9)	0.135
Mean tumor volume, cm <sup>3</sup> (range)	4	14.3(1.1–125.6)	5	11(0.7–29)	0.072
Optic canal involvement (%)	9	149(36)	1	20(26)	0.114
Major vascular encasement (%)	8	135(40)	4	59(47)	0.218
Mean follow-up (mo, range)	27	53(3–192)	12	19(1–98)	0.002
Mean tumor volume, cm <sup>3</sup> (range)	4	14.3(1.1–125.6)	5	11(0.7–29)	0.072

Abbreviations: ETSA, endoscopic transsphenoidal approach; TCA, transcranial approach.

Funnel plot with respect to CSF leakage is shown (→ Fig. 5) and it was a nonsignificant plot ( $p > 0.05$ ). From Egger's test performed on the publications used in this study, there was no bias with specific respect to visual improvement, GTR, and CSF leakage (→ Table 5).

## Discussion

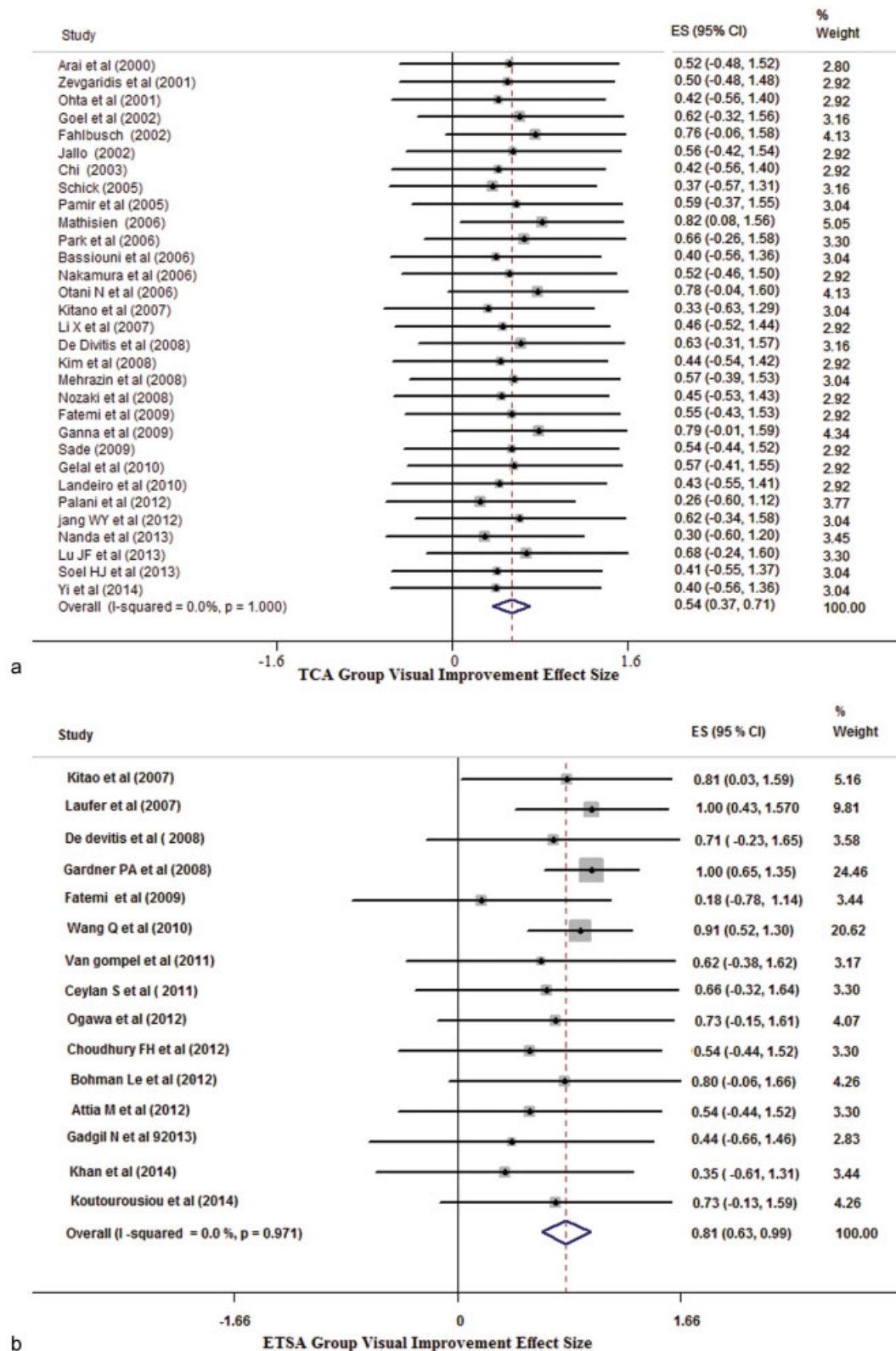
### Background

Complete removal of MSM via the TCA, first described by Stirling and Edin in 1897,<sup>57</sup> was performed by Cushing and Eisenhardt in

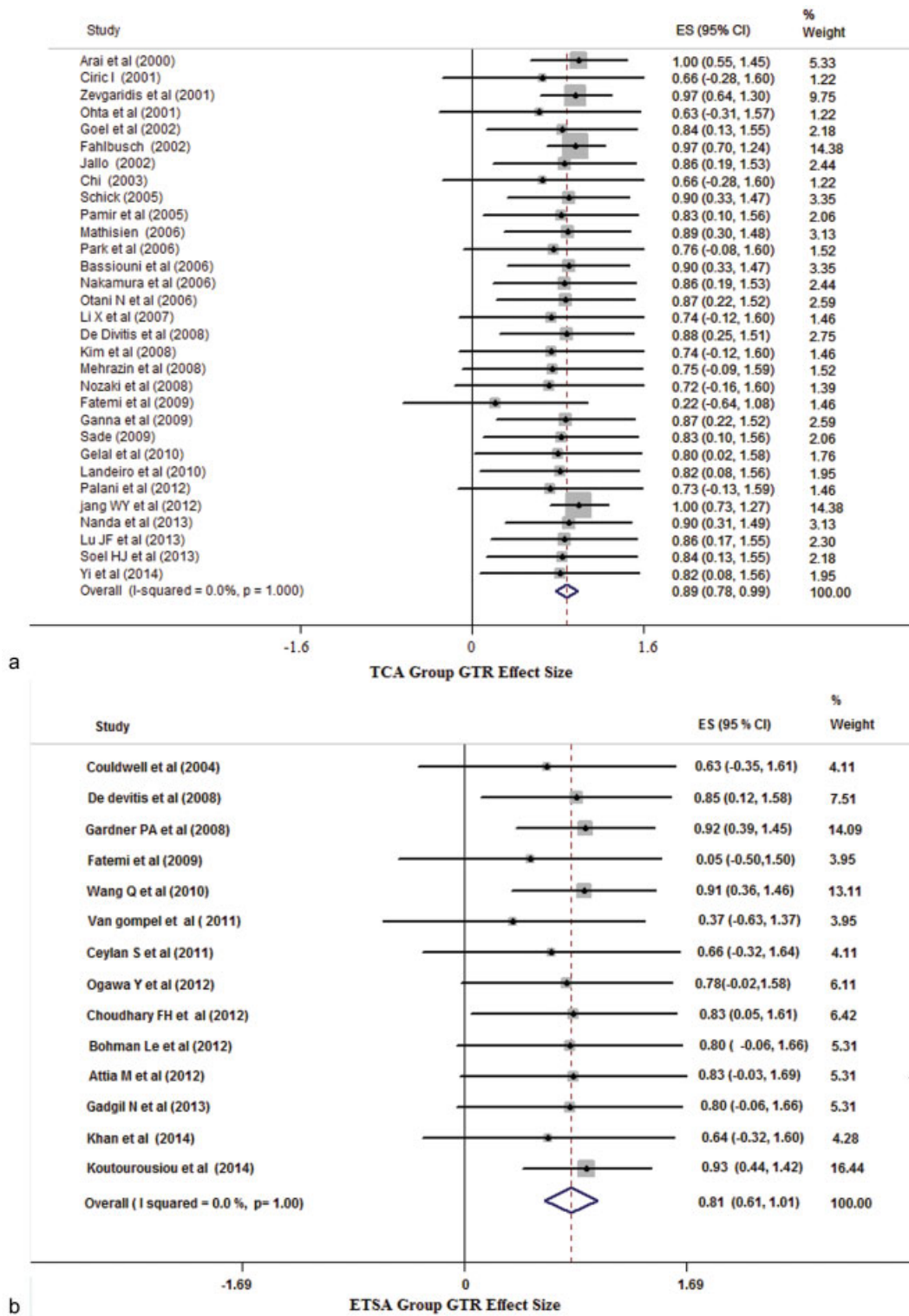
**Table 4** Comparison of surgical outcomes after resection of midline suprasellar meningioma (MSM) between TCA and ETSA groups

Variables	Proportion	OR; 95% CI	p-value
GTR			
TCA	0.80	1.3; 0.74–7.68	0.43
ETSA	0.83		
Visual improved			
TCA	0.71	1.2; 0.25–8.92	0.26
ETSA	0.70		
CSF leak			
TCA	0.08	2.5; 1.78–11.56	0.04
ETSA	0.17		
Visual worse			
TCA	0.18	1.6; 0.43–6.11	0.12
ETSA	0.15		
Tumor recurrence			
TCA	0.07	1.8; 1.1–6.39	0.02
ETSA	0.05		

Abbreviations: CI, confidence interval; CSF, cerebrospinal fluid; ETSA, endoscopic transsphenoidal approach; GTR, gross total resection; OR, odds ratio; TCA, transcranial approach.



**Fig. 2** It demonstrates comparison between transcranial and endoscopic transsphenoidal approach with respect to postoperative visual improvement. Forest plot demonstrates the 95% confidence intervals and percentiles weights associated with the individual and combined study groups for (a) transcranial approach group and (b) endoscopic transsphenoidal approach group.

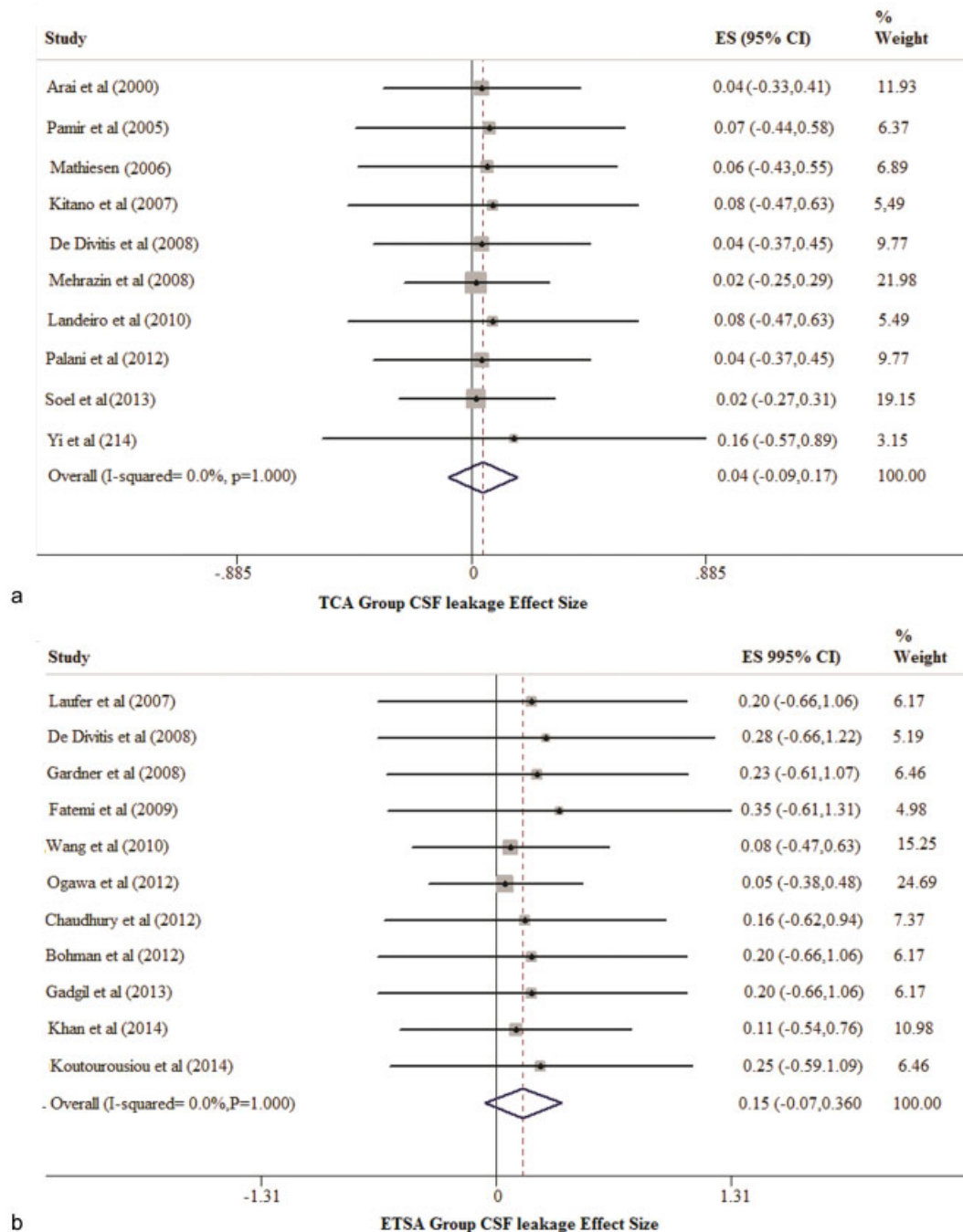


**Fig. 3** It demonstrates comparison between transcranial and endoscopic transsphenoidal approach with respect to gross total resection. Forest plot demonstrates the 95% confidence intervals and percentiles weights associated with the individual and combined study groups for (a) transcranial approach group and (b) endoscopic transsphenoidal approach group.

1916.<sup>58</sup> Since then, MSMs have been removed by different transcranial approaches that include: frontolateral, frontotemporal/pterional, orbitopterional/orbitozygomatic, unilateral subfrontal, bilateral subfrontal, interhemispheric, supraorbital, and pterional.<sup>7,13,14,25,30-33,59,60</sup> With time, the

complications, risks, and associated morbidities with TCA gave rise to TSA that was devoid of the previous risks. TSA was introduced by Herman Schloffer, who in 1907 resected a pituitary tumor via TSA.<sup>61</sup> TSA was found to be effective and safer for suprasellar meningiomas that were predominantly

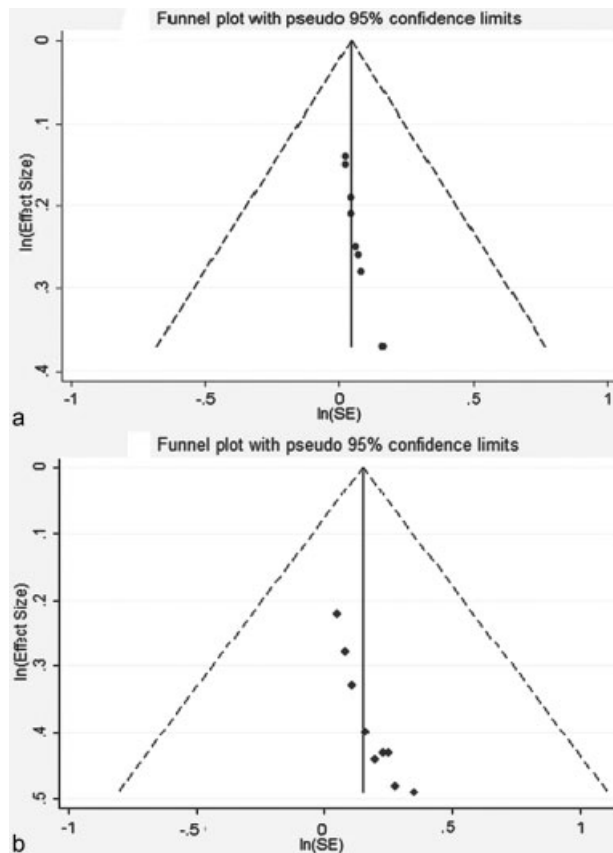




**Fig. 4** It demonstrates comparison between transcranial and endoscopic transsphenoidal approach with respect to cerebrospinal fluid leakage. Forest plot demonstrates the 95% confidence intervals and percentiles weights associated with the individual and combined study groups for (a) transcranial approach group and (b) endoscopic transsphenoidal approach group.

located in the midline<sup>17,47,62-66</sup> though its study-based advantages and disadvantages need affirmation.<sup>13,25,52,67</sup> Even though TSA has refined with evolution of microscope-based<sup>52,68</sup> or currently by endoscope-based techniques,<sup>21,47,69-71</sup> there still remains the most common problem of CSF leakage. Similarly, to limit this CSF leakage during ETSA, varieties of closure methods like: fat and fascial graft,<sup>72</sup> fat and synthetic dural substitute,<sup>51</sup> mixture (fascial graft, methacrylate, mucoperichondrium, and fibrin glue),<sup>73</sup> mixed (fascia lata and Nissel or DuraSeal),<sup>47</sup> or mixed (fascial graft and nasoseptal flap)<sup>46</sup> for dural reconstruction have been proposed. Among these closure

methods, a study done by de Divitis<sup>19</sup> has reported a higher (29%) rate of CSF leakage that specifically utilized a multilayer closure involving collagen matrix, dural substitute, a reabsorbable plate, and fibrin sealant. Various reconstruction techniques during the TCA have been suggested to prevent postoperative CSF leakage that occur mainly in the frontal sinus<sup>74</sup> and resultant meningitis, including the use of pericranial flap with or without adipose tissue being the most popular one.<sup>6,75</sup> Progressively, however, with the evolution of vascularized nasoseptal flap reconstruction technique, the CSF leakage rate has dramatically decreased to 16% with a *p*-value



**Fig. 5** Begg's funnel plot for publication bias in cerebrospinal fluid leak for both (a) transcranial approach and (b) endoscopic transsphenoidal approach. Points indicate the effect size (pointed as a proportion) included in meta-analysis plotted against the calculated standard error on a natural logarithm scale, dashed line represents 95% confidence interval,

approaching  $<0.0001$ .<sup>76,77</sup> Whatever the modification be made with procedures, reconstruction performed with a dural or institution of a newer vascularized nasoseptal sealing technique, higher rate of CSF leakage still persists with ETSA.

### Evolution of Microscopic and Endoscopic Transsphenoidal Approach

ETSA is an endoscopic-guided MSM removal procedure that delivers good illumination, wide panoramic view of the surgical target especially between the PS and clival recess.

Some of the studies performed on ETSA have reported complete resection of tumor in 88% patients, with visual improvement in 87% and visual worsening in 6%.<sup>78</sup> While Couldwell et al.<sup>52</sup> have reported complete resection in 64% patients with tuberculoma sellae meningioma and visual worsening in 9% with microscope-based TSA. Similar results have also been documented by Fatemi et al with complete resection in 50% patients, near total resection in 21% patients, with visual improvement in 82% and visual worsening in 7%.<sup>20</sup> However, access through a small aperture of nasal speculum in the microscope-based TSA approach alone had drawbacks by the limited exposure of operative corridor, field of view of surgical target, and surgical freedom of instrument maneuverability. Moreover, studies performed by Kaptain et al, Dusick et al, Cook et al, and Couldwell et al comparing the superiority among these procedures, have revealed that rather than individual microscope-based TSA or ETSA, combination of both procedures were found to be the superior approach due to the wide degree of visual freedom it provided during exploration and removal of the tumor.<sup>17,52,62,63</sup>

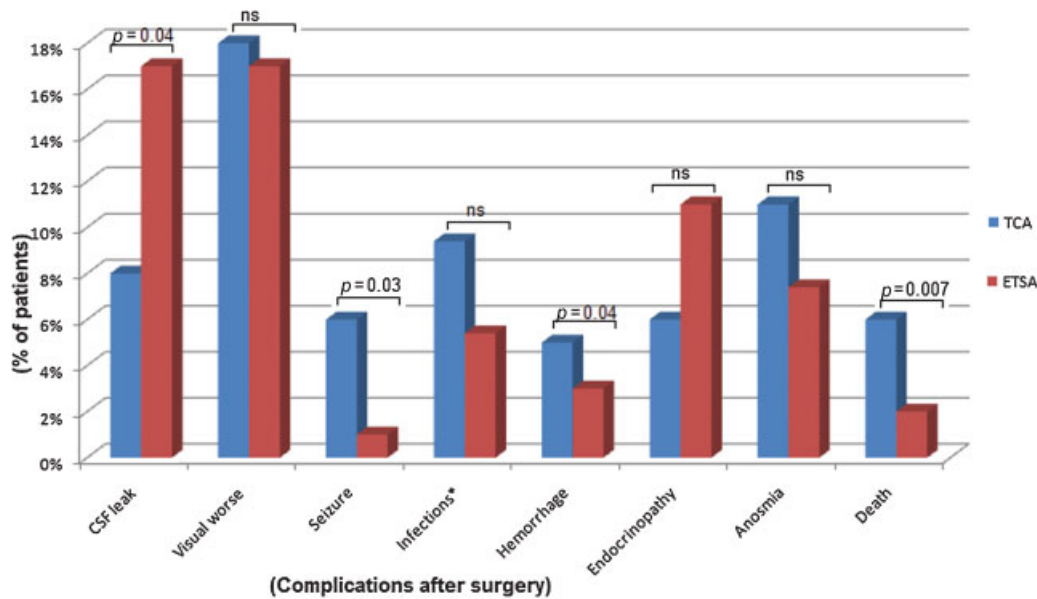
### Procedures Related Advantages and Disadvantages of Transcranial Approach and Endoscopic Transsphenoidal Approach

Both of the procedures have their own advantages over each other but the specific choices in treatment of MSM have been on an ad hoc basis. The important advantages of the TCA have been: surgeon's familiarity with traditional approach, direct microscopic visualization of the tumor, early identification of adjacent neurovascular structure, early decompression of the optic nerve via anterior clinoidectomy, increased range of instrument maneuverability (surgical freedom), better control of vascular structures, and ability to address tumor that extends superiorly or laterally on the optic nerve.<sup>72</sup> TCA, however, has some disadvantages like: easily visible scar, longer recovery time, risk of injury to brain tissue caused by frontal lobe retraction, difficulty in removing tumors located medial to ipsilateral carotid artery/optic nerve,<sup>19,72</sup> and the incidences of increased blood losses. Similarly, ETSA has been superior at early devascularization of the main feeding arteries,<sup>19</sup> early decompression of the medial side of optic nerve by unroofing the optic canal,<sup>21</sup> visualizing the lower plane of the optic chiasma,<sup>9,51,52,72</sup> and providing better

**Table 5** Summary of results of publication bias

Approaches	Variables	Publication bias ( <i>p</i> -value)		Number of studies
		Begg's	Egger's	
TCA	Visual improvement	0.07	0.12	31
	Gross total resection	0.23	0.27	31
	CSF leak	0.36	0.41	10
ETSA	Visual improvement	0.22	0.18	15
	Gross total resection	<i>p</i> = 0.59	<i>p</i> = 0.45	14
	CSF leak	<i>p</i> = 0.09	<i>p</i> = 0.11	12

Abbreviations: CSF, cerebrospinal fluid; ETSA, endoscopic transsphenoidal approach; TCA, transcranial approach.



**Fig. 6** Perioperative complications following transcranial and endoscopic transsphenoidal approach for midline suprasellar meningioma resection.

cosmetic results.<sup>51</sup> This approach also shortens the recovery time, lessens injury to brain parenchyma (no brain retraction),<sup>19</sup> provides clear vision between the internal carotid artery (ICA) to ICA and easy removal of sellar extension tumors. Moreover, it has also been the choice of surgery in elderly patients or patients with major comorbidities that cannot stand surgery.<sup>21,52</sup> However, ETSA has been limited in number of cases due to increased risk of CSF leakage/CSF fistulae<sup>19,52</sup> and inadequate removal due to the nature of tumor (hard/calcified/large/above optic nerve/more laterally located).<sup>19</sup>

### Surgical Outcomes

The reports of the present study relate favorably with those of other studies.<sup>19,20,78,79</sup> For example, Komotar et al observed significantly higher rate of GTR in endoscopic group compared with transcranial group (92.8 vs 63.2%;  $p < 0.001$ ).<sup>79</sup> Removal of the tumor as much as possible is the ultimate goal of resection in neurosurgery. Nonetheless, several studies have highlighted the fact that complete resection at the cost of visual deterioration or hypothalamic dysfunction should not be attempted. With the advent of modern microsurgery, the amount of GTR rate has leaped from 35 to 76% (macro-surgical era) to 58 to 100% (of the microsurgical era).<sup>25</sup> Resection of MSM is a complex procedure and depends on various factors like size of meningioma, arterial encasement, peritumoral edema, and approaches followed.<sup>34</sup> Whatever the influential factor may be, the extent of resection is paramount in predicting subsequent recurrence. Studies conducted earlier have reported the yield of GTR during TCA to be 70 to 100% while that with ETSA to be between 50 to 84%.<sup>20,63</sup> Contrarily, studies conducted by de Divitiis et al<sup>19</sup> have revealed 83.3% GTR during TCA while 86.4% GTR yield during ETSA. Our findings too followed the latter pattern with 80% GTR during TCA and 83% GTR during ETSA, with no statistical association ( $p = 0.43$ ).

One of the undesired results of MSM surgery is tumor recurrence which is influenced by varieties of factors. As outlined by Fahlbusch and Schott,<sup>13</sup> these factors can be: 1) extent of tumor resection, 2) histological grading of the tumor, 3) length of follow-up period, and 4) mode and quality of assessment of tumor recurrence. TSA approach being less invasive with a shorter hospital stay, the compliance to long-term follow-up becomes questionable. Most of the previously conducted ETSA studies have had 6 to 24 months of follow-ups (mean,  $21 \pm 18$  months)<sup>51</sup> while the mean follow-up duration for TCA was 51.8 months (0.8–112 months).<sup>79</sup> Recurrence rate for MSM ranges from 5% to > 30% and the rate increases with longer follow-ups.<sup>1-3,10,12,80</sup> Our observations, as shown in ►Table 3, too shared the same fact as seen by lack of 100% follow-up rates with both the procedures, (TCA, 73.3% vs ETSA, 79%). Moreover, the length of mean follow-up period for TCA was longer as compared with ETSA (53 vs 19 months) and the  $p$ -value approaching 0.002. As a result, the recurrence rate with TCA was higher as compared with ETSA (7 vs 5%;  $p = 0.02$ ). Meningiomas, although histologically benign, can recur and progress over time, so longer follow-up is necessary to evaluate the long-term outcome.

As mentioned earlier, good visual outcome is the target of a successful MSM surgery. In relation to the surgical approach undertaken, recent meta-analysis have demonstrated more visual improvements with ETSA (75%) as compared with TCA (58.4%), although the observations did not have statistical significance.<sup>19</sup> Our studies also demonstrated almost similar rate of visual improvement with no statistically significant difference (TCA vs ETSA, 71 vs 70%;  $p = 0.26$ ), as depicted in ►Table 4. Moreover, some series have identified ETSA to deliver higher visual functional improvement in comparison to TCA.<sup>22,49,69,79,81</sup> Our observations, however, also demonstrated higher rate of visual worsening with TCA

than with ETSA and no statistical association (18 vs 15%;  $p = 0.12$ ). This lower rate of visual worsening encountered with the ETSA approach was attributed to minimal manipulation of compromised ischemic optic apparatus, adequate and early visualization of the subchiasmatic blood vessels, and precision and safer handling of the optic apparatus.<sup>51</sup>

### Operative Complications

On the other hand, we observed that both TCA and ETSA did not differ significantly in visual improvement and GTR but postoperative complications, specifically, seizure and hemorrhage was significantly predominant in TCA as compared with ETSA.<sup>19,78</sup> Some series reported that surgical morbidities such as seizure and hemorrhage were lower in patients treated with ETSA as compared with TCA. Symon and Rosenstein also reported that new onset seizure was a commonly occurring complication of MSM surgery being as high as in 10.9% of cases during TCA.<sup>82</sup> Our study also revealed cases of new onset seizure and the prevalence being more (6%) with TCA than with ETSA (1%). Similarly, intracerebral hemorrhage was found to be more with TCA than ETSA (5 vs 3%). Observation of low cases of seizure and hemorrhage in ETSA in comparison to TCA is expected because in TCA, more or less frontal lobe retraction needs to be done which may cause rupture of small feeding blood vessels and injury to brain parenchyma causing seizure. But ETSA has been superior to TCA in the field of early devascularization of main feeding vessels and no brain retraction.<sup>19</sup> Theoretically, postoperative CSF leakage is a potential complication of approaches and occurs via the frontal sinus during TCA. But in practice and in numerous researches namely, Komotar et al<sup>79</sup> (21.3 vs 4.3%;  $p < 0.001$ ), ETSA is found to be associated with higher rates of CSF leakage than with the TCA.<sup>19,20,63,83</sup> Our study has also shown that postoperative CSF leakage occurs more with ETSA than with TCA (17 vs 8%;  $p = 0.04$ ) (► **Table 4**).

Finally, we report that TCA and ETSA surgical approaches for MSM removal do not display complete superiority over each other when assessed on the basis of postoperative outcome measures. This was apparent since TCA and ETSA displayed poor outcomes with regard to recurrence rates and CSF leakage respectively, coincidentally, two of the commonly used postoperation determinants of improvement. Generally, it was observed that both TCA and ETSA did not improve worsening of visual function, visual improvement, and GTR. However, reduced CSF leakage and increased recurrence rate was associated with TCA, while reduced recurrent rate and increased CSF leakage was attributable to ETSA. The poor recurrence rate associated with TCA may be linked to the long follow-up period, while the comparatively reduced recurrence rate in ETSA cohorts may be accounted for by the short follow-up period. It was apparent that patients who underwent MSM removal by both TCA and ETSA have almost similar preoperative clinical characteristics, an observation which strengthens the comparability of the two cohorts. The results of this review are not much different from recent studies, which have shown that none of the surgical approaches could

be seen as an end in itself since both have advantages and disadvantages, thus the choice of TCA or ETSA may be determined by tumor characteristics, patient-specific clinical presentations, risk/benefits, and prioritization of clinical objectives.

### Limitations

This study, among other factors, may be limited by case heterogeneity, methodological heterogeneity which cannot be cured completely by statistical method, because the study is retrospective in nature. For instance, length of follow-up and tumor characteristics for both cohorts in some cases differed.

### Conclusions

Put together, the choice of TCA or ETSA for surgical removal of MSMs may depend on many factors including tumor characteristics, patient-specific clinical presentations, risk/benefit assessment, and the clinical objective. Ideally, a surgical approach that can maximize the advantages of both TCA and ETSA while at the same time minimize the risks associated with these approaches must be sought.

#### Conflict of Interest

None.

#### Funding

None.

#### Acknowledgments

We would like to thank Dr. Dejun Wu, Dr. Jian Tao, and Dr. Li Dekun at the Department of Neurosurgery, Anhui Medical University for their valuable guidance and revision of our illustrations.

### References

- 1 Al-Mefty O, Smith R. Tuberculum sellae meningiomas. *Meningiomas* Raven, New York 1991;395411:395–411
- 2 Al-Mefty O, Holoubi A, Rifai A, Fox JL. Microsurgical removal of suprasellar meningiomas. *Neurosurgery* 1985;16(3):364–372
- 3 Brihaye J, Brihaye-van Geertruyden M. Management and surgical outcome of suprasellar meningiomas. *Proceedings of the 8th European Congress of Neurosurgery Barcelona, September 6–11, 1987*: Springer; 1988:124–129
- 4 Arifin MZ, Mardjono I, Sidabutar R, Wirjomartani BA, Faried A. Pterional approach versus unilateral frontal approach on tuberculum sellae meningioma: single centre experiences. *Asian J Neurosurg* 2012;7(1):21–24
- 5 Chi JH, McDermott MW. Tuberculum sellae meningiomas. *Neurosurg Focus* 2003;14(6):e6
- 6 Ciric I, Rosenblatt S. Suprasellar meningiomas. *Neurosurgery* 2001;49(6):1372–1377
- 7 Goel A, Muzumdar D, Desai KI. Tuberculum sellae meningioma: a report on management on the basis of a surgical experience with 70 patients. *Neurosurgery* 2002;51(6):1358–1363, discussion 1363–1364

- 8 Ganna A, Dehdashti AR, Karabatsou K, Gentili F. Fronto-basal interhemispheric approach for tuberculoma sellae meningiomas; long-term visual outcome. *Br J Neurosurg* 2009;23(4):422–430
- 9 Galal A, Faisal A, Al-Werdany M, El Shehaby A, Lotfy T, Moharram H. Determinants of postoperative visual recovery in suprasellar meningiomas. *Acta Neurochir (Wien)* 2010;152(1):69–77
- 10 Mirimanoff RO, Dosoretz DE, Linggood RM, Ojemann RG, Martuza RL. Meningioma: analysis of recurrence and progression following neurosurgical resection. *J Neurosurg* 1985;62(1):18–24
- 11 Nanda A, Ambekar S, Javalkar V, Sharma M. Technical nuances in the management of tuberculoma sellae and diaphragma sellae meningiomas. *Neurosurg Focus* 2013;35(6):E7
- 12 Andrews BT, Wilson CB. Suprasellar meningiomas: the effect of tumor location on postoperative visual outcome. *J Neurosurg* 1988;69(4):523–528
- 13 Fahlbusch R, Schott W. Pterional surgery of meningiomas of the tuberculoma sellae and planum sphenoidale: surgical results with special consideration of ophthalmological and endocrinological outcomes. *J Neurosurg* 2002;96(2):235–243
- 14 Jallo GI, Benjamin V. Tuberculoma sellae meningiomas: microsurgical anatomy and surgical technique. *Neurosurgery* 2002;51(6):1432–1439, discussion 1439–1440
- 15 Schick U, Hassler U. Surgical management of tuberculoma sellae meningiomas: involvement of the optic canal and visual outcome. *J Neurol Neurosurg Psychiatry* 2005;76(7):977–983
- 16 Zevgaridis D, Medele RJ, Müller A, Hischa AC, Steiger H-J. Meningiomas of the sellar region presenting with visual impairment: impact of various prognostic factors on surgical outcome in 62 patients. *Acta Neurochir (Wien)* 2001;143(5):471–476
- 17 Kaptain GJ, Vincent DA, Sheehan JP, Laws ER Jr. Transsphenoidal approaches for the extracapsular resection of midline suprasellar and anterior cranial base lesions. *Neurosurgery* 2001;49(1):94–100, discussion 100–101
- 18 Park C-K, Jung H-W, Yang S-Y, Seol HJ, Paek SH, Kim DG. Surgically treated tuberculoma sellae and diaphragm sellae meningiomas: the importance of short-term visual outcome. *Neurosurgery* 2006;59(2):238–243, discussion 238–243
- 19 de Divitiis E, Esposito F, Cappabianca P, Cavallo LM, de Divitiis O. Tuberculoma sellae meningiomas: high route or low route? A series of 51 consecutive cases. *Neurosurgery* 2008;62(3):556–563, discussion 556–563
- 20 Fatemi N, Dusick JR, de Paiva Neto MA, Malkasian D, Kelly DF. Endonasal versus supraorbital keyhole removal of craniopharyngiomas and tuberculoma sellae meningiomas. *Neurosurgery* 2009;64(5, Suppl 2):269–284, discussion 284–286
- 21 Kitano M, Taneda M, Nakao Y. Postoperative improvement in visual function in patients with tuberculoma sellae meningiomas: results of the extended transsphenoidal and transcranial approaches. *J Neurosurg* 2007;107(2):337–346
- 22 Van Gompel JJ, Frank G, Pasquini E, Zoli M, Hoover J, Lanzino G. Expanded endonasal endoscopic resection of anterior fossa meningiomas: report of 13 cases and meta-analysis of the literature. *Neurosurg Focus* 2011;30(5):E15
- 23 Bassiouni H, Asgari S, Stolke D. Tuberculoma sellae meningiomas: functional outcome in a consecutive series treated microsurgically. *Surg Neurol* 2006;66(1):37–44, discussion 44–45
- 24 Liu Y, Chotai S, Ming C, Jin S, Pan J, Qi S. Characteristics of midline suprasellar meningiomas based on their origin and growth pattern. *Clin Neurol Neurosurg* 2014;125:173–181
- 25 Nakamura M, Roser F, Struck M, Vorkapic P, Samii M. Tuberculoma sellae meningiomas: clinical outcome considering different surgical approaches. *Neurosurgery* 2006;59(5):1019–1028, discussion 1028–1029
- 26 Arai H, Sato K, Okuda O, et al. Transcranial transsphenoidal approach for tuberculoma sellae meningiomas. *Acta Neurochir (Wien)* 2000;142(7):751–756, discussion 756–757
- 27 Kim T-W, Jung S, Jung T-Y, Kim I-Y, Kang S-S, Kim S-H. Prognostic factors of postoperative visual outcomes in tuberculoma sellae meningioma. *Br J Neurosurg* 2008;22(2):231–234
- 28 Landeiro JA, Gonçalves MB, Guimarães RD, et al. Tuberculoma sellae meningiomas: surgical considerations. *Arq Neuropsiquiatr* 2010;68(3):424–429
- 29 Pamir MN, Özdoğan K, Belirgen M, Kilic T, Özek MM. Outcome determinants of pterional surgery for tuberculoma sellae meningiomas. *Acta Neurochir (Wien)* 2005;147(11):1121–1130, discussion 1130
- 30 Sade B, Lee JH. High incidence of optic canal involvement in tuberculoma sellae meningiomas: rationale for aggressive skull base approach. *Surg Neurol* 2009;72(2):118–123, discussion 123
- 31 Nozaki K, Kikuta K, Takagi Y, Mineharu Y, Takahashi JA, Hashimoto N. Effect of early optic canal unroofing on the outcome of visual functions in surgery for meningiomas of the tuberculoma sellae and planum sphenoidale. *Neurosurgery* 2008;62(4):839–844, discussion 844–846
- 32 Ohta K, Yasuo K, Morikawa M, Nagashima T, Tamaki N. Treatment of tuberculoma sellae meningiomas: a long-term follow-up study. *J Clin Neurosci* 2001;8(Suppl 1):26–31
- 33 Mathiesen T, Kihlström L. Visual outcome of tuberculoma sellae meningiomas after extradural optic nerve decompression. *Neurosurgery* 2006;59(3):570–576, discussion 570–576
- 34 Palani A, Panigrahi MK, Purohit AK. Tuberculoma sellae meningiomas: a series of 41 cases; surgical and ophthalmological outcomes with proposal of a new prognostic scoring system. *J Neurosci Rural Pract* 2012;3(3):286–293
- 35 Li X, Liu M, Liu Y, Zhu S. Surgical management of tuberculoma sellae meningiomas. *J Clin Neurosci* 2007;14(12):1150–1154
- 36 Otani N, Muroi C, Yano H, Khan N, Pangalu A, Yonekawa Y. Surgical management of tuberculoma sellae meningioma: role of selective extradural anterior clinoidectomy. *Br J Neurosurg* 2006;20(3):129–138
- 37 Jang W-Y, Jung S, Jung T-Y, Moon K-S, Kim I-Y. The contralateral subfrontal approach can simplify surgery and provide favorable visual outcome in tuberculoma sellae meningiomas. *Neurosurg Rev* 2012;35(4):601–607, discussion 607–608
- 38 Mehrazin M, Mirfalah R. Early postoperative visual outcome in microsurgically treated suprasellar meningiomas predict long-term visual outcome. *Turk Neurosurg* 2008;18(4):380–386
- 39 Seol HJ, Park H-Y, Nam D-H, et al. Clinical outcomes of tuberculoma sellae meningiomas focusing on reversibility of postoperative visual function. *Acta Neurochir (Wien)* 2013;155(1):25–31
- 40 Lu ZF, Cheng XB, Zhao YG, Shi BZ. Twenty-nine cases of resection of suprasellar meningioma through small bone window: an interhemispheric approach. *Contemp Oncol (Pozn)* 2013;17(6):525–529
- 41 Ceylan S, Koc K, Anik I. Extended endoscopic transsphenoidal approach for tuberculoma sellae meningiomas. *Acta Neurochir (Wien)* 2011;153(1):1–9
- 42 Chowdhury FH, Haque MR, Goel AH, Kawsar KA. Endoscopic endonasal extended transsphenoidal removal of tuberculoma sellae meningioma (TSM): an experience of six cases. *Br J Neurosurg* 2012;26(5):692–699
- 43 Gadgil N, Thomas JG, Takashima M, Yoshor D. Endoscopic resection of tuberculoma sellae meningiomas. *J Neurol Surg B Skull Base* 2013;74(4):201–210
- 44 Koutourousiou M, Fernandez-Miranda JC, Stefkó ST, Wang EW, Snyderman CH, Gardner PA. Endoscopic endonasal surgery for suprasellar meningiomas: experience with 75 patients. *J Neurosurg* 2014;120(6):1326–1339
- 45 Ogawa Y, Tominaga T. Extended transsphenoidal approach for tuberculoma sellae meningioma—what are the optimum and critical indications? *Acta Neurochir (Wien)* 2012;154(4):621–626

- 46 Khan OH, Krischek B, Holliman D, et al. Pure endoscopic expanded endonasal approach for olfactory groove and tuberculum sellae meningiomas. *J Clin Neurosci* 2014;21(6):927–933
- 47 Laufer I, Anand VK, Schwartz TH. Endoscopic, endonasal extended transsphenoidal, transplanum transtuberulum approach for resection of suprasellar lesions. *J Neurosurg* 2007;106(3):400–406
- 48 Gardner PA, Kassam AB, Thomas A, et al. Endoscopic endonasal resection of anterior cranial base meningiomas. *Neurosurgery* 2008;63(1):36–52, discussion 52–54
- 49 Attia M, Kandasamy J, Jakimovski D, et al. The importance and timing of optic canal exploration and decompression during endoscopic endonasal resection of tuberculum sella and planum sphenoidale meningiomas. *Neurosurgery* 2012;71(1, Suppl Operative):58–67
- 50 Bohman L-E, Stein SC, Newman JG, et al. Endoscopic versus open resection of tuberculum sellae meningiomas: a decision analysis. *ORL J Otorhinolaryngol Relat Spec* 2012;74(5):255–263
- 51 Wang Q, Lu X-J, Ji W-Y, et al. Visual outcome after extended endoscopic endonasal transsphenoidal surgery for tuberculum sellae meningiomas. *World Neurosurg* 2010;73(6):694–700
- 52 Couldwell WT, Weiss MH, Rabb C, Liu JK, Apfelbaum RI, Fukushima T. Variations on the standard transsphenoidal approach to the sellar region, with emphasis on the extended approaches and parasellar approaches: surgical experience in 105 cases. *Neurosurgery* 2004;55(3):539–547, discussion 547–550
- 53 DerSimonian R. Combining evidence from clinical trials. *Anesth Analg* 1990;70(5):475–476
- 54 DerSimonian R, Charette LJ, McPeck B, Mosteller F. Reporting on methods in clinical trials. *N Engl J Med* 1982;306(22):1332–1337
- 55 DerSimonian R, Laird N. Meta-analysis in clinical trials. *Control Clin Trials* 1986;7(3):177–188
- 56 DerSimonian R. Meta-analysis in the design and monitoring of clinical trials. *Stat Med* 1996;15(12):1237–1248, discussion 1249–1252
- 57 Stirling J, Edin M. Tumor of the meninges in the region of the pituitary body, pressing on the chiasma. *Ann Ophthalmol* 1897;6:15–16
- 58 Cushing H, Eisenhardt L. Suprasellar meningiomas. Meningiomas: Their Classification, Regional Behaviour, Life History, and Surgical End Results. UK: Hafner Publishing Co Ltd; 1938:224–49
- 59 Benjamin V, Russell SM. The microsurgical nuances of resecting tuberculum sellae meningiomas. *Neurosurgery* 2005;56(2, Suppl):411–417, discussion
- 60 Noguchi A, Balasingam V, McMenomey SO, Delashaw JB Jr. Supraorbital craniotomy for parasellar lesions. Technical note. *J Neurosurg* 2005;102(5):951–955
- 61 Schmidt RF, Choudhry OJ, Takkellapati R, Eloy JA, Couldwell WT, Liu JK. Hermann Schloffer and the origin of transsphenoidal pituitary surgery. *Neurosurg Focus* 2012;33(2):E5
- 62 Dusick JR, Esposito F, Kelly DF, et al. The extended direct endonasal transsphenoidal approach for nonadenomatous parasellar tumors. *J Neurosurg* 2005;102(5):832–841
- 63 Cook SW, Smith Z, Kelly DF. Endonasal transsphenoidal removal of tuberculum sellae meningiomas: technical note. *Neurosurgery* 2004;55(1):239–244, discussion 244–246
- 64 Kassam AB, Thomas A, Carrau RL, et al. Endoscopic reconstruction of the cranial base using a pedicled nasoseptal flap. *Neurosurgery* 2008;63(1, Suppl 1):ONS44–ONS52, discussion ONS52–ONS53
- 65 Kouri JG, Chen MY, Watson JC, Oldfield EH. Resection of suprasellar tumors by using a modified transsphenoidal approach. Report of four cases. *J Neurosurg* 2000;92(6):1028–1035
- 66 Maira G, Anile C, Albanese A, Cabezas D, Pardi F, Vignati A. The role of transsphenoidal surgery in the treatment of craniopharyngiomas. *J Neurosurg* 2004;100(3):445–451
- 67 Honegger J, Fahlbusch R, Buchfelder M, Huk WJ, Thierauf P. The role of transsphenoidal microsurgery in the management of sellar and parasellar meningioma. *Surg Neurol* 1993;39(1):18–24
- 68 Fatemi N, Dusick JR, de Paiva Neto MA, Kelly DF. The endonasal microscopic approach for pituitary adenomas and other parasellar tumors: a 10-year experience. *Neurosurgery* 2008;63(4, Suppl 2):244–256, discussion 256
- 69 Cappabianca P, Cavallo L, Esposito F, De Divitiis O, Messina A, De Divitiis E. Extended endoscopic endonasal approach to the midline skull base: the evolving role of transsphenoidal surgery. *Adv Tech Stand Neurosurg* 2008;33:151–199
- 70 de Divitiis E, Cavallo LM, Esposito F, Stella L, Messina A. Extended endoscopic transsphenoidal approach for tuberculum sellae meningiomas. *Neurosurgery* 2007;61(5, Suppl 2):229–237, discussion 237–238
- 71 Liu JK, Christiano LD, Patel SK, Tubbs RS, Eloy JA. Surgical nuances for removal of tuberculum sellae meningiomas with optic canal involvement using the endoscopic endonasal extended transsphenoidal transplanum transtuberulum approach. *Neurosurg Focus* 2011;30(5):E2
- 72 Bowers CA, Altay T, Couldwell WT. Surgical decision-making strategies in tuberculum sellae meningioma resection. *Neurosurg Focus* 2011;30(5):E1
- 73 Ceylan S, Koc K, Anik I. Extended endoscopic approaches for midline skull-base lesions. *Neurosurg Rev* 2009;32(3):309–319, discussion 318–319
- 74 Chokyu I, Goto T, Ishibashi K, Nagata T, Ohata K. Bilateral subfrontal approach for tuberculum sellae meningiomas in long-term postoperative visual outcome. *J Neurosurg* 2011;115(4):802–810
- 75 Mahmoud M, Nader R, Al-Mefty O. Optic canal involvement in tuberculum sellae meningiomas: influence on approach, recurrence, and visual recovery. *Neurosurgery* 2010;67(3, Suppl Operative ):ons108–ons118, discussion ons118–ons119
- 76 Hadad G, Bassagasteguy L, Carrau RL, et al. A novel reconstructive technique after endoscopic expanded endonasal approaches: vascular pedicle nasoseptal flap. *Laryngoscope* 2006;116(10):1882–1886
- 77 Zanation AM, Carrau RL, Snyderman CH, et al. Nasoseptal flap reconstruction of high flow intraoperative cerebral spinal fluid leaks during endoscopic skull base surgery. *Am J Rhinol Allergy* 2009;23(5):518–521
- 78 Clark AJ, Jahangiri A, Garcia RM, et al. Endoscopic surgery for tuberculum sellae meningiomas: a systematic review and meta-analysis. *Neurosurg Rev* 2013;36(3):349–359
- 79 Komotar RJ, Starke RM, Raper DM, Anand VK, Schwartz TH. Endoscopic endonasal versus open transcranial resection of anterior midline skull base meningiomas. *World Neurosurg* 2012;77(5–6):713–724
- 80 Rosenstein J, Symon L. Surgical management of suprasellar meningioma. Part 2: Prognosis for visual function following craniotomy. *J Neurosurg* 1984;61(4):642–648
- 81 Dehdashti AR, Ganna A, Witterick I, Gentili F. Expanded endoscopic endonasal approach for anterior cranial base and parasellar lesions: indications and limitations. *Neurosurgery* 2009;64(4):677–687, discussion 687–689
- 82 Symon L, Rosenstein J. Surgical management of suprasellar meningioma. Part 1: The influence of tumor size, duration of symptoms, and microsurgery on surgical outcome in 101 consecutive cases. *J Neurosurg* 1984;61(4):633–641
- 83 Wang Q, Lu XJ, Li B, Ji WY, Chen KL. Extended endoscopic endonasal transsphenoidal removal of tuberculum sellae meningiomas: a preliminary report. *J Clin Neurosci* 2009;16(7):889–893