


Grisel Syndrome: Case Report

Síndrome de Grisel: Relato de caso

Bruno Roncaglio¹ Tadeu Gervazoni Debom¹ Marcus Alexandre Novo Brazolino¹
Thiago Cardoso Maia¹ José Lucas Batista Filho¹ Igor Machado Cardoso¹ Charbel Jacob Junior¹ 

¹ Department of Orthopedics and Traumatology, Instituto de Coluna Vertebral, Hospital Santa Casa de Misericórdia, Vitória, ES, Brazil

Address for correspondence Bruno Roncaglio, Departamento de Ortopedia e Traumatologia, Instituto de Coluna Vertebral, Hospital Santa Casa de Misericórdia, Vitória, ES, 29025-023, Brazil (e-mail: institutodecoluna@gmail.com; brroncaglio@gmail.com).

Arq Bras Neurocir 2020;39(1):37–40.

Abstract

We report a case of a rare disease, Grisel syndrome, which manifests as a kind of rotational fixation of the atlas on the axis, resulting from an infectious process of the upper airways. In the present report, we discuss etiology, clinical presentation, diagnosis, treatment and outcome after intervention.

Keywords

- ▶ atlantoaxial joint / injuries
- ▶ grisel syndrome / treatment

Resumo

Relatamos um caso de doença rara, a síndrome de Grisel, que se manifesta como um tipo de fixação rotatória do atlas sobre o eixo, decorrente de processo infeccioso das vias aéreas superiores. Neste relato, discutiremos etiologia, quadro clínico, diagnóstico, tratamento e evolução do caso após intervenção.

Palavras-chave

- ▶ articulação atlantoaxial / lesões
- ▶ síndrome de grisel / tratamento

Introduction

Grisel syndrome is a rare type of rotational fixation of the atlas on the axis (C1-C2), initially described in 1830, when Bell¹ reported a case of atlantoaxial subluxation secondary to a process of syphilitic ulcerative pharynx. Subsequently, it has been described as a rare complication of inflammatory processes secondary to otorhinolaryngological and gastroenterologic surgical interventions and to upper airway infections (UAIs). The etiopathogenesis has not been fully clarified, but it is described as an association with an infection or inflammatory process of the head and neck region with subsequent dissemination to the atlantoaxial joint, which would weaken at the level of its bone and ligamentous insertion. It has an incidence of 68% among the population younger than 12 years of age, and of 90% among those under 21 years of age.^{2,3} The typical presentation is with cervical pain, deformity and limitation of movements (fixed torticollis), with the existence

of a recent inflammatory or infectious process. The child adopts a cock robin position, due to the presence of the so-called paradoxical torticollis, which differs from the common muscular torticollis because, instead of shortening, there is stretching of the sternocleidomastoid muscle. Another finding from the clinical examination is the Sudek sign, in which the C2 spinous process is diverted to the same side of the head. In less than 15% of the cases, neurological complications occur, ranging from transient sensory alterations to tetraplegia, and even sudden death. The common differential diagnosis is meningitis, and retropharyngeal abscess, spasmodic muscle torticollis, trauma and adverse drug reactions should also be considered.⁴ Imaging exams help in the diagnosis. Radiography and computed tomography (CT) can show an asymmetry between the lateral masses of C1 and an increase in the atlantodental interval.

The classification of Fielding et al⁵ (→ Fig. 1) enables the grouping of the different degrees of atlantoaxial subluxation

received
September 18, 2017
accepted
December 8, 2017

DOI <https://doi.org/10.1055/s-0037-1598650>.
ISSN 0103-5355.

Copyright © 2020 by Thieme Revinter Publicações Ltda, Rio de Janeiro, Brazil

License terms



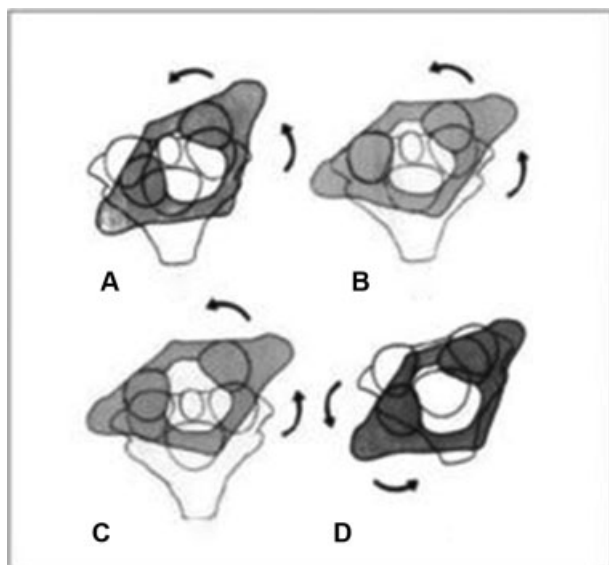


Fig. 1 (A) Type I; (B) type II; (C) type III; (D) type IV.

and assists in the prediction of the prognosis for potential complications, dividing the cases into: type I, fixed rotational subluxation; type II, anterior deviation = 3–5 mm; type III, anterior deviation > 5 mm; and type IV, posterior deviation. The treatment is conservative at first. Cases of failure, irreducible subluxation and recurrences have surgical indication.⁵

The objective of the present work is to report a rare case of Grisel syndrome, with inveterate atlantoaxial subluxation and its treatment with cranial halo, and to describe its physiopathology.

Clinical Case

A 9-year-old male patient was admitted to our service with cervical pain, deformity and limitation in range of motion for 50 days, with no history of trauma, which was treated as spasmodic torticollis. Regarding his previous history, the patient presented a picture of UAI in the three weeks preceding the onset of symptoms, with resolution after the use of symptomatic relief medications. Upon clinical examination, a limitation in the amplitude of the cervical movement was observed, with inclination of the head to the right and deviation of the contralateral chin, without neurological deficit (► **Fig. 2**). The patient was submitted to radiography and computed tomography (CT) scans, in which a C1-C2 rotational subluxation was visualized (► **Figs. 3, 4 and 5**). The patient was submitted to cranial halo and traction in a surgical center, which was maintained for 15 days in a Stagnara chair with progressive traction, and subsequently used a halo vest for 12 weeks (► **Fig. 6**), obtaining C1-C2 reduction with a 5-mm index measured in the coronal and axial planes (► **Figs. 7 and 8**). The patient presented good evolution with the proposed treatment, and did not evolve with functional limitation in the range of motion of the cervical spine (► **Fig. 9**).

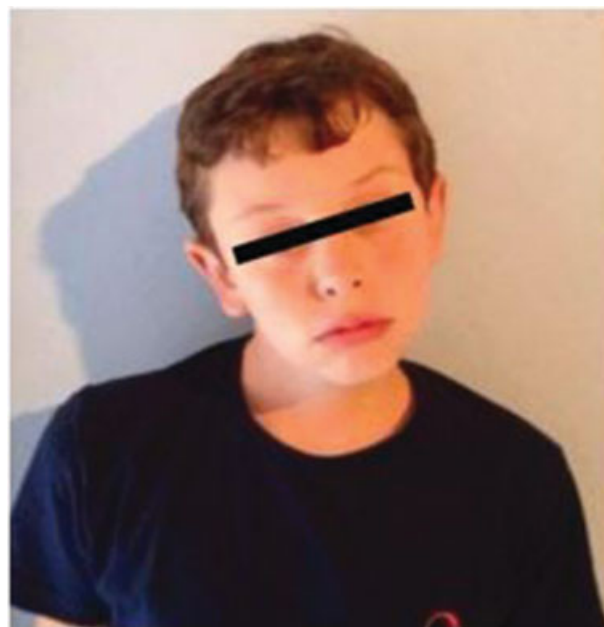


Fig. 2 Clinical image of a patient with head tilt to the right and rotated back to the contralateral side.

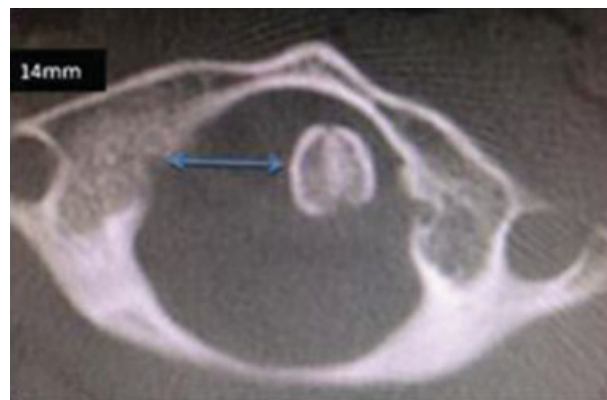


Fig. 3 Computed tomography; axial view showing rotational subluxation in C1-C2.

Discussion

Grisel syndrome is an eminently pediatric pathology, although there are cases reported in adults. In a series of cases, Watson-Jones⁶ and Wilson et al⁴ demonstrated that most cases are manifested in children under 10 years old. It results from a pathological relaxation of the ligaments around the C1-C2 joint, following an inflammatory, infectious or surgical procedure.^{7,8}

The diagnosis of non-traumatic atlantoaxial subluxation requires radiological investigation. Simple cervical spine radiography may present an asymmetry between the joints in the anteroposterior projection and increase in the atlantodental interval in lateral projections. In children, the atlantodental interval normally measures less than 3 mm. An increase in this interval to more than 5 mm would suggest traumatic or non-traumatic subluxation.⁸ The exam of choice in the evaluation of the bone cervical spine is the CT, while magnetic resonance

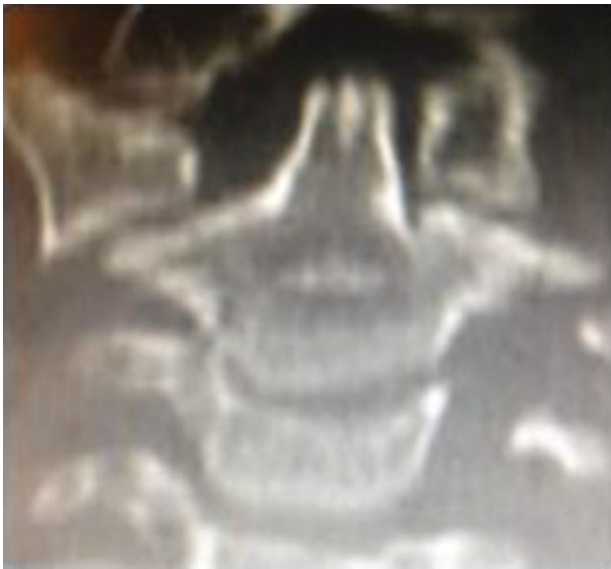

Fig. 4 Computed tomography; coronal view showing rotational subluxation in C1-C2.

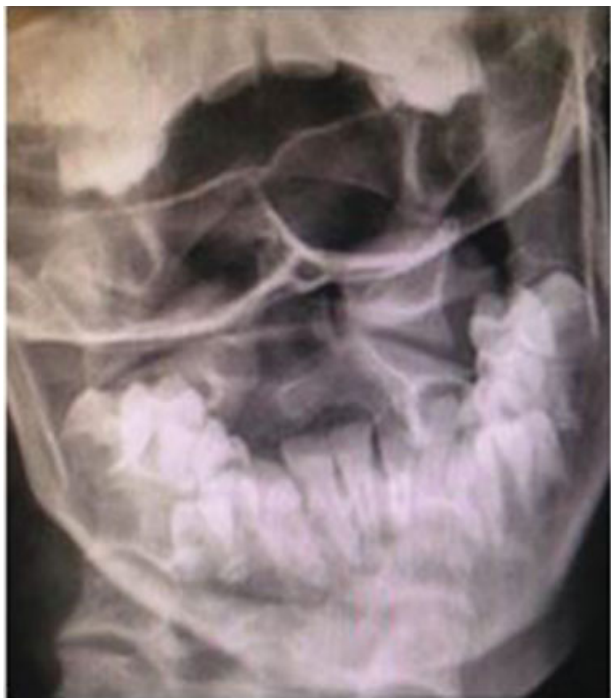

Fig. 5 Transoral radiography of the cervical spine showing subluxation in C1-C2.

imaging (MRI) provides information related to the structures of the surrounding soft tissues and spinal cord.

In the case in question, the patient presented an irreducible lesion, with an atlantoaxial interval of 14 mm, and type III in the Fielding et al⁵ classification. Due to the delayed definitive diagnosis, there was no spontaneous reduction of the subluxation, and the patient was submitted to skeletal traction.

The prognosis with the conservative treatment is excellent, when the diagnosis is established in adequate time, that is, less than 3 weeks after the onset of the first symptoms. After this period, some form of surgical intervention may be required

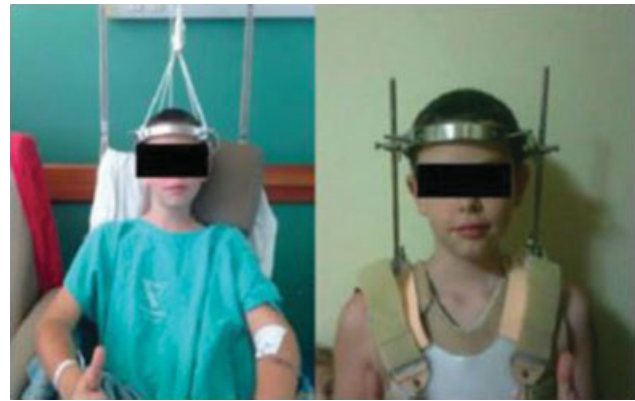

Fig. 6 Patient in traction and with halo vest for bloodless reduction.

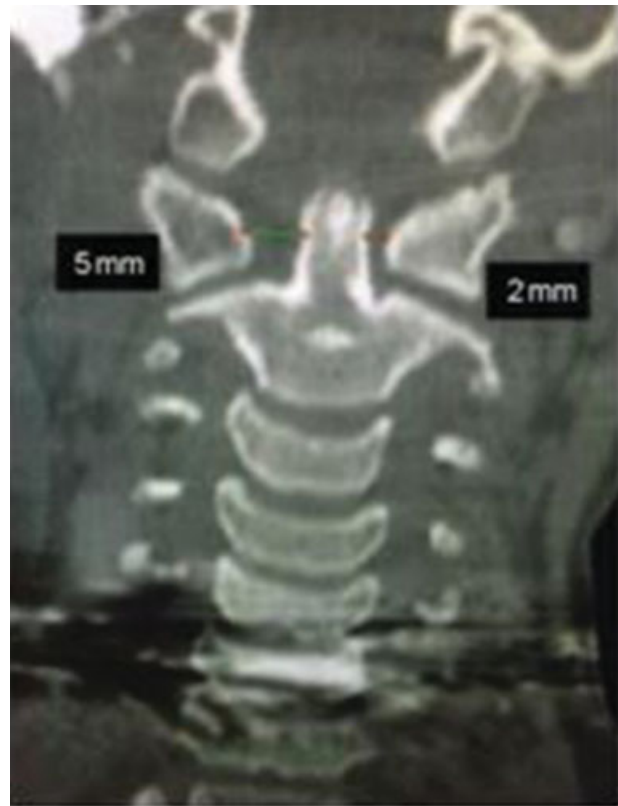

Fig. 7 Computed tomography; frontal view showing acceptable reduction of the subluxation in C1-C2.

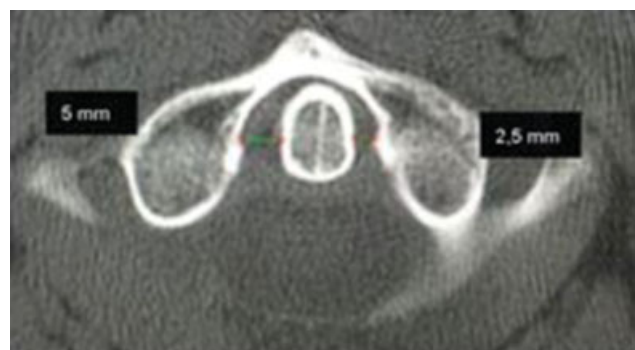

Fig. 8 Computed tomography; axial view showing acceptable reduction of the subluxation in C1-C2.

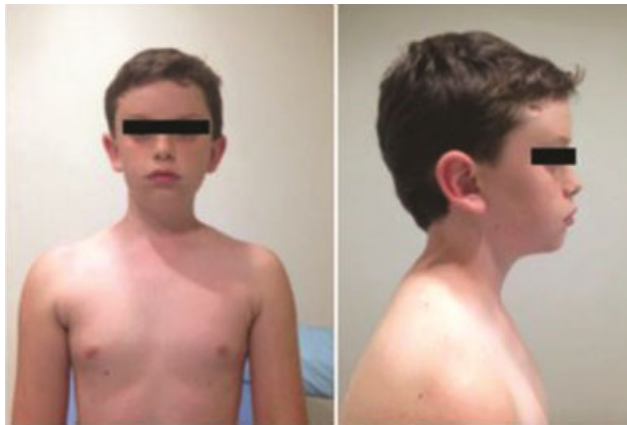

Fig. 9 Clinical image of the patient in anteroposterior and profile views after the reduction.

due to the irreducibility.⁹ In most cases, the subluxation is reduced spontaneously.¹⁰

The treatment for Grisel syndrome is controversial. It usually starts with conservative and supportive measures, including resting, cervical collar, analgesics, anti-inflammatories, muscle relaxants and, when necessary, antibiotic therapy and abscess drainage.³ The expected time for spontaneous reduction, in most cases, is after 7 days of treatment; after the reduction of the lesion and regression of the inflammatory process, the stability is recovered.¹⁰ In cases in which spontaneous reduction does not occur, manual reduction under sedation, cranial traction and, lastly, surgical treatment with craniocervical arthrodesis may be attempted.^{9,11,12} Wetzell and La Rocca⁸ proposed a treatment protocol for non-traumatic atlantoaxial rotational subluxation based on the Fielding et al⁵ classification. The conservative treatment for lesions of types I, II and III would be soft paste, rigid collar (Philadelphia) and halo-vest respectively. For type-IV lesions, they recommend surgical treatment, which is also indicated in cases of failure of the conservative treatment, recurrence of subluxation, and irreducible subluxations.⁸ Gomes et al¹³ evaluated retrospectively 35 cases of Grisel syndrome treated at a referral hospital, and they found 19 female children with a mean age of 6.9 years. Cervical pain was the main complaint of 85% of the patients, followed by deformity and loss of mobility. History of UAI was present in 80% of the cases, and trauma was also found in 14%. Only one patient suffered neurological deficit (deltoid and triceps paresis), with complete remission after the treatment. According to Fielding et al,⁵ 14 patients were classified as type II, and there were no cases of type IV. The treatment performed with collar alone in twenty patients had good results. Surgical treatment was performed in six cases, with C1-C2 arthrodesis preceded by a reduction with halo and traction. Complications resulting from the treatment were scarce. Pilge et al¹⁴ reported an 11-year-old patient with 2 months of evolution of atlantoaxial subluxation after surgery for cochlear implantation, in which a reduction was performed under general anesthesia and myorelaxants, followed by cervical collar. The reduction was satisfactory.

The patient in the present report was submitted to progressive load (halo) traction for 2 weeks, and used a halo vest for another 12 weeks. The case showed satisfactory evolution, obtaining a reduction of C1-C2, with an index of around 5 mm measured in the coronal plane.

Conclusion

Despite its rarity, it is fundamental that the medical community know this entity, in order to avoid subdiagnoses and consequent irreversible injuries.

Conflict of Interests

The authors have no conflict of interests to declare.

References

- Bell C. The nervous system of the human body, embracing papers to the Royal Society on the subject of nerves. London: Longman, Rees and Orme; 1830:403
- Bocciolini C, Dall'Olio D, Cunsolo E, Cavazzuti PP, Laudadio P. Grisel's syndrome: a rare complication following adenoidectomy. *Acta Otorhinolaryngol Ital* 2005;25(04):245-249
- Fernández Cornejo VJ, Martínez-Lage JF, Piqueras C, Gelabert A, Poza M. Inflammatory atlanto-axial subluxation (Grisel's syndrome) in children: clinical diagnosis and management. *Childs Nerv Syst* 2003;19(5-6):342-347
- Wilson M, Michele AA, Jacobson EW. Spontaneous dislocation of the atlanto-axial articulation, including a report of a caso with quadriplegia. *J Bone Joint Surg* 1940;22:698
- Fielding JW, Hawkins RJ, Hensinger RN, Francis WR. Atlantoaxial rotary deformities. *Orthop Clin North Am* 1978;9(04):955-967
- Watson-Jones R. Spontaneous hyperemic dislocation of the atlas. *Proc R Soc Med* 1932;25:586
- Feldmann H, Meister EF, Küttner K. [From the expert's office. Atlanto-axial subluxation with spastic torticollis after adenoidectomy resp. tonsillectomy in rose position - malpractice of the surgeon or the anaesthesiologist?] *Laryngorhinootologie* 2003;82(11):799-804
- Wetzell FT, La Rocca H. Grisel's syndrome. *Clin Orthop Relat Res* 1989;240(240):141-152
- Subach BR, McLaughlin MR, Albright AL, Pollack IF. Current management of pediatric atlantoaxial rotatory subluxation. *Spine* 1998;23(20):2174-2179
- Phillips WA, Hensinger RN. The management of rotatory atlanto-axial subluxation in children. *J Bone Joint Surg Am* 1989;71(05):664-668
- Martinez-Lage JF, Martinez Perez M, Fernandez Cornejo V, Poza M. Atlanto-axial rotatory subluxation in children: early management. *Acta Neurochir (Wien)* 2001;143(12):1223-1228
- Park SW, Cho KH, Shin YS, et al. Successful reduction for a pediatric chronic atlantoaxial rotatory fixation (Grisel syndrome) with long-term halter traction: case report. *Spine* 2005;30(15):E444-E449
- Gomes FCP, Meyer GPV, Lutaka AS, et al. Avaliação retrospectiva dos casos de Síndrome de Grisel no IOT-HCFMUSP. *Coluna/Columna* vol.10 n.2. São Paulo 2011
- Pilge H, Prodingner PM, Bürklein D, Holzappel BM, Lauen J. Non-traumatic subluxation of the atlanto-axial joint as rare form of acquired torticollis: diagnosis and clinical features of the Grisel's syndrome. *Spine* 2011;36(11):E747-E751