

Delayed Closure of Giant Omphaloceles in West Africa: Report of Five Cases

Oumama El Ezzi¹ Raymond Bossou² Olivier Reinberg¹ Sabine Vasseur Maurer¹
Anthony de Buys Roessingh¹

¹Department of Pediatric Surgery, CURCP, Centre Hospitalier Universitaire Vaudois, Lausanne, Switzerland

²Departement du zou et collines – Pédiairy, Abomey, Benin

Address for correspondence Anthony de Buys Roessingh, MD, PhD, HDR, Department of Pediatric Surgery, CURCP, Centre Hospitalier Universitaire Vaudois, Lausanne 1011, Switzerland (e-mail: anthony.debuys-roessingh@chuv.ch).

Eur J Pediatr Surg Rep 2017;5:e4–e8.

Abstract

Giant omphalocele (GO) management is controversial and not easy. Conservative management at birth and delayed surgical closure is usually mandatory. Postponed surgery may be challenging and carry the risk of intensive care treatment. We report on five children who were treated in our department for GO between 2000 and 2010. Initially, the patients were managed conservatively in West Africa. Delayed closure of the ventral hernia was performed in Switzerland after patient transfer through a nongovernmental organization. Fascial closure was performed at the median age of 23 months. Median diameter of the hernias was 10 × 10 cm ranging from 10 × 8 cm to 24 × 15 cm. Four (80%) patients had associated anomalies. Three children needed mechanical ventilation in the intensive care unit after surgery. Median hospitalization was 19 days. Complications were seen in two patients. The follow-up showed no recurrence of ventral hernia. There was no mortality.

Keywords

- ▶ giant omphalocele
- ▶ treatment
- ▶ delayed closure

This report shows that conservative management of a GO at birth with delayed closure of the ventral hernia after transferring the patients to a European center is a safe approach for West African children and avoids life-threatening procedures. Delayed closure of a GO may be nevertheless challenging everywhere.

New Insights and the Importance for the Pediatric Surgeon

Delayed closure of a GO is challenging, and this type of surgery in West Africa remains risky and life compromising at any age.

Introduction

Omphalocele is a congenital abdominal defect that occurs in 1 of 4,000 to 7,000 live births. Sex ratio is 1:1. It is called giant omphalocele (GO) when the defect is larger than 5 cm or contains the liver.^{1,2} Omphaloceles are believed to result from a failure of the lateral unfolding of the embryo, leading to an inadequate development of the abdominal cavity.^{3,4} A GO consists of a three-layered membrane of peritoneum that contains mainly intestines and liver, Wharton's jelly, and amnion.⁵ A high incidence (60%) of associated congenital anomalies is reported, essentially cardiovascular malforma-

tions.^{6,7} Prognosis depends on the presence of congenital malformations and karyotypic anomalies.⁸ The mortality of this pathology is considerable, ranging from 10 to 25%.⁹ For infants requiring positive ventilation at birth, the mortality may be as high as 67% compared with 25% in cases managed nonoperatively with delayed surgical closure.¹⁰


The disproportion of the abdominal cavity and the contents of the hernia, and the inadvisability to perform neonatal closure of the defect can be criteria for its classification as a GO.¹¹ Many strategies for the management of GO have been described. When feasible, primary staged closure is widely accepted. For patients with several comorbidities,

received
September 6, 2016
accepted after revision
January 27, 2017

DOI <http://dx.doi.org/10.1055/s-0037-1599796>.
ISSN 2194-7619.

© 2017 Georg Thieme Verlag KG
Stuttgart • New York

License terms



significant pulmonary compromise and/or very low weight at birth, or when conditions of neonatal resuscitation are deficient, conservative management with primary epithelialization followed by a delayed closure of ventral herniation is a safer approach.^{12,13}

In this case series, we present here our experience with five children born in West Africa with GO, who were transferred and treated in Lausanne after initial management in their home countries. The aim of this study was to analyze the results of delayed closure of GO to determine whether this surgery could be performed at the local institutions.

Case Series

Between 2000 and 2010, five children with GO were treated in our service of pediatric surgery at the Centre Hospitalier Universitaire Vaudois (CHUV) in Lausanne. All patients came from West Africa.

The Department of Pediatric Surgery of the University Hospital in Lausanne (CHUV) has been providing medical support to Benin and Togo since 1980 by organizing yearly surgical missions and follow-up of operated children. The surgical missions take place in the Hospital Center of the Department of Zou and Colline, in Abomey, Benin. The Pediatric Hospital of Sédo-Goho, built in 1997 in Abomey, Benin, selects children according to their pathology in preparation for the surgical mission.¹⁴ The five children presented here were selected for transfer to our hospital in Switzerland during our surgical missions to Benin. Their condition was deemed too serious for local treatment and surgery. The criteria for the transfer of these five children were associated anomalies and size of the omphalocele.

Five patients (three girls, two boys; [Table 1](#)) were transferred to Switzerland for reconstructive surgery. Three were natives of Benin, two others came from Togo. Surgery was not performed in Abomey because of the possibly complex nature of the procedure, associated medical conditions, and degree of availability and adequacy of postoperative care.

There was no available information about term, mode of delivery, and weight at birth. Obviously, there was not any

prenatal diagnosis. Patient 1 ([Table 1](#)) had an operation in his native country following the Gross technique in the first day of life.¹⁵ All others benefited from nonsurgical topical therapy leading to epithelialization of the GO. Limited data were available concerning initial treatment because of a lack of detailed medical documents. There was no precise information on the duration of hospitalization after birth and on the frequency of topical applications. Data regarding chromosomal abnormalities in this group of patients were not available.

The median diameter of the hernias was 10 × 10 cm, ranging from 10 × 8 cm to 24 × 15 cm. In patient 5, the entire liver protruded in the GO ([Fig. 1](#)). In the other patients, the omphalocele contained part of the liver and the intestines. Associated anomalies were observed in four (80%) patients, including tetralogy of Fallot (one), patent ductus arteriosus (one), bilateral inguinal hernia (two), bilateral cryptorchidism (one), pelvic kidney (one), partial sterna cleft (one), and Goltz's syndrome (one), an autosomal dominant inherited disorder characterized by numerous basal cell carcinomas, maxillary keratocysts, and musculoskeletal malformations.^{4,16}

Cardiovascular anomalies found in two patients were corrected surgically before GO management. Both were operated in our hospital.

Delayed closure was performed at a median age of 23 months (range: 17–56 months). Direct closure was possible in four patients. Fascial edges were defined. Herniated viscera were reduced and fasciae were closed with interrupted nonabsorbable sutures without any patches. No difficulties were related to the surgical procedure, and the abdominal wall closure was realized without undue tension.

Patient 5 required four operations and five general anesthetics. He underwent staged closure following the Schuster modified technique¹⁷: two meshes (GORE DUALMESH Biomaterial 18 × 24 × 2 mm, W. L. Gore & Associates), which were fashioned to the size of each fascial edge of the defect ([Fig. 1](#)), were sutured centrally to each other to attain viscera coverage. The surrounding skin flaps were mobilized and then approximated over the patches, leaving them

Table 1 Patient cohort

Patient	Sex	Associated malformations	Size (cm)	Age at surgery (m)	ICU stay (d)	Mechanical ventilation (d)	Hospital stay (d)	Parenteral nutrition (d)	Complications	Controls
1	M	Tetralogy of Fallot Bilateral inguinal hernia	10 × 10	34	0	0	17	0		3
2	F	Patent ductus arteriosus	20 × 10	56	0	3	12	0		2
3	F		10 × 8	17	3	0	19	6	High blood pressure	1
4	F	Goltz's syndrome Pelvic kidney Sternal cleft	10 × 8	23	15	10	19	15		1
5	M	Bilateral inguinal hernia Bilateral cryptorchidism	24 × 15	17	42	41	84	37	Oliguria Respiratory distress Patch exposure Wound infection	3

Abbreviation: ICU, intensive care unit.

partially exposed. Gradual plication of the sac with metallic clamps was then performed every 48 to 72 hours at the bedside in the pediatric intensive care unit (ICU). The patches were removed and definitive closure achieved in the operating room 84 days later. Concomitant procedures included sternal cleft closure associated to an appendectomy ($n = 1$) and correction of a bilateral hernia ($n = 1$).

Postoperative complications were observed in two patients. The first patient showed a transient high blood pressure that did not require treatment and declined spontaneously 4 weeks later. The second suffered respiratory distress requiring prolonged intubation, central venous line sepsis due to *Staphylococcus epidermidis*, and wound infection associated with dehiscence and patch exposure. Both patients survived.

Of our five patients, three had to remain in the pediatric ICU during the postoperative period, with a mean stay of 20 days. Three required mechanical ventilation 3, 10, and 41 days, respectively.

Three patients needed parenteral feeding for a mean duration of 19.3 days (range: 6–37).

In the other two patients, early enteral feeding was possible without any parenteral nutritional support.

The length of hospitalization varied from 12 to 84 days, with a median stay of 19 days, after which the patients returned to their home countries. The follow-up controls ranged from one to three postoperative controls that took place each year in Benin 10 to 36 months after surgery. No recurrence of a ventral hernia was observed during this follow-up period.

Discussion

This case series shows that conservative management of GO at birth in West Africa without neonatal intensive care and delayed closure of the ventral hernia in a European center turned out to be safe.

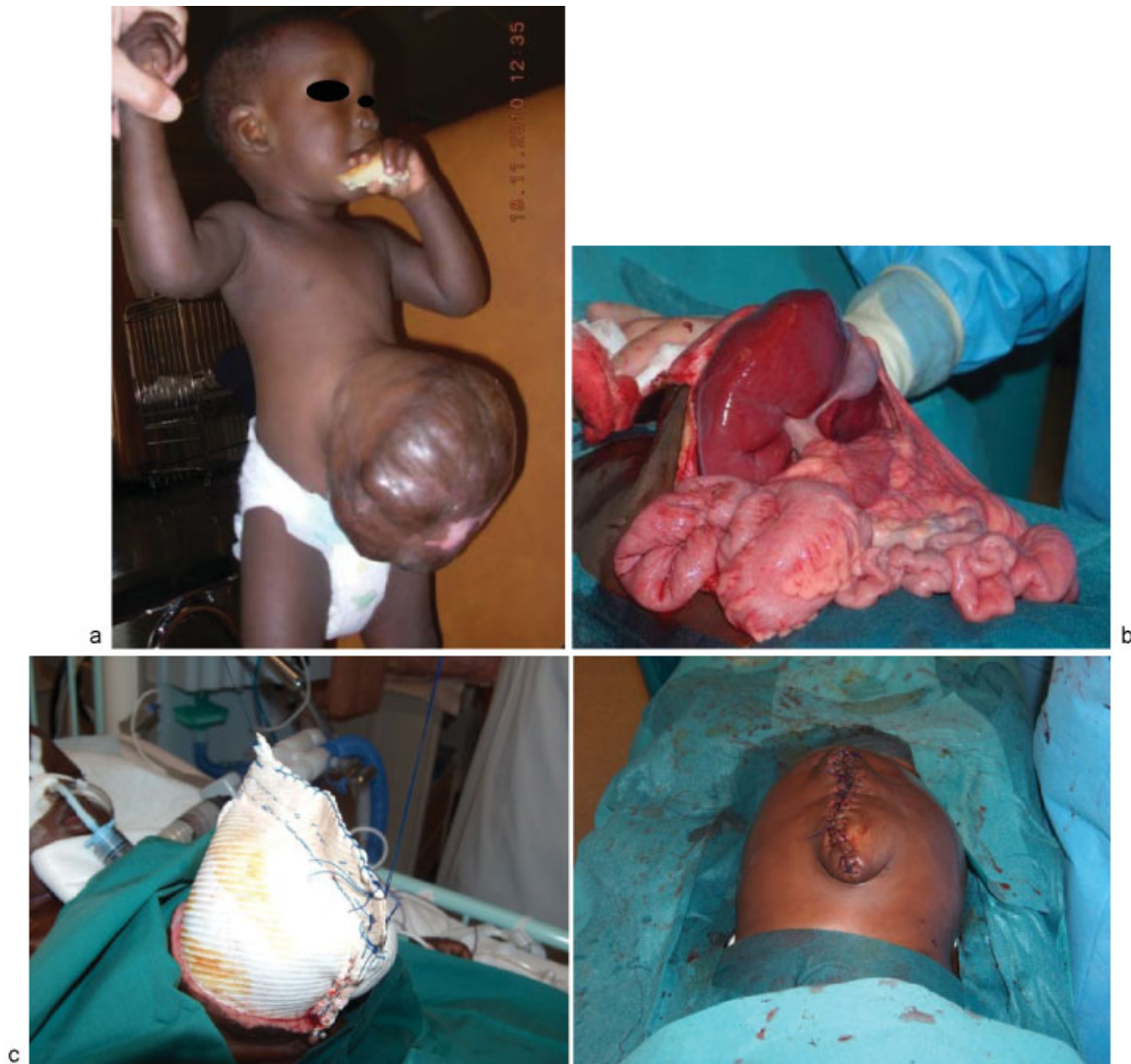

Fig. 1 Steps of ventral hernia correction in patient 5. (A) Preoperative aspects of giant omphalocele (GO). (B) Peroperative aspect: GO content and GO closure using the Schuster technique. (C) Gradual plication and final closure of ventral hernia.

Complication rates were low. The age of the child at the time of reconstructive surgery does not seem to be an important criterion for complications and safety. Nevertheless, the delayed closure of a GO is challenging, and this type of surgery in West Africa seemed not to be feasible.

GO treatment is still controversial and quite challenging. Primary fascial closure in the case of a GO may be problematic because of the undercapacity of the abdominal cavity.^{18,19} The visceral reintegration could lead to several life-threatening complications such as respiratory or cardiac failure, in addition to digestive ischemia and liver or renal insufficiency.^{9,19} In this case, the patient needs either intensive care with intubation, or a new operation applying a surgical alternative, for instance, the use of the Schuster bag. Nowhere did we find any clues for measuring the risk of surgical reopening.

Operating a GO in West Africa may lead to postoperative difficulties and is therefore very risky. Survival may be compromised. We only had five patients, and yet three of them needed intensive care after abdominal closure. According to different studies, children may spend long time in the ICU because of the prolonged need for ventilation (3–71 days) with a high risk of sepsis.^{20,21} Such a strategy is not applicable in West African hospitals because of local conditions.

Local complications such as wound dehiscence and infection are also to be considered.^{10,19}

Conservative treatment (delayed closure) consists in initial nonsurgical management of the GO sac followed by a delayed closure of the ventral hernia.²² Topical epithelialization of the GO is one of the main conservative approaches. Alcohol was the first topical agent used by Ahlfeld in 1899. Then, in 1987, Hatch and Baxter reported two successful cases using silver sulfadiazine with delayed closure at 9 months.²³ Several topical agents were used to promote escharification and epithelialization of the omphalocele sac, including silver nitrate or sulfadiazine, mercurochrome, and povidone-iodine. Silver sulfadiazine seems to be the most used agent for primary epithelialization.²

Another procedure for the management of GO consists of the use of a silo bag for gradual reduction.²⁴ But the placement of a silo may sometimes be technically difficult and needs to be done under general anesthesia. The risk of infection and/or dislodgement must be taken into account.

In our study, the use of a prosthetic implant was needed in patient 5 who had undergone five operations for the implementation, change, and removal of the patch. He is the patient who had the most postoperative complications, including oliguria, respiratory distress with 41 days of mechanical ventilation, patch exposure, and wound infection.

Direct abdominal wall closure was performed in the remaining four patients. However, two of them needed to be treated in the ICU, and one had to be intubated for several days. Their evolution was uneventful, without cardiopulmonary compromise and a relatively short hospital stay (12–19 days). In the group treated by Pereira et al, 18% needed admission to the ICU postoperatively.¹⁹

There is controversy regarding the best age for surgical correction of a ventral hernia. Available studies suggest a time ranging from 6 months to 2 years.^{19,24} In our experience, it is approximately 23 months, which also depended on the time at which West African patients are referred to us. No recurrence of the hernia was observed during our modest follow-up. Neither was any mortality reported. This is comparable to the results reported in the literature.²⁴

Conflict of Interest

None.

References

- Pelizzo G, Maso G, Dell'Oste C, et al. Giant omphaloceles with a small abdominal defect: prenatal diagnosis and neonatal management. *Ultrasound Obstet Gynecol* 2005;26(07):786–788
- Adam AS, Corbally MT, Fitzgerald RJ. Evaluation of conservative therapy for exomphalos. *Surg Gynecol Obstet* 1991;172(05):394–396
- Kamata S, Ishikawa S, Usui N, et al. Prenatal diagnosis of abdominal wall defects and their prognosis. *J Pediatr Surg* 1996;31(02):267–271
- David KM, Robert SS, Stringer MD, et al. Abdominal Wall Defects Pediatric Surgery and Urology: Long Term Outcomes. W.B. Saunders: London; 1998:243–56
- Mann S, Blinman TA, Douglas Wilson R. Prenatal and postnatal management of omphalocele. *Prenat Diagn* 2008;28(07):626–632
- Ali Nawaz Khan NT Sumaira Mac Donald. Omphalocele. *Medicine medscape com website*; 2008
- Kumar HR, Jester AL, Ladd AP. Impact of omphalocele size on associated conditions. *J Pediatr Surg* 2008;43(12):2216–2219
- Robinson JN, Abuhamad AZ. Abdominal wall and umbilical cord anomalies. *Clin Perinatol* 2000;27(04):947–978
- Lee SL, Beyer TD, Kim SS, et al. Initial nonoperative management and delayed closure for treatment of giant omphaloceles. *J Pediatr Surg* 2006;41(11):1846–1849
- Tsakayannis DE, Zurakowski D, Lillehei CW. Respiratory insufficiency at birth: a predictor of mortality for infants with omphalocele. *J Pediatr Surg* 1996;31(08):1088–1090, discussion 1090–1091
- Campos BA, Tatsuo ES, Miranda ME. Omphalocele: how big does it have to be a giant one? *J Pediatr Surg* 2009;44(07):1474–1475, author reply 1475
- Festen C, Severijnen RS, vd Staak FH. Nonsurgical (conservative) treatment of giant omphalocele. A report of 10 cases. *Clin Pediatr (Phila)* 1987;26(01):35–39
- Mehrabi V, Mehrabi A, Kadivar M, Soleimani M, Fallahi A, Khalilzadeh N. Staged repair of giant recurrent omphalocele and gastroschisis “Camel-Litter method”—a new technique. *Acta Med Iran* 2012;50(06):388–394
- de Buys Roessingh AS, Dolci M, Zbinden-Trichet C, Bossou R, Meyrat BJ, Hohlfeld J. Success and failure for children born with facial clefts in Africa: a 15-year follow-up. *World J Surg* 2012;36(08):1963–1969
- Gross RE. A new method for surgical treatment of large omphaloceles. *Surgery* 1948;24(02):277–292
- Minkes RK, Oldham KT, Colombani PM, et al. Abdominal wall defects. In: *Principles and Practice of Pediatric Surgery*. Philadelphia, PA: Lippincott Williams & Wilkins; 2005:1103–1119
- Schuster SR. A new method for the staged repair of large omphaloceles. *Surg Gynecol Obstet* 1967;125(04):837–850

- 18 Geissler GH. Abdominal wall defects. Arensman RM, Bambini DA, Almond PS. *Pediatric Surgery*. Georgetown, TX: Landes Bioscience; 2000:361–365
- 19 Pereira RM, Tatsuo ES, Simões e Silva AC, et al. New method of surgical delayed closure of giant omphaloceles: Lazaro da Silva's technique. *J Pediatr Surg* 2004;39(07):1111–1115
- 20 Mitanchez D, Walter-Nicolet E, Humblot A, Rousseau V, Revillon Y, Hubert P. Neonatal care in patients with giant omphalocele: arduous management but favorable outcomes. *J Pediatr Surg* 2010;45(08):1727–1733
- 21 Barlow B, Cooper A, Gandhi R, Niemirska M. External silo reduction of the unruptured giant omphalocele. *J Pediatr Surg* 1987;22(01):75–76
- 22 Tran DA, Truong QD, Nguyen MT. Topical application of povidone-iodine solution (Betadine) in the management of giant omphaloceles. *Dermatology* 2006;212(Suppl 1):88–90
- 23 Hatch El Jr, Baxter R. Surgical options in the management of large omphaloceles. *Am J Surg* 1987;153(05):449–452
- 24 van Eijck FC, Aronson DA, Hoogveen YL, Wijnen RM. Past and current surgical treatment of giant omphalocele: outcome of a questionnaire sent to authors. *J Pediatr Surg* 2011;46(03):482–488