Double-Level Vascularized Lymph Node Transfer for Treatment of Extremity Lymphedema

Michelle R. Coriddi, MD[1] Daniel S. Eiferman, MD[2] Roman Skoracki, MD, FRCSC, FACS[1]

[1] Department of Plastic Surgery, The Ohio State University, Columbus, Ohio
[2] Department of General Surgery, The Ohio State University, Columbus, Ohio

Address for correspondence Roman Skoracki, MD, FRCSC, FACS, Department of Plastic Surgery, The Ohio State University, 915 Olentangy River Road, Suite 2100, Columbus, OH 43212 (e-mail: roman.skoracki@osumc.edu).

J Reconstr Microsurg Open 2017;2:e75–e77.

Surgical treatments for lymphedema, such as vascularized lymph node transfer, are becoming more popular. Reported donor sites include the groin, axilla, submentum, supraclavicular, omental, and recently described, the jejunal mesentery.[1–20] Improvements in lymphedema following vascularized lymph node transfer have varied greatly. Placement of the vascularized lymph node can be either proximal or distal on the extremity. Literature has shown improvements in lymphedema regardless of recipient site; however, some suggest that the benefit may be greater when placed distally.[8] Others believe that release of scar tissue in the axilla or groin prior to inset of the vascularized lymph node contributes greatly to the effectiveness of the procedure.

Here, we describe an innovative combination of these techniques: jejunal mesenteric vascularized lymph node transfer to the distal wrist and scar release/excision with free omental flap to the axilla. Additionally, we propose a scar scale to categorize scarring of the previously dissected nodal basin.

The jejunal mesenteric lymph node transfer is performed as previously described to the distal wrist.[17] Briefly, the flap is harvested through a midline mini-laparotomy, supraumbilical incision approximately 5 cm in length. The jejunum is delivered through the incision and run proximally toward the ligament of Trietz. A cluster of lymph nodes in the proximal jejunal mesentery with an appropriately sized artery and vein is identified by transillumination and palpation. The flap is raised with the cluster of lymph nodes and mesenteric vascular pedicle en bloc while preserving bowel continuity. The flap is anastomosed to the distal wrist, typically in an end-to-side fashion to the radial artery and end-to-end fashion to the radial vein or cephalic vein. Inset is performed by removing subcutaneous tissue, creating a pocket for the flap. Primary closure is usually obtained (►**Fig. 1**). A full-thickness skin graft can be harvested as an ellipse adjacent to the abdominal incision and used if primary closure cannot be obtained. Flap monitoring can be achieved by an implantable doppler crystal inserted directly into the flap or percutaneously with a hand-held doppler.

Attention is then turned to the axilla where the area of scar is released and excised. This usually includes a careful dissection of the axillary vein, which is often encased in scar and may be narrowed by scar bands. We then utilize the open abdomen

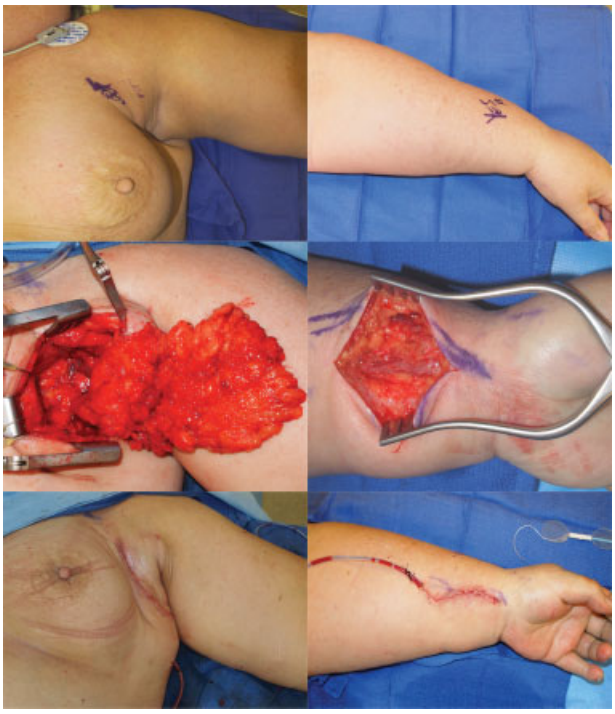

Fig. 1 Double-level vascularized lymph node transfer. Photographs of standard patient before surgical intervention (top), after anastomosis of the omental flap to the axillary vessels (left center) and jejunal mesenteric lymph node flap to the wrist (right center), and after inset and closure (bottom).

received
April 11, 2017
accepted after revision
May 25, 2017

DOI https://doi.org/10.1055/s-0037-1604156.
ISSN 2377-0813.

Copyright © 2017 by Thieme Medical Publishers, Inc., 333 Seventh Avenue, New York, NY 10001, USA. Tel: +1(212) 584-4662.

License terms

Table 1 The Ohio scar scale (for axillary or inguinal node dissections)

Grade	Description
0	No scar, no surgical intervention to area
1	Superficial scar, mobile (no tethering, adequate subcutaneous fat layer)
2	Scar extending into subdermal structures, deep palpable scar, remains mobile against deeper structures (i.e., chest wall, groin, fascia/musculature)
3	Visible tethering of skin, scar tethering skin to underlying deeper structure (i.e., chest wall, deep fascia of the groin), scar is usually depressed/dimpling
4	Painful tethered scar

from the harvest of the vascularized jejunal lymph node transfer to harvest a portion of the omentum for placement into the axilla. The omentum is examined to determine if the right or left gastroepiploic artery and vein would provide a better pedicle and identify the position of any nodes, which are usually located along the greater curvature of the stomach. Once this decision is made, the omentum adjacent to the pedicle is dissected free from the transverse colon, stomach, and remaining omentum. The harvested omentum generally measures 10 × 20 cm. The gastroepiploic artery and vein are then anastomosed in an end-to-end fashion to previously prepared vessels on the lateral chest wall. These vessels are generally the lateral thoracic or the serratus branch of the thoracodorsal. The omental flap is inset to fill the dead space created by scar release and excision (►**Fig. 1**).

The postoperative course includes elevation and abduction of the upper extremity for 1 week. Patients are slowly progressed to full range of motion. Clear liquid diet is initiated immediately postoperatively and the diet is advanced as tolerated on postoperative day 1. To date, five patients have received double lymph node transfers. Preliminary results are promising and will be reported once adequate follow-up (greater than 1 year) has been achieved.

By using the abdomen as a donor site for vascularized lymph node transfer, we are able to harvest both a jejunal mesenteric vascularized lymph node and omental flap simultaneously. Therefore, we can gain the benefits of both a distal node placement on the extremity, axillary/groin scar release, and proximal vascularized node flap inset to assist with lymphangiogenesis. Placing the omental flap in the axilla/groin fills the dead space and prevents rescarring of the axilla. Using the jejunal mesenteric vascularized lymph node at the wrist allows for a primary closure in most cases as this flap is small. Additional benefits of using the abdomen as a donor site include decreased risk for donor site lymphedema, reliable vascular anatomy, and well-concealed scar.

As surgical treatments for lymphedema become more popular, it is essential to determine the efficacy of these procedures and establish criteria to select the proper procedure for the patient. To create these criteria, it is necessary to have standard definitions that outline the factors contributing to the development of lymphedema. Factors such as radiation and lymph node dissection are objectively reported. However, axillary scarring does not have an objective measurement tool. To our knowledge, there is no metric to describe severity of scarring after cancer-related treatments. In the absence of a specific instrument, we propose the Ohio State scar scale as a simple and descriptive tool for use in diagnosing and communicating the degree of scarring after lymph node removal (►**Table 1**).

We believe the double-level vascularized lymph node transfer, the distal placement of the jejunal mesenteric lymph node flap and simultaneous axillary scar release with omental flap placement, maximizes benefits for patients. Using the abdomen as a donor site allows for harvest of more than one flap and has a decreased risk of donor site lymphedema. Using the Ohio scar scale will assist in clarifying the degree of scarring due to cancer-related treatments, which is useful when reporting outcomes of lymphedema surgery.

Conflict of Interest
None.

References

1 Raju A, Chang DW. Vascularized lymph node transfer for treatment of lymphedema: a comprehensive literature review. Ann Surg 2015;261(05):1013–1023
2 Becker C, Vasile JV, Levine JL, et al. Microlymphatic surgery for the treatment of iatrogenic lymphedema. Clin Plast Surg 2012; 39(04):385–398
3 Cormier JN, Rourke L, Crosby M, Chang D, Armer J. The surgical treatment of lymphedema: a systematic review of the contemporary literature (2004-2010). Ann Surg Oncol 2012;19(02):642–651
4 Lin CH, Ali R, Chen SC, et al. Vascularized groin lymph node transfer using the wrist as a recipient site for management of postmastectomy upper extremity lymphedema. Plast Reconstr Surg 2009;123(04):1265–1275
5 Saaristo AM, Niemi TS, Viitanen TP, Tervala TV, Hartiala P, Suominen EA. Microvascular breast reconstruction and lymph node transfer for postmastectomy lymphedema patients. Ann Surg 2012;255(03):468–473
6 Becker C, Assouad J, Riquet M, Hidden G. Postmastectomy lymphedema: long-term results following microsurgical lymph node transplantation. Ann Surg 2006;243(03):313–315
7 Gharb BB, Rampazzo A, Spanio di Spilimbergo S, Xu ES, Chung KP, Chen HC. Vascularized lymph node transfer based on the hilar perforators improves the outcome in upper limb lymphedema. Ann Plast Surg 2011;67(06):589–593
8 Cheng MH, Chen SC, Henry SL, Tan BK, Lin MC, Huang JJ. Vascularized groin lymph node flap transfer for postmastectomy upper limb lymphedema: flap anatomy, recipient sites, and outcomes. Plast Reconstr Surg 2013;131(06):1286–1298

9 Dancey A, Nassimizadeh A, Nassimizadeh M, Warner RM, Waters R. A chimeric vascularised groin lymph node flap and DIEP flap for the management of lymphoedema secondary to breast cancer. J Plast Reconstr Aesthet Surg 2013;66(05):735–737
10 Cheng MH, Huang JJ, Nguyen DH, et al. A novel approach to the treatment of lower extremity lymphedema by transferring a vascularized submental lymph node flap to the ankle. Gynecol Oncol 2012;126(01):93–98
11 Viitanen TP, Mäki MT, Seppänen MP, Suominen EA, Saaristo AM. Donor-site lymphatic function after microvascular lymph node transfer. Plast Reconstr Surg 2012;130(06):1246–1253
12 Althubaiti GA, Crosby MA, Chang DW. Vascularized supraclavicular lymph node transfer for lower extremity lymphedema treatment. Plast Reconstr Surg 2013;131(01):133e–135e
13 Sapountzis S, Singhal D, Rashid A, Ciudad P, Meo D, Chen HC. Lymph node flap based on the right transverse cervical artery as a donor site for lymph node transfer. Ann Plast Surg 2014;73(04):398–401
14 Vignes S, Blanchard M, Yannoutsos A, Arrault M. Complications of autologous lymph-node transplantation for limb lymphoedema. Eur J Vasc Endovasc Surg 2013;45(05):516–520
15 Pons G, Masia J, Loschi P, Nardulli ML, Duch J. A case of donor-site lymphoedema after lymph node-superficial circumflex iliac artery perforator flap transfer. J Plast Reconstr Aesthet Surg 2014;67(01):119–123
16 Tourani SS, Taylor GI, Ashton MW. Vascularized lymph node transfer: a review of the current evidence. Plast Reconstr Surg 2016;137(03):985–993
17 Coriddi M, Skoracki R, Eiferman D. Vascularized jejunal mesenteric lymph node transfer for treatment of extremity lymphedema. Microsurgery 2017;37(02):177–178
18 Ciudad P, Kiranantawat K, Sapountzis S, et al. Right gastroepiploic lymph node flap. Microsurgery 2015;35(06):496–497
19 Mardonado AA, Chen R, Chang DW. The use of supraclavicular free flap with vascularized lymph node transfer for treatment of lymphedema: A prospective study of 100 consecutive cases. J Surg Oncol 2017;115(01):68–71
20 Scaglioni MF, Arvanitakis M, Chen YC, Giovanoli P, Chia-Shen Yang J, Chang EI. Comprehensive review of vascularized lymph node transfers for lymphedema: Outcomes and complications. Microsurgery 2016. Doi: 10.1002/micr.30079