

Intramedullary Dermoid Cyst of the Cervical Spinal Cord – C5–C7 Level

Cisto dermoide intermedular da medula espinhal cervical – nível C5–C7

Palanisamy Seerangan¹ Aravinth Kumar Ashok¹ Jolarpettai Venugopal Mahendran¹

¹Institute of Neurosurgery, Madras Medical College, Chennai, Tamil Nadu, India

Arq Bras Neurocir 2018;37:140–144.

Address for correspondence Jolarpettai Venugopal Mahendran, PhD, Institute of Neurosurgery, Madras Medical College, Park Town, Chennai, Tamil Nadu 600003, India (e-mail: mahendranvenugopal@gmail.com).

Abstract

Introduction Inclusion cysts of the spinal cord are rarely intramedullary. Such cysts are commonly located in the lumbar and thoracic regions and are usually associated with congenital spinal dysraphism and dermal sinus. Intramedullary dermoid cysts in the cervical region without spinal dysraphism are extremely rare. To our knowledge, only seven such cases are reported in the literature to date.

Materials and Methods An 18-year-old female patient presented with weakness in all four limbs, more distal than proximal muscle weakness, that had been progressing for 3 years. The magnetic resonance imaging (MRI) showed an intramedullary lesion from C5–C7 with peripheral ring enhancement. “Whorls” were observed within the lesion on T2 weighted image, with associated excavation of vertebral bodies C5–C7. Operative procedure and findings: partial laminectomy of C5–D1 was performed. The dura was opened. A small myelotomy was made in the root entry zone. About 1.5 ml of yellowish colored fluid was drained. White shiny debris with hair, whitish pultaceous content and teeth were removed. Complete excision of cyst and its wall was performed.

Results The histopathological examination revealed that the cyst wall was lined by stratified squamous epithelium with underlying dermis showing hair follicles, sebaceous glands, adipose tissue and cyst filled with keratin debris suggestive of dermoid cyst.

Conclusion The intramedullary location of the dermoid cyst in the cervical cord and the absence of any congenital spinal dysraphism make this case a very unique and rare entity and warrants its inclusion in the reported cases of rare intramedullary space occupying lesions.

Keywords

- ▶ intramedullary dermoid cyst
- ▶ cervical spinal cord
- ▶ rare presentation
- ▶ absence of spinal dysraphism

Resumo

Introdução Cistos de inclusão da medula espinhal raramente são intramedulares. Tais cistos são comumente localizados nas regiões lombares e torácicas e geralmente estão associados com disrafismo espinhal congênito e sinus dérmico. Cistos dermóides intramedulares na região cervical sem a presença de disrafismo espinhal são extremamente raros. Apenas sete casos foram relatados na literatura até a data do presente estudo.

received
November 23, 2017
accepted
January 5, 2018
published online
March 27, 2018

DOI <https://doi.org/10.1055/s-0038-1639605>.
ISSN 0103-5355.

Copyright © 2018 by Thieme Revinter Publicações Ltda, Rio de Janeiro, Brazil

License terms



Materiais e Métodos Uma paciente de 18 anos de idade apresentou fraqueza nos quatro membros, mais distal que proximal, com três anos progressivos de duração. A ressonância magnética apresentou uma lesão intramedular de C5 a C7 com realce do anel periférico. Espirais foram observadas dentro da lesão na imagem ponderada em T2, com escavação dos corpos vertebrais C5–C7. Procedimentos operatórios e achados: realização de laminectomia parcial de C5 a D1. A dura cervical foi aberta. Uma pequena mielotomia foi feita na zona de entrada da raiz. Cerca de 1,5 ml de fluido amarelado foi extraído. Detritos brancos brilhantes com cabelo, polpa esbranquiçada e dentes foram removidos. Foi realizada a excisão completa do cisto com parede de cisto.

Palavras-chave

- ▶ cisto dermoide intramedular
- ▶ cordão cervical medular
- ▶ apresentação rara
- ▶ ausência de disrafia espinhal

Resultados O exame histopatológico revelou que a parede do cisto estava alinhada por epitélio escamoso estratificado com derme subjacente apresentando folículos capilares, glândulas sebáceas, tecido adiposo e cisto cheio de detritos de creatinina, sugerindo cisto dermoide.

Conclusão A posição intramedular do cisto dermoide no cordão cervical e a ausência de disrafismo espinhal congênito faz deste um caso único, uma entidade rara, e assegura sua inclusão junto aos casos relatados de lesões raras ocupando espaço intramedulares.

Introduction

Inclusion cysts of the spinal cord are rarely intramedullary, with only a few cases having been reported in the literature. Intraspinal dermoid cysts are commonly located in the lumbar and thoracic regions and are usually associated with congenital spinal dysraphism and dermal sinus. Intramedullary dermoid cyst in the cervical region without spinal dysraphism (▶ Fig. 1) is extremely rare, with only seven cases being reported in the literature to date. We report a case of an intramedullary dermoid cyst in the cervical cord of an 18-year-old female patient.

Presentation

Our patient was an 18-year-old female, who presented with gradual progressive weakness of muscles of both upper limbs and both lower limbs, weakness of the distal limb muscles, more than the proximal muscle group, ongoing for 3 years in the form of difficulty in holding objects, mixing food, and difficulty in walking, climbing, squatting on the floor, etc.

Upon examination, power in the upper limbs was ⅓ on the right side and ⅔ on the left side with weakness of hand grip (right-20%, left-30%). In the upper limbs, the triceps and supinator reflexes were absent. The power in both lower limbs was ⅔ and with spasticity, and the patient was able to walk with difficulty. The plantar reflex was extensor bilaterally, with exaggerated ankle and knee jerks and the patient also sustained clonus of both ankles. There were no sensory changes in the upper and lower limbs, or in the rest of the body.

The MRI of the cervical spine with contrast study showed widening of the cervical spinal cord from C5–C7 (▶ Fig. 2). An intramedullary space occupying lesion was present, which was hypo intense on T1 weighted images, hyper intense on T2 weighted images, and with peripheral ring enhancement on contrast study. Also, “whorls” were seen within the lesion on

T2 weighted images (▶ Fig. 3). There was associated excavation of the cervical vertebral bodies in the C5–C7 levels.

Operative Technique

The patient was operated under general anesthesia in prone position. An intraoperative injection of methyl-prednisolone was given and continued in the postoperative period for 23 hours at a dose of 30 mg/kg bolus over 1 hour followed by 5.4 mg/kg/hr for 23 hours. A midline incision extending from just below C2–D1 was made. The paraspinal muscles were retracted laterally by sub periosteal dissection. A partial laminectomy of C5, C6, C7 and D1 was performed.

After laminectomy, the cervical dura was found to be bulging and enlarged. The dura was opened in the midline and retracted by stay sutures. The cord was enlarged, and a low-grade torsion was noted. A small myelotomy was made in the root entry zone, initially. About 1 to 1.5 ml of yellowish colored fluid was drained. The myelotomy was subsequently extended rostrally and caudally. White shiny debris with hair (▶ Fig. 4) was removed. Whitish pultaceous contents mixed with hair and teeth (▶ Fig. 5) were removed. Complete excision of cyst along with the cyst wall was performed. The myelotomy was left open. The dura was closed with 6-0 Prolene. The muscles and skin were subsequently closed with absorbable stitches. Recovery from anesthesia was uneventful.

Results

Immediately after the surgery, the patient's power in the lower limbs was ⅔ and ⅔ in the upper limbs. There was no respiratory distress. Over a period of 3 days, the power improved to ⅔ in the lower limbs and ⅔ in the upper limbs. The catheter was removed on the 10th postoperative day, and the patient was able to void urine naturally without any bladder dysfunction. Bowel movements were normal, and

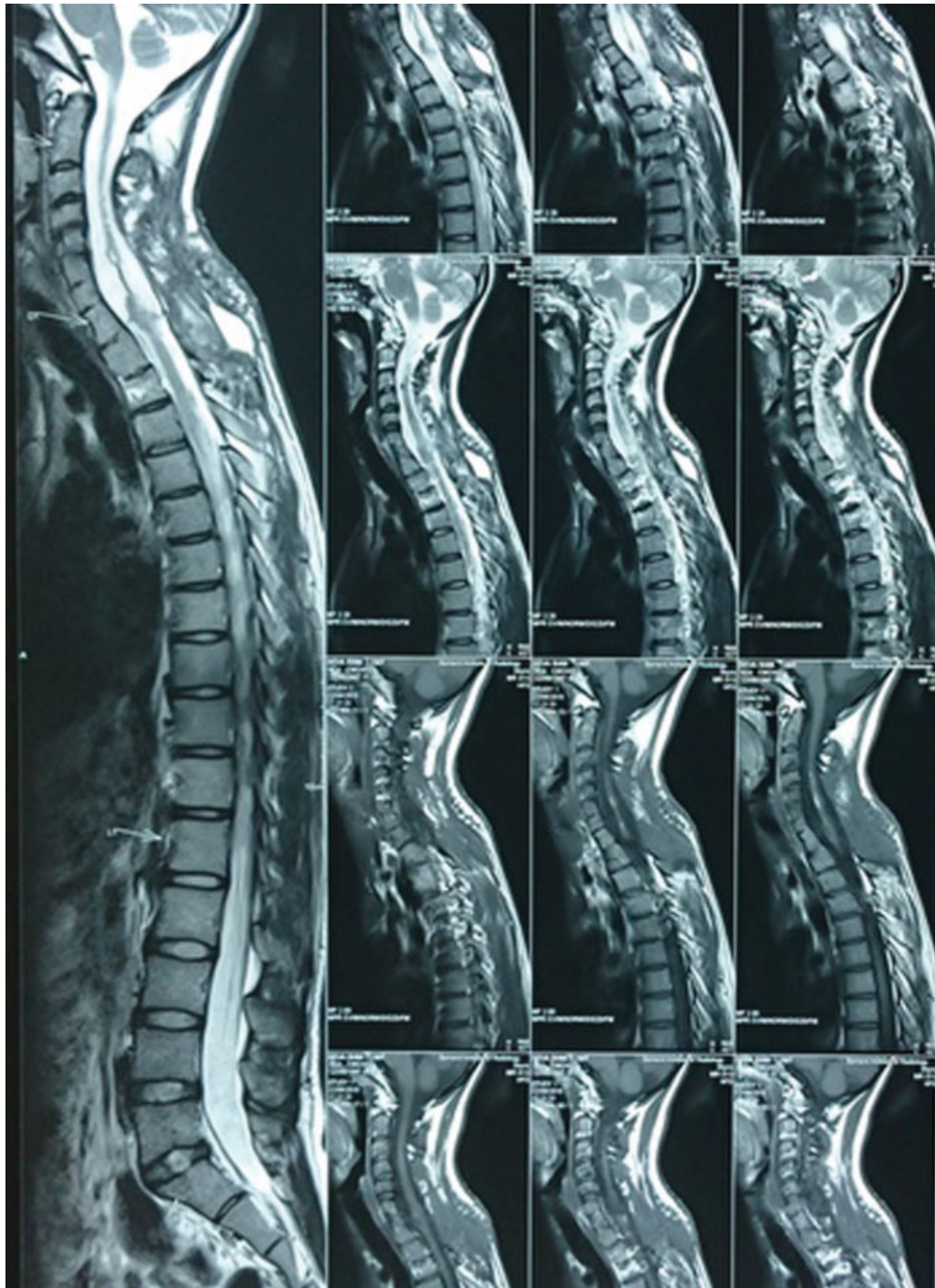


Fig. 1 Intramedullary dermoid cyst at C5–C7 level without spinal dysraphism.

there was no incontinence of feces. The patient was able to walk with support on the 10th postoperative day. The wound healed well, and the stitches were removed on the 14th postoperative day, after which the patient was discharged.

Histopathology

The sections show that the cyst wall was lined by stratified squamous epithelium with underlying dermis showing hair follicles, sebaceous glands, adipose tissue and cyst filled with keratin debris (► **Fig. 6**).

Discussion

The common locations of dermoid cysts are:

1. Scalp (angle of eye and retro mastoid region)
2. Skull bones (intradiploic)
3. Intracranial, in the suprasellar region and posterior fossa
4. Intraspinal, mainly intradural, and associated with other spine defects.

The dermoid cysts are a developmental abnormality and arise from the nests of embryonic ectoderm that get buried

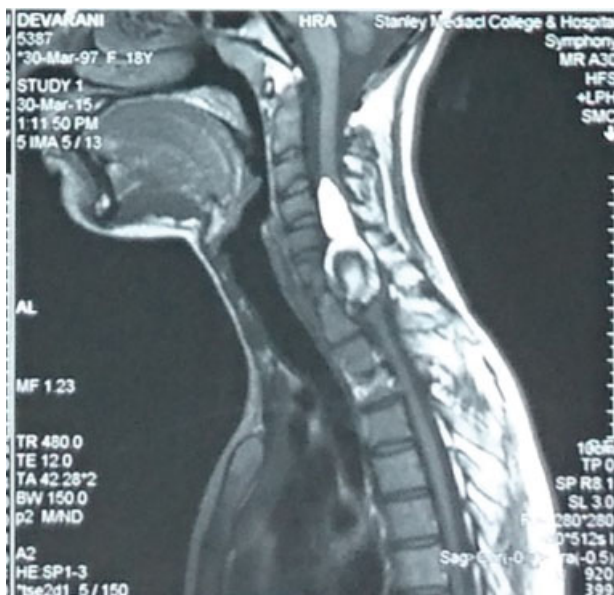

Fig. 2 T1-weighted magnetic resonance imaging focusing on intramedullary dermoid cyst at C5–C7 level.

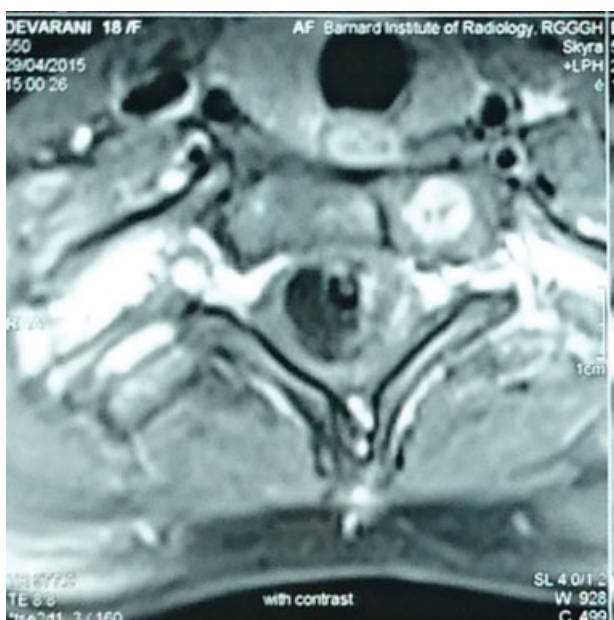


Fig. 3 Whorls seen on T2-weighted magnetic resonance imaging.

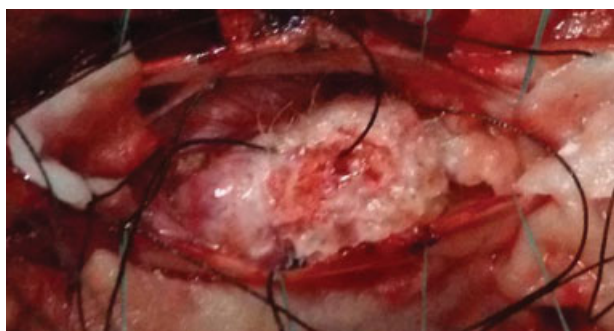


Fig. 4 Intraoperative picture of dermoid cyst.

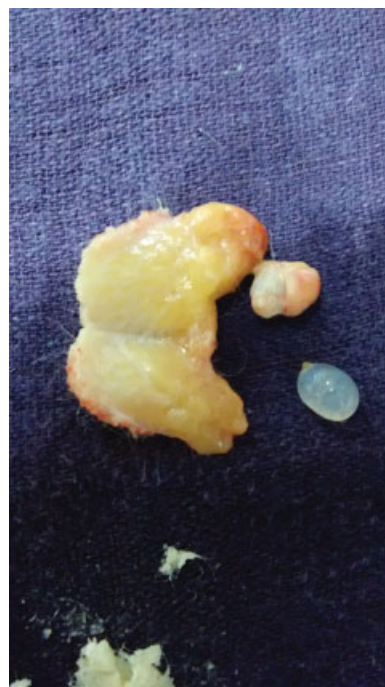

Fig. 5 Macroscopic image of the excised specimen showing its ectodermal derivatives.

or trapped under the lines of fusion of the ectodermal folds in the developing embryo.^{1,2}

It is well known that the nervous system develops from the ectoderm. The cells on the dorsal aspect of the developing embryo thicken to form the neural plate or placode along the axis of the embryo. The neural plate bends and closes to form a tube called the neural tube, from which the entire nervous system develops. The neural tube closes in the dorsal midline first, and the closure then extends cranially and caudally so that the anterior neuropore closes at 24 days and the posterior neuropore at 28 days. Thus, as the neural tube closes last in the caudal part, that is the lumbo-sacral region, there is a bigger chance that this process may be disturbed, and nests of cutaneous tissue may get trapped within the developing tube, giving rise to dermoid cysts. Hence, the propensity for the dermoid cyst to occur in the lumbosacral region.

Also, dermoid cysts are commonly associated with spinal dysraphism. This is because the process that gives rise to spinal dysraphism is also responsible for the development of the dermoid cyst.^{3,4} The low incidence of dermoid cysts in the cervical region is likely related to the embryological process of neural tube closure, which begins in the area of the neural tube destined to become the lower cervical cord and proceeds rostrally and caudally.

Spinal inclusion cysts are usually intradural, intramedullary in the cervical spinal cord region, with the other common lesions being neuroenteric cysts, arachnoid cysts, epidermoid and dermoid cysts.^{1,2}

Dermoid cysts usually present themselves in childhood, as a consequence of associated anomalies or by symptoms of cord tethering and mass effects. However, in this case, the patient had no associated developmental anomaly of the

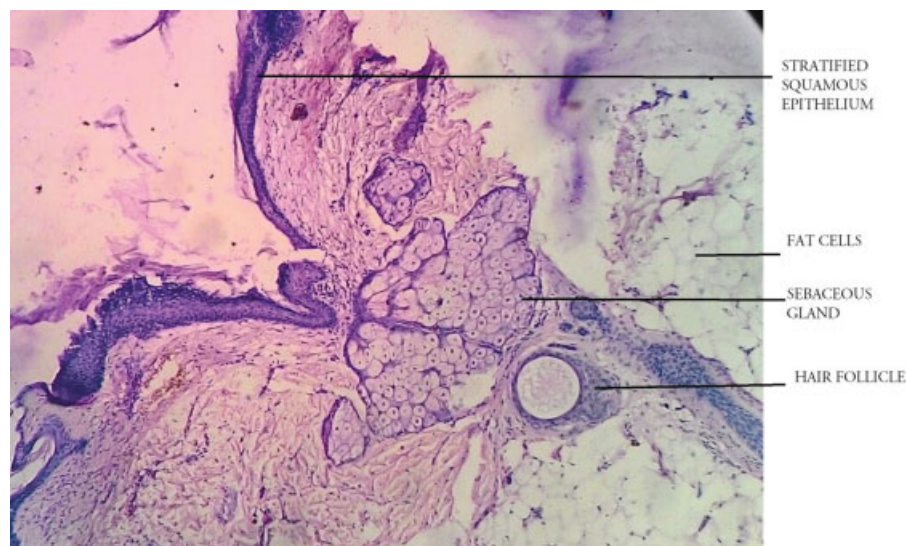


Fig. 6 Histopathology slide

spine. Because of the absence of any other congenital anomaly of the spine, the patient presented at a later age, after she had developed significant symptoms, particularly in the left side of the body. Total excision of the dermoid cyst was performed by standard micro neurosurgical technique employed for other intramedullary tumors.

We could find three other cases⁵⁻⁸ in which a dermoid cyst was in the cervical cord and was not associated with any other congenital anomalies of the spine. In other reported cases,^{6,7,9} the location of the dermoid cyst and the presence or absence of congenital anomaly of the spine were not clear as they were dated before the advent of MRI. Hence, it is difficult to ascertain whether these cases represent the "true" intramedullary dermoid cyst or are part of a developmental defect.

Conclusion

The intramedullary location of the dermoid cyst in the cervical cord and the absence of any congenital spinal dysraphism make this case a very unique and rare entity and add to the reported cases of rare intramedullary space occupying lesions.

Conflict of Interest

Authors declare no conflicts of interest.

References

- 1 Shubha AM, Mohanty S, Das K, Garg I. Congenital inclusion tumours in spinal dysraphism. *Indian J Pediatr* 2010;77(02):167-170
- 2 Ogden AT, Khandji AG, McCormick PC, Kaiser MG. Intramedullary inclusion cysts of the cervicothoracic junction. Report of two cases in adults and review of the literature. *J Neurosurg Spine* 2007;7(02):236-242
- 3 Bourhis LE. [Intramedullary dermoid cyst]. *Rev Neurol (Paris)* 1952; 86(04):339-340
- 4 Buur T, Mørch MM. [Intramedullary dermoid cyst]. *Ugeskr Laeger* 1981;143(52):3552-3553
- 5 Kumar S, Gupta S, Puri V, Gupta RK, Malik R. Intramedullary dermoids in children. *Indian Pediatr* 1990;27(06):626-629
- 6 Najjar MW, Kusske JA, Hasso AN. Dorsal intramedullary dermoids. *Neurosurg Rev* 2005;28(04):320-325
- 7 Sharma NC, Chandra T, Sharma A, Bajaj M, Kundu R. Long-segment intramedullary spinal dermoid. *Indian J Radiol Imaging* 2009;19(02):148-150[PMC free article] [PubMed]
- 8 Gagliardi FM, Ferrari G. Su un caso di dermoide intramidollare. *Acta Neurochir (Wien)* 1969;21(02):197-204
- 9 Roth M, Hanák L, Schröder R. [Intramedulární dermoid]. *Cesk Neurol* 1966;29(05):351-354