

Direct Parastomal Percutaneous Embolization for Bleeding Stomal Varices

Manu K. Singh¹ Stuart E. Braverman¹ Steve Hartzman¹ Arthur Lee¹

¹Department of Interventional Radiology, Santa Barbara Cottage Hospital, Santa Barbara, California, United States

Address for correspondence Manu K. Singh, MD, Santa Barbara Cottage Hospital, Santa Barbara, CA, United States (e-mail: manukushsingh@gmail.com).

J Clin Interv Radiol ISVIR 2018;2:126–127

Abstract

A 71-year-old woman with a history of colon cancer and nonalcoholic fatty liver disease presented with lower gastrointestinal (GI) bleeding. Workup revealed cirrhosis with peristomal varices, which was managed successfully with computed tomography (CT)–guided percutaneous parastomal access and subsequent embolization.

Keywords

- ▶ cirrhosis
- ▶ parastomal percutaneous embolization
- ▶ peristomal varices
- ▶ variceal embolization
- ▶ varices

Images in IR

A 71-year-old woman postcolostomy for colorectal cancer 20 years ago presented with multiple hospital admissions for lower gastrointestinal (GI) bleeding. Her medical history was significant for nonalcoholic cirrhosis resulting from fatty infiltration of the liver. After multiple negative colonoscopies, the source of bleeding was suggested at the mucosa of the ostomy site, which was unsuccessfully treated with silver nitrate. A computed tomographic (CT) scan was performed, which demonstrated evidence of cirrhosis with prominent

peristomal varices (▶**Fig. 1A**, arrow) supplied by a large collateral vein (▶**Fig. 1B**, arrow). After review of the diagnostic imaging, it was thought that percutaneous access with CT guidance might allow for optimal access. Under CT guidance, the large collateral vein was identified and accessed with a 21-gauge needle from an anterior approach adjacent to the stoma allowing for guidewire placement (▶**Fig. 2**). The patient was then transferred to the angiography suite. Through a microintroducer sheath, a microcatheter was advanced to the portal venous system. Injection of the accessed collateral

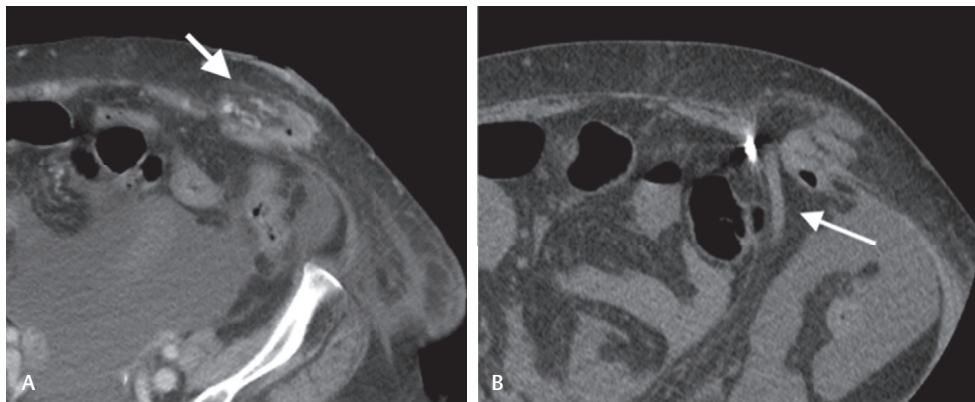


Fig. 1 Stomal varices (**A**, arrow) supplied by a large collateral varix in the left lower quadrant (**B**, arrow).

received
April 28, 2017
accepted after revision
September 27, 2017
published online
June 20, 2018

DOI <https://doi.org/10.1055/s-0038-1641675>.
ISSN 2457-0214.

Copyright ©2018 by Indian Society of Vascular and Interventional Radiology

License terms



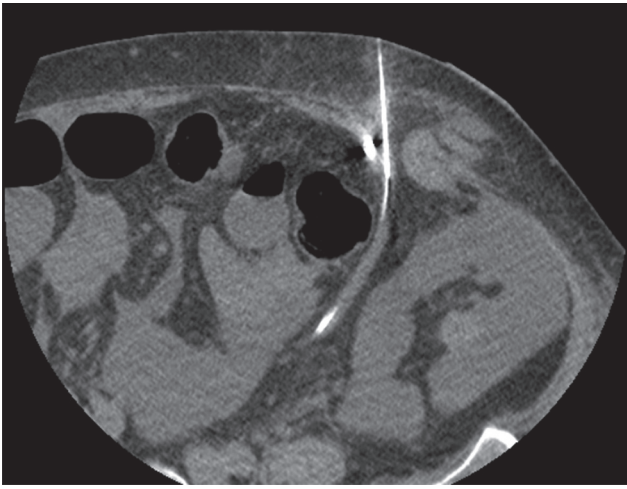


Fig. 2 CT-guided percutaneous access of the large collateral supplying the parastomal varices.

below at its confluence with the splenic vein demonstrated retrograde flow toward the left lower quadrant stoma opacifying peristomal collaterals. Embolization was then performed using microcoils (►**Fig. 3**, arrow), across a channel of tangle of collateral vessels; Gelfoam slurry was then injected in the

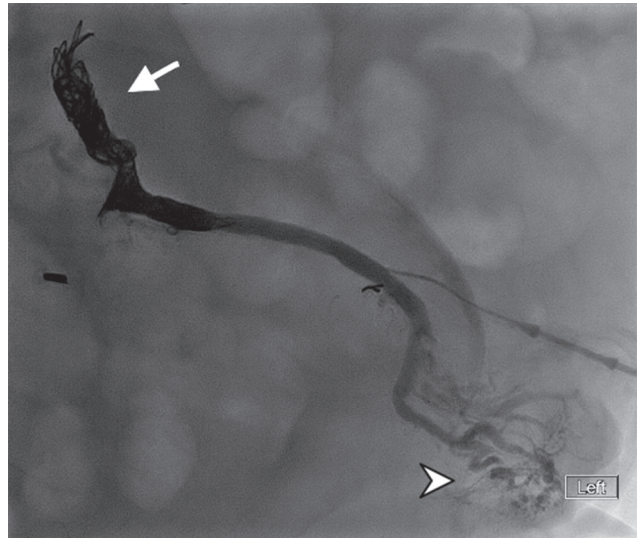

Fig. 3 After coil embolization (arrows), Gelfoam slurry was then injected, which flowed to the peristomal varices (arrowhead).

most peripheral segment with flow to the peristomal varices achieving stasis (►**Fig. 3**, arrowhead). The patient's hemoglobin stabilized and without further episodes of stomal bleeding upon discharge and at 6-week follow-up.