

From Mitten Hand to Five Individual Fingers: One-Stage Coverage Using a Deep Inferior Epigastric Perforator Free Flap for an Extensive Degloving Hand Injury

Min Ji Kim, MD¹ Bo Young Park, MD, PhD²

¹Plastic and Reconstructive Surgery, Asan Medical Center, University of Ulsan College of Medicine, Seoul, Republic of Korea

²Department of Plastic and Reconstructive Surgery, Ewha Womans University Mokdong Hospital, Seoul, South Korea

Address for correspondence Bo Young Park, MD, PhD, Department of Plastic Surgery, Ewha Womans University Mokdong Hospital, 1071 Anyangcheon-ro, Yangcheon-gu, Seoul 07985, Korea (e-mail: byps@icloud.com).

J Reconstr Microsurg Open 2018;3:e28–e31.

Abstract

Keywords

- ▶ deep inferior epigastric perforator flap
- ▶ upper extremity reconstruction
- ▶ degloving injury

Coverage of hands with degloving injuries is currently being investigated, but it typically involves combinations of free flap operations to cover wide dimensions. In this study, the deep inferior epigastric perforator (DIEP) flap was successfully used to salvage a severely injured hand. After performing an open wound coverage with a flap operation, we did several minimal division operations under local anesthesia, which is a logical surgical option when the patient suffers from general deterioration immediately following significant trauma. We believe that this application of DIEP flap allows for a shorter operation time, decreased rates of infection for one-step coverage, and a higher chance of functional digit division compared with conventional methods.

The total degloving injury of the hand is one of the most serious injuries that can be further complicated with severe contamination and crushing of soft tissue or neurovascular structures and is regarded as a condition that requires performing amputation.¹ Although variable treatment options are available for degloving injuries of the hand, reconstruction remains one of the most difficult problems for microsurgeons.

If the injury involves five digits or both sides of hand dorsum and palm, the dimensions of the flap can be inadequate for coverage. In addition, if the territory of the flap needed to envelop the defect is larger than anticipated from preoperative planning, two free flaps are recommended for coverage of complete degloving injuries of the hand.

Even if one free flap and local flaps are combined for coverage, operating times are long, followed by extensive hospitalization periods required for adequate wound healing. However, when these flaps were successfully transferred, interdigitation still remains a difficult procedure.

Therefore, we applied a deep inferior epigastric perforator (DIEP) flap, which is the largest flap usually used for breast reconstruction, to perform a “one-stage coverage of a total degloved hand.” Based on our experience, we will report on satisfactory results after one-stage coverage following separation procedures for severe degloved hand reconstruction.

Case Report

A 53-year-old man was involved in a rolling machine accident and sustained major degloving injuries of the whole hand and digits with exposure of bones and tendons.

Due to severely crushed bony fragments, he had to undergo amputation of his proximal thumb, proximal second finger, proximal third finger, fourth proximal interphalangeal joint, and fifth middle phalangeal joint. After the amputation was performed by the orthopedic team, the patient was left with scrawny digits and a hand that lacked circumferential soft tissue (▶ Fig. 1).

received
September 13, 2017
accepted after revision
March 21, 2018

DOI <https://doi.org/10.1055/s-0038-1649490>.
ISSN 2377-0813.

Copyright © 2018 by Thieme Medical Publishers, Inc., 333 Seventh Avenue, New York, NY 10001, USA.
Tel: +1(212) 584-4662.

License terms



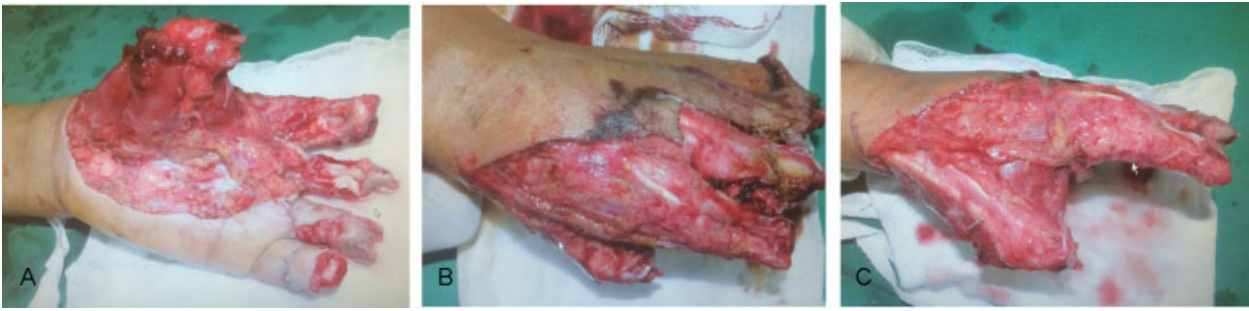

Fig. 1 Preoperative images of the patient who was involved in a rolling machine accident resulting in a degloving injury of volar and dorsal side on his left hand that combined with multiple digit amputations. (A) Volar, (B) dorsal, and (C) radial sides.

Preoperative Consideration

Immediately following the emergency amputations, he was transferred to plastic surgery for wound management. Infection control was the foremost issue for flap operation preparation. Serial debridement resulted in an improved wound bed that allowed for early flap coverage 4 days after trauma. In attempts to prevent the contracture of the remaining thumb, we performed a K-wire digit fixation.

Free Flap Reconstruction: Making a Mitten

The patient presented a near total degloving defect, and thus, vascular tissue was required for reconstruction. The defect measured $\sim 30 \times 13$ cm extending from the volar side to the dorsal area of the hand. A DIEP flap was harvested after customizing a design. At this point, we needed to determine what percentage of the flap to inset to take into account special considerations for anastomosis. Compared with a DIEP flap for breast reconstruction, we needed to involve all areas of the flap, including Hartrampf zone IV, to accommodate additional vascular flow to strengthen the circulation of the flap. One arterial anastomosis was made using an end-to-side technique, and a three-vein anastomosis was made using an end-to-end pattern with three perforators for abundant blood supply.

We created an anastomosis between the deep inferior epigastric artery and the dorsal branch of the radial artery

with multiple venous anastomoses to the dorsal veins (\rightarrow Fig. 2). The abdominal donor site was primarily closed and the flap successfully survived. The patient was discharged from the hospital within 20 days.

Digit Reconstruction with Step-Wise Division Operations

The patient recovered quickly after our one-stage coverage operation. Thus, we could start the second step of our reconstruction: debulking and interdigitation at postoperative 6 weeks. Throughout the 1.5-year follow-up period, the patient underwent a total of seven operations under local anesthesia for debulking and division of digits in an out-patient setting.

First, the patient had to undergo liposuction several times before division. Then, a standard syndactyly hourglass design allowed for the subsequent separation of digits. By using remnant skin from the DIEP, we had to harvest only a minimal amount of additional skin for covering digit defects after division. Initially, after the flap operation, the DIEP flap had enough skin and fatty tissue that allowed us to use it and its bulky portion for pulp reconstruction and division. In the patient's last division operation, we focused on restoring the grasping function of the thumb. Independent finger function with power and length preservation seems to have been satisfactorily achieved, as the patient was able to return to work (\rightarrow Fig. 3).

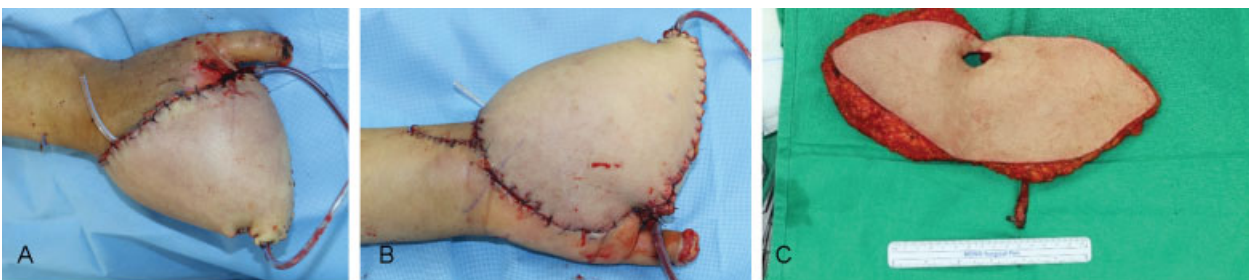


Fig. 2 A 30×13 cm deep inferior epigastric perforator free flap was performed after wide debridement of nonvitalized tissue. Using only one operation, we made mitten first that could fully cover the whole defect. From this coverage, we could prevent infection and also get tolerable general condition for patient. (A) Dorsal side, (B) volar side (C), and a harvested abdominal flap; we made one arterial anastomoses (end-to-side) and three venous anastomoses (end-to-end) for abundant blood supply.

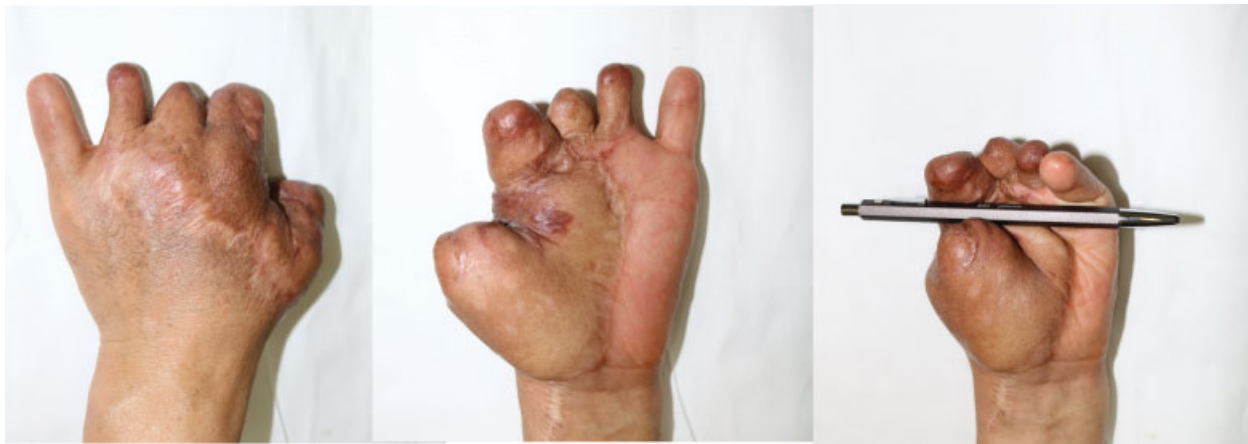

Fig. 3 Postoperative images at 1-year follow-up. The flap survived well and multiple minor operations for division were completed. The patient could get preservation of thumb grasping function with satisfactory power.

Discussion

A total degloving injury of the hand results in extensive loss of soft tissue and significant functional impairment. Goals of reconstruction are preservation of length in hand, aesthetic coverage, and finally restoration of function. At this point, an early coverage should be performed. However, because a total degloving injury is infrequent in the literature, there has been neither an evolution in reconstructive techniques nor a gold standard. Groin flaps are a reliable option that shows advantages such as easy harvests, relatively large skin paddles, and minimal donor site morbidity, but can be insufficient in dimension to cover the extensive defects. An anterolateral thigh (ALT) flap could provide pliable tissue, but it too is not enough to cover the whole defect. Thus, most studies recommend the usage of multiple combination of flaps.² Henry et al suggested a three-flap reconstruction of an extensive hand and finger degloving injury, while Cowen and Giannotto suggested multiple thoracoabdominal pedicle flaps.³

Furthermore, Zhang et al suggested using multiple chimeric flaps for reconstruction.⁴ Recently, the combination of ALT and groin flaps showed feasibility in managing this kind of injury by providing substantial amounts of tissue.

Currently, DIEP flaps have become a standard in autologous breast reconstruction, due to abundant yields of skin and soft tissue, and surgeons' familiarity with the surrounding anatomy that makes it easy to handle.^{5,6} Providing the largest amount of skin and soft tissue might be an advantage for extensive traumatic wound repair.⁷

However, we should regard several technical considerations during DIEP flaps on total degloving injuries of the hand. This patient initially had severe injuries beyond necrotic tissue, amputated bone, and crushed tendon. Thus, the possibility of injury on recipient vessels should be considered. Preoperative computed tomography angiography is useful to select a recipient vessel.

Also, when the DIEP flap was harvested, the Hartrampf zone IV with weak perfusion was usually sacrificed for breast reconstruction. With the 100% inset of harvested flaps, we should secure abundant vascular supply for the entire flap.⁸

To solve the circulation problem, a bipedicle procedure or anastomosis of multiple veins, usually used for breast reconstruction, should be made.⁹ Technically, it is a tedious procedure and needs sophisticated dissection skills.

Based on its bulky soft tissue and remnant skin, we could obtain additional skin for making a web during interdigitation after liposuction. Also, DIEP flaps could provide natural dimension for grasping that could mimic web spaces. The patient could achieve grasping motions after a few division operations.

Including minor operations, the management of degloved hand needs quite a long hospital course. Thus, we suggest one-stage coverage with one donor site, which is very efficient and easily acceptable from the patient's perspective, making a good rapport with the surgeon. The advantages of single-stage early coverage are the prevention of serious soft tissue infections and osteomyelitis, which result in additional amputations. We believe that DIEP flaps can be an excellent option for covering extensive defects of the hand for functional restoration.

Funding

Dr. Kim reports grants from Ewha Womans University, during the conduct of the study.

Conflict of Interest

None.

References

- 1 Rajasekaran S, Sabapathy SR. Management of Mangled Extremities. In *Orthopedics in Disasters*: Springer; 2016:305–320
- 2 Hansen DC, Moon WK, Kusuma SK. Prophylactic free flap for chronic lower-extremity soft-tissue defect prior to total knee arthroplasty: a case report. *JBJS Case Connect* 2013;3(03):e75
- 3 Cowen NJ, Giannotto RP. Multiple flap coverage for degloving hand injuries. *South Med J* 1978;71(03):281–288
- 4 Zhang YX, Wang D, Zhang Y, et al. Triple chimeric flap based on anterior tibial vessels for reconstruction of severe traumatic injuries of the hand with thumb loss. *Plast Reconstr Surg* 2009; 123(01):268–275
- 5 Healy C, Allen RJ Sr. The evolution of perforator flap breast reconstruction: twenty years after the first DIEP flap. *J Reconstr Microsurg* 2014;30(02):121–125

- 6 Van Landuyt K, Blondeel P, Hamdi M, Tonnard P, Verpaele A, Monstrey S. The versatile DIEP flap: its use in lower extremity reconstruction. *Br J Plast Surg* 2005;58(01):2–13
- 7 Hou C, Chang S, Lin J, Song D. Deep Inferior Epigastric Artery Perforator (DIEP) Flap. In *Surgical Atlas of Perforator Flaps*: Springer; 2015:131–138
- 8 Zeltzer AA, Van Landuyt K. Reconstruction of a massive lower limb soft-tissue defect by giant free DIEAP flap. *J Plast Reconstr Aesthet Surg* 2012;65(02):e42–e45
- 9 Koshima I, Moriguchi T, Soeda S, Tanaka H, Umeda N. Free thin paraumbilical perforator-based flaps. *Ann Plast Surg* 1992;29(01):12–17