

Approach to the Adequate Choice of the Intramedullary Screw for the Treatment of Hand Bone Fractures — Radiological Study in Metacarpals and Proximal and Medial Phalanges

Aproximación a la elección adecuada del tornillo intramedular para el tratamiento de las fracturas de los huesos de la mano — estudio radiológico en metacarpiano y falanges proximales y medias

María Jesús Rivera Vegas¹ Pablo Martínez Núñez² Rebeca Astorga Veganzones²

¹Facultativo Especialista, Servicio de Cirugía Plástica, Estética y Reparadora del Hospital Universitario de Burgos, Burgos, Spain

²Médico Interno y Residente, Servicio de Cirugía Plástica, Estética y Reparadora del Hospital Universitario de Burgos, Burgos, Spain

Address for correspondence María Jesús Rivera Vegas, MD, Servicio de Cirugía Plástica, Estética y Reparadora del Hospital Universitario de Burgos, Burgos, Spain (e-mail: riveravegas@gmail.com).

Rev Iberam Cir Mano 2018;46:26–33.

Abstract

Introduction One option to treat unstable and transverse fractures of the phalanges and metacarpals is intramedullary screw fixation. So far there are no references in the literature on how to choose the most appropriate screw in each case despite leaving more frequent use. However, Non-negligible complications may result in incorrect screw selection.

Material and Method One hundred radiographs were studied, in postero-anterior and oblique projection. Long fingers were measured. We were looking for the limiting measure, which is defined as the smallest dimension of the medullary in a cross-section of the bone. The limiting measure will indicate the screw that we should use.

Results A great variability was found in limiting measure. This variability was equal when studied men and women. Inverse linear regression between size of the medullary and cortical bone was observed.

Conclusions Measure the medullary of the fractured bone is an easy, fast and cheap strategy which can allow better results when we treat fractures with intramedullary screws.

Keywords

- ▶ metacarpal fractures
- ▶ cannulated screws
- ▶ intramedullary fixation
- ▶ phalangeal fractures

Resumen

Introducción El uso de tornillos intramedulares de compresión en la fijación de las fracturas extraarticulares de metacarpianos y falanges, es un método de osteosíntesis en auge para el tratamiento de fracturas inestables transversas u oblicuas cortas. Pero hasta el momento, los criterios para la determinación del tornillo adecuado no han sido tratados en la literatura. Sin embargo, una incorrecta selección puede causar graves complicaciones. El objetivo del estudio es seleccionar el tornillo canulado de

compresión correcto para cada paciente a partir de medidas obtenidas en radiografías simples en proyecciones convencionales.

Material y Métodos Se estudiaron las radiografías de mano de 100 pacientes, en proyección anteroposterior y oblicua, midiendo los dedos largos. Se buscó la medida limitante, que se define como la menor dimensión de la medular en un corte transversal del hueso, tanto para los metacarpianos, como para las falanges proximales y medias.

Resultados La medida limitante de los metacarpianos se valora en las radiografías PA y en las falanges proximales y medias en las oblicuas. Se observó una gran variabilidad en la medida limitante, que se mantiene cuando estudiamos por género. Además de una regresión lineal inversa entre el tamaño de la medular y el tamaño de las corticales.

Conclusiones El objetivo de este estudio fue determinar mediante radiología convencional los diámetros de las cavidades medulares de metacarpianos y falanges, y usar esos como guía en la selección del diámetro del tornillo canulado, y de ese modo, tratar de hacer más predecible la obtención de resultados óptimos evitando la aparición de complicaciones potencialmente graves.

Palabras clave

- ▶ fractura metacarpiana
- ▶ tornillo canulado
- ▶ fijación intramedular
- ▶ fractura falange

Introduction

The use of intramedullary compression cannulated screws in the fixation of metacarpal and phalanx fractures is a method that has experienced a sharp increase in recent years. Its use is indicated in unstable transverse and short, oblique fractures, both metaphyseal and dysphasia in patients with closed epiphyseal plaques.¹ From the time when the first publications described their applicability in the treatment of metacarpal and proximal phalanges, the use of intramedullary compression cannulated screws has extended to medial phalanges with excellent results.² By means of this treatment method, the aim is to avoid the complications that appear relatively frequently with the use of the classical fixation methods, such as Kirchner (K) needles and screws.³⁻⁶

In their study, Avery et al. stated that the intramedullary compression screws contribute a more resistant fixation than the K needles,⁷ demonstrating that the fixation allows for the patients to carry out protocols of immediate mobilization, in this way avoiding the stiffness and tendinous adherences, and favoring an early reincorporation into normal life.⁷

Various surgical techniques have been described for the placement of intramedullary screws, such as the retrograde introduction through the metacarpal head, and the antero-grade introduction by means of the luxation of the proximal joint to the corresponding fracture. But until now, the criteria for the selection of the appropriate screw has not been discussed in the literature. The incorrect selection can cause severe complications, such as iatrogenic fracture of the bone or the union of fragments for scarce compression.

The objective of this study was to determine by means of conventional radiology the diameters of the medullary cavities of the metacarpal and phalanges and use them as guides in the selection of the diameter of the cannulated screw, and in this way make the most accurate selection to obtain

optimum results avoiding the chance of potentially severe complications.

Material and Methods

One-hundred patients, 54 men and 46 women, were selected; they had been subjected to a posteroanterior and oblique X-ray of the hand, in which the large fingers (second and fifth fingers) were measured. Patients were excluded if they presented radiographically evident osteoarticular conditions, bone fractures, and if complete bone maturation was not present.

Three doctors performed the measurements using the IRE Image Channel software (IRE Rayos X S.A., Madrid, Spain). The measurements were taken in anteroposterior and oblique projections. Oblique projections were used because this is the protocol at our center.

In the metacarpals, we performed a preliminary study by means of measuring the medullary cavity diameter at different heights with the objective of knowing what the narrowest point was. In this study, we found out that the narrowest point was located in the proximities of the union of the two proximal thirds of the diaphysis of the second and fourth finger, and in the diaphysis half in the fifth finger. In the proximal and medial phalanges, the narrowest area of the medullary cavity is at the union between the head and the diaphysis.

The measurements of the exterior diameter and of the medullary cavity at the same point were registered in each one of the projections, both in the posterior-anterior (PA) and in the oblique projections this point was found at a slightly different height within the specific area, starting from these measurements we ascertained the percentage that the medullary cavity occupied with respect to the exterior measurement and the width of the cortical bone. If the projection is PA, the cortical bone measurements are radial and cubital,

while in the oblique projection, the cortical bone measurements are palmar and dorsal. In each patient, 2 measurements were obtained per radiograph, which means 24 measurement projections were taken, with a total of 48 measurements.

The limiting measurement was found, that is, the narrowest dimension of the medullary cavity diameter, by means of a transversal cut of the bone. This measurement is approximately the maximum diameter of the rod of the screw that can be introduced into the medullary cavity without the occurrence of secondary complications due to inappropriate choice but allowing the union to be stabilized.

In the case of the metacarpals, the prior anatomical knowledge describes the medullary canal as a cylinder,⁸ to such an extent that the measurements could be taken both in PA and in oblique projection. To prove the veracity of this affirmation the interior measurements taken in PA projection and in oblique were compared applying the t Student statistics for a sample of two tails. The t values obtained were 0.95 for the 2nd finger, and 0.90 for the 3rd, 4th, and 5th fingers. These values confirm that there are no statistically significant differences in the measurements obtained in both projections. Once demonstrated, by consensus of the researchers, it was decided to take the measurements in the metacarpals in the PA projection to avoid the superpositioning that the metacarpals suffer in the oblique projection and that could make precise measurement difficult (→ Fig. 1).

In the case of the proximal and half phalanges, since the shape of the canal is flattened from front to back,⁹ the measurement should be taken in the oblique projection, as it is the narrowest, and for this reason, the limiting one (→ Fig. 2).¹⁰

In the data analysis, we took into account the variable gender to determine if there existed significant differences between men and women.

We also measured the size of the cortical width. Once the medullary cavity diameter and the cortical width were known, we established the existence or not of a linear dependence between both variables by means of the Pearson correlation coefficient. An R^2 value was established, which was used as the coefficient of determination that determines the quality of the model to replicate the results.

The screws that we have in our setting are of two types, one with spires along the entire length, and the other is a "Herbert" type, that is, with spires in the proximal and distal regions. They come in different tip and thread sizes (→ Table 1), and the distribution of our data are based on those sizes.

Results

The average age of the sample was 42.75 years, with a standard deviation of 20 years, and an age range between 13 and 88 years old.

On analyzing the measurements obtained, we found the following results.

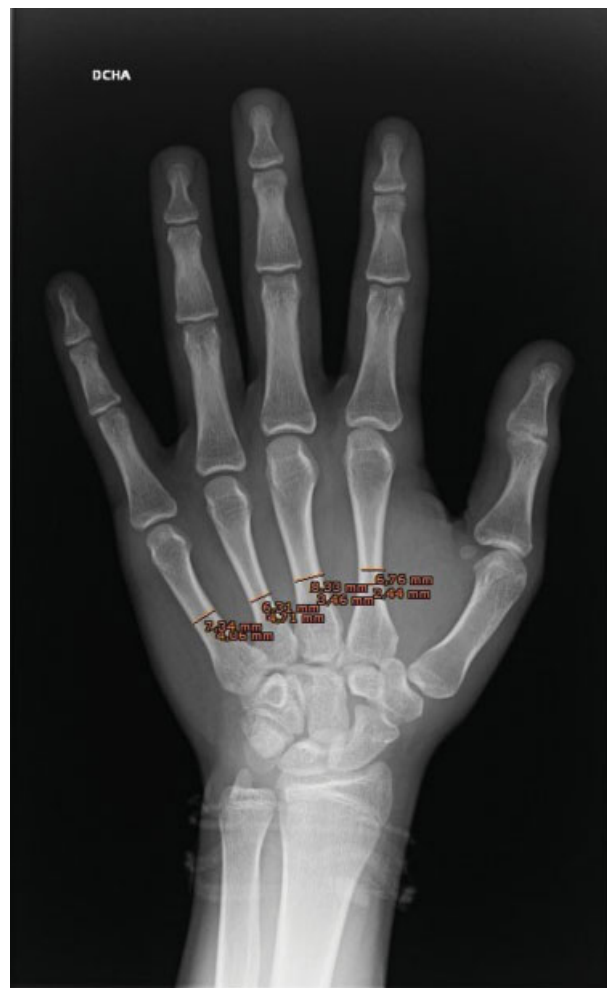

Fig. 1 Measurement of the metacarpals of the large fingers on PA radiograph using IRE Image Channel software (IRE Rayos X S.A., Madrid, Spain).

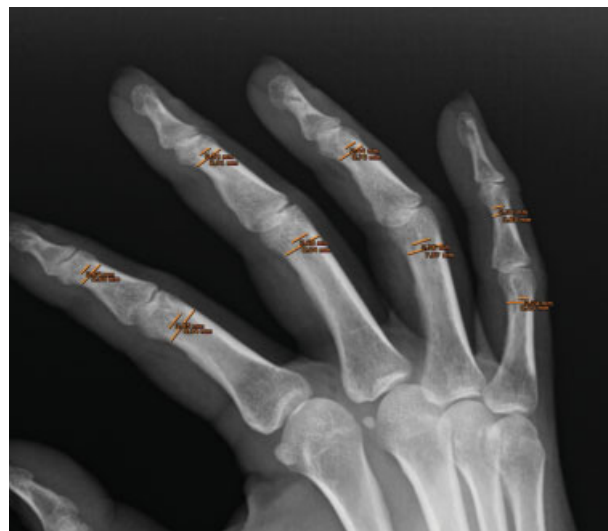

Fig. 2 Measurement of the proximal and medial phalanges of the large fingers in an oblique radiograph using IRE Image Channel software (IRE Rayos X S.A., Madrid, Spain).

Table 1 Measurements of the screws used as reference

Screw type	Width
Complete cannulated spirals	4.0 mm
Complete cannulated spirals	3.5 mm
Complete cannulated spirals	2.5 mm
Partial cannulated spirals (herbert)	3.0 mm
Partial cannulated spirals (herbert)	2.2 mm

There is great variability in results of the medullary cavity measurements, with a wide range in each one of the bones measured. This variability is maintained when our results are filtered by gender, although the average medullary cavity width of men is 14% greater than that of women.

A linear regression was observed between the width of the medullary cavity and the width of the cortical bone in all of the bones studied, that is to say, the narrower the medullary cavity the wider the cortical bone, conclusion reached after applying the Pearson correlation test.

In **Fig. 3A**, we can observe the medullary cavity of a phalanx with a screw that is too wide, and in **Fig. 3B**, the same bone when an appropriate screw for its size is introduced.

Metacarpals

Measurement of the medullary cavity diameter in the PA projection, in which the limiting measurement is found (**Tables 2 and 3**).

The linear regression between the medullary cavity diameter percentage and the width of the cortical bone reaches R^2 values between 0.7 and 0.8, that is to say, there is a relation of high statistical potential.

2nd finger: the medullary cavity of the metacarpal presents an average width of 3.64 mm (range 0.93–5.78 mm).

In ~ 80% of the cases, the medullary cavity presents an average width of 3 mm or more. As an example of the great

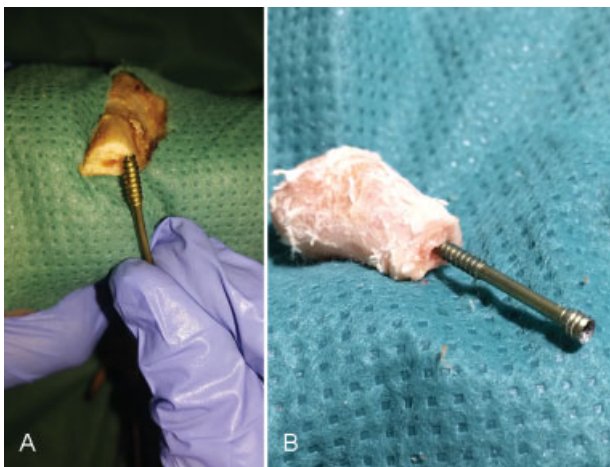


Fig. 3 (A) Comparison of the size of the medullary canal in a proximal phalanx of a cadaver with a screw whose caliber is too big. (B) Screw with adequate size embedded in the medullary canal of the same phalanx.

Table 2 Mean medullary measure of metacarpals, percentage and mean size of the cortical in all collected metacarpals

Table of percentages				
Metacarpals	2 nd	3 rd	4 th	5 th
Internal PA (mean)	3.65 mm	3.78 mm	3.18 mm	4.23 mm
TOTALS	T 2 nd	T 3 rd	T 4 th	T 5 th
> 5 mm	9%	11%	1%	17%
4–5 mm	24%	27%	18%	45%
3.5–4 mm	18%	22%	15%	18%
3–3.5 mm	26%	23%	27%	12%
2.5–3 mm	11%	11%	23%	7%
2.2–2.5 mm	4%	1%	7%	1%
< 2.2 mm	6%	5%	9%	0%
Cortical PA (mean)	2.31 mm	2.14 mm	1.68 mm	1.63 mm
Oblique cortical (mean)	2.29 mm	2.19 mm	1.7 mm	1.43 mm

Abbreviations: PA, posterior anterior.

variability of the medullary cavity measurements, 6% of them present a size narrower than 2.2 mm and 9%, present a size wider size than 5 mm.

3rd finger: the medullary cavity of the metacarpal presents an average width of 3.78 mm (range 0.56–6.1 mm).

83% of the metacarpals present a medullary cavity width of 3 mm or more. The majority of the data obtained on the second are comparable to those obtained in the third finger.

4th finger: the medullary cavity of the metacarpal presents an average width of 3.18 mm (range 0.82–5.83 mm).

65% of the medullary cavities of our sample present widths of 3 mm or less. A total of 9% corresponds to medullary cavities narrower than 2.2 mm and only 1% presents medullary cavities wider than 5 mm.

In women, a decrease in the percentage in which screws of 3 mm or more could be used was observed.

5th finger: the medullary cavity of the metacarpal presents an average width of 4.2 mm (range 2.35–7.26 mm).

92% of the phalanges present a medullary cavity width of 3 mm or more. A total of 45% present a medullary width greater than 4 mm, and 17% greater than 5 mm.

Proximal Phalange

The measurement of the medullary cavity was performed in oblique cuts, which allowed us to find the limiting measurement (**Tables 4 and 5**).

2nd finger: the medullary cavity of the phalanx presents an average width of 4.21 mm (range 1.77–7.06 mm.).

A total of 83% of the phalanges have a medullary cavity width of 3 mm or more. The medullary cavities of 27% of the patients were wider than 4 mm and in 25% of them, it was 5 mm-wide. Against this and, as an example of the great variability of the medullary cavity measurements, 3% present a size narrower than 2.2 mm.

Table 3 Mean medullar measure of metacarpals, percentage and mean size of the cortical in metacarpals by gender

Table of percentages					Table of percentages				
Metacarpals	2 nd	3 rd	4 th	5 th	Metacarpals	2 nd	3 rd	4 th	5 th
Internal PA (mean)	3.78 mm	3.79 mm	3.28 mm	4.43 mm	Intern PA (mean)	3.49 mm	3.78 mm	3.05 mm	4 mm
MEN	M 2 nd	M 3 rd	M 4 th	M 5 th	WOMEN	W 2 nd	W 3 rd	W 4 th	W 5 th
> 5 mm	11.1%	12.9%	2%	27.7%	> 5 mm	6.5%	8.6%	0%	4.3%
4–5 mm	31.4%	25.4%	23.9%	38.9%	4–5 mm	21.7%	26%	13%	17.3%
3.5–4 mm	14.8%	18.5%	16.6%	18.5%	3.5–4 mm	19.5%	28.3%	10.8%	52.1%
3–3.5 mm	25.9%	24%	22.2%	5.5%	3–3.5 mm	26%	21.7%	32.6%	19.5%
2.5–3 mm	7.4%	11.1%	18.5%	9.2%	2.5–3 mm	15.2%	10.8%	28.2%	4.3%
2.2–2.5 mm	1.8%	1.8%	3.7%	0%	2.2–2.5 mm	6.5%	0%	10.8%	2.1%
< 2.2 mm	7.4%	5.5%	12.9%	0%	< 2.2 mm	4.3%	4.3%	4.3%	0%
Cortical PA (mean)	2.44 mm	2.34 mm	1.76 mm	1.73 mm	Cortical PA (mean)	2.15 mm	1.90 mm	1.59 mm	1.52 mm
Oblique cortical (mean)	2.47 mm	2.37 mm	1.82 mm	1.51 mm	Oblique cortical (mean)	2.07 mm	1.99 mm	1.57 mm	1.33 mm

Abbreviations: PA, posterior anterior.

3rd finger: the medullary cavity of the phalange presents an average width of 4.06 mm (range 1.96–7.09 mm).

A total of 86% of the medullary cavities of the phalanges have a width of 3 mm or more. The majority of the data obtained on the third finger is comparable to those obtained on the second finger.

Table 4 Mean medullar measure of proximal phalanges, percentage, and mean size of the cortical in all proximal phalanges

Table of percentages				
Proximal phalanx	2 nd	3 rd	4 th	5 th
Internal oblique (mean)	4.21 mm	4.06 mm	3.61 mm	2.89 mm
TOTALS	T 2 nd	T 3 rd	T 4 th	T 5 th
> 5 mm	25%	16%	8%	0%
4–5 mm	27%	34%	25%	10%
3.5–4 mm	19%	20%	21%	9%
3–3.5 mm	12%	16%	19%	24%
2.5–3 mm	12%	11%	18%	24%
2.2–2.5 mm	2%	1%	5%	13%
< 2.2 mm	3%	2%	4%	20%
Cortical PA (mean)	2.22 mm	2.28 mm	2.1 mm	1.7 mm
Oblique cortical (mean)	2.11 mm	2.18 mm	1.9 mm	1.46 mm

Abbreviations: PA, posterior anterior.

4th finger: the medullary cavity of the phalanx presents an average width of 3.6 mm (range 1.79–5.83 mm).

A total of 73% of the proximal phalanges have a medullary cavity width of 3 mm or more.

In the distribution by gender, we observed a clear decrease in the percentage of female patients in which the medullary cavity is 3 mm or wider.

5th finger: the medullary cavity of the phalanx presents an average width of 2.89 mm (range 1.48–4.9 mm).

A total of 57% of the phalanges present a medullary cavity width of 3 mm or less. A total of 20% of those studied present a medullary cavity size narrower than 2.2 mm.

The distribution by gender is very similar.

Middle Phalange

The measurement of the medullary cavity was performed in oblique radiographs, which allowed us to find the limiting measurement (→ **Table 6 and 7**).

2nd finger: the medullary cavity of the phalange presents an average width of 2.60 mm (range 0.63–5.28 mm).

A total of 51% of the middle phalanges present a medullary cavity narrower than 3 mm. We should point out that 33% of the medullary cavities do not reach 2.2 mm. As an example of the great variability, 6% of the medullary cavities present a size wider than 4 mm, and 2% wider than 5 mm.

The results are maintained in both men and in women.

3rd finger: the medullary cavity of the phalanx presents an average width of 2.9 mm (range 1.05–6.07 mm).

A total of 53% of the phalanges have a medullary cavity narrower than 3 mm. This finger has the greatest variability in the size of medullar, presenting 11% of the medullary cavities wider than 4 mm, and 3% wider than 5 mm. The results are maintained both genders.

Table 5 Mean medullar measure of proximal phalanges, percentage including each measurement, and mean size of the cortical in proximal phalanges by gender (mm)

Table of percentages					Table of percentages				
Proximal phalanx	2 nd	3 rd	4 th	5 th	Proximal phalanx	2 nd	3 rd	4 th	5 th
Internal oblique (mean)	4.5 mm	4.3 mm	3.85 mm	3.08 mm	Internal oblique (mean)	3.88 mm	3.77 mm	3.34 mm	2.68 mm
MEN	M 2 nd	M 3 rd	M 4 th	M 5 th	WOMEN	W 2 nd	W 3 rd	W 4 th	W 5 th
> 5 mm	35%	22.2%	12.9%	0%	> 5 mm	13%	8.6%	2.1%	0%
4–5 mm	27.9%	37.6%	27.8%	16.6%	4–5 mm	26.1%	30.4%	21.7%	2.1%
3.5–4 mm	12.9%	24%	24%	9.2%	3.5–4 mm	26.1%	15.2%	17.3%	8.7%
3–3.5 mm	11.1%	7.4%	14.8%	20.3%	3–3.5 mm	13%	26.1%	23.9%	28.2%
2.5–3 mm	11.1%	7.4%	14.8%	25.9%	2.5–3 mm	13%	15.2%	21.7%	21.7%
2.2–2.5 mm	0%	0%	3.7%	14.8%	2.2–2.5 mm	4.3%	2.1%	6.5%	10.8%
< 2.2 mm	1.8%	1.8%	1.8%	12.9%	< 2.2 mm	4.3%	2.1%	6.5%	28.2%
Cortical PA (mean)	2.38 mm	2.4 mm	2.24 mm	1.88 mm	Cortical PA (mean)	2.03 mm	2.14 mm	1.9 mm	1.63 mm
Oblique cortical (mean)	2.23 mm	2.33 mm	2.18 mm	1.59 mm	Oblique cortical (mean)	1.98 mm	2 mm	1.78 mm	1.3 mm

Abbreviations: PA, posterior anterior.

4th finger: the medullary cavity of the phalanx presents an average width of 2.76 mm (range 0.56–5.9 mm).

A total of 66% of the middle phalanges present medullary cavity diameter narrower than 2.5 mm and 30% have a size narrower than 2.2 mm.

In the distribution by genders, 76% of the women present the medullary cavities narrower than 2.5 mm.

Table 6 Mean medullar measure of middle phalanx, percentage and mean size of the cortical of all middle phalanges

Table of percentages				
Middle phalanx	2 nd	3 rd	4 th	5 th
Internal oblique (mean)	2.6 mm	2.9 mm	2.76 mm	2.38 mm
TOTAL	T 2 nd	T 3 rd	T 4 th	T 5 th
> 5 mm	2%	3%	2%	0%
4–5 mm	6%	11%	7%	3%
3.5–4 mm	8%	8%	9%	4%
3–3.5 mm	10%	21%	16%	10%
2.5–3 mm	26%	19%	26%	19%
2.2–2.5 mm	15%	13%	11%	16%
< 2.2 mm	33%	25%	29%	48%
PA cortical (mean)	1.73 mm	1.89 mm	1.76 mm	1.37 mm
OBL cortical (mean)	1.57 mm	1.64 mm	1.6 mm	1.17 mm

Abbreviations: PA, posterior anterior.

5th finger: the medullary cavity of the phalanx presents an average width of 2.3 mm (range 0.99–4.41 mm).

A total of 48% of the middle phalanges have a medullary cavity narrower than 2.2 mm. A total of 35% of the medullary cavities present a width between 2.5 and 2.2 mm.

In terms of distribution by genders, the percentage of female patients that present a medullary cavity narrower than 2.2 mm increases to up to 56%.

Discussion

In our study, we observe a great variability of the results of the medullary cavities of the bones studied. This variability is maintained when the results are filtered by gender; even if the medullary cavities of men are 14% wider than those of women, on average. We also observe a linear regression between the size of the medullary cavity and the size of the cortical bone in all of the bones studied; that is to say, the narrower the medullary cavity diameter the wider the cortical bone.

A large number of the extra-articular fractures of the metacarpals or phalanges are susceptible to conservative treatment with adequate results, but it is not insignificant the number of fractures in these locations that are unstable and need surgical treatment for a satisfactory resolution; at times, they are operated on for functional requirements of the patient, who wishes to quicken the recovery and return to normal life.^{11–13} Throughout the years, many techniques and devices have been described and defended for the osteosynthesis of these fractures, each one of them with their advantages and disadvantages. But to this today there is still no consensus regarding which of the techniques is the

Table 7 Mean medullar measure in mm, percentage including each measurement, and mean size of the cortical of middle phalanges by gender

Table of percentages					Table of percentages				
Middle phalanges	2 nd	3 rd	4 th	5 th	Middle phalanges	2 nd	3 rd	4 th	5 th
Internal oblique (mean)	2.56 mm	2.8 mm	2.91 mm	2.46 mm	Internal oblique (mean)	2.57 mm	2.98 mm	2.58 mm	2.28 mm
MEN	M 2 nd	M 3 rd	M 4 th	M 5 th	WOMEN	W 2 nd	W 3 rd	W 4 th	W 5 th
> 5 mm	1.8%	3.7%	3.7%	0%	> 5 mm	2.1%	2.1%	0%	0%
4–5 mm	5.6%	7.4%	7.4%	1.8%	4–5 mm	6.5%	15.2%	6.5%	4.3%
3.5–4 mm	11.1%	9.2%	12.9%	5.5%	3.5–4 mm	4.3%	6.5%	4.3%	2.1%
3–3.5 mm	5.5%	29.6%	20.3%	12.9%	3–3.5 mm	15.2%	10.8%	10.8%	6.5%
2.5–3 mm	25.9%	20.3%	20.3%	20.3%	2.5–3 mm	26%	17.3%	32.6%	17.3%
2.2–2.5 mm	14.8%	9.2%	12.9%	18.5%	2.2–2.5 mm	15.2%	17.3%	8.7%	13%
< 2.2 mm	35.1%	20.3%	22.2%	40.7%	< 2.2 mm	30.4%	30.4%	36.9%	56.5%
Cortical PA (mean)	1.75 mm	1.91 mm	1.76 mm	1.41 mm	Cortical PA (mean)	1.70 mm	1.86 mm	1.76 mm	1.33 mm
Oblique cortical (mean)	1.63 mm	1.72 mm	1.62 mm	1.24 mm	Oblique cortical (mean)	1.51 mm	1.54 mm	1.55 mm	1.08 mm

Abbreviations: PA, posterior anterior.

Medullar and cortical means. Percentage of measured bones in ones eligible to screws.

most adequate, and it is the surgeon who, depending on his experience, decides to use one or the other.¹⁴

It is difficult to define the method of ideal fixation, one that would allow for early mobilization after surgery, quick incorporation into work and sports activities, limit the surgical bony exposure and minimize the need to withdraw the osteosynthesis material. By means of the use of cannulated screws, these requirements are met but they also present a series of limitations and complications, such as pseudoarthrosis, cutaneous necrosis for the protrusion of the osteosynthesis material as well as the shattering of the diaphysis of the bone that accommodates the screw.^{15,16} On using these screws in the retrograde via a small defect in the extensor apparatus is created as well as in the dorsal third of the articular surface. Previous analysis through 3D computerized tomography has shown that the articular surface that is damaged is minimal, and as it is so dorsal, it does not support an articular burden that could compare with the rest of the joint.¹⁷ In spite of these results supporting the use of the technique, more studies analyzing the long-term repercussion of the articular and tendinous violation need to be carried out.

As an alternative to the use of the percutaneous cannulated screw, we could use the open approach of the focus of the fracture and the fixation by means of mini-plates and screws, but the rate of complications is high, with the occurrence of infections, delays in consolidation of the fracture, tear or loosening of the plaque, complex regional pain syndrome, adhesion of the extensor apparatus and stiffness.^{18,19} The plaques and screws also have their advantage compared with the percutaneous cannulated screws. In

this sense, Melamed et al demonstrated that the tangential burden that is capable of supporting a transverse diaphysis fracture of the metacarpal treated by means of intramedullary cannulated screws without heads is significantly lower than that which supports a fracture treated by means of a plaque and screw.²⁰

Until recently, the choice of using the cannulated screw in the treatment of the fractures was based on the experience of the surgeon. Now, however, there are authors who have treated the topic of correct choice of the screw in other procedures, such as arthrodesis of the distal interphalangeal joint. These authors make reference to the importance of accurately selecting the screw to avoid potential complications. In these studies, they conclude that the measurement of the diameter of the medullary canal is the most adequate variable for choosing the size of the screw, and that, in the case of the distal phalanx the shape of the canal, flattening from front to back, the measurement should be taken in the oblique/lateral projection, thus allowing the surgeons to find the limiting measurement. Also, they situate the narrowest area of the medullary canal of the distal phalanx in the union between the head and diaphysis.^{19,20} For this, in the long fingers, the measurements in the phalanges should be performed in the oblique/lateral projection at the height of the union of the head and neck. The oblique and lateral measurements do not present statistically significant differences, with both projections being able to be used indistinctly. The measurements of the metacarpals should be performed in the PA projection in the union of the two proximal thirds with the distal third of the second to fourth finger and in the fifth finger in the diaphysis medial area.

The data obtained in our study corroborate that previously published by Mintalucci,²¹ and amplify their observations to the medial and proximal phalanges. This has allowed us to suggest a manner of standardizing the choice of the adequate screw, based on conventional tests that are conducted on all patients at the moment of surgery and simple measurements that do not have a steep learning curve. With this study, we have tried to determine the average measurements of the diameters of the medullary cavities that can help us to select the adequate diameter of the screw to be used prior to the surgery. Our study is radiological, but our objective is to obtain a series of conclusions that will help us in clinical work. For example, when we come across a fracture of the 5th metacarpal at the clinic, in 92% of the cases we will use a screw of more than 3 mm or in the case of medial phalanges of the 5th finger, in the half of the cases we should think about performing another technique as in 48% of the men and 56% of the women they have a medullary canal narrower than 2.2 mm and in our case, with the screws that we have at our disposal, we could risk the integrity of the cortical bone.

Of special mention are the medullary measurements that are above or below the width of the screws evaluated according to **Table 1**, which are what we have in our hospital. In the case of a medullary canal wider than 5 mm, we will carefully consider their use as they might not give the necessary embedding of the screw and remain mobile between the cortical bones. When the medullary canal is narrower than 2.2 mm, the placement of the medullary screws could lead to rupture of the cortical bone.

We observe a linear regression between the diameter of the medullary cavity and the cortical bone width in all the bones studied; that is to say, the narrower the medullary canal, the wider the cortical bone. In the metacarpals, the coefficient of determination (R^2) is situated between 0.7 and 0.8, which demonstrates a strong linear dependence between both variables. In the proximal and medial phalanges, the R^2 value is lower, which indicates that the linear dependence is not as strong. When assessing the thickness of the cortical bone, the use of the bit could open the medulla of the bone without fracturing it. In order for this to occur, the placement of the K needle prior to the procedure should be perfectly centered in the medulla. This action can be dangerous and should be evaluated carefully.

Our study has various limitations to take into account. One limitation is that each one of the radiographs was evaluated by only one of the researchers. In spite of the measurements being taken with the same software with the capacity of measuring differences of fractions of millimeters, this could bring bias as there are already significant interobserver variations in the measurements. Also, the measurements were made by means of workstations chosen by each of the researchers, so there could exist differences in the number of pixels of the margins of the medullary canal due to the quality of the equipment chosen.

Based on the findings of our study, we could conclude that there is a great variability in the measurements obtained in the bones studied, as it is very important to take the medullary measurements of the bones to select the most appropriate

screw that does not produce iatrogenic damage upon being placed and that fixes the fracture in the best possible way.

References

- del Piñal F, Moraleda E, Rúas JS, de Piero GH, Cerezal L. Minimally invasive fixation of fractures of the phalanges and metacarpals with intramedullary cannulated headless compression screws. *J Hand Surg Am* 2015;40(04):692-700
- Giesen T, Gazzola R, Poggetti A, Giovanoli P, Calcagni M. Intramedullary headless screw fixation for fractures of the proximal and middle phalanges in the digits of the hand: a review of 31 consecutive fractures. *J Hand Surg Eur Vol* 2016;41(07):688-694
- Haughton D, Jordan D, Malahias M, Hindocha S, Khan W. Principles of hand fracture management. *Open Orthop J* 2012;6(01):43-53
- Eberlin KR, Babushkina A, Neira JR, Mudgal CS. Outcomes of closed reduction and periarticular pinning of base and shaft fractures of the proximal phalanx. *J Hand Surg Am* 2014;39(08):1524-1528
- Kurzen P, Fusetti C, Bonaccio M, Nagy L. Complications after plate fixation of phalangeal fractures. *J Trauma* 2006;60(04):841-843
- Hsu LP, Schwartz EG, Kalainov DM, Chen F, Makowicz RL. Complications of K-wire fixation in procedures involving the hand and wrist. *J Hand Surg Am* 2011;36(04):610-616
- Avery DM III, Klinge S, Dyrna F, et al. Headless compression screw versus Kirschner wire fixation for metacarpal neck fractures: a biomechanical study. *J Hand Surg Am* 2017;42(05):392.e1-392.e6
- Lazar G. MD, Schuller-Ellis F. Intramedullary structure of human metacarpals. *J Hand Surg Am* 1980;5(05):477-481
- Schuller-Ellis F, Laza G. Internal Morphology of Human Phalanges. *J Hand Surg Am* 1984;4(9A):490-495
- Wang WL, Darke M, Goitz RJ, Andrews CL, Fowler JR. A comparison of plain radiographs and computed tomography for determining canal diameter of the distal phalanx. *J Hand Surg Am* 2014;39(06):1068-1074
- Dickson DR, Mehta SS, Nuttall D, Ng CY. A systematic review of distal interphalangeal joint arthrodesis. *J Hand Microsurg* 2014;6(02):74-84
- Oetgen ME, Dodds SD. Non-operative treatment of common finger injuries. *Curr Rev Musculoskelet Med* 2008;1(02):97-102
- Kozin SH, Thoder JJ, Lieberman G. Operative treatment of metacarpal and phalangeal shaft fractures. *J Am Acad Orthop Surg* 2000;8(02):111-121
- Friedrich JB, Vedder NB. An evidence-based approach to metacarpal fractures. *Plast Reconstr Surg* 2010;126(06):2205-2209
- Kocak E, Carruthers KH, Kobus RJ. Distal interphalangeal joint arthrodesis with the Herbert headless compression screw: outcomes and complications in 64 consecutively treated joints. *Hand (NY)* 2011;6(01):56-59
- Song JH, Lee JY, Chung YG, Park JJ. Distal interphalangeal joint arthrodesis with a headless compression screw: morphometric and functional analyses. *Arch Orthop Trauma Surg* 2012;132(05):663-669
- ten Berg PW, Mudgal CS, Leibman MI, Belsky MR, Ruchelsman DE. Quantitative 3-dimensional CT analyses of intramedullary headless screw fixation for metacarpal neck fractures. *J Hand Surg Am* 2013;38(02):322-330.e2
- Page SM, Stern PJ. Complications and range of motion following plate fixation of metacarpal and phalangeal fractures. *J Hand Surg Am* 1998;23(05):827-832
- Fusetti C, Meyer H, Borisch N, Stern R, Santa DD, Papaloizos M. Complications of plate fixation in metacarpal fractures. *J Trauma* 2002;52(03):535-539
- Melamed E, Hinds RM, Gottschalk M, Kennedy O, Capo JT. Comparison of Dorsal Plate Fixation Versus Intramedullary Headless Screw Fixation of Unstable Metacarpal Shaft Fractures: A Biomechanical Study. *Hand (NY)* 2016;11(04):421-426
- Mintalucci D, Lutsky KF, Matzon JL, Rivlin M, Niver G, Beredjiklian PK. Distal interphalangeal joint bony dimensions related to headless compression screw sizes. *J Hand Surg Am* 2014;39(06):1068-74.e1