

# Morphological and Morphometric Study of the Supratrochlear Foramen

F.A. Silva<sup>1</sup> T.S. Silva<sup>1</sup> P.R.F.B. Souza<sup>1</sup> R.S. Reis<sup>1</sup> M.R.S. Ferreira<sup>1</sup> C.P. Magalhães<sup>1</sup>

<sup>1</sup>Laboratório de Anatomia Humana, Centro Acadêmico de Vitória, Universidade Federal de Pernambuco – UFPE, Bela Vista, Vitória de Santo Antão, PE, Brazil

J Morphol Sci 2018;35:54–57.

Address for correspondence F.A. Silva, MD, Laboratório de Anatomia Humana, Centro Acadêmico de Vitória, Universidade Federal de Pernambuco – UFPE, Rua Alto do Reservatório, s/n, Bela Vista, Vitória de Santo Antão, PE 55608-680, Brazil (e-mail: fernandaalda.s@hotmail.com).

## Abstract

**Introduction** The supratrochlear foramen (SF) is located in the distal portion of the humerus, formed in between the coronoid fossa and the olecranon fossa. Is associated with a narrowing of the medullary canal in the distal humerus, in addition to being a phylogenetic characteristic, more common in ancient populations. The objective was to evaluate the incidence of the supratrochlear foramen, its shape, dimensions and translucency of the septum.

**Materials and Methods** A total of 141 humerus adults, 72 right and 69 left-handed individuals from the collection of the Human Bone of the Academic Center of Vitória-Brazil. The format was classified as oval, round, irregular and cribriform. The vertical (VD) and transversal (TD) diameter were measured and the translucency of the septum was observed.

**Results** Of the 141 humerus, 19.8% (28) had SF 39.3% (11) on the right side and 60.7% (17) on the left side. The oval was the most recurrent, found in 39% of the cases and the translucency was identified in 78% (110) of the bones. The mean VD was 3.653 mm and 3.492 mm on the right and left sides, respectively. The mean of the TD was 4.853 mm on the right side and 5.427 mm on the left. The area averages were  $19.633 \pm 20.57$  mm<sup>2</sup> on the right side and  $19.919 \pm 19.24$  mm<sup>2</sup> on the left side.

**Conclusion** The knowledge of SF favors the preoperative procedures of patients with fractures in the distal humerus, necessary for the surgeries in the region.

## Keywords

- ▶ humerus
- ▶ supratrochlear foramen
- ▶ anatomical variations
- ▶ radiology
- ▶ phylogeny

## Introduction

Bones are irregular structures that have elevations, protrusions and open areas for passages of vessels and nerves, these impressions are called bone accidents. These accidents are generated by several factors, such as fixation of the skeletal muscles, vessels and nerves transiting the bone surface, ligaments attaching to the ends of the bones and some viscera using them as a point of support.<sup>1</sup> Some accidents may not be present in the most individuals, being considered anatomical variations, such as the supratrochlear foramen. The supratrochlear foramen is located in the distal portion of the humerus and is formed by the absence of the septum that

separates the coronoid fossa and the fossa of the olecranon (Merckel, 1825).<sup>2</sup> Some authors suggest that the supratrochlear septum is not perforated in the embryonic development, and that it is intact up to 7 years of age.<sup>3</sup>

Its development occurs more frequently during adolescence or in adulthood, due to the incomplete ossification of that region.<sup>4</sup> Anthropologists argue that SF is more common in individuals of ancient civilizations when compared with contemporary populations, as well as present in primates, being considered a phylogenetic characteristic.<sup>5</sup> There have been reports that the presence of SF is associated with a narrowing of the medullary canal in the distal humerus.<sup>6,7</sup>

received  
March 8, 2017  
accepted  
February 16, 2018

DOI <https://doi.org/10.1055/s-0038-1660487>.  
ISSN 2177-0298.

Copyright © 2018 by Thieme Revinter Publicações Ltda, Rio de Janeiro, Brazil

License terms



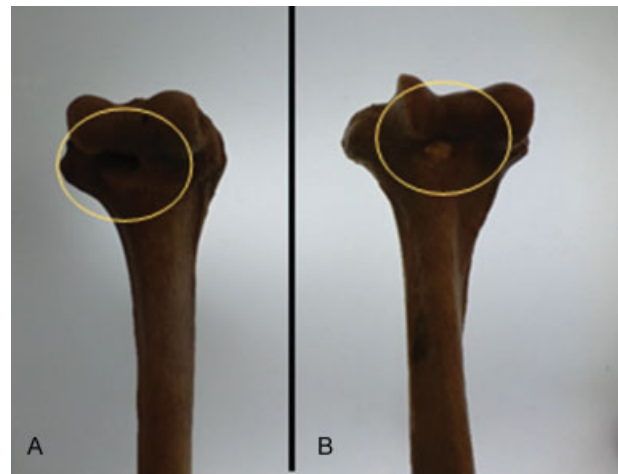
Knowledge of this association plays an important role in the intramedullary fixation procedure, since this region is commonly affected by fractures, especially in early childhood. The width of the canal is statistically smaller in humerus with SF, which can directly affect the entry point of an intramedullary fixation rod.<sup>8</sup> In this context, the objective was to evaluate the incidence of the supratrochlear foramen, its shape, dimensions and translucency of the septum of this region.

## Methods

Eighty-six adult human skeletons were used, where 55 had right and left side humerus, 17 only right side humerus and 14 left side humerus, totaling 141 bones. Being 72 rights and 69 left, coming from the collection of the Human Bone Collection of the Academic Center of Vitória-Brazil, authorization number CAAE 43228015.0.0000.5208. The presence of SF was observed, and when present they were classified according to their shape (oval, round, irregular and cribriform) (►Fig. 1). Measurements of vertical diameter and transverse diameter were also performed using a Lee Tools® 150-mm stainless steel digital caliper. The SF area was calculated through the ImageJ 150i program, from photographs of the bones. The translucency of the septum was also observed, placing the lower end of the humerus against the light of a negatoscope (►Fig. 2). For the data analysis, a normality test was used, and then the parametric (Student *t*-test) and non-parametric (Mann-Whitney) tests were applied.

## Results and Discussion

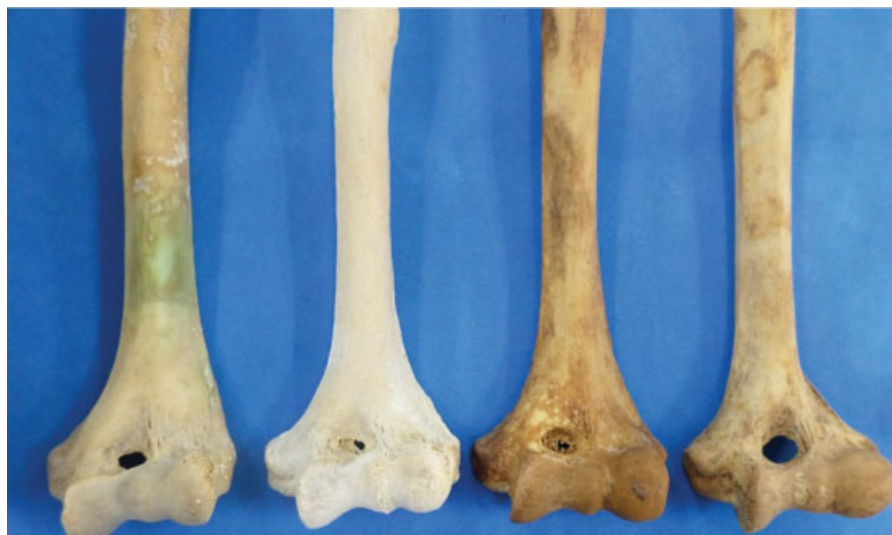Of the 141 bones studied, 19.8% (28) presented SF. The highest prevalence occurred in left side 60.7% (17), corroborating other authors.<sup>9-11</sup> However, Nayak et al<sup>12</sup> described a prevalence of 44.5% on the right side and 26.8% on the left



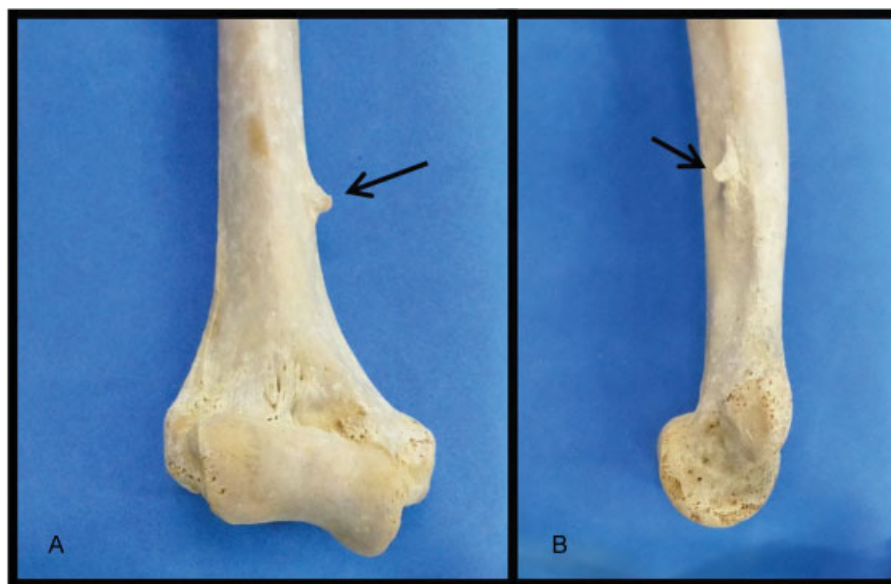**Fig. 2** Observation of the translucency of the septum of the inferior humerus end using the negatoscope. No translucency (A) and presence of translucency of the septum (B).

side, differing from our study. Already Singhal and Rao<sup>13</sup> identified a prevalence of 27.9% on the right side and 27.8% on the left side. The intermittent pressure of the olecranon and the coronoid process in the septum of the humerus can potentially lead to bone resorption and the formation of SF.<sup>14</sup> If mechanical stress is the causative agent, we can infer that SF is more frequent in the side that the individual has a higher prevalence of use, such as the right side in the case of rightists.

SF is a phylogenetic feature, also found in primates, and which can be inhibited by a more robust member. Explaining the higher frequency of SF on the left side observed in our study. This fact is due the intermittent pressure in the region resulting in hyperemia and strengthening of the bone septum,<sup>15</sup> which occurs on the right side in right-handed individuals, generating a more robust member compared with the left one.



**Fig. 1** Different shapes of the supratrochlear foramina (right to left): oval, irregular, cribriform and round.



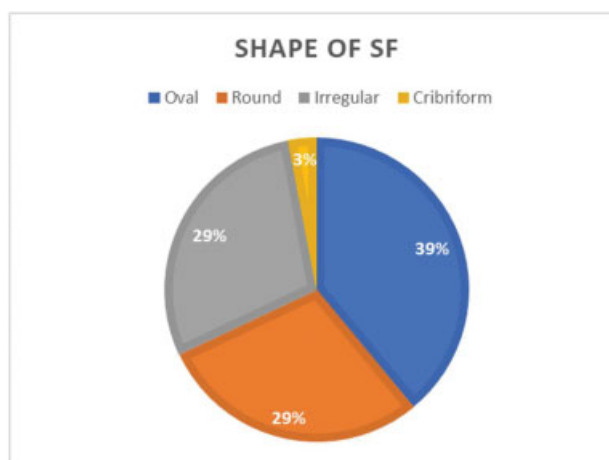
**Fig. 3** Humerus with the presence of the supracondylar process (arrows). Anterior view (A) and medial view (B).

According to Paraskevas et al. (2012),<sup>16</sup> there is an association between SF and presence of the supracondylar process, however, in this study, only one humerus was identified with the presence of the supracondylar process, not associated with SF (► **Fig. 3**).

Regarding the SF format, the oval type was the most recurrent, found in 39% of the cases, corroborating the study by Kumar et al. (2015)<sup>17</sup> (► **Fig. 4**). The translucency was

identified in 78% (110) of the analyzed bones; If there is a poor radiological interpretation, SF can be confused with osteolytic or cystic lesion at the distal humerus, an important finding during radiological examinations.<sup>8</sup> In relation to the SF measurements, the mean vertical diameter of the SF was 3.653 mm (0.5700–7.860 mm) and 3.492 mm (1.230–8.330 mm) on the right and left sides, respectively. The mean cross-sectional diameter was 4.853 mm (0.3900–9.870 mm) on the right side and 5.427 mm (1.770–11.25 mm) on the left side. The difference between the two sides was not significant (► **Table 1**).

The area averages were almost identical,  $19.633 \pm 20.57$  mm<sup>2</sup> on the right side and  $19.919 \pm 19.24$  mm<sup>2</sup> on the left side (► **Table 2**). The knowledge of the VD and TD of the SF



**Fig. 4** Percentage of SF formats identified in the study.

**Table 2** Area values of the supratrochlear foramen

Area values*	Left side	Right side
Maximum	1.109	0.4060
medium	17.95	12.73
Minimum	77.75	66.11
Average	19.92	19.63
Standard deviation	19.24	20.57

\*Measurements were in mm<sup>2</sup>. Mean ± standard deviation.

**Table 1** Measurements of the Supratrochlear foramen

Measurements*	Right side		Value p < 0.05	Test t
Vertical Diameter	3.653 ± 1.983	3.492 ± 1.746	0.824	0.225
Horizontal Diameter	4.853 ± 2.934	5.427 ± 2.540	0.587	0.550

\*All measurements were in millimeters (mm). Mean ± standard deviation.

helps in preoperative procedures of orthopedic surgeries, as well as the awareness of the various forms and dimensions of this foramen may help to avoid errors in the interpretation of radiographs.<sup>16,18</sup>

## Conclusion

The knowledge of SF improves the understanding of the distal humerus region, favoring the preoperative procedures of patients with fractures in this region, necessary in the practice of orthopedic surgeons and radiologists.

### Acknowledgments

To the Laboratory of Anatomy of the Academic Center of Vitoria, Federal University of Pernambuco.

## References

- Nobeschi ML. *Osteologia*. São Paulo: Instituto CIMAS; 2010
- Meckel JH, Kate BR, Dubey PN. A note on the septal apertures in the humerus of central Indians. *East Anthropol* 1970; 33:270–284
- Li J, Mao Q, Li W, Li X. An anatomical study of the supratrochlear foramen of the Jining population. *Turk J Med Sci* 2015;45(06): 1369–1373. Doi: 10.3906/sag-1407-44
- Morton SH, Crysler WE. Osteochondritis dissecans of the supra-trochlear septum. *J Bone Jt Surg* 1945;27:12–24
- Raghavendra K, Reddy YAK, Shirol VS, Dixit D, Desai SP. Morphometric analysis of septal aperture of humerus. *Int J Med Research Health Sciences* 2014;3(02):269–272
- Akpınar F, Aydinlioğlu A, Tosun N, Doğan A, Tuncay I, Unal O. A morphometric study on the humerus for intramedullary fixation. *Tohoku J Exp Med* 2003;199(01):35–42. Doi: 10.1620/tjem.199.35
- Koyun N, Aydinlioğlu A, Gümrukçüoğlu FN. Aperture in coronoid-olecranon septum: A radiological evaluation. *Indian J Orthop* 2011;45(05):392–395. Doi: 10.4103/0019-5413.83945
- De Wilde V, De Maeseneer M, Lenchik L, Van Roy P, Beeckman P, Osteaux M. Normal osseous variants presenting as cystic or lucent areas on radiography and CT imaging: a pictorial overview. *Eur J Radiol* 2004;51(01):77–84. Doi: 10.1016/S0720-048X(03)00180-3
- Bhanu PS, Sankar KD. Anatomical note of supratrochlear foramen of humerus in south costal population of Andhra Pradesh. *Narayana Medical Journal* 2012;1(02):28–34
- Krishnamurthy A, Yelicharla AR, Takkalapalli A. Supratrochlear foramen of humerus: a morphometric study. *Inter J Biolog Med Research* 2011;2(03):829–831
- Veerappan V, Ananthi S, Kannan NG, et al. Anatomical and radiological study of supratrochlear foramen of humerus. *World J Pharm Sci* 2013;2(01):313–320
- Nayak SR, Das S, Krishnamurthy A, Prabhu LV, Potu BK. Supratrochlear foramen of the humerus: an anatomico-radiological study with clinical implications. *Ups J Med Sci* 2009;114(02):90–94. Doi: 10.1080/03009730802688819
- Singhal S, Rao V. Supratrochlear foramen of the humerus. *Anat Sci Int* 2007;82(02):105–107. Doi: 10.1111/j.1447-073X.2007.00172.x
- Mays S. Septal aperture of the humerus in a mediaeval human skeletal population. *Am J Phys Anthropol* 2008;136(04):432–440. Doi: 10.1002/ajpa.20826
- Hrdlicka A. The humerus: septal apertures. *Anthropology* 1932; 10:31–96
- Paraskevas GK, Natsis K, Anastasopoulos N, Ioannidis O, Kitsoulis P. Humeral septal aperture associated with supracondylar process: a case report and review of the literature. *Ital J Anat Embryol* 2012;117(03):135–141
- Kumar UCD, Sukumar V, Sirisha V, Rajesh S, Krishna M, Kalpana T. Morphologic and morphometric study of supra trochlear foramen of dried human humeri of telangana region. *Int J Current Research Review* 2015;7(09):95–98
- Ndou R, Smith P, Gemell R, Mohatla O. The supratrochlear foramen of the humerus in a South African dry bone sample. *Clin Anat* 2013;26(07):870–874