

Prenatal Diagnosis and Successful Palliation of Absent Aortic Valve with Hypoplastic Left Heart Syndrome: A Case Report and Review of Literature

Amna Qasim, MD^{1*} Chelsea B. Johnson, MD¹ Muhammad A. Aly, BS¹ Ashraf M. Aly, MD, PhD^{2*}

¹Department of Pediatrics, University of Texas Medical Branch, Galveston, Texas

²Division of Pediatric Cardiology, University of Texas Medical Branch, Galveston, Texas

Address for correspondence Amna Qasim, MD, Department of Pediatrics, University of Texas Medical Branch, 301 University Boulevard, Galveston, TX-77555 (e-mail: amnahqasim@gmail.com).

Am J Perinatol Rep 2019;9:e121–e126.

Abstract

Introduction Congenital absence of the aortic valve leaflets is a rare association with hypoplastic left heart syndrome (HLHS).

Case A 37-year-old pregnant woman was referred for fetal evaluation of possible HLHS at 22 weeks of gestation. The fetal echocardiogram (ECHO) was remarkable for a hypoplastic left atrium, nearly atretic mitral valve, small left ventricle, and a hypoplastic aortic valve with severe aortic insufficiency. A female infant was born at term and postnatal ECHO confirmed the above findings. In addition, there was complete absence of the aortic valve leaflets. The patient underwent Norwood's procedure at day 5 of life with atrial septectomy, over-sewing of the aortic valve annulus, and a 4 mm Sano's shunt between the right ventricle and the main pulmonary artery. She tolerated this surgery well and subsequently underwent a bidirectional Glenn's procedure at 8 months of life.

Conclusion Prenatal diagnosis of absent aortic valve should be suspected in the presence of severe aortic insufficiency in the fetal ECHO. Early postnatal intervention is critical as those patients are likely to deteriorate quickly. The over-sewing of the aortic valve may be important to prevent coronary steal and myocardial hypoperfusion which could potentially be detrimental.

Keywords


- ▶ fetal echocardiography (ECHO)
- ▶ absent aortic valve
- ▶ hypoplastic left heart syndrome


Absence of the aortic valve (AAV) is a very rare congenital heart defect, unlike the absence of pulmonary valves. AAV is usually associated with other cardiac and non-cardiac anomalies. Most of the previously reported cases have been in spontaneously aborted fetuses, underscoring the high mortality of this heart defect.

Case

A 37-year-old pregnant female (Gravida 5, Para 3) was referred for fetal echocardiogram (ECHO) due to concerns

of hypoplastic left heart (HLH) on anatomy ultrasound scan. Fetal ECHO at 22 weeks was significant for a hypoplastic left atrium, nearly atretic mitral valve, small nonapex forming left ventricle (LV), hypoplastic aortic valve with severe aortic insufficiency (▶ **Fig. 1**). Serial fetal ECHOs showed the same findings throughout pregnancy. No evidence of hydrops was seen. At 39-week gestation, a female infant was delivered with a birth weight 3.2 kg and Apgar's scores of 8 and 8 at 1 and 5 minutes, respectively. Prostaglandin E-1 (0.05 mcg/kg/min) infusion was started within an hour of delivery. Postnatal ECHO findings (▶ **Fig. 2**, ▶ **Video 1**) showed HLH variant with absent aortic valve and severe aortic insufficiency, a large PDA, moderate sized atrial septal defect (ASD), and poor left ventricular posterior wall function. The LV was diffusely echogenic but there was no clear endocardial fibro elastosis.

 Author's ORCID ID of Amna Qasim is orcid.org/0000-0002-0592-6705.

 Author's ORCID ID of Ashraf M. Aly is orcid.org/0000-0001-9548-8034.

received
September 12, 2018
accepted after revision
December 2, 2018

DOI <https://doi.org/10.1055/s-0038-1677480>.
ISSN 2157-6998.

Copyright © 2019 by Thieme Medical Publishers, Inc., 333 Seventh Avenue, New York, NY 10001, USA.
Tel: +1(212) 584-4662.

License terms



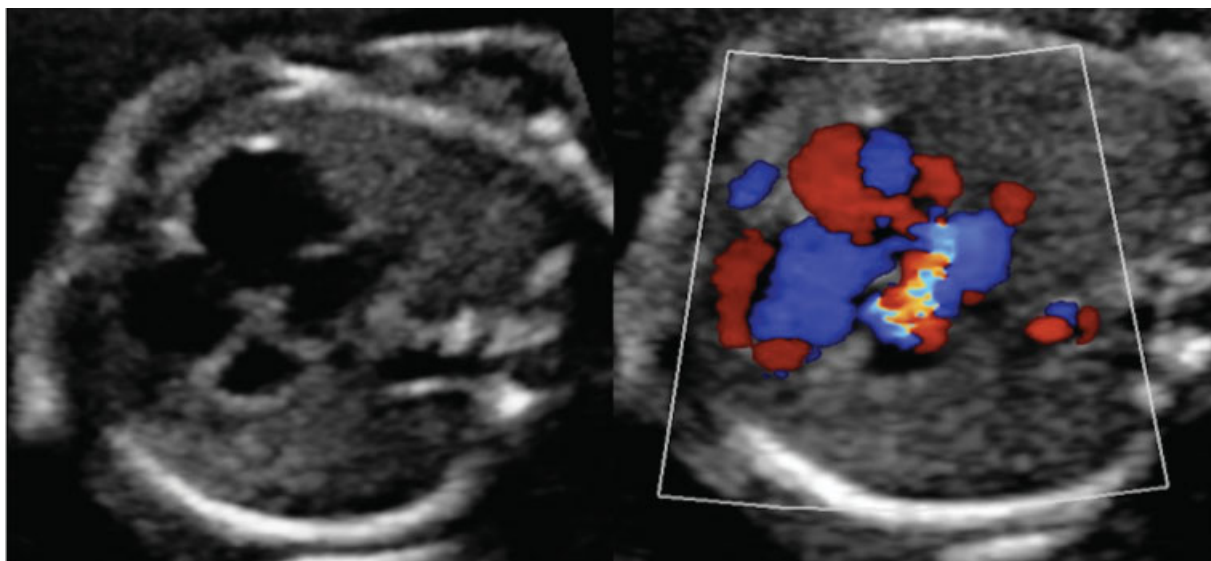


Fig. 1 Fetal ECHO “4-chamber view” showing a hypoplastic left ventricle and left atrium (left) and color Doppler’s image showing aortic regurgitation (right).

There was decelerated mitral inflow and a mild tricuspid valve insufficiency. The right ventricle was globular with a normal function. The coronary anatomy was normal but the flow was difficult to assess. Since the patient had no dysmorphic features or any extra cardiac anomaly, no genetic testing was done. The patient successfully underwent the first stage Norwood’s procedure on the 5th day of life. The procedure included atrial septectomy, an end to side main pulmonary artery to aorta (Damus-Kaye-Stansel) anastomosis, PDA ligation, over-sewing of the aortic valve, and the placement of a 4 mm Sano’s shunt between the right ventricle and the main pulmonary artery. Subsequently, she underwent the bidirectional Glenn’s procedure at 8 months of life and is currently

doing well and maintaining her O₂ saturations in the mid-80s on room air.

Video 1

A parasternal long axis view showing a hypoplastic left ventricle and an absent aortic valve with severe regurgitation. Online content including video sequences viewable at: www.thieme-connect.com/products/ejournals/html/10.1055/s-0038-1677480.

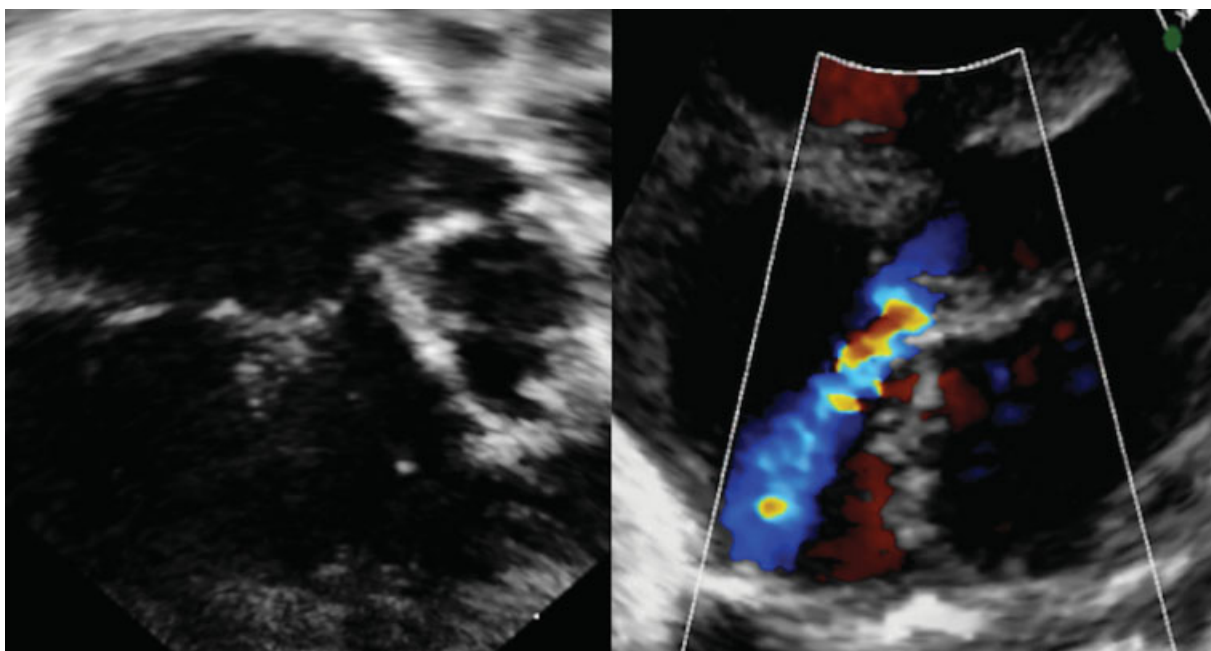


Fig. 2 Postnatal ECHO showing a hypoplastic left ventricle seen in 4-chamber view (left) and aortic regurgitation seen in parasternal long axis view (right).

Discussion

Absent aortic valve (AAV) is a rare congenital heart defect with our case being the 26th that was reported in literature.¹ It is usually associated with other congenital anomalies

including HLH, double outlet right ventricle (DORV), mitral atresia and absent, or dysplastic pulmonary valve. The clinical presentation may vary but mainly includes cyanosis, respiratory distress and cardiomegaly in the majority of reported cases. ► **Table 1** shows a review of previously

Table 1 Summary of all reported cases with absent aortic valves

Case no., gender	Diagnosis age and method	Other CHD	Noncardiac anomalies	Clinical presentation	Outcome	Ref.
1, M	36 h, autopsy	DORV, enlarged RA and RV, ASD, PDA, dysplastic LV, hypoplastic MV and LV	Accessory spleen	Severe cyanosis and cardiomegaly at 36 h	Death at 2 d	7
2, M	32 wk, fetal ECHO + autopsy	DORV, common AV canal, hypoplastic MV and LV	Absent R SVC, anomalous L SVC, splenic nodules, gut malrotation	Hydrops, severe polyhydramnios, RD	Death at 20 h	8
3, M	24 h, ECHO + autopsy	Hypoplastic MV and LV, EFE of LV	None	Cyanosis, RD, tachycardia	Death at 8 d	9
4, M	4 h, ECHO + autopsy	Hypoplastic LA, EFE of LV, anomalous RSA, dysplastic TV and PV, PDA	3 lobes in left lung and horseshoe kidneys	Severe cyanosis and RD	Death at 4 d	10
5, F	1 d, autopsy	ASD, VSD, Interrupted aortic arch, anomalous RSA	DiGeorge's syndrome (absent thymus, PTH glands)	RD, cardiomegaly	Death at 36 h	11
6, M	12 h, ECHO + autopsy	MV atresia, Dysplastic PV, PDA, normal LV	ND	RD, cyanosis	Death at 24 h	12
7, M	11 h, ECHO + autopsy	Dysplastic MV, PDA	ND	Cyanosis, RDS	Death at 16 h	13
8, M	20 h, autopsy	Dysplastic MV, PV stenosis, LV EFE	Cortical renal cysts, hydronephrosis, nephrosis, microcephaly	Cyanosis, RD, cardiomegaly	Death at 20 h	14
9, M	24 h, autopsy	Hypoplastic LA and LV, LV EFE, ASD, PDA	Hemosiderosis of liver, minimal deposits in kidney and spleen	RD, cyanosis	Death at 24 h	14
10, M	4 d, echo	MV atresia, Ebstein malformation, TAPVR, PDA	Hemosiderosis of liver	Cyanosis	Death at 6 d	14
11, F	18 wk, autopsy	DORV, HLV, VSD, straddling of TV, MV atresia, absent PV	Hypoplastic nose, radial aplasia, absent thumbs, absent left index finger, intestinal malrotation, horseshoe kidney	Spontaneous abortion, severely macerated fetus	IUD at 18 wk	15
12, M	18 wk, autopsy	Absent PV, VSD, small MV, thickened LV	Cleft lip/palate, low set ears	Spontaneous abortion, severely macerated fetus	IUD at 18 wk	15
13, F	18 wk, autopsy	Complete AVSD, persistent LSVC, anomalous RSA	Nuchal bleb, edema, thymic hypoplasia,	Generalized edema	Abortion at 18 wk	16

(Continued)

Table 1 (Continued)

Case no., gender	Diagnosis age and method	Other CHD	Noncardiac anomalies	Clinical presentation	Outcome	Ref.
			Trisomy 13 on cytogenetics			
14, F	14 wk, autopsy	DORV, VSD, absent PV, MV atresia, hypoplastic LA	Cystic hygroma, umbilical herniation, single UA, thymic hypoplasia	–	Artificial abortion at 14 wk	¹⁶
15, M	21 wk, autopsy	DORV, VSD, absent PV	Cystic hygroma, single UA, absent thymus	Generalized edema	Artificial abortion at 21 wk	¹⁶
16, ND	17 wk, fetal ECHO + autopsy	DORV, HLV, VSD, PDA	Hydranencephaly, hypoplastic left forearm, right radial aplasia	Hydrops, pericardial effusion, cardiomegaly	Termination at 18 wk	¹⁷
17, M	9 h, 2D ECHO	VSD, patent LSVC, absent MV, PDA, EFE of LV	High-arched palate, low set ears	Heart failure, cyanosis	Death at 20 h	¹⁸
18, M	12 h, ECHO + cath	HLH, EFE of LV, dysplastic MV	ND	Cyanosis, cardiomegaly	Norwood's + BT shunt at 7 dol, death at 20 dol	¹⁹
19, M	ND, ECHO	Dysplastic LV, MV atresia, PDA	None	Mild cyanosis	Norwood's at 12 dol, heart transplant at 1.5 mo	³
20, M	Fetal ECHO at 29 wk	VSD, PDA, dysplastic PV	ND	Fetal hydrops	Death at 4 h	²⁰
21, M	2 d, ECHO	MV atresia	ND	Cyanosis, Respiratory distress	Norwood's at 9 d, BDG at 6 mo, Fontan's at 6 y	^{2,21}
22, ND	31 wk, Fetal ECHO	LV hypertrophy and EFE	Generalized lymphangiectasis, systemic air embolism	Fetal hydrops	Death at 2 h	²²
23, F	24 wk, Fetal ECHO	DORV, large VSD, left SVC, AP window	Cystic hygroma, cerebral ventriculomegaly, microcephaly, clinodactyly, bilateral ear dysplasia, choanal atresia	Respiratory depression	Death at 2 d	²³
24, M	24 wk, Fetal ECHO	HLH, MV atresia	Broad fingers	Cardiomegaly, cyanosis	Norwood's and BDG at 3 mo, death at 10 mo	¹
25, M	23 wk, Fetal ECHO	Dilated LV, EFE, hypoplastic MV	ND	Fetal hydrops	IUD at 28 w	¹

Abbreviations: AAV, absent aortic valve; AP, aorticopulmonary; ASD, atrial septal defect; AV, atrioventricular; AVSD, atrioventricular septal defect; BDG, bi-directional Glenn; CHD, congenital heart disease; d, day; dol, day of life; DORV, double outlet right ventricle; ECHO, echocardiogram; EFE, endocardial fibroelastosis; F, female; h, hour; HLH, hypoplastic left heart; HLV, hypoplastic left ventricle; IUD, intrauterine demise; L, left; LV, left ventricle; M, male, mo, months; MV, mitral valve; ND, not described; PDA, patent ductus arteriosus; PTH, parathyroid glands; PV, pulmonary valve; R, right; RA, right atrium; RD, respiratory distress; RSA, right subclavian artery; RV, right ventricle; SVC, superior vena cava; TAPVR, total anomalous pulmonary venous return; TV, tricuspid valve; UA, umbilical artery; wk, week; y, year.

reported cases to date. The rarity of this condition may be due to the high rate of mortality leading to spontaneous abortions. Even though it was initially thought to be an X-linked recessive condition due to the first few reports being males, that does not seem to be the case since a few female cases have been reported.

Only two reported cases have survived beyond the first few days of life. Harada et al² described the first case of successful palliative surgery in a patient with HLH syndrome and AAV. At 9 days of life, the patient underwent Norwood's procedure with a Blalock-Taussig (BT) shunt. The aortic valve was noted to be absent and left ventricular cavity size was small with endocardial fibroelastosis. The patient did well and underwent the bidirectional Glenn's procedure at the age of 6 months and the Fontan's procedure at the age of 6 years. The aortic annulus was not oversewn with the thought that coronary circulation would be maintained owing to the markedly diminished size and compliance of the LV. In addition, a balloon occlusion of the left ventricular outflow tract showed no effect on the coronary circulation.

The second case of AAV that survived beyond the first few days of life was reported by Krasemann et al.³ Associated cardiac defects included mitral atresia and a large noncontractile hypoplastic LV. On day 12 of life the infant underwent the Norwood's procedure with additional surgical closure of the aortic valve with the goal of preservation of coronary perfusion. The postoperative course was complicated by difficulty weaning from mechanical ventilation. An orthotopic heart transplantation was successfully performed 4 weeks after the Norwood's procedure. The postoperative course was uneventful. The child was doing well at 5 months of age when this case was reported.

The majority of reported cases of AAV were diagnosed either on autopsy or on postnatal ECHO, with only a handful of cases diagnosed on fetal ECHO (–Table 1). Fetal ECHO was introduced as a diagnostic modality in the early 1970s and has advanced significantly over the past few decades.⁴ It has been shown to be a valuable tool in the optimization of perinatal care.^{5,6} To date, no fetal interventions have been attempted for the palliation of this condition.

Our case is one of the first few reported cases that were diagnosed by fetal ECHO, the second case that underwent successful palliative repair, and the third case that survived beyond the first few days of life. To our knowledge, it is also the first reported case in which the infant underwent successful Norwood's procedure with closure of the aortic valve annulus. Closure of the aortic valve annulus would prevent the development of coronary steal syndrome that may occur if continued aortic regurgitation leads to increased left ventricular size and compliance.

Conclusion

AAV is rare and is usually associated with other congenital cardiac anomalies, especially HLHS. It should be suspected in the presence of aortic insufficiency on fetal ECHO. Palliative repair with Norwood's procedure with over-sewing of the

aortic annulus could potentially prevent coronary steal and myocardial hypoperfusion in these patients.

Ethical Approval

This article does not contain any studies with human participants performed by any of the authors.

Informed Consent

Informed consent was waived for this study since no identifying information was included.

Conflict of Interest

The authors declare that they have no conflicts of interest.

References

- Murakami T, Horigome H, Shiono J, et al. Prenatal diagnosis of congenital absence of aortic valve: a report of two cases with different outcomes and a literature review. *Fetal Diagn Ther* 2015; 38(04):307–314
- Harada Y, Takeuchi T, Satomi G, Yasukouchi S. Absent aortic valve: successful palliation in the neonate. *Ann Thorac Surg* 1998;66(03):935–936
- Krasemann T, Kehl HG, Hammel D, Asfour B. Congenital aortic regurgitation due to absent aortic cusps and high-degree mitral stenosis. *Pediatr Cardiol* 2003;24(03):304–306
- Maulik D, Nanda NC, Maulik D, Vilchez G. A brief history of fetal echocardiography and its impact on the management of congenital heart disease. *Echocardiography* 2017;34(12): 1760–1767
- Liu H, Zhou J, Feng QL, et al. Fetal echocardiography for congenital heart disease diagnosis: a meta-analysis, power analysis and missing data analysis. *Eur J Prev Cardiol* 2015;22(12): 1531–1547
- Holland BJ, Myers JA, Woods CR Jr. Prenatal diagnosis of critical congenital heart disease reduces risk of death from cardiovascular compromise prior to planned neonatal cardiac surgery: a meta-analysis. *Ultrasound Obstet Gynecol* 2015;45(06): 631–638
- Toews WH, Lortscher RH, Kelminson LL. Double outlet right ventricle with absent aortic valve. *Chest* 1975;68(03):381–382
- Bierman FZ, Yeh MN, Swersky S, Martin E, Wigger JH, Fox H. Absence of the aortic valve: antenatal and postnatal two-dimensional and Doppler echocardiographic features. *J Am Coll Cardiol* 1984;3(03):833–837
- Rossi MB, Ho SY, Tasker RC. Absent aortic valve leaflets. *Int J Cardiol* 1986;11(02):235–237
- Niwa K, Ikeda F, Miyamoto H, Nakajima H, Ando M. Absent aortic valve with normally related great arteries. *Heart Vessels* 1987;3(02):104–107
- Weintraub RG, Chow CW, Gow RM. Absence of the leaflets of the aortic valve in DiGeorge syndrome. *Int J Cardiol* 1989;23(02): 255–257
- Cabrera A, Galdeano JM, Pastor E. Absence of the aortic valve cusps with mitral atresia, normal left ventricle, and intact ventricular septum. *Br Heart J* 1990;63(03):187–188
- Parikh SR, Hurwitz RA, Caldwell RL, Waller B. Absent aortic valve in hypoplastic left heart syndrome. *Am Heart J* 1990;119(04): 977–978
- Lin AE, Chin AJ. Absent aortic valve: a complex anomaly. *Pediatr Cardiol* 1990;11(04):195–198
- Hartwig NG, Vermeij-Keers C, De Vries HE, Gittenberger-De Groot AC. Aplasia of semilunar valve leaflets: two case reports and developmental aspects. *Pediatr Cardiol* 1991;12(02): 114–117

- 16 Miyabara S, Ando M, Yoshida K, Saito N, Sugihara H. Absent aortic and pulmonary valves: investigation of three fetal cases with cystic hygroma and review of the literature. *Heart Vessels* 1994;9(01):49–55
- 17 Marek J, Skovránek J, Povýsilová V. Congenital absence of aortic and pulmonary valve in a fetus with severe heart failure. *Heart* 1996;75(01):98–100
- 18 Nakagawa M, Okamoto N, Fujino H, et al. Doppler echocardiographic evaluation of the hemodynamics in absent aortic valve. *Can J Cardiol* 1999;15(11):1283–1286
- 19 Rouillard KP, Moore P, Silverman NH. Congenital absence of aortic valvar leaflets: a rare variant of the hypoplastic left heart syndrome. *Cardiol Young* 2001;11(04):453–457
- 20 Eronen M, Heikkilä P. Absent aortic and dysplastic pulmonary valves associated with ventricular septal defect in fetal hydrops. *Pediatr Cardiol* 2003;24(04):400–402
- 21 Hibino N, Harada Y, Hiramatsu T, Yasukochi S, Satomi G. Fontan operation for hypoplastic left heart syndrome with absent aortic valve. *J Thorac Cardiovasc Surg* 2004;128(02):315–316
- 22 Muneuchi J, Kuraoka A, Ochiai Y, Nishibatake M, Sese A, Joo K. Fatal systemic air embolism in a neonate with absent aortic valve. *Pediatr Cardiol* 2011;32(06):839–841
- 23 Sabati AA, Wong PC, Randolph L, Pruetz JD. Absent aortic valve associated with double outlet right ventricle and aortopulmonary window: physiologic implications of a rare malformation in both the fetus and neonate. *Congenit Heart Dis* 2014;9(03):E98–E104