

# Effects of Supraphysiological Doses of Anabolic Androgenic Steroids on the Left Ventricles of Male and Female Mice Submitted to Swimming

Laís Cristina Teodoro Jerônimo<sup>1</sup> Priscila Franco<sup>1</sup> Petrus Pires Marques<sup>2</sup> Flávia da Ré Guerra<sup>3</sup>  
Wagner Costa Rossi Junior<sup>3</sup> Alessandra Esteves<sup>3</sup>

<sup>1</sup> Universidade Federal de Alfenas, Alfenas, MG, Brazil

<sup>2</sup> Department of Morphology, Universidade José Vellano, Alfenas, MG, Brazil

<sup>3</sup> Department of Anatomy, Universidade Federal de Alfenas, Alfenas, MG, Brazil

Address for correspondence Alessandra Esteves, PhD, Departamento de Anatomia, Universidade Federal de Alfenas, Rua Gabriel Monteiro da Silva, n°700, Centro, Alfenas- MG, Brazil, CEP 37130-000 (e-mail: aesteves015@gmail.com).

J Morphol Sci 2019;36:2–6.

## Abstract

The use of anabolic androgenic steroids (AAS) has grown into a worldwide substance abuse problem over the last decades, with the doses taken by illegal users being 10 to 100 times higher than the therapeutic ones. In the present experiment, 60 mice were divided into 3 groups of 20 animals. Group 1 received testosterone cypionate (Deposteron [EMS, São Bernardo do Campo, SP, Brazil]); group 2 received stanozolol (Stanozolol Depot, Landerlan, Lambaré, Paraguay), and group 3 received saline solution), each one composed by 10 males and 10 females, treated once a week and put to swimming thrice a week for 2 months. After euthanasia, their chests were opened, the hearts removed and processed histologically for morphometric analyses. The specimens were cut into 6 different sections and each one was measured with the help of an optical microscope with a 40-fold magnification. For such analyses, the Axiovision Rel. 4.8.2 (Carl Zeiss Microscopy LLC, Peabody, MA, USA) and Axiovision 4 Module Interactive Measurement (Carl Zeiss Microscopy LLC) software were used. The results showed that there was an increase in the diameter of the left ventricles in the male mice treated with Deposteron while in the female animals treated with Winstrol, there was a decrease in the left ventricular diameter in relation to the other two groups. Thus, one can conclude that the use of supraphysiological doses of the given AAS significantly alters the ventricular diameter in both male and female animals, which can cause a considerable change in both heart rate and blood pressure, and potentially induce disorders that are very relevant to the organism.

## Keywords

- ▶ anabolic steroids
- ▶ left ventricle
- ▶ mice
- ▶ morphometric analysis

## Introduction

The use of anabolic androgenic steroids (AAS) has grown into a worldwide substance abuse problem over the last decades. Today, the majority of AAS users are not competitive athletes, but, instead, they are typically young to middle-aged men who use them primarily for personal appearance.<sup>1</sup> The use of AAS is a public health concern for adolescent boys who have suffered bullying by being labeled gay/bisexual.<sup>2</sup>

The doses taken by these users are usually 10 to 100 times higher than the therapeutic ones, bringing forth hyperandrogenism. Although these doses promote increased strength and muscle development, they concomitantly develop hormonal disorders that lead to a variety of harmful consequences.<sup>3</sup>

Among the most striking AAS side effects are the increase in hematocrit and coagulation, causing thromboembolism, intracardiac thrombosis and stroke, as well as other cardiac

received  
August 22, 2018  
accepted  
January 28, 2019  
published online  
March 1, 2019

DOI <https://doi.org/10.1055/s-0039-1681110>  
ISSN 2177-0298.

Copyright © 2019 by Thieme Revinter Publicações Ltda, Rio de Janeiro, Brazil

License terms



disturbances including arrhythmias, cardiomyopathies, and, possibly, sudden death, adenomas and carcinomas.<sup>4</sup>

The use of anabolic agents causes adverse effects on the musculoskeletal system, increasing the risk of tendon rupture; this is due to the increase of strength and muscle mass.<sup>5</sup>

The anabolic activity of testosterone and its derivatives manifests primarily by its myotrophic action, which results in increased muscle mass by rising protein synthesis in the muscle.<sup>6</sup>

Krieg et al<sup>7</sup> analyzed cardiac changes by echocardiogram and observed an increase in the ventricular mass index and in the interventricular septum thickness in AAS users compared with non-users, and also a loss of diastolic function associated with a reduction in peak velocity during the initial phase initial of diastolic filling.

Studies performed with powered athletes by means of echocardiogram examination demonstrated that the cardiac remodeling that occurs as an effect of the use of anabolic steroids is irreversible.<sup>8</sup>

This paper intends to analyze the possible morphometric changes in the left ventricular diameter of male and female mice submitted to swimming that received supraphysiological doses of two types of AAS.

## Material and Methods

In this work, we used 60 Swiss mice (30 males and 30 females) from the Universidade Federal de Alfenas (UNIFAL-MG) bioterium, housed in boxes with 10 animals each, treated with commercial ration and water “ad libitum” (at will) and kept in a light-dark cycle of 12 hours. The present experiment was analyzed and approved by the Ethics Committee for Research and Animal Experimentation (ECRAE) of the University (protocol n° 414/2012).

The treatment with AAS consisted of intraperitoneal injections of two types of AAS, as follows: group 1 (10 male and 10 female animals) received a dose of 0.8 mg/kg

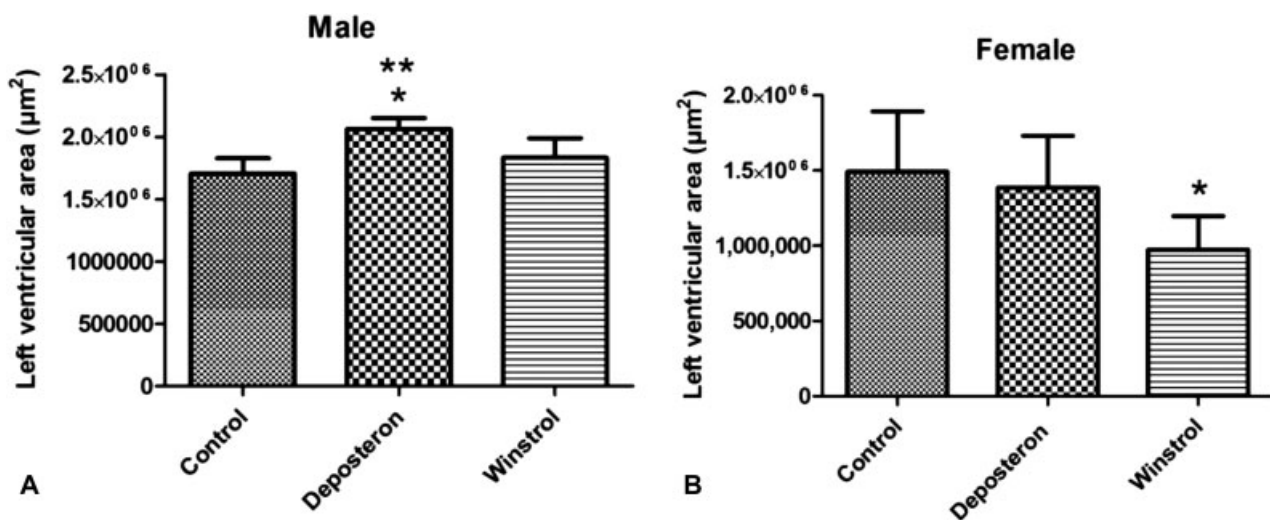
of Deposteron (EMS, São Bernardo do Campo, SP, Brazil); group 2 (10 male and 10 female animals) received a dose of 1.8 mg/kg of Winstrol (Stanozolol Depot, Landerlan, Lambaré, Paraguay), and group 3 (10 male and 10 female animals) received 1.8 mg/kg saline solution. The animals were treated for 2 months, with the doses being administered twice a week at 2-day intervals. On each of these interposed days, all mice were submitted to swimming for 10 minutes.

After euthanasia by inhalation of isoflurane, the chests of the mice were opened, and the hearts were entirely removed. Finally, they were stored in glass containers immersed in a buffered paraformaldehyde solution (pH 7.4) and remained in this fixative solution for 24 hours. Thus, the specimens were processed following the standardized sequence for a conventional histological procedure: alcohol dehydration, xylol diaphanization, and paraffin inclusion. Each heart was put in a paraffin block and cut into 7  $\mu\text{m}$ -thickness sections in Jinhua YIDI Medical Appliance CO., LTD (Jinhua City, Zhejiang Province, China) microtome and stained with hematoxylin and eosin. For the morphometric analysis, 6 distinct sections were selected and measured using an optical microscope with 40-fold magnification, and for the morphometric analysis of the ventricular cavity we used the Axiovision Rel. 4.8.2 (Carl Zeiss Microscopy LLC, Peabody, MA, USA) and Axiovision 4 Module Interactive Measurement (Carl Zeiss Microscopy LLC) software.<sup>9</sup>

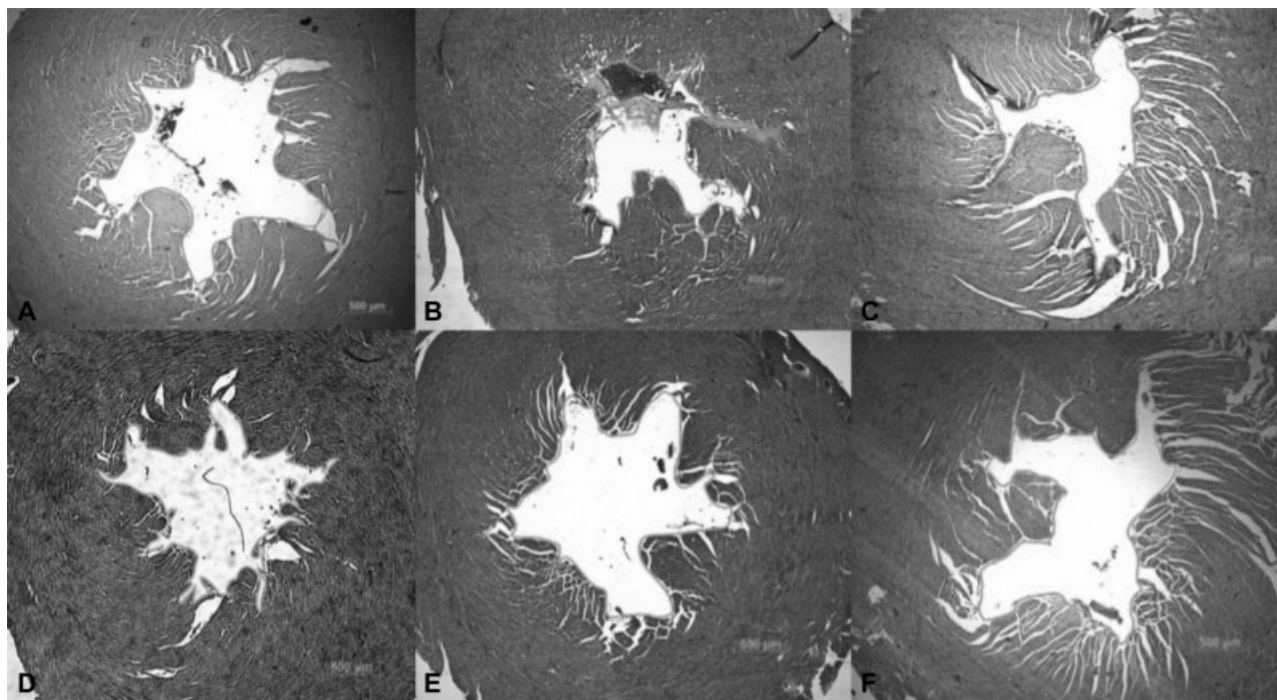
To evaluate the mean values of the left ventricle areas, according to mice's gender and treatment imposed (research groups), the variance analysis of variance was used. When a significant difference ( $p < 0.01$ ) was observed among the groups while comparing different variables, the Tukey test was used to discriminate differences and/or similarities among the evaluated means.<sup>9</sup>

## Results

According to the graph and photomicrographs (~Fig. 1A and 2E), it can be observed that in the male mice treated with



**Fig. 1** Comparative graphs of left ventricular diameter in male and female animals, respectively. (A) \* Statistically significant differences of control group animals compared with Deposteron animals ( $p < 0.001$ ) and \*\* Statistically significant differences of Winstrol animals compared with Deposteron animals ( $p < 0.01$ ). (B) Statistically significant differences of control group animals in relation to Winstrol animals ( $p < 0.01$ ).



**Fig. 2** Photomicrography of the cross-sections of the left ventricle of mice in both sexes and in different groups studied. A: Female control group; B: Deposteron female; C: Winstrol female; D: Male control group; E: Deposteron male, and F: Winstrol male.

Deposteron there was a significant increase ( $p < 0.001$ ) in the diameter of the left ventricle in relation to the control group ( $\rightarrow$  Fig. 2D) and the group treated with Winstrol ( $p < 0.01$ ) ( $\rightarrow$  Fig. 2F).

In the females, the results show that the group treated with Winstrol ( $\rightarrow$  Figs. 1B and 2C) presented a significant decrease in ventricular diameter ( $p < 0.01$ ) in relation to the control ( $\rightarrow$  Fig. 2A) and the Deposteron ( $\rightarrow$  Fig. 2B) groups.

## Discussion

Differences between genders are often ignored and underestimated when studying the cardiovascular system, and these cause biases and losses in the performed researches.<sup>10</sup> However, previous clinical and epidemiological studies have corroborated and acknowledged gender differences in cardiovascular function and disease.<sup>11</sup> The causal link between the use of AAS and the occurrence of cardiovascular diseases has been increasingly evidenced through researches, which demonstrate the frequent use of these substances associated with the rise in the occurrence of death due to cardiac arrest among the users.<sup>12-14</sup> Such studies corroborate the findings in the present study, which show that AAS use may cause morphological changes in the left ventricle and that they can lead to the appearance of cardiovascular diseases.

Cardiac changes in women and men may have been influenced by both dose and time period of administration of the drugs used, and these factors, isolated or together, may have led to different effects in both sexes. However, there are limitations and scarcity of data in the literature regarding the relevance and peculiarities of the different types of AAS.

Neto et al<sup>15</sup> suggest that the AAS dose is directly related to the aromatization of the testosterone; that is, the higher the dose, the greater the aromatization and the greater cardiac compromise. Pirompol et al<sup>16</sup> concluded that cardiac hypertrophy is not related to the dose, but to exposure to the induction of maladaptative heart responses. Therefore, although it was not possible to measure the interference of the dosage, period of use and active principle of the AAS used, the results presented here may induce and contribute to the interest and awakening for future researches.

A second hypothesis consists in the association of AAS action and the activation and increase of the sympathetic autonomic nervous system action. When present in the bloodstream, AAS reach the hypothalamus through the vascular organ of the terminal lamina or through the subfornical organ, structures that do not present a blood-brain barrier, facilitating the absorption and interaction by specific cellular groups of neurons acting on the control of viscera, blood osmolarity, angiotensin II levels and blood pressure. These negative influences of AAS use on the sympathetic modulation have already been evidenced and recorded by Neto et al,<sup>15</sup> whose study contributes to and strengthens the results observed here.

The consequences of non-therapeutic and abusive use of testosterone (AAS and its derivatives) are associated with an increase in blood pressure and induction of left ventricular changes, with consequent cardiac hypertrophy, as shown in some studies already performed.<sup>17-20</sup>

Initially, it was expected that there would be no change in the ventricular diameter in females because they have a greater amount of estrogen as a differential characteristic. This hormone is a protective factor for the cardiovascular system, and such concept has already been evidenced in

some previously published papers.<sup>21–23</sup> Nonetheless, some authors suggested that the decrease in the diameter of the left ventricle in female animals under supraphysiological doses of the AAS could be due to an increase in the left ventricular wall, leading to a decrease in the ventricular chamber volume with consequent hypertension, resulting in heart failure and left ventricular hypertrophy.<sup>24,25</sup>

Another hypothesis that would lead to an increase of muscle mass in females would be based on the same reason observed by Hayward et al,<sup>26</sup> who administered AAS to women and consequently observed an increase in cardiac muscle mass. This could explain the findings of increased muscle mass with a consequent decrease in diameter in females, in this study, in addition to the fact that the drugs themselves lead to an increase in ventricular mass. Thus, although females have to modulate hormonal protection (estrogen) in the cardiovascular system, such hormone would not have been able to prevent ventricular changes nor would it attenuate the androgenic actions of supraphysiological doses of AAS.

In male animals, it is suggested that the reason for finding the opposite result to that observed in female subjects was due to the drugs investigated in the present experiment, for they increased the left ventricular lumen because of an atrophy of the cardiac muscle and supposed decrease of left myocardial thickness. These effects can lead to chronic ischemia, which drives to fibrosis, reducing heart fiber nutrition, exactly as demonstrated in other studies.<sup>27,28</sup>

Other studies demonstrate that another reason that could lead to an increase in left ventricular diameter in male animals, as found in this study, is that AAS would induce dilated cardiomyopathy, primary heart muscle disease with dilation and change in the contractile function of the left ventricle, which is more prevalent in men than in women.<sup>29,30</sup>

Another factor that could contribute to the increase in left ventricular diameter is that, physiologically, males have a greater amount of endogenous testosterone when compared with females; this factor, added to supraphysiological doses, could lead to toxicity of the cardiac muscle tissue by inducing pro-oxidative actions on the cardiovascular system.<sup>10</sup>

This wide variety of hypotheses may be a reflection of the limitations pertinent to AAS studies and of the morphological consequences to the cardiovascular system caused by the use of AAS. This is due to several reasons, such as the manifestation of the effects, that do not appear in a short-term period and make it difficult to provide an early diagnosis, as well as the intrinsic factors of the AAS (dose, duration of treatment and active principle) that interfere in their action.<sup>1,31–33</sup>

## Conclusion

Thus, one can conclude that the use of supraphysiological doses of the administered AAS significantly and differently alters the ventricular diameter in male and female animals. Such findings may contribute to elucidate the possible effects and consequences of the indiscriminate use of these drugs concerning the cardiovascular system.

## Financial Support

Fundação de Amparo à Pesquisa do Estado de Minas Gerais (FAPEMIG, in the Portuguese acronym)/UNIFAL-MG

## Conflicts of Interest

The authors have no conflicts of interest to declare.

## References

- Kanayama G, Pope HG Jr. History and epidemiology of anabolic androgens in athletes and non-athletes. *Mol Cell Endocrinol* 2018;464:4–13
- Parent MC, Bradstreet TC. Sexual orientation, bullying for being labeled gay or bisexual, and steroid use among US adolescent boys. *J Health Psychol* 2018;23(04):608–617. Doi: 10.1177/1359105317692144
- Smurawa TM, Congeni JA. Testosterone precursors: use and abuse in pediatric athletes. *Pediatr Clin North Am* 2007;54(04):787–796, xii. Doi: 10.1016/j.pcl.2007.05.002
- Nieschlag E, Vorona E. Doping with anabolic androgenic steroids (AAS): Adverse effects on non-reproductive organs and functions. *Rev Endocr Metab Disord* 2015;16(03):199–211. Doi: 10.1007/s11154-015-9320-5
- Marqueti RC, Paulino MG, Fernandes MN, de Oliveira EM, Selistrede-Araujo HS. Tendon structural adaptations to load exercise are inhibited by anabolic androgenic steroids. *Scand J Med Sci Sports* 2014;24(01):e39–e51. Doi: 10.1111/sms.12135
- Kam PC, Yarrow M. Anabolic steroid abuse: physiological and anaesthetic considerations. *Anaesthesia* 2005;60(07):685–692. Doi: 10.1111/j.1365-2044.2005.04218.x
- Krieg A, Scharhag J, Albers T, Kindermann W, Urhausen A. Cardiac tissue Doppler in steroid users. *Int J Sports Med* 2007;28(08):638–643. Doi: 10.1055/s-2007-964848
- Urhausen A, Albers T, Kindermann W. Are the cardiac effects of anabolic steroid abuse in strength athletes reversible? *Heart* 2004;90(05):496–501. Doi: 10.1136/hrt.2003.015719
- Alves DM, Silva MSO, Zavan B, et al. Morphometric analysis of mice's ventricular myocardium submitted to androgenic anabolizing steroids use. *Journal of morphological. Science* 2015;32(01):33–36. Doi: 10.4322/jms.071614
- Tostes RC, Carneiro FS, Carvalho MH, Reckelhoff JF. Reactive oxygen species: players in the cardiovascular effects of testosterone. *Am J Physiol Regul Integr Comp Physiol* 2016;310(01):R1–R14. Doi: 10.1152/ajpregu.00392.2014
- Hayward CS, Kelly RP, Collins P. The roles of gender, the menopause and hormone replacement on cardiovascular function. *Cardiovasc Res* 2000;46(01):28–49
- D'Andrea A, Caso P, Salerno G, et al. Left ventricular early myocardial dysfunction after chronic misuse of anabolic androgenic steroids: a Doppler myocardial and strain imaging analysis. *Br J Sports Med* 2007;41(03):149–155. Doi: 10.1136/bjism.2006.03017
- Kasikcioglu E, Oflaz H, Umman B, Bugra Z. Androgenic anabolic steroids also impair right ventricular function. *Int J Cardiol* 2009;134(01):123–125. Doi: 10.1016/j.ijcard.2007.12.027
- Thiblin I, Lindquist O, Rajs J. Cause and manner of death among users of anabolic androgenic steroids. *J Forensic Sci* 2000;45(01):16–23
- Barbosa Neto O, da Mota GR, De Sordi CC, et al. Long-term anabolic steroids in male bodybuilders induce cardiovascular structural and autonomic abnormalities. *Clin Auton Res* 2018;28(02):231–244
- Pirompol P, Teekabut V, Weerachatanukul W, Bupha-Intr T, Wattanapermpool J. Supra-physiological dose of testosterone induces pathological cardiac hypertrophy. *J Endocrinol* 2016;229(01):13–23
- Christakou CD, Diamanti-Kandarakis E. Role of androgen excess on metabolic aberrations and cardiovascular risk in women with



- polycystic ovary syndrome. *Womens Health (Lond)* 2008;4(06):583–594. Doi: 10.2217/17455057.4.6.583
- 18 Cho MH, Jung KJ, Jang HS, Kim JI, Park KM. Orchiectomy attenuates kidney fibrosis after ureteral obstruction by reduction of oxidative stress in mice. *Am J Nephrol* 2012;35(01):7–16. Doi: 10.1159/000334598
  - 19 Elnakish MT, Hassanain HH, Janssen PM, Angelos MG, Khan M. Emerging role of oxidative stress in metabolic syndrome and cardiovascular diseases: important role of Rac/NADPH oxidase. *J Pathol* 2013;231(03):290–300. Doi: 10.1002/path.4255
  - 20 Frati P, Busardò FP, Cipolloni L, Dominicis ED, Fineschi V. Anabolic Androgenic Steroid (AAS) related deaths: autoptotic, histopathological and toxicological findings. *Curr Neuropharmacol* 2015;13(01):146–159. Doi: 10.1152/ajpregu.00392.2014
  - 21 Ellis JA, Infantino T, Harrap SB. Sex-dependent association of blood pressure with oestrogen receptor genes ERalpha and ERbeta. *J Hypertens* 2004;22(06):1127–1131
  - 22 Pedrosa DF, de Rezende LCD, Silva VI, Rangel LBA, Gonçalves WLS, Graceli JB. Efeitos benéficos do estrogênio no Sistema Cardiovascular. *Revista Científica Perspectivas On Line*. 2009;3(12):190–196
  - 23 Apaijai N, Charoenphandhu N, Ittichaichareon J, et al. Estrogen deprivation aggravates cardiac hypertrophy in nonobese Type 2 diabetic Goto-Kakizaki (GK) rats. *Biosci Rep* 2017;37(05):1–10. Doi: 10.1042/BSR20170886
  - 24 Montisci M, El Mazloum R, Cecchetto G, et al. Anabolic androgenic steroids abuse and cardiac death in athletes: morphological and toxicological findings in four fatal cases. *Forensic Sci Int* 2012;217(1–3):e13–e18. Doi: 10.1016/j.forsciint.2011.10.032
  - 25 Soares MCR, Abreu IC, Assencio F, Borges MOR. Decanoato de nandrolona Aumenta a Parede Ventricular Esquerda, mas Atenua o Aumento da Cavidade Provocado Pelo Treinamento de Natação em Ratos. *Rev Bras Med Esporte* 2011;17(06):420–424. Doi: 10.1530/JOE-15-0506
  - 26 Hayward CS, Webb CM, Collins P. Effect of sex hormones on cardiac mass. *Lancet* 2001;357(9265):1354–1356. Doi: 10.1016/S0140-6736(00)04523-2
  - 27 Dickerman RD, Schaller F, McConathy WJ. Left ventricular wall thickening does occur in elite power athletes with or without anabolic steroid Use. *Cardiology* 1998;90(02):145–148
  - 28 Mewis C, Spyridopoulos I, Kühlkamp V, Seipel L. Manifestation of severe coronary heart disease after anabolic drug abuse. *Clin Cardiol* 1996;19(02):153–155. Doi: 10.1002/clc.4960190216
  - 29 Codd MB, Sugrue DD, Gersh BJ, Melton LJ III. Epidemiology of idiopathic dilated and hypertrophic cardiomyopathy. A population-based study in Olmsted County, Minnesota, 1975–1984. *Circulation* 1989;80(03):564–572
  - 30 Albanesi Filho F. Cardiomiopatas. *Arq Bras Cardiol* 1998;71(02):95–107
  - 31 Cecchi R, Muciaccia B, Ciallella C, et al. Ventricular androgenic-anabolic steroid-related remodeling: an immunohistochemical study. *Int J Legal Med* 2017;131(06):1589–1595. Doi: 10.1007/s00414-017-1589-3
  - 32 Sinha-Hikim I, Artaza J, Woodhouse L, et al. Testosterone-induced increase in muscle size in healthy young men is associated with muscle fiber hypertrophy. *Am J Physiol Endocrinol Metab* 2002;283(01):E154–E164
  - 33 Zaugg M, Jamali NZ, Lucchinetti E, et al. Anabolic-androgenic steroids induce apoptotic cell death in adult rat ventricular myocytes. *J Cell Physiol* 2001;187(01):90–95. Doi: 10.1002/1097-4652(2001)9999:9999<00:AIDJCP1057>3.0.CO;2-Y