

Mosaicplasty Technique in the Treatment of Isolated Knee Femoral Condyle Osteochondral Lesions – a Retrospective Study*

Técnica de mosaicoplastia no tratamento de lesões osteocondrais isoladas do côndilo femoral do joelho – estudo retrospectivo

Samir Karmali¹ Rui Guerreiro¹ Daniel Sá da Costa¹ Jorge Fonseca¹ Ricardo Gonçalves² 

¹Orthopedic Department, Hospital Vila Franca de Xira, Vila Franca de Xira, Portugal

²Orthopedic Department, Shoulder and Elbow Unit, Hospital Privado de Gaia, Vila Nova de Gaia, Portugal

Address for correspondence Ricardo Gonçalves, MD, Orthopedic Department, Shoulder and Elbow Unit, Hospital Privado de Gaia, Rua Fernão de Magalhães, n° 2, Fração E, 24 4404-501, Vila Nova de Gaia, Portugal (e-mail: goncalves.ricardo@gmail.com).

Rev Bras Ortop 2019;54:316–321.

Abstract

Objective Focal osteochondral lesions of the knee are found in two thirds of patients undergoing arthroscopy; their treatment, when isolated and especially in young individuals, remains a debating topic. The present study analyzes the results obtained by the application of the mosaicplasty technique on the treatment of isolated knee femoral condyle osteochondral lesions.

Methods Retrospective study of patients submitted to mosaicplasty and to subjective analyses with pre- and postsurgery International Knee Documentation Committee (IKDC) scores.


Results A total of 13 cases with an average age of 34 years old, with male patients ($n = 4$; 31%) with an average age of 23 years old (range: 17–31 years old), and female patients ($n = 9$; 69%) with an average age of 39 years old (range: 16–56 years old); medial versus lateral femoral ($n = 11$; 85% versus $n = 2$; 15%); the average size of the lesion was 1.8 cm² (range: 0.6–4 cm²); average follow-up time: 5.045 ± 3.47 years (range: 1.15–11.01 years). The average preoperative IKDC score was of 31.63 points (± 20.24), the average postoperative IKDC score was of 74.18 points (± 20.26). The difference between the post- and preoperative IKDC scores was of 42.55 (± 21.05) points, being the minimal score increase of 8.1 points and the maximum score increase of 82.8 points. A statistically significant difference ($p < 0.001$) was found between the IKDC scores before and after the surgery. A statistically significant relation ($p = 0.038$) was found between the IKDC score increase (the difference between the postoperative and the preoperative scores) and the dimension of the lesion.

Conclusions Mosaicplasty with osteochondral autograft transfer, when adequately used, can produce excellent results with great durability and functional impact, low morbidity rates and costs. Expansion of the indication criteria shows promising mid-term and long-term results.

Keywords

- ▶ osteochondritis/diagnosis
- ▶ osteochondritis/surgery
- ▶ arthroscopy
- ▶ knee joint
- ▶ cartilage, articular

* The present study was conducted at the Orthopedic Department, Hospital Vila Franca de Xira, Portugal.

 Ricardo Gonçalves's ORCID is <https://orcid.org/0000-0002-0311-7023>.

Resumo

Objetivo Lesões osteocondrais focais do joelho são encontradas em dois terços dos pacientes submetidos à artroscopia; seu tratamento, quando isoladas e, principalmente, em indivíduos jovens, ainda é debatido. O presente estudo analisa os resultados obtidos com a aplicação da técnica de mosaicoplastia no tratamento de lesões osteocondrais isoladas do côndilo femoral do joelho.

Métodos Estudo retrospectivo de pacientes submetidos a mosaicoplastia e a análise subjetiva com pontuações do International Knee Documentation Committee (IKDC, na sigla em inglês) antes e após a cirurgia.

Resultados Um total de 13 pacientes com uma média de idade de 34 anos; pacientes do sexo masculino ($n = 4$; 31%) apresentaram uma média de idade de 23 anos (17–31 anos), e pacientes do sexo feminino ($n = 9$; 69%) apresentaram uma média de idade de 39 anos (16–56 anos); femoral medial ou lateral ($n = 11$; 85% e $n = 2$; 15%, respectivamente); o tamanho médio da lesão foi $1,8 \text{ cm}^2$ ($0,6\text{--}4 \text{ cm}^2$); o tempo médio de acompanhamento foi $5,045 \pm 3,47$ anos (1,15–11,01 anos). A pontuação IKDC média pré-operatória foi 31,63 pontos ($\pm 20,24$), e a pós-operatória foi 74,18 pontos ($\pm 20,26$). A diferença entre as pontuações IKDC obtidas depois e antes da cirurgia foi de 42,55 ($\pm 21,05$) pontos, com o aumento mínimo de 8,1 pontos, e máximo de 82,8 pontos. Uma diferença estatística significativa ($p < 0,001$) foi encontrada entre a pontuação IKDC antes e após a cirurgia. Uma relação estatisticamente significativa ($p = 0,038$) foi observada entre o aumento da pontuação IKDC (a diferença entre a pontuação pré- e pós-operatória) e as dimensões da lesão.

Conclusões A mosaicoplastia com transferência de autoenxerto osteocondral, quando adequadamente usada, pode produzir resultados excelentes com grande durabilidade e impacto funcional, baixas taxas de morbidade e baixos custos. A expansão dos critérios de indicação mostra resultados promissores em médio e longo prazo.

Palavras-chave

- ▶ osteocondrite/diagnóstico
- ▶ osteocondrite/cirurgia
- ▶ artroscopia
- ▶ articulação do joelho
- ▶ cartilagem articular

Introduction

Focal osteochondral lesions of the knee are found in two thirds of patients undergoing arthroscopy.¹ The treatment of these lesions, when these are isolated and especially in young individuals, remains a debating topic.^{2–4} Knee replacement surgery is not a good solution, and a technique that can reconstitute *ad integrum*, a normal hyaline cartilage articular surface, still does not exist.^{2,4–6} Presently, the available techniques follow principles of palliation (debridement and chondroplasty), repair (microfracture), and autologous chondrocyte implantation (ACI) restoration, osteochondral autograft transfer (OTA), and osteochondral allograft (OCA).^{2,3} The former, in which we can include mosaicplasty (OTA), has been applied mainly for symptomatic relief and in an attempt to regain an articular surface with biofunctional properties similar to those of an injured joint, aiming for function preservation and less progression of the osteoarticular disease.^{2,7–9} The present study aims to analyze the results obtained by the application of the mosaicplasty technique on the treatment of isolated knee femoral condyle osteochondral lesions.

Methodology

Retrospective analyses of patients with knee osteochondral lesions, selected and submitted to the mosaicplasty repair technique in our institution between 2001 and 2015. The inclusion criteria were: patients ≤ 60 years old, with single osteochondral femoral condyle lesion (Outerbridge III/IV) $< 4 \text{ cm}^2$ in the preoperative MRI (International Cartilage Repair Society – ICRS) and confirmed arthroscopically, with follow-up of at least 1 year. Patients with associated lesions (e.g., tibia or patella), malalignment, or previous realignment surgery, were excluded (▶ **Table 1**).

The procedure was performed using the Osteochondral Autograft Transfer System (OATS) (Arthrex, Inc., Naples, FL, USA) and according to the technique described by Hangody⁷, by arthroscopy with a mini arthrotomy for graft harvesting and transfer from its location (trochlear circumferential non-weight bearing area) to the osteochondral defect. (▶ **Fig. 1**). Postoperative protocol with weight bearing restriction for 2 weeks, followed by partial weight bearing (10–20% of the body weight) until the 6th week,

Table 1 Inclusion and exclusion criteria

Inclusion criteria
Age \geq 16 years old and \leq 60 years old
Isolated femoral condyle osteochondral lesion
Grade III/IV (Outerbrigde)
Size \leq 4 cm ²
Follow-up > 1 year
Exclusion criteria
Associated lesions (e.g., tibia or patella)
Malalignment or previous realignment surgery
Ligamentar instability
Inflammatory disease

total weight bearing until 6 months, and unrestricted activity thereafter.

The patients were submitted to subjective evaluation with the International Knee Documentation Committee (IKDC) form, in the period between the lesion and the surgery, and

again 1 year after the surgery. Data analyses were made with IBM SPSS Statistics for Windows, Version 22.0 (IBM Corp., Armonk, NY, USA).

Results

From the analyses of the 13 cases eligible for the present study (**► Table 2**), we have found an average age of 34 years old, with male patients ($n = 4$; 31%) with an average age of 23 years old (range: 17–31 years old), and female patients ($n = 9$; 69%) with an average age of 39 years old (range: 16–56 years old). Lesions affected more the medial femoral condyle compared with the lateral ($n = 11$; 85% versus $n = 2$; 15%) and the observed average size of the lesion was 1.8 cm² (0.6–4), 7 of which were > 2 cm². The average follow-up time of the patients was of 5.045 ± 3.47 years (range: 1.15–11.01 years). During the 1st year, none of the patients developed infections or complications in the donor site; 1 of the patients (female, 54 years old) was submitted to a total knee arthroplasty (TKA) 13 months after the mosaicplasty (6 years later, the TKA was revised). The average preoperative IKDC score was of 31.63 points (± 20.24), whereas the average postoperative IKDC score was of 74.18 points (± 20.26). The difference between

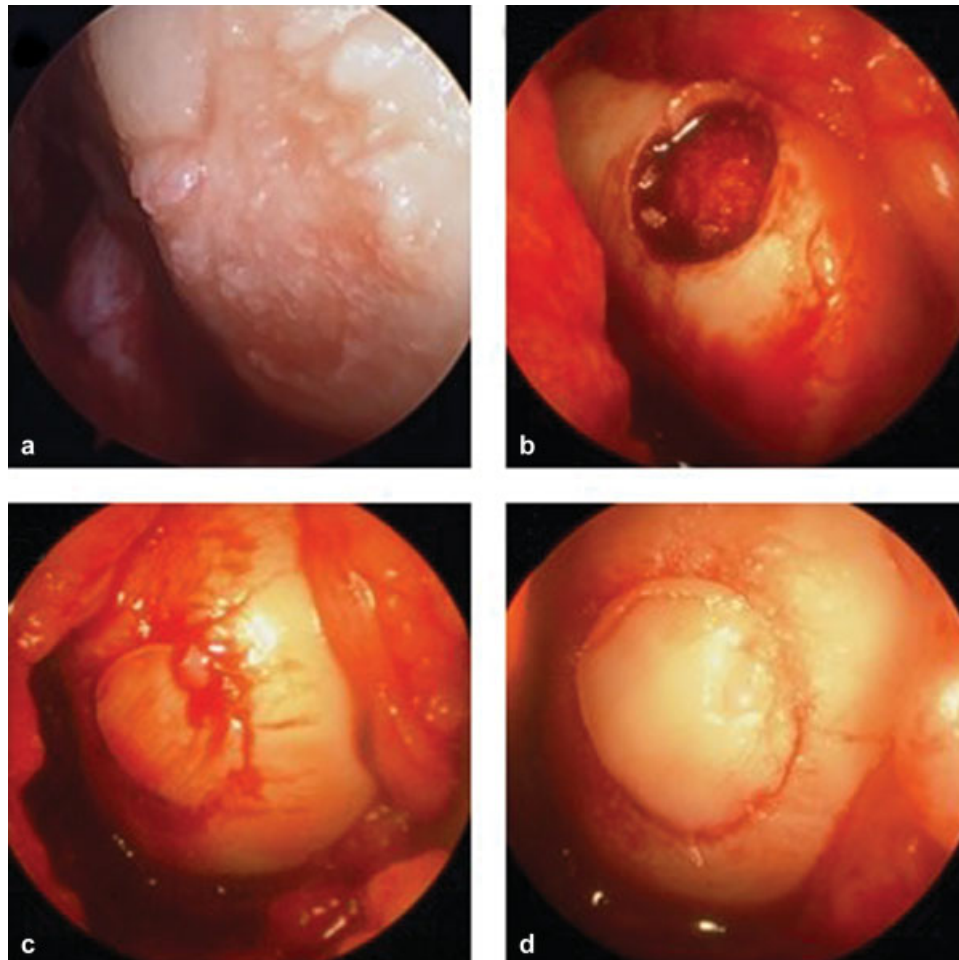
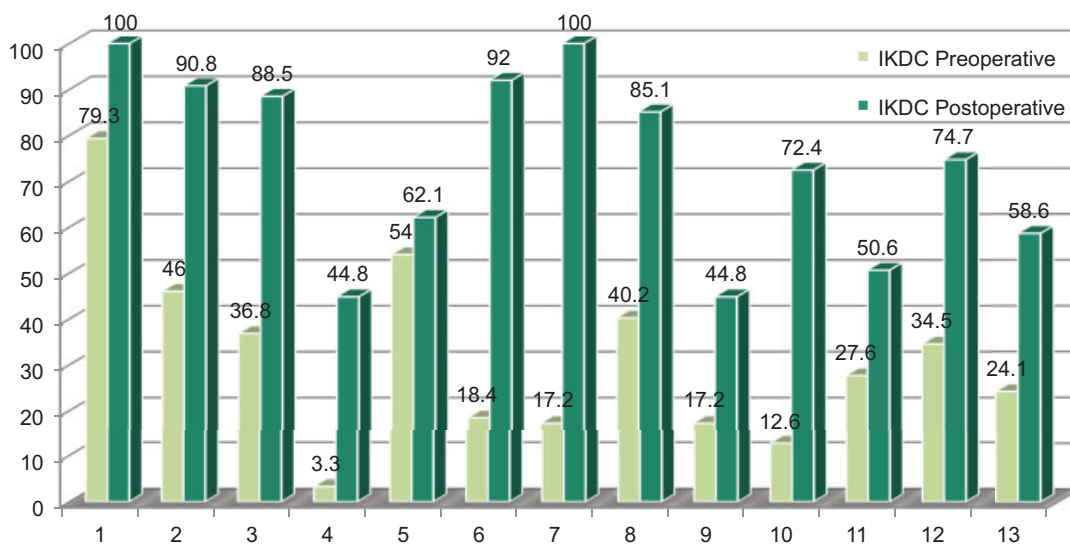


Fig. 1 Operative technique: (a) osteochondral lesion of the medial femoral condyle; (b) donor site - trochlear circumferential non-weight bearing area; (c) and (d) final repair.

Table 2 Patients included in the study group

n	Age (years)	Gender*	Localization**	Size (cm ²)	Preoperative IKDC	Postoperative IKDC	Follow-up (years)
1	25	M	MFC	1	79.3	100	3.00
2	16	F	MFC	3	46	90.8	11.01
3	16	F	LFC	4	36.8	88.5	11.01
4	17	M	MFC	2	3.3	44.8	8.01
5	54	F	MFC	1	54	62.1	6.79
6	18	M	MFC	3	18.4	92	4.00
7	36	F	MFC	2	17.2	100	2.00
8	30	F	LFC	1	40.2	85.1	3.00
9	42	F	MFC	0.6	17.2	44.8	2.36
10	48	F	MFC	2	12.6	72.4	1.15
11	56	F	MFC	0.9	27.6	50.6	2.78
12	31	M	MFC	1	34.5	74.7	7.97
13	53	F	MFC	2	24.1	58.6	2.51

Abbreviations: F, female; IKDC, International Knee Documentation Committee; LFC, lateral femoral condyle; M, male; MFC, medial femoral condyle.
 *gender:
 **localization.



Age	25	16	16	17	54	18	36	30	42	48	56	31	53
Gender	M	F	F	M	F	M	F	F	F	F	F	M	F
Localization	MFC	MFC	LFC	MFC	MFC	MFC	MFC	LFC	MFC	MFC	MFC	MFC	MFC
Size	1	3	4	2	1	3	2	1	0,6	2	0,9	1	2
Δ IKDC	20,7	44,8	51,7	41,5	8,1	73,6	82,8	44,9	27,6	59,8	23,0	40,2	34,1

Fig. 2 Results: graphic bar showing the preoperative and postoperative IKDC score for each patient of the study. Age and follow-up in years; Size in cm². Abbreviations: F, female; IKDC, International Knee Documentation Committee; LFC, lateral femoral condyle; M, male; MFC, medial femoral condyle. -Δ IKDC = post-operative IKDC – pre-operative IKDC.

the post- and preoperative IKDC scores was of 42.55 (± 21.05) points, being the minimal score increase of 8.1 points, and the maximum score increase of 82.8 points (► **Fig. 2**). A statisti-

cally significant difference ($p < 0.001$) was found between the IKDC scores before and after the surgery – paired samples Wilcoxon test (► **Fig. 3**). Statistically significant correlations

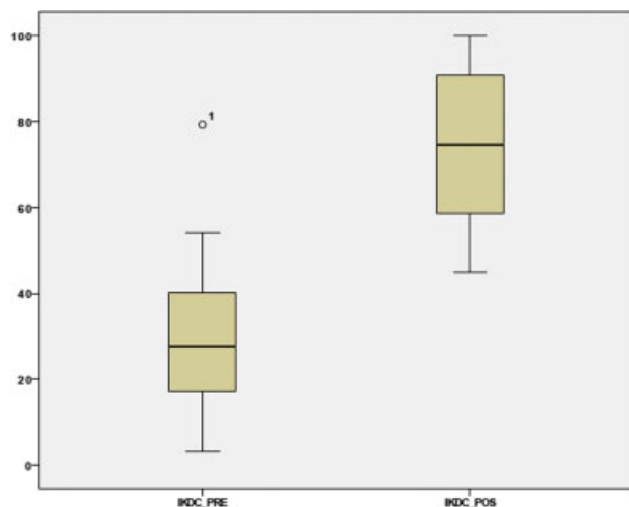


Fig. 3 Boxplot graphic showing preoperative and postoperative IKDC scores, using paired samples, nonparametric Wilcoxon test with IBM SPSS Statistics for Windows, Version 22.0— $p < 0.001$. Abbreviations: IKDC, International Knee Documentation Committee.

between the IKDC score and age or gender were not found. However, a statistically significant relation ($p = 0.038$) was found between the IKDC score increase (the difference between the postoperative and the preoperative scores) and the dimension of the lesion.

Discussion

The treatment of articular cartilage lesions comprises procedures of palliation (debridement and chondroplasty), repair (microfracture), and reconstruction (ACI, OTA, and OCA).^{2,4,10} Their application is driven by clinical and morphological criteria. According to the most recent literature reviews that discuss the treatment of osteochondral lesions of the knee, lesions with dimensions $< 2 \text{ cm}^2$ are best treated through microfracture (first-line option) or OTA.¹¹ The latter shows more longevity and durability of results, especially among high functional demand patients, when compared with microfractures.^{3,4} When lesions range from 2 to 4 cm^2 , they should be treated by OTA or by ACI.³ Regarding lesions with dimensions $\geq 4 \text{ cm}^2$, OTA morbidity is not neglectable, which is a reason why these should be approached with ACI or OCA (being the latter especially applied in extensive post-traumatic lesions or osteochondritis dissecans).³ Osteochondral autograft transfer, like other reconstructive techniques, confers good symptomatic and functional results and prevents the progression of degenerative changes. Moreover, it presents some advantages, such as its low cost, the absence of immunological reactions and of infectious transmission (when compared with OCA), and can be performed in a single surgical time.^{2,3,7-9} This procedure, when used in lesions ranging from 2 to 4 cm^2 , has more efficacy and durability; as shown in our study (which analyzed lesions up to these

dimensions), a correlation with statistical significance between the gain in IKDC scores and the lesion size can be made. The known complication rate is low, as observed in our study group. Results tend to be good in the medium to long term, being worse with increasing age, in females, and in greater size defects ($> 4 \text{ cm}^2$).^{2,3} The significant improvement in the IKDC score seen in our study, when comparing the pre- and postoperative status, is in line with other recent studies that use this or other functional evaluation scores.^{9,12,13}

Conclusion

Hyaline cartilage regeneration is not possible nowadays, and remains the greatest goal to be achieved in the treatment of osteochondral lesions. Mosaicplasty with OTA, when adequately used, can produce excellent results, with great durability and functional impact, low morbidity rates and costs. Although it has restricted indications, expansion of the criteria for its use has shown promising mid-term and long-term results, as shown in the recent literature.

Conflicts of Interests

The authors have no conflicts of interests to declare.

References

- 1 Curl WW, Krome J, Gordon ES, Rushing J, Smith BP, Poehling GG. Cartilage injuries: a review of 31,516 knee arthroscopies. *Arthroscopy* 1997;13(04):456–460
- 2 Berta Á, Duska Z, Tóth F, Hangody L. Clinical experiences with cartilage repair techniques: outcomes, indications, contraindications and rehabilitation. *Eklek Hastalik Cerrahisi* 2015;26(02): 84–96
- 3 Krych AJ, Harnly HW, Rodeo SA, Williams RJ III. Activity levels are higher after osteochondral autograft transfer mosaicplasty than after microfracture for articular cartilage defects of the knee: a retrospective comparative study. *J Bone Joint Surg Am* 2012;94 (11):971–978
- 4 Gudas R, Kalesinskas RJ, Kimtys V, Stankevicius E, Toličius V, Bernotavicius G, et al. A prospective randomized clinical study of mosaic osteochondral autologous transplantation versus microfracture for the treatment of osteochondral defects in the knee joint in young athletes. *Arthroscopy* 2005;21(09):1066–1075
- 5 Smith GD, Knutsen G, Richardson JB. A clinical review of cartilage repair techniques. *J Bone Joint Surg Br* 2005;87(04): 445–449
- 6 Bedi A, Feeley BT, Williams RJ 3rd. Management of articular cartilage defects of the knee. *J Bone Joint Surg Am* 2010;92(04): 994–1009
- 7 Hangody L, Kish G, Kárpáti Z, Szerb I, Udvarhelyi I. Arthroscopic autogenous osteochondral mosaicplasty for the treatment of femoral condylar articular defects. A preliminary report. *Knee Surg Sports Traumatol Arthrosc* 1997;5(04): 262–267
- 8 Hangody L, Füles P. Autologous osteochondral mosaicplasty for the treatment of full-thickness defects of weight-bearing joints: ten years of experimental and clinical experience. *J Bone Joint Surg Am* 2003;85-A(Suppl 2):25–32
- 9 Hangody L, Dobos J, Baló E, Pánics G, Hangody LR, Berkes I. Clinical experiences with autologous osteochondral mosaicplasty in an

- athletic population: a 17-year prospective multicenter study. *Am J Sports Med* 2010;38(06):1125–1133
- 10 McNickle AG, Provencher MT, Cole BJ. Overview of existing cartilage repair technology. *Sports Med Arthrosc Rev* 2008;16(04):196–201
 - 11 Richter DL, Schenck RC Jr, Wascher DC, Treme G. Knee Articular Cartilage Repair and Restoration Techniques: A Review of the Literature. *Sports Health* 2016;8(02):153–160
 - 12 Solheim E, Hegna J, Øyen J, Harlem T, Strand T. Results at 10 to 14 years after osteochondral autografting (mosaicplasty) in articular cartilage defects in the knee. *Knee* 2013;20(04):287–290
 - 13 Reverte-Vinaixa MM, Joshi N, Diaz-Ferreiro EW, Teixidor-Serra J, Dominguez-Oronoz R. Medium-term outcome of mosaicplasty for grade III-IV cartilage defects of the knee. *J Orthop Surg (Hong Kong)* 2013;21(01):4–9