

# A Baby Feeding Nipple: Simple, Cost effective, and Safe Technique for Removal of Denture

Gaurav Kumar Gupta<sup>1</sup> Atul Gawande<sup>1</sup> Deepak Sharma<sup>1</sup> Sandeep Nijhawan<sup>1</sup>

<sup>1</sup>Department of Gastroenterology, SMS Medical College and Hospital, Jaipur, Rajasthan, India

**Address for correspondence** Dr. Gaurav Kumar Gupta, MD, DM  
Department of Gastroenterology, SMS College and Hospital, Jaipur,  
Rajasthan, India (e-mail: kumarggauravpgi@gmail.com).

J Digest Endosc 2019;10:126–129

## Abstract

**Introduction** Denture ingestion occurs commonly in the elderly and frequently impacted in the esophagus due to the sharp edges. This can lead to serious complications such as perforation. We are describing here a simple, cost effective and safe technique for removal of dentures.

**Material and methods** We used a handmade hood protector made from baby feeding nipple with rat-toothed forceps to safely remove ingested denture in two middle aged patients. Both patients had subcutaneous emphysema.

**Results** Dentures were removed successfully in both patients. Following denture removal, endoscopic examination of the esophagus did not show any sign of mucosal damage, ulceration, bleeding, or perforation.

**Conclusion** We successfully and safely removed denture from the stomach using handmade hood designed from a baby feeding tube. It may be beneficial for wide visual field and safety. It is an easy, effective, and safe design for the removal of sharp foreign bodies like dentures.

## Keywords

- ▶ baby feeding nipple
- ▶ denture
- ▶ endoscope

## Introduction

Foreign body ingestion is a common problem a gastroenterologist faces in his day-to-day practice. Most of the denture ingestion occurs in elderly because of the reduced sensation of oral mucosa and reduced motor control of laryngopharynx.<sup>1</sup> Dentures are frequently impacted in the esophagus due to the sharp edges. Accidentally, ingested dentures can lead to serious complications in gastrointestinal tract such as perforation.<sup>2</sup> Therefore, early detection and management are most important to prevent serious complications.

## Patients and Methods

### Case 1

A 50-year-old hypertensive man came with a history of alleged ingestion of denture while taking his antihypertensive medication. After that patient developed pain in the throat after which he visited the private hospital and underwent X-ray neck and X-ray upper abdomen. Upper gastrointestinal

endoscopy was done on the next day. On endoscopy the denture was seen in stomach and removal of denture was tried but it was a failed attempt. On the same day of the procedure, the patient developed swelling over the neck with dyspnea and dysphagia to both solids and liquids; after that he was referred to our center. On examination, the patient had crepitations over bilateral cervical and infraclavicular region with no signs of peritoneal irritation. X-ray chest and upper abdomen was done in our institute which showed subcutaneous emphysema in the cervical region and artificial dentures wires were seen in the stomach. Ryles tube was placed, and the patient was managed conservatively. Patient's emphysema got resolved on the third day of admission to our center. Gastroscopy was planned on the fourth day of admission.

### Case 2


A 50-year-old man came with a history of denture ingestion followed by pain during swallowing and chest pain. On next day patient visited our institute. On examination, his vitals were stable, and the patient had subcutaneous emphysema

over bilateral neck region. He underwent X-ray chest and abdomen which showed wires of the denture in mid esophagus. Upper gastrointestinal endoscopy was planned on the same day which showed impacted denture in the mid esophagus. Initially, the denture was disimpacted into the stomach with the snare.

In both patients, rat-toothed forceps could not be used for denture removal because of their sharp edges having risk of injury to mucosa and perforation. Hence, baby feeding nipple was used to prevent trauma to the mucosa. A hand-made hood protector was designed from baby feeding nipple (Bonny Baby-Care Pvt. Ltd., Noida, Uttar Pradesh, India). It is made up of liquid silicon. The narrow part of the nipple was cut 5 mm from its blunt end. After cutting it has an internal diameter of 9 mm and an external diameter of 11 mm (►Fig. 1). It is made up of liquid silicon. The hood was fastened to the distal end of the endoscope (GIF-Q150; Olympus Corporation, Tokyo, Japan) which was 9.2 mm in diameter, with the help leukoplast adhesive (►Fig. 2). The wide base of the nipple which was used to cloak the denture has the diameter of 23 mm (►Fig. 3). The length of impacted denture was 35 mm (►Fig. 4). The endoscopy was done under conscious sedation with 2 mg of midazolam (1 mg/mL injected over 1 minute and given 5 minutes before the procedure) in both patients. Initially, feeding nipple was retracted over endoscope before insertion of scope in the mouth. After insertion of scope in stomach rat-toothed forceps was inserted through the biopsy channel of endoscope and denture was grasped by its edge by rat-toothed forceps then the forceps was withdrawn keeping endoscope in its position up to the tip of endoscope (►Fig. 5). Then, the endoscope



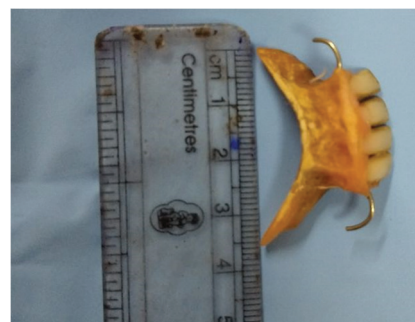
**Fig. 1** The narrow part of nipple was cut at 5 mm from end with internal diameter and external diameter 9 mm and 11 mm, respectively.



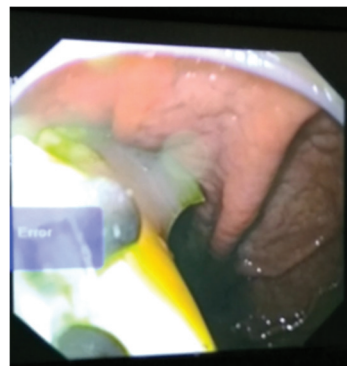
**Fig. 2** Baby feeding nipple fastened endoscope with the help of leukoplast adhesive.



**Fig. 3** Diameter of wide base of feeding nipple.



**Fig. 4** Length of denture.



**Fig. 5** Endoscopic image. Denture in the stomach grasped by rat toothed forceps. Denture not inside the hood.

was withdrawn. Wide neck of the nipple has smooth circular edge which helps nipple to revert in its normal position during removal of the scope due to the mechanical effect of the gastroesophageal junction. After reversion of nipple, the hood of nipple well covered most of the part of the denture and also the edge of the wide neck of nipple keeps the mucosa away from remaining part of denture which remains outside the hood, thus preventing any injury to the mucosa of the esophagus (►Figs. 6 and 7).

## Results

Following denture removal, endoscopic examination of the esophagus did not show any sign of mucosal damage, ulceration, bleeding, or perforation. The complete endoscopic procedure took only 18 minutes in the first case and 15 minutes in

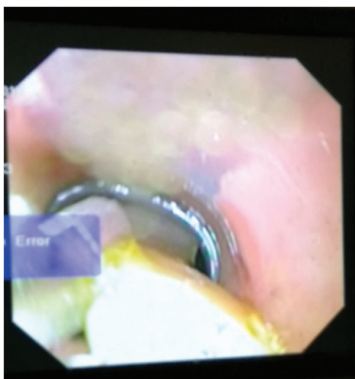


Fig. 6 Endoscopic image. Denture inside hood seen in esophagus.

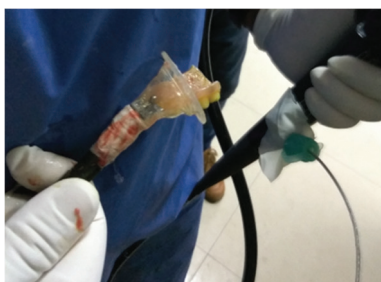

Fig. 7 Denture inside nipple hood after procedure.

the second case. After procedure, both patients did not develop subcutaneous emphysema, and they were hemodynamically stable. Postprocedural patients were kept under observation. The first patient and the second patient were discharged in stable condition on the next day and same day, respectively.

## Discussion

Coins are the most common foreign body ingestion in children while denture ingestion is more common in the elderly.<sup>1</sup> About 70% of denture impaction occurs in the esophagus. The incidence of denture impaction varies from 0.4 to 17.6%.<sup>3,4</sup> The physiological constrictions of the esophagus are an important cause of denture impaction, the commonest site of impaction is cricopharyngeal sphincter. Following denture ingestion, the most common symptom is dysphasia. The other clinical features are hypersalivation, retrosternal fullness, regurgitation of undigested food, and odynophagia.<sup>5</sup> Sharp hooks likely damage esophageal mucosa during endoscopic removal. Therefore, many authors recommend surgical removal over the endoscopic removal of sharp dentures.<sup>1,6,7</sup> However, denture ingestion is more common in old age which itself increases chances of morbidity and mortality in these patients. Furthermore, it increases the hospital stay of patients. Hence, there was always a need for endoscopic management of these patients. In a retrospective analysis, endoscopic and colonoscopic removal of denture using distal attachment over scope was successful in 92% and 100%, respectively.<sup>8</sup> Endoscopic removal of dentures is associated with favorable success rate and outcome with less morbidity and mortality and early hospital discharge. There are various handmade and commercial devices available for removal of

sharp foreign bodies such as overtube, a latex protector hood, latex glove, and condom.<sup>9-12</sup>

To the best of our knowledge, these are the first reported cases of removal of the sharp foreign body using baby feeding nipple. The liquid silicon material makes it more transparent and has more tensile strength. Furthermore, the diameter of the wide neck of the nipple is 23 mm which gives a better field of vision and its bell shape design leads to self-dilatation of tight upper esophageal sphincter which leads to easy removal of hood and denture. This device produces little discomfort to the patient as the hood is retracted over scope during insertion of scope through the upper esophageal sphincter. Preparation of this device is easy as it required only cutting of narrow end of the baby feeding tube and fitting it to the end of the endoscope. Although commercial devices are simple to use,<sup>10</sup> they are costly and not available in all medical institutions, especially in developing countries like India. The baby feeding nipple is inexpensive, widely available, and easy to use. We have also used this device for removal of an ingested razor blade, and a safety pin in the past.

## Conclusion

We successfully and safely removed denture from stomach using handmade hood designed from a baby feeding tube. It may be beneficial for wide visual field and safety. It is an easy, effective, and safe design for removal of sharp foreign bodies like dentures.

### Financial Support and Sponsorship

Nil.

### Conflicts of Interest

None.

## References

- 1 Toshima T, Morita M, Sadanaga N, et al. Surgical removal of a denture with sharp clasps impacted in the cervicothoracic esophagus: report of three cases. *Surg Today* 2011;41(9):1275-1279
- 2 Rohida NS, Bhad WA. Accidental ingestion of a fractured Twin-block appliance. *Am J Orthod Dentofacial Orthop* 2011;139(1):123-125
- 3 Nandi P, Ong GB. Foreign body in the oesophagus: review of 2394 cases. *Br J Surg* 1978;65(1):5-9
- 4 Bandyopadhyay SN, Das S, Das SK, Mandal A. Impacted dentures in the oesophagus. *J Laryngol Otol* 2014;128(5):468-474
- 5 Singh P, Singh A, Kant P, Zonunsanga B, Kuka AS. An impacted denture in the oesophagus-an endoscopic or a surgical emergency-a case report. *J Clin Diagn Res* 2013;7(5):919-920
- 6 Chua YK, See JY, Ti TK. Oesophageal-impacted denture requiring open surgery. *Singapore Med J* 2006;47(9):820-821
- 7 Dalvi AN, Thapar VK, Jagtap S, et al. Thoracoscopic removal of impacted denture: report of a case with review of literature. *J Minim Access Surg* 2010;6(4):119-121
- 8 Mizuno KI, Takahashi K, Tominaga K, et al. Endoscopic removal of ingested dentures and dental instruments: a retrospective analysis. *Gastroenterol Res Pract* 2016;2016:3537147
- 9 Seo YS, Park JJ, Kim JH, et al. Removal of press-through-packs impacted in the upper esophagus using an overtube. *World J Gastroenterol* 2006;12(36):5909-5912

- 10 Bertoni G, Sassatelli R, Conigliaro R, Bedogni G. A simple latex protector hood for safe endoscopic removal of sharp-pointed gastroesophageal foreign bodies. *Gastrointest Endosc* 1996;44(4):458-461
- 11 Kao LS, Nguyen T, Dominitz J, Teicher HL, Kearney DJ. Modification of a latex glove for the safe endoscopic removal of a sharp gastric foreign body. *Gastrointest Endosc* 2000;52(1):127-129
- 12 Lin LF. Condoms used to assist difficult endoscopic removal of impacted upper esophageal foreign bodies. *Adv Dig Med* 2016;3:24-27