



Delayed Onset Abducens Nerve Palsy following Uncomplicated Large Cystic Vestibular Schwannoma Resection: Case Report

Sima Sayyahmelli¹ Pinar Aydin¹ Mustafa K. Baskaya¹

¹Department of Neurological Surgery, University of Wisconsin Medical School, Madison, Wisconsin, United States

Address for correspondence Mustafa K. Baskaya, MD, Department of Neurological Surgery, University of Wisconsin Medical School, K4/834 CSC, 600 Highland Avenue, Madison, WI 53792-0001, United States (e-mail: baskaya@neurosurgery.wisc.edu).

J Neurol Surg Rep 2019;80:e37–e40.

Abstract

Although delayed facial palsy after vestibular schwannoma (VS) surgery is a poorly understood but a well-known phenomenon, other delayed cranial nerve palsies in the cerebellopontine angle have not been reported after VS surgery. In this report, we describe a 54-year-old woman with a large cystic VS who experienced double vision and a new delayed onset right abducens nerve (AbN) palsy, 3 weeks after gross total resection of VS via a translabyrinthine approach. To the best of our knowledge, this is the first report describing delayed isolated AbN palsy after uncomplicated VS surgery. Magnetic resonance imaging findings and the management of this complication following VS surgery are discussed in this case report.

Keywords

- ▶ abducens nerve
- ▶ acoustic canal
- ▶ delayed onset
- ▶ vestibular schwannoma

Introduction

Large vestibular schwannoma (VS) can cause considerable brain stem and adjacent cranial nerves compression that increases surgery-related morbidity and mortality rates.¹ Delayed facial palsy (DFP) is a well-known phenomenon that has been reported to occur in 15 to 29% of patients undergoing VS resections.² However, the exact etiology and mechanism of DFP remain unknown.³

In spite of being very rare, abducens nerve (AbN) palsy can occur as an early onset and transient complication after VS surgery and carries significant morbidity.¹

We describe a 54-year-old woman with a large cystic VS, who experienced double vision and delayed onset right AbN palsy 3 weeks following translabyrinthine resection surgery. To the best of our knowledge, this is the first report describing delayed isolated AbN palsy after uncomplicated VS surgery.

Case Report

A 54-year-old woman with a 1-year history of imbalance, dizziness, and difficulty in word discrimination presented in the neurosurgery clinic. Magnetic resonance imaging (MRI)

showed an approximately 6 cm, large cystic right cerebellopontine angle mass with extension into the internal acoustic canal. There was also a significant amount of brain stem and fourth ventricle compression with early signs of hydrocephalus (–Fig. 1A, B).

The patient underwent gross total resection using a translabyrinthine approach. The surgery was uneventful. Postoperative MRI confirmed gross total resection (–Fig. 2A, B). Per the routine protocol, she received steroids and valacyclovir for 10 days in the postoperative period. Her facial nerve function was House–Brackmann grade II immediately after the surgery. Other cranial nerves, except right-sided hearing loss which existed before surgery, were intact, and she did not experience any subjective double vision after surgery.

Three weeks after surgery, her facial nerve function had improved to House–Brackmann grade I. However, she reported having double vision and had a new AbN palsy on the right side. Her other cranial nerve functions remained intact except hearing loss on the right side, which had existed before surgery. MRI showed a persistent edema within the right middle cerebellar peduncle that was present in both the pre- and immediate postoperative MRIs (–Fig. 3A, B). MRI

received
November 30, 2018
accepted after revision
June 18, 2019

DOI <https://doi.org/10.1055/s-0039-1694737>.
ISSN 2193-6358.

© 2019 Georg Thieme Verlag KG
Stuttgart · New York

License terms



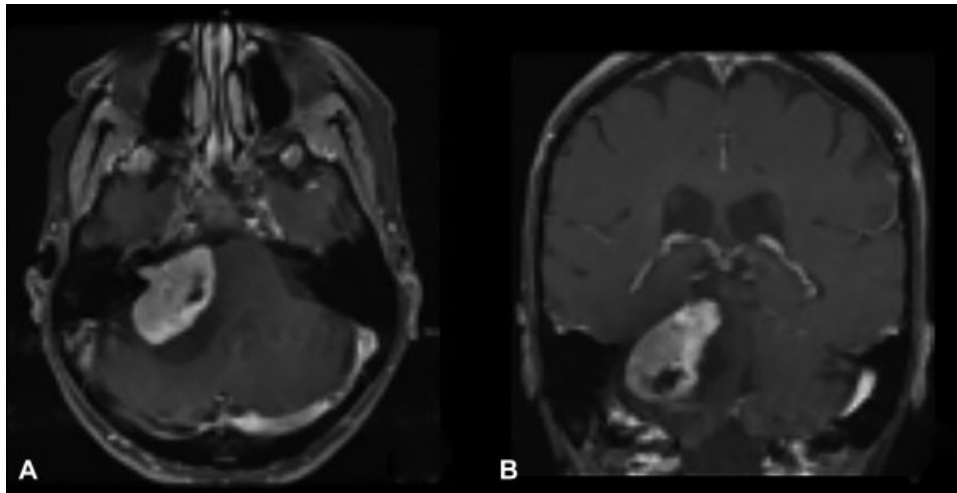


Fig. 1 Preoperative post-contrast axial (A) and coronal (B) T1-weighted MRIs show an approximately 6 cm, large cystic right cerebellopontine angle mass with extension into the internal acoustic canal. Note brain stem and fourth ventricle compression with the early signs of hydrocephalus. MRI, magnetic resonance imaging.

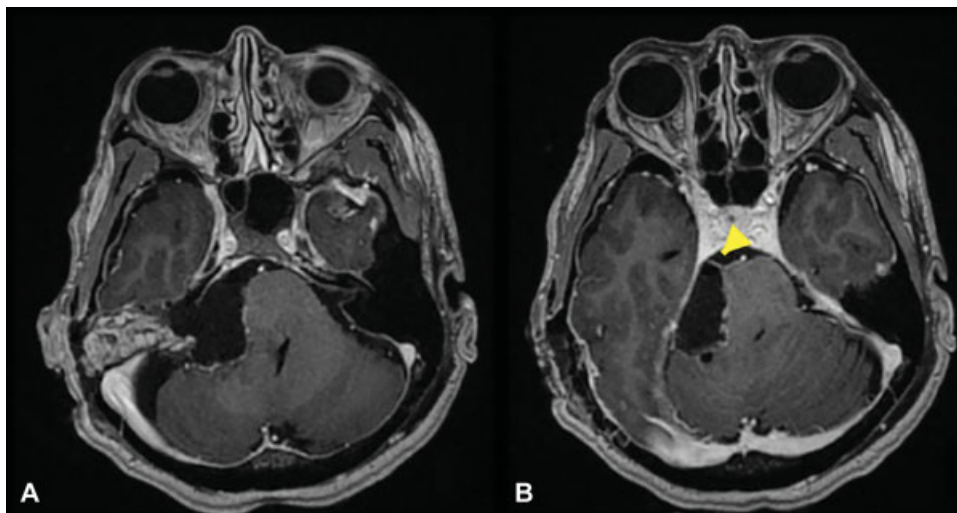


Fig. 2 Postoperative post-contrast axial (A, B) T1-weighted MRIs confirmed gross total resection without any enlargement or abnormal enhancement of the right trigeminal nerve and AbN (yellow arrowhead). AbN, abducens nerve; MRI, magnetic resonance imaging.

also showed a mild abnormal enhancement of the right trigeminal nerve and AbN (► **Fig. 3C, D**). Oral dexamethasone and valacyclovir were then restarted for an additional 2 weeks. Her reported double vision at 3 weeks after surgery and delayed onset AbN palsy on the right side (► **Fig. 4A**) were completely improved (► **Fig. 4B**). At a 3-year follow-up, the patient remained tumor free with normal cranial nerve function, except for her prior right-sided hearing loss.

Discussion

DFP generally occurs between 4 and 30 days after VS surgery⁴ where there is otherwise complete or near-complete recovery of facial nerve function.³ Since the role of viral reactivation as a cause of some portions of DFP was elucidated, some studies⁵ have advocated for the use of perioperative famciclovir, which has been reported to reduce the incidence of DFP from 25% in the control group to 20%.

In addition to the risk of injury to the seventh and eighth cranial nerves, other cranial nerve deficits may also occur in the patients with a large VSs. Immediate AbN palsy was present in 4% of a series of giant VSs resections published by Samii et al.¹ However, delayed AbN palsy after VS surgery has not been reported previously. To the best of our knowledge, this is the first report describing delayed isolated AbN palsy after uncomplicated VS surgery, although there is a case report of delayed isolated AbN palsy following uncomplicated microvascular decompression for hemifacial spasm.⁶ Further research is needed to clarify the etiology of these delayed cranial nerve palsies.

The correlation between the postoperative enhancement of the cranial nerves and the onset of new cranial nerve deficits has not been evaluated in the literature. In the case presented here, a slight contrast enhancement of the AbN and the trigeminal nerves, with enlargement of both nerves, was noted on the postoperative 3-week MRI (► **Fig. 3C, D**). Although it is

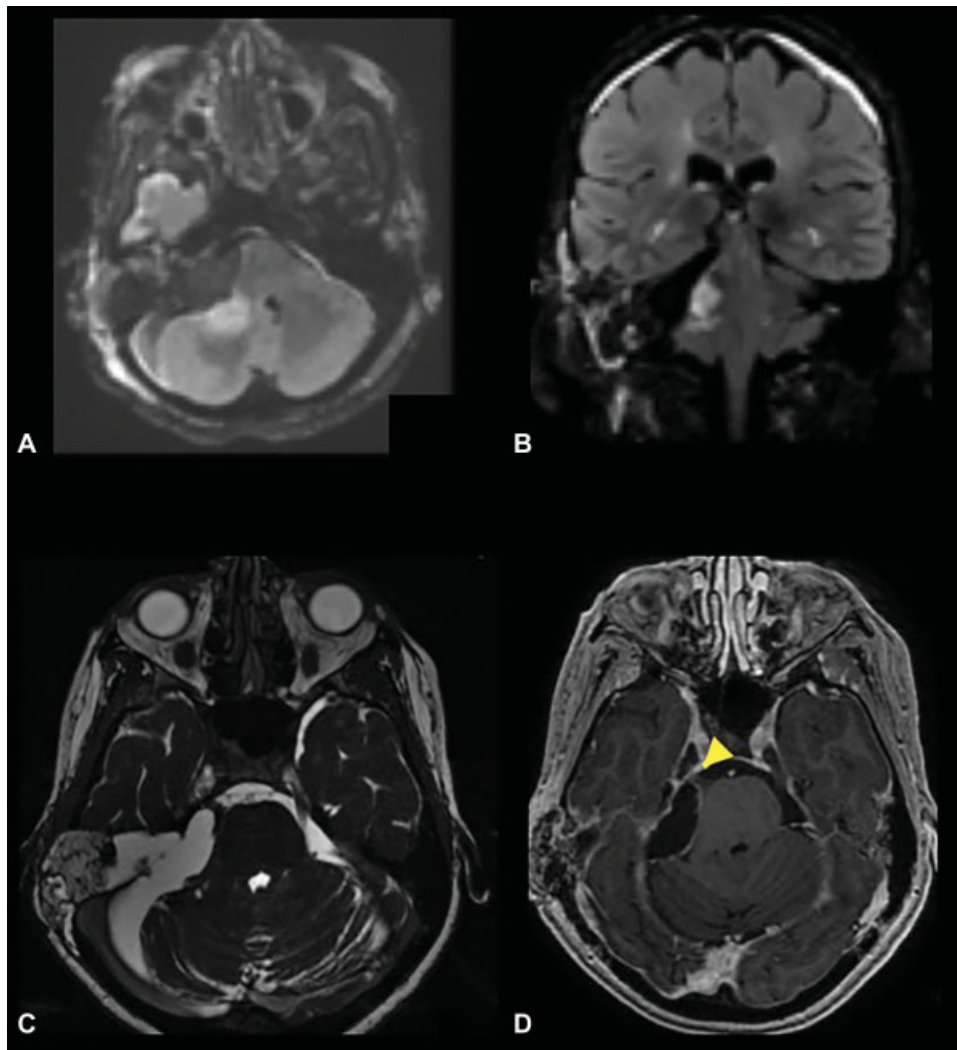


Fig. 3 Postoperative postcontrast axial (A) and coronal (B) T1-weighted MRIs show persistent edema within the right middle cerebellar peduncle and mild enlargement (C) and abnormal enhancement (D) of the right trigeminal nerve and AbN (yellow arrowhead). AbN, abducens nerve; MRI, magnetic resonance imaging.

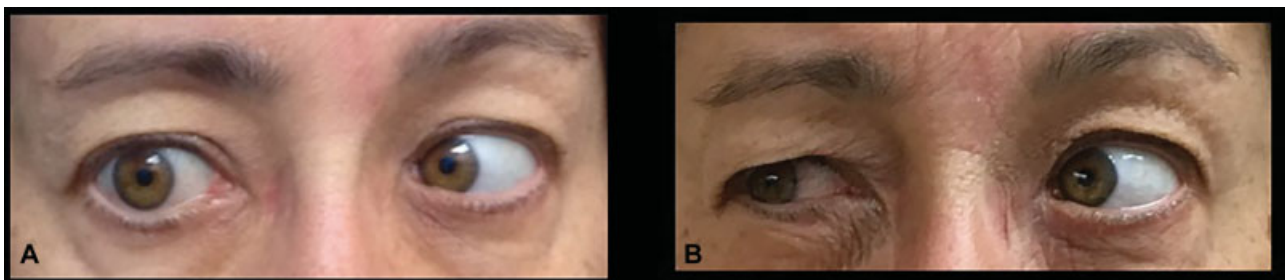


Fig. 4 Three weeks after surgery, the examination of the extraocular eye movements showed a new-onset AbN palsy on the right side (A). At 3-year follow-up, the patient remains without recurrence of VS and the examination of the extraocular eye movements showed completely improvement of AbN function (B). AbN, abducens nerve; VS, vestibular schwannoma.

difficult to elucidate the clinical significance of these radiological findings, these observations were only correlated with the AbN and not with the trigeminal nerve. Vulnerability of the AbN has been attributed to the angulation points of the nerve and not to its long intracranial course.⁷

We hypothesize that asymptomatic trigeminal nerve involvement can be attributed to different symptomatic thresholds between the trigeminal nerve and the AbN for the same

pathologic process. It is also possible that subtle facial sensory deficits related to trigeminal nerve involvement could be present, which could not be elucidated by neurological examination.

Conclusion

Delayed isolated AbN palsy following uncomplicated VS surgery is an extremely rare complication, and to the best of our

knowledge, this is the first report describing this complication. Although the etiology and the best management options for DFP are still unknown, surgeons should keep the possibility of delayed isolated AbN palsy after uncomplicated VS surgery in mind. Steroids along with valacyclovir, as recommended in DFP, might be used to treat delayed AbN palsy after VS surgery.

Disclosure of Funding

None.

Conflict of Interest

None.

References

- 1 Samii M, Gerganov VM, Samii A. Functional outcome after complete surgical removal of giant vestibular schwannomas. *J Neurosurg* 2010;112(04):860–867
- 2 Sampath P, Rhines LD, Holliday MJ, Brem H, Long DM. Late-onset facial nerve degeneration after vestibular schwannoma surgery: incidence, putative mechanisms, and prevention. *Neurosurg Focus* 1998;5(03):e6
- 3 Morton RP, Ackerman PD, Pisansky MT, et al. Prognostic factors for the incidence and recovery of delayed facial nerve palsy after vestibular schwannoma resection. *J Neurosurg* 2011;114(02):375–380
- 4 Grant GA, Rostomily RR, Kim DK, et al. Delayed facial palsy after resection of vestibular schwannoma. *J Neurosurg* 2002;97(01):93–96
- 5 Brackmann DE, Fisher LM, Hansen M, Halim A, Slattery WH. The effect of famciclovir on delayed facial paralysis after acoustic tumor resection. *Laryngoscope* 2008;118(09):1617–1620
- 6 Han JS, Lee JA, Kong DS, Park K. Delayed cranial nerve palsy after microvascular decompression for hemifacial spasm. *J Korean Neurosurg Soc* 2012;52(04):288–292
- 7 Yaman ME, Ayberk G, Eylen A, Ozveren MF. Isolated abducens nerve palsy following lumbar puncture: case report and review of the mechanism of action. *J Neurosurg Sci* 2010;54(03):119–123