

Median Nerve Parachordoma Masquerading Schwannoma: An Uncommon Case

Sumit Bansal¹ Pritinanda Mishra² Mamita Nayak² Rabi Sahu¹ Ashis Patnaik¹

¹Department of Neurosurgery, All India Institute of Medical Sciences, Bhubaneswar, Orissa, India

²Department of Pathology and Lab Medicine, All India Institute of Medical Sciences, Bhubaneswar, Orissa, India

Indian J Neurosurg 2019;8:145–146

Benign tumors involving peripheral nerves of the upper extremity are uncommon. An entrapment syndrome resulting from the growing tumor causes symptoms. Pain is the most common complaint. We present a rare case of a median nerve parachordoma, a rare type of a benign tumor that presents as a palpable and painful mass on the flexor aspect of the forearm.

A 62-year-old woman presented with a painful swelling at the flexor aspect of the right forearm. On clinical examination, there was a painful solid mass, which was 2 cm in length, little sensitive to pressure, and had mobility restriction in both transverse and longitudinal directions. Percussion over the mass produced a Tinel's-like sensation along the median nerve. The patient experienced mild numbness in the distribution of the median nerve in the palm, but no motor weakness or muscle atrophy was noticed.

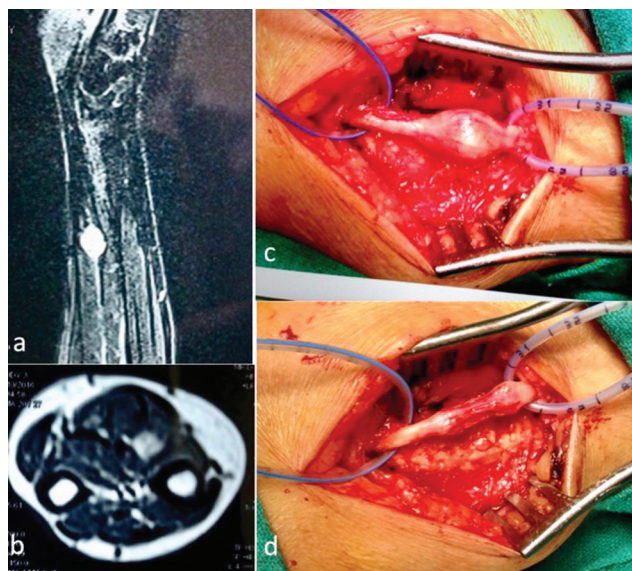


Fig. 1 MRI examination of right forearm showed contrast-enhancing lesion deep to the flexor tendon of forearm (a, b). The tumor was arising from the median nerve in the right forearm, below the flexor tendon of forearm (c). The mass was encapsulated and removed totally (d).

Address for correspondence Sumit Bansal, MCh, Assistant Professor, Room No. 419, Department of Neurosurgery, All India Institute of Medical Sciences, Bhubaneswar, Orissa 751019, India (e-mail: drsumitbansal@gmail.com).

On magnetic resonance imaging (MRI) examination, lesion had a relatively homogenous low signal, slightly lower to the flexor tendon of the forearm, on T1-weighted images. On T1 fat-suppressed contrast images, increased gadolinium enhancement was noticed (►Fig. 1a, b). Based on the clinical and MRI features, provisional diagnosis of a nerve sheath tumor arising from the median nerve was made.

A longitudinal incision centered over the tumor bulk at the distal part of flexor aspect of right forearm was performed. Adequate exposure of the nerve was done, both proximal and distal to the tumor. On exploration, the tumor was found to arise from the median nerve in the right forearm, below the flexor tendon. The tumor had an eccentric position and was firmly attached to the median nerve. The epineurium was longitudinally incised, and the soft tumor mass was dissected from surrounding nerve fascicles. The mass was encapsulated and removed completely (►Fig. 1c, d). Postoperative course was uneventful with no new neurologic deficit. The histopathology report was suggestive of parachordoma (►Fig. 2). At 1-month follow-up, the wound was healed with no new symptoms.

Parachordomas (or myoepitheliomas) are rare soft tissue tumors with approximately 100 cases reported,¹ with

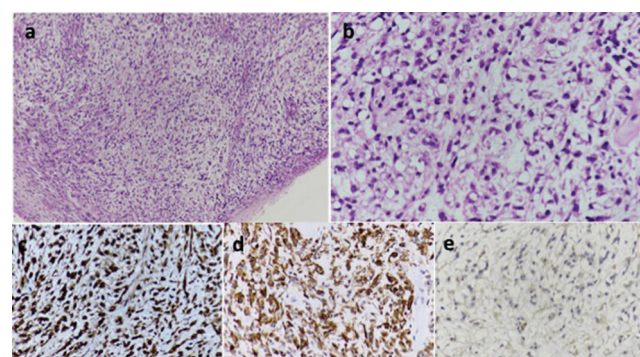


Fig. 2 (a) Epithelioid cells and spindle cells lying in myxoid stroma (H&E 100X). (b) Epithelioid cells with clear cytoplasm (H&E 400X). (c–e) Tumor cells are immunopositive for S-100, cytokeratin, and negative for P53 (IHC 400X).

received
July 25, 2017
accepted after revision
November 22, 2017
published online
August 23, 2019

DOI <https://doi.org/10.1055/s-0039-1694840>
ISSN 2277-954X.

©2019 Neurological Surgeons'
Society of India

License terms



Table 1 Published literature of upper limb parachordoma cases

Case No.	Age (y)	Sex	Site	Recurrence	Metastasis	Fatal	Authors (y)
1	12	Male	Arm	No	No	No	Dabska (1977)
2	22	Female	Forearm	No	No	No	
3	28	Female	Finger	2 y	No	No	
4	25	Male	Finger	Unknown	Unknown	No	Sanguenza and White (1994)
5	45	Female	Palm	3 mo	No	No	Niezabitowski et al. (1995)
6	25	Female	Triceps	No	No	No	Fisher and Miettinen (1997)
7	14	Male	Wrist	Unknown	Unknown	No	
8	25	Female	Forearm	Yes	No	No	Imlay et al. (1998)
9	42	Female	Forearm	No	No	No	Folpe et al. (1999)
10	38	Male	Deltoid	No	No	No	
11	20	Female	Hand	No	No	No	Separovic et al. (2001)
12	60	Female	Arm	No	No	No	Clabeaux et al. (2008)
13	6	Female	Forearm	No	Yes	No	Guedes et al. (2009)
14	76	Male	Hand	2 y	No	No	Bell et al. (2009)
15	31	Male	Wrist	1 mo	No	No	Fulciniti et al. (2011)
16	67	Female	Arm	No	Yes	No	De Comas et al. (2011)
17	28	Male	Shoulder	1 y	Unknown	No	Karakaya et al. (2011)
18	44	Male	Index finger	No	No	No	Ali et al. (2012)
19	32	Male	Arm	No	No	No	Estrems Diaz et al. (2013)

19 cases in upper limbs till date^{2,3} (► **Table 1**). They have an indolent nature with a male predilection, typically occurring in the fourth decade of life and usually in the extremities.² There have been reports regarding late recurrence and metastasis.⁴ Parachordoma was originally believed to be a chordoma occurring in nonaxial sites, but now it is considered as a unique entity.⁵ The management for these lesions is wide surgical excision, with clinical and imaging follow-up to exclude recurrence.

Other differential diagnosis was schwannoma, which is more commonly seen than parachordoma. They are usually solitary and benign lesions. Schwannomas can be asymptomatic or can produce pain, a positive Tinel's sign or a Tinel's-like sensation, and sensory symptoms. The slow growth pattern of benign nerve tumors allows for adaptation of the nerve function to the pressure effects.⁶ Schwannomas share many features with other soft tissue tumors and are frequently misdiagnosed due to similarities.

Tumors of the median nerve are diagnostically challenging and median nerve parachordoma is rare as compared with schwannoma. The diagnosis is made only through histopathology. Parachordoma should be included in differential diagnosis of soft tissue tumor arising in the forearm, especially arising from the median nerve.

Financial Support

None.

Conflicts of Interest

None.

References

- De Comas AM, Deavers MT, Raymond AK, Madewell JE, Lewis VO. Intra-neural parachordoma of the arm with regional metastases. *Skeletal Radiol* 2011;40(7):943–946
- Clabeaux J, Hojnowski L, Valente A, Damron TA. Case report: parachordoma of soft tissues of the arm. *Clin Orthop Relat Res* 2008;466(5):1251–1256
- Gao HX, Liu CX, Zou H, et al. Parachordoma/myoepithelioma of the kidney: first report of a myxoid mimicry in an unusual location. *Int J Clin Exp Pathol* 2014;7(3):1258–1265
- Fisher C, Miettinen M. Parachordoma: a clinicopathologic and immunohistochemical study of four cases of an unusual soft tissue neoplasm. *Ann Diagn Pathol* 1997;1(1):3–10
- Kinoshita G, Yasoshima H. Fatal parachordoma. *J Orthop Sci* 2007;12(1):101–106
- Ogose A, Hotta T, Morita T, et al. Tumors of peripheral nerves: correlation of symptoms, clinical signs, imaging features, and histologic diagnosis. *Skeletal Radiol* 1999;28(4):183–188