

# Review of Bladder Pain and Referred T12–L2 Input as One Etiology for Interstitial Cystitis

A. Lee Dellon, MD, PhD<sup>1</sup> Amin S. Herati, MD<sup>2</sup>

<sup>1</sup>Department of Plastic Surgery and Neurosurgery, Johns Hopkins University, Baltimore, Maryland

<sup>2</sup>Department of Urology, Johns Hopkins University, Baltimore, Maryland

Address for correspondence A. Lee Dellon, MD, PhD, Department of Plastic Surgery and Neurosurgery, Johns Hopkins University, 1122 Kenilworth Dr., suite 18, Towson, MD, 21204 (e-mail: aldellon@dellon.com).

J Reconstr Microsurg Open 2019;4:e58–e63.

## Abstract

**Background** The etiology of interstitial cystitis (IC)/bladder pain syndrome (BPS) remains a mystery. Based on two patients, whose IC/BPS was relieved by resection of injured iliohypogastric (IH) and ilioinguinal (II) nerves, injured by endoscopic prostatectomy in the first patient and a stretch/traction injury in the second patient, a referred pain pathway is hypothesized that can be applied to patients with IC/BPS and previous abdominal wall surgery/injury.

**Methods** The known neurophysiology of bladder function was reviewed as were the pathways for accepted referred pain syndromes.

**Results** Perception of bladder filling occurs by impulses generated from stretch receptors in the bladder wall, traveling along visceral afferent fibers that enter the thoracolumbar spinal cord at T12, L1, and L2, the same location as the sympathetic outflow to the viscera and the same location as some of the visceral afferents from the bladder. The II and IH nerves originate from T12, L1, and sometimes L2 somatic, dorsal root ganglia. It is hypothesized that somatic afferent pain impulses, from the lower abdominal wall, are misinterpreted as visceral afferent impulses from the bladder, giving rise to the urinary frequency and urgency of IC/BPS. Resecting injured cutaneous afferents (II and IH) permitted long-term IC/BPS relief in the first patient for 59 months and in the second patient for 30 months. Neural inputs from the sacral visceral afferents and sacral somatic afferents did not appear to be involved in this referred pain pathway.

**Conclusion** Nerve blocks of the T12–L2 spinal nerves in patients with bladder pain who also have had abdominal wall surgery/injury may identify IC/BPS patients for whom resection of the II and IH nerves may prove beneficial in obtaining lasting IC/BPS relief.

## Keywords

- ▶ bladder pain
- ▶ ilioinguinal
- ▶ iliohypogastric

Interstitial cystitis (IC)/bladder pain syndrome (BPS) is characterized by lower urinary tract symptoms along with pain, discomfort, or pressure perceived in the urinary bladder, lasting longer than 6 weeks in the absence of infection or other identifiable cause.<sup>1</sup> Like other chronic pain disorders, IC/BPS remains a diagnosis of exclusion, with no known single cause, and no accepted universal treatment, severely diminished psychosocial functioning, and poor quality of life in black, Hispanic, and white men and women.<sup>1–4</sup> A review of bladder neurophysiology, emphasizing afferent innervation, and a

discussion of clinical observations related to referred pain can lead to a hypothesis for a microsurgical intervention in BPS.

To understand the neurophysiologic basis of bladder pain, it is important to recall that the bladder fills under normal circumstances with low-intravesical pressure (< 10 cm H<sub>2</sub>O). With bladder filling, the bladder's lamina propria thins and the detrusor muscle's smooth muscle bundles reorganize from a top-to-bottom arrangement to a side-to-side configuration<sup>5</sup>. Reorganization of the smooth muscle bundles is dependent on the activity of afferent (sensory) A  $\delta$  and C-nerve fibers,<sup>5</sup> and

received  
December 31, 2018  
accepted  
June 22, 2019

DOI <https://doi.org/10.1055/s-0039-1696954>.  
ISSN 2377-0813.

Copyright © 2019 by Thieme Medical Publishers, Inc., 333 Seventh Avenue, New York, NY 10001, USA.  
Tel: +1(212) 584-4662.

License terms



parasympathetic, postganglionic, efferent (motor), cholinergic stimulation from the S2–S4 innervation.<sup>6,7</sup> Immunohistochemical studies localize the sensory fibers within the detrusor muscle wall,<sup>8</sup> with unmyelinated C fibers extending into the urothelium, where they can be stimulated by bladder inflammatory molecules and changes in acidity,<sup>9</sup> while the efferent fibers pass from the splanchnic nerves into the pelvic plexus (inferior hypogastric plexus) and then into the bladder itself (► Fig. 1).

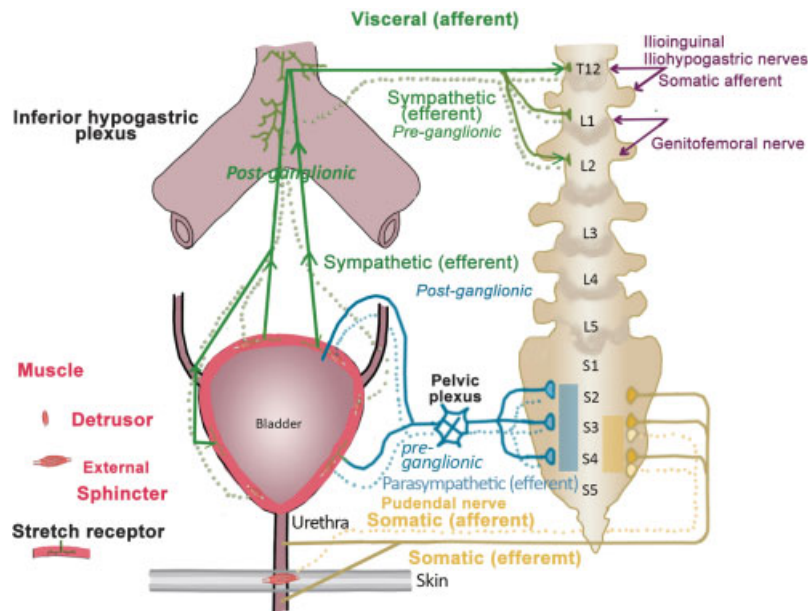
Despite this parasympathetic stimulation, the detrusor muscle does not contract, because it is inhibited by noradrenergic stimulation from the T12–L2 sympathetic, postganglionic, efferent (motor) innervation. However, with progressive bladder filling, the neural circuit switches from inhibition to contraction of the detrusor muscle, which is initiated by an increase in the conduction velocity of the afferent (sensory) fibers, transmitted by visceral afferent, stretch fibers, into the T12–L2 (thoracolumbar) region. When the sympathetic efferent inhibitory stimulation stops, the detrusor muscle contracts, initiating micturition. As part of this reflex, the parasympathetic efferent input to the internal and external sphincter is released to permit urine to flow. Voluntary “over-ride” of this reflex is accomplished through the somatic efferent (motor) activity of the pudendal (also S2–S4) nerve (► Fig. 1).<sup>10–12</sup>

In 1994, a patient with 2 years of left lower quadrant abdominal and pelvic pain was reported with onset of symptoms following an elective abdominoplasty.<sup>13</sup> At reoperation, she was found to have a muscle plication suture about the left iliohypogastric (IH) nerve. Resection of this IH neuroma gave lasting relief of her left lower quadrant and

pelvic pain symptoms. Bladder pain, however, was not specifically reported. In 2011, Dellon described the referred pain of ilioinguinal (II) and IH neuromas to the bladder, since the sympathetic innervation of the bladder had a similar origination, that is, thoracolumbar sympathetic outflow to the bladder; both the sympathetic outflow to the bladder and the II and IH arise from the same spinal segments, T12–L2.<sup>14</sup>

In this paper, we report two patients with IC/BPS who had their symptoms relieved after resection of the IL and IH nerves. These clinical observations suggest that the IC/BPS can be, in fact, a referred pain, a pain not originating from within the bladder itself. The concept of referred pain as a source of IC/BPS has not been hypothesized previously.

The commonly accepted referred pain “syndromes” are listed in ►Table 1 along with their proposed neurophysiologic mechanisms. Referred to pain, as used here, is the best understood in terms used by Doran in 1967,<sup>15</sup> “The physiologic mechanism of referred pain depends on nothing more complex than the termination of pain afferents from the viscera, the deep somatic structures, and the skin, on a common pool of connector neurons in the same segment of the spinal cord. This theory only requires the basic physiological process of summation to make it explain the observed clinical facts. The exact site to which ... a pain is referred is almost certainly finally determined by the higher centres of the brain.” Here, we propose the concept of referred pain from injury to the II and IH which are somatic, afferent (cutaneous and sensory) branches of the T12 through L2 intercostal branches, and possibly from injury to the genitofemoral nerve (GF), causing referred pain interpreted as IC/BPS cortically. We propose an interaction with the known T12–



**Fig. 1** Illustration of three separate contributions to the bladder innervation, thoracolumbar, sacral visceral, and sacral somatic, each of which contains both afferent and efferent fibers. For the referred pain pathway, the thoracolumbar region (T12–L2) contains the visceral afferent (dark green) input from stretch receptors in the bladder/detrusor muscle wall. These participate in spinal reflex for bladder filling. Once a certain bladder volume has been reached, the intensity of neural impulses peaks, and this perception passes to the conscious level to permit voiding. It is hypothesized, here, that the somatic afferent input from the iliohypogastric and ilioinguinal (and perhaps genitofemoral) nerves (dark purple) into the T12–L2 dorsal spinal cord can be misinterpreted as arising from the visceral afferents from this same level, causing bladder pain syndrome.

**Table 1** Examples of referred pain

Pain originates at	Pain referred to	Proposed referral Mechanism
Heart (myocardium)	Left arm	Vagus afferents link to C5–T1
Diaphragm/pleura	Shoulder/back	C3–C6 (phrenic n.) to intercostals
Rotator cuff	Deltoid/shoulder	C5–C6 motor/sensory
Hypopharynx	Middle ear	IX and X cranial nerve
Hard palate	Frontal sinus “brain freeze”	Trigeminal nerve to sphenopalatine ganglion
Thoracolumbar dorsal facets	Low back, thigh, groin	Dorsal ramus/ventral ramus, thoracolumbar region
Ilioinguinal and Iliohypogastric and genitofemoral	Bladder	T12–L2 somatic and visceral efferents

L2 input from the bladder, the visceral afferents and, perhaps, the efferent sympathetic, as the neurophysiologic mechanism of this IC/BPS referred pain.

## Methods

A review of the senior author’s (A.L.D.) experience with groin pain patients from 1994 through the present was undertaken to identify patients with bladder pain. A literature review of the study of bladder innervation and a review of the history of bladder denervation for IC/BPS was done searching for evidence that can be used to explain “T12–L2 referred bladder pain” hypothesis.

## Results

The review of bladder innervation confirmed that there are three distinct sources as illustrated in ►**Fig. 1**. The pudendal nerve, from the sacral nerve roots S2–S4 contains sensory input from the rectum, perineum, urethra, scrotum/labia, and penis/clitoris which is perceived in the sensory cortex, and motor output to urinary and bowel sphincters which is under voluntary control. The parasympathetic innervation of the bladder also comes from the sacral nerve roots, S2–S4, and is “involuntary,” autonomic motor supplying primarily the detrusor muscle of the bladder, while at the same time conveying visceral afferents, whose sensory impulses do not reach the cortex but rather are related to spinal reflexes. In contrast, the thoracolumbar (T12, L1, and L2) region provides somatic afferents from the groin and suprapubic skin whose impulses are perceived in the sensory cortex. These cutaneous nerves are the II and IH nerves, and most often arise from T12 and L1. The GF nerve originates from L1 and L2, and most typically has its sensory input interpreted as testicular pain or mons pubis/labial pain, from its genital component, while the perception of input from the femoral component is most often probably disregarded. There is, however, a great varia-

tion in the skin territories innervated by II, IH, and GF, with significant overlap patterns.<sup>16</sup> In patients where the femoral component of the GF nerve innervates the usual II territory, the GF input may participate in the “T12–L2 referred bladder pain” mechanism. With regard to bladder pain, signals arise from the visceral afferent component of what is traditionally just considered as the “sympathetic outflow to the pelvis.” It is true that visceral efferent, preganglionic, nerve fibers leave T12–L2 to synapse within the hypogastric plexus leaving as postganglionic fibers to the pelvic structures, including the bladder. But along this same pathway travel afferent fibers whose stretch receptors lie in the bladder wall adjacent to the detrusor muscle, sending information about bladder volume. When these afferent impulses reach the T12–L2 level, and synapse in the dorsal horn, they permit stimulation that initiates a reflex that affects the sympathetic discharge such that its inhibition of the detrusor muscle stops, initiating bladder contraction. Some of this input also reaches the cortex allowing us to be aware of the need to urinate. The neurophysiology is such that nociceptive input from the injured II, IH, or sometimes GF nerve, can enter the dorsal horn of the thoracolumbar region and be interpreted as impulses coming from the visceral afferents at that same spinal level. These inputs summate, creating “T12–L2 referred bladder pain.”

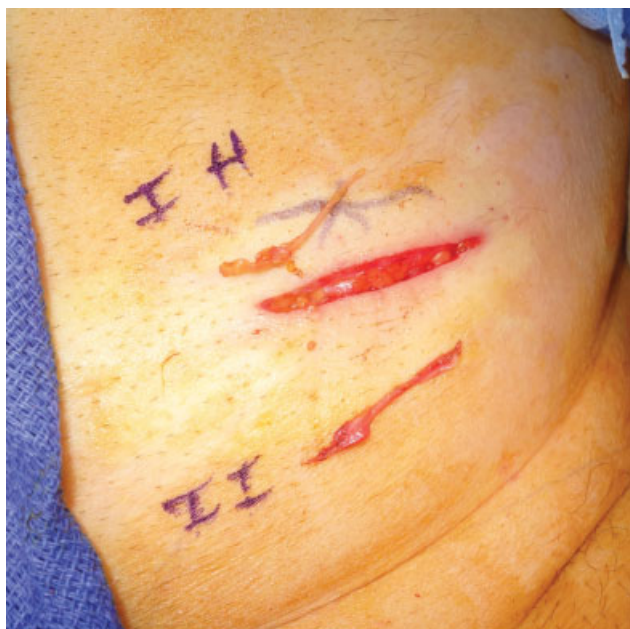Review of the senior author’s patients, including those previously published,<sup>17</sup> identified just two patients in whom there was a clear complaint of IC/BPS. These two patients and their surgical responses to resecting the II and IH are described below:

### Case 1

A 66-year-old man had a robotic prostatectomy in 2010. He awoke from surgery with the perception that “glass shards” were sticking into his bladder. Neuropathic pain medication was not helpful. Imaging studies showed no tumor recurrence and his PSA remained at zero. His preoperative O’Leary–Sant voiding pain indices were 14 and 12, and his pelvic pain and urgency/frequency scale was  $17 + 11 = 28$ . His physical examination demonstrated pain over the right lower quadrant portal, related to the II and IH nerves, while the left side had no tenderness. At surgery, December 2, 2012, the right II and IH nerves were divided at the level of the anterior iliac crest (►**Fig. 2**), and the proximal ends of these nerves placed into the preperitoneal space. His bladder pain was completely relieved. Five years postoperative his O’Leary–Sant voiding pain indices improved to 5 and 3, and his Pelvic pain and urgency/frequency scale improved to  $5 + 3 = 8$ . His last follow-up report was in November of 2018, 59 months after surgery. He remained without bladder pain or urinary symptoms.

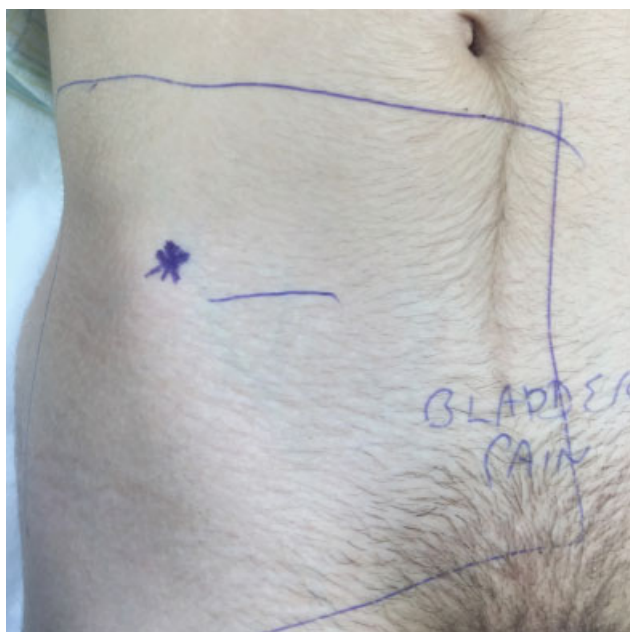### Case 2

A 16-year-old boy sustained blunt trauma to the right lower quadrant during a football game in June of 2014. His symptoms were primarily “bladder pain” associated with urinary frequency and urgency but no dysuria. His urgency and frequency was almost hourly. He had seen 20 physicians



**Fig. 2** Abdominal wall of patient demonstrating incision medial to the anterior iliac crest, with the excised iliohypogastric (IH) and ilioinguinal (II) nerves lying next to the incision.

over the preceding 17 months, cystoscopy was normal, neuropathic medications did not help, and a sacral “interstim” did not give relief. Imaging studies were all normal. His physical examination demonstrated discrete pain over the II and IH region with referred pain to his bladder (►**Fig. 3**). Because he was tender in the right lower quadrant, local nerve block into this area was done, and gave him few hours of relief. A nerve block at T12/L1 gave relief of the urgency and frequency for 6 hours. On November 5, 15, he had the



**Fig. 3** Case 2, demonstrating asterisk (\*) at the site of trigger spot with pain referred to the bladder. The blue line is the border to be prepared for surgery.

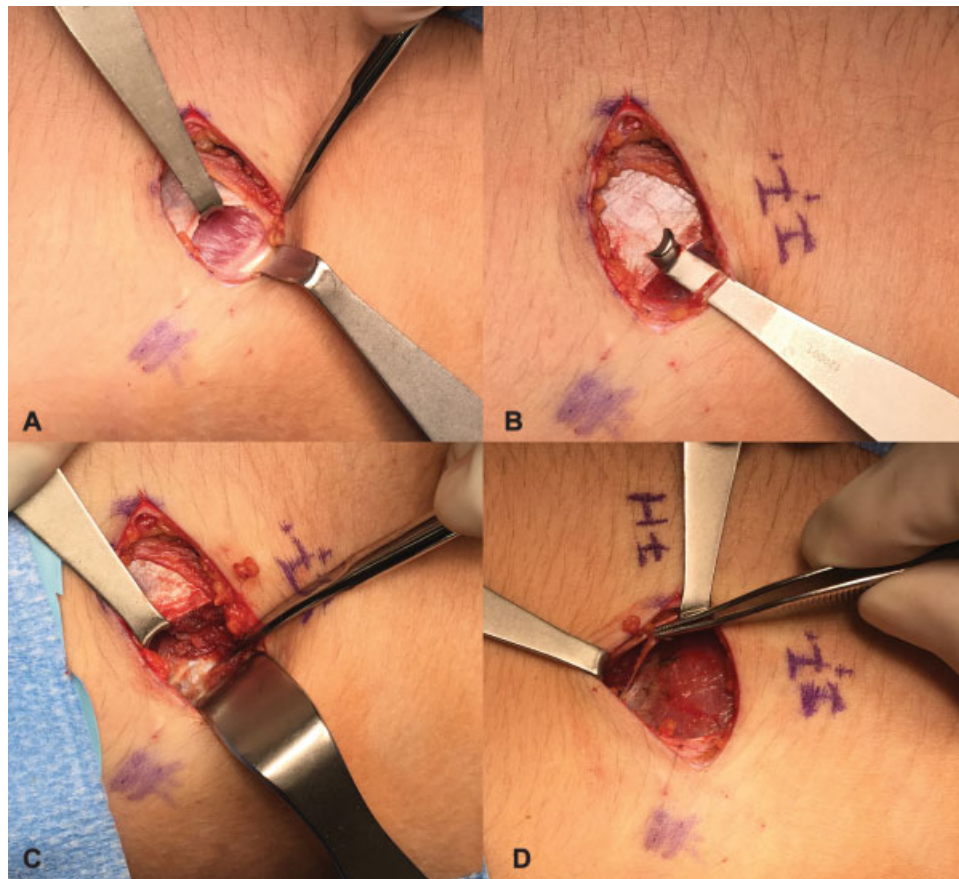
right II and IH nerves resected (►**Fig. 4**). On follow-up, May 30, 18, 30 months after surgery, he remained without bladder symptoms and was playing varsity soccer in high school.

## Discussion

This is the first report of relief of IC/BPS by resecting one or more peripheral cutaneous nerves. The weakness of this report is that it is based upon just two retrospectively observed patients. However, the observations made permit expression of a hypothesis of referred pain from somatic afferents, the II and IH nerves, and possibly GF, arising from T12–L2, giving rise to IC/BPS by virtue of a similar origin from the thoracolumbar spine as the visceral afferents to the bladder that travel with the sympathetic nerves.

Anderson and Langley, in a series of papers, in the late 19th century, had studied innervation of pelvic organs. They reported that the hypogastric nerves contained 10% afferent fibers, and the pelvic visceral (splanchnic) nerves contained 33% afferent fibers.<sup>18</sup> Thus, both the “sympathetic” and the “parasympathetic” outflow contain both visceral afferents and visceral efferent nerve fibers. Today, these afferents are usually not further discussed, with emphasis being placed on the motor function of these autonomic nerves related to the detrusor muscle and the internal and external urinary sphincter muscles. Here, we emphasize the importance of BPS as being transmitted primarily through the thoracolumbar visceral afferents.

There have been direct attempts to relieve IC/BPS by dividing the presacral sympathetic innervation. It is our view that these approaches did not simply consider that resection of the sympathetic nerves or their plexus would also divide the accompanying visceral afferents. For example, in his observations, made at surgery in patients having simultaneous cystoscopy and stimulation/division of the presacral plexus, James Learmonth, a Neurosurgeon then at the Mayo Clinic, noted “*in one case, the patient stated that handling the presacral nerve with forceps was attended by a crushing pain in the bladder.*”<sup>11</sup> Learmonth also noted that while division of the presacral nerve relieved bladder pain, it has had little if any effect on urethral irritation.<sup>11</sup> (Our urethral sensory impulses travel with the pudendal, somatic afferents.) We might ask if any of the patients that Learmonth reported as having been treated for bladder pain might have benefitted from division of the II and IH nerves instead of having a presacral neurectomy, which requires a challenging retroperitoneal dissection. One of Learmonth’s groups of patients did not have pain but had neurogenic bladder spasms related to spinal cord injury, and these patients had relief by presacral sympathectomy. Of his 11 patients treated for “vesicle pain,” one had bladder carcinoma, while the others had a diagnosis of “interstitial cystitis” or “posterior urethritis.” None of this group with, what we would today call IC/BPS, was reported to have had previous abdominal wall surgery or trauma, so that most likely resection or nerve block of the II and IH nerves would not have helped Learmonth’s patients.



**Fig. 4** Case 2 illustrating surgical approach to resecting the iliohypogastric (IH) and ilioinguinal (II) nerves. (A) The white edge of the incised external oblique fascia is retracted to show the ilioinguinal nerve lying upon the internal oblique muscle adjacent to the white inguinal ligament. (B) The II nerve is shown on a retractor. (C) With the external oblique fascia retracted, the IH nerve is noted on the internal oblique muscle more cephalad, near to the internal oblique fascia. (D) The IH nerve is grasped in a clamp.

Learmonth was not the first to attempt bladder denervation. He reported that Piri, in “Europe,” did the first presacral sympathectomy.<sup>19</sup> The translation of Piri’s paper is “Clinical Contributions to the Surgery of the Autonomic Nervous System IV. The Cure of Tuberculous Cystitis” (translated by Nicoletta Ghisas, PhD) Learmonth may be considered to be the “first peripheral nerve surgeon,” having done the first carpal decompression (1933) and the first submuscular ulnar nerve transposition (1942).<sup>20</sup>

In extensive dissection, and electrical stimulation and recording of the canine bladder, in 1937, Talaat reported that “the main function of the afferent nerve fibers in the hypogastric (nerve) is to carry painful impulses.”<sup>21</sup> Talaat also noted that the “pudic nerve,” the pudendal nerve, when stimulated by saline flowing in the urethra, gave an electrical response, but did not do so with bladder distention. Learmonth observed directly in humans that stimulation of the hypogastric plexus evoked perception of bladder pain.<sup>10,11</sup>

The next published attempt to learn more about bladder denervation was reported in 1938,<sup>22</sup> and attempted to learn why Learmonth’s observed that some patients did not improve, and some patients improved only briefly. Scott and Schroeder reported 11 patients with bladder pain, primarily due to tuberculous disease, but in three patients from unknown cause or interstitial cystitis.<sup>22</sup> They found

additional branches arising from the inferior mesenteric plexus, and some more laterally from the hypogastric plexus, so that if the surgical denervation took this more widespread dissection approach in the retroperitoneum, a long-term relief of bladder pain could be obtained.

Inclusion of the GF (L1–L2) nerve in this hypothesis seems warranted because patients with IC/BPS report pain in the “genitals,”<sup>23</sup> patients with IC/BPS have segmental hyperalgesia in the T11 dermatome (T12–L2 were not tested),<sup>24</sup> and the high percentage of women with “abdominal wall pain” associated with pelvic pain.<sup>25</sup> To determine whether this inclusion is warranted, patients whose main complaint is testicular or mons pubis/labial pain would need to be queried on whether they also have symptoms consistent with IC/BPS and then have appropriate level spinal nerve blocks to determine their outcome on the IC/BPS symptoms.

In more recent work, elimination of vagus afferents was shown not to affect the afferent impulses to the thoracolumbar outflow track in mice, and the stretch receptors were demonstrated, by immunohistological staining of (calcitonin gene-related peptide) receptor, to be located in the detrusor muscle.<sup>25–27</sup> We may conclude from this that sensory input from the bladder reaches the thoracolumbar dorsal root entry zone, where spinal reflexes result, and then that input is routed up the brainstem to the conscious level for cortical

interpretation. In the present hypothesis, we conclude that the somatic input to this thoracolumbar spine from the II, IH (and possibly from the GF) nerves evokes that same spinal response and cortical interpretation.

## Conclusion

Injury to cutaneous nerves of the lower abdominal wall, such as the II and IH nerves, generate somatic afferent neural impulses that enter the thoracolumbar spine, interact with visceral afferents from the bladder that travel along with the sympathetic efferent fibers from that same T12–L2 region. These afferent inputs summate to be interpreted (misinterpreted) as IC/BPS. This referred pain can be identified by appropriate nerve block, and the IC/BPS symptoms relieve by microsurgical resection of the neuromas of the II and IH nerves.

### Conflict of Interest

None declared.

## References

- Hano P. Editorial comment to hypersensitive bladder: a solution to confused terminology and ignorance concerning interstitial cystitis. *Int J Urol* 2014;21(Suppl 1):48
- Clemens JQ, Link CL, Eggers PW, Kusek JW, Nyberg LM Jr, McKinlay JB; BACH Survey Investigators. Prevalence of painful bladder symptoms and effect on quality of life in black, Hispanic and white men and women. *J Urol* 2007;177(04):1390–1394
- Verghese TS, Riordain RN, Champaneria R, Latthe PM. Complementary therapies for bladder pain syndrome: a systematic review. *Int Urogynecol J Pelvic Floor Dysfunct* 2016;27(08):1127–1136
- Pazin C, de Souza Mitidieri AM, Silva AP, Gurian MB, Poli-Neto OB, Rosa-E-Silva JC. Treatment of bladder pain syndrome and interstitial cystitis: a systematic review. *Int Urogynecol J Pelvic Floor Dysfunct* 2016;27(05):697–708
- Chai TC, Birder LA. Physiology and Pharmacology of the Bladder and Urethra. In: Wein AJ, Kavoussi LR, eds. *Campbell-Walsh Urology*. 14th ed. Philadelphia, PA: Elsevier
- le Feber J, van Asselt E, van Mastrigt R. Afferent bladder nerve activity in the rat: a mechanism for starting and stopping voiding contractions. *Urol Res* 2004;32(06):395–405
- Choudhary M, van Asselt E, van Mastrigt R, Clavica F. Neurophysiological modeling of bladder afferent activity in the rat overactive bladder model. *J Physiol Sci* 2015;65(04):329–338
- Gillespie JJ, Markerink-van Ittersum M, de Vente J. Sensory collaterals, intramural ganglia and motor nerves in the guinea-pig bladder: evidence for intramural neural circuits. *Cell Tissue Res* 2006;325(01):33–45
- Yoo PB, Woock JP, Grill WM. Somatic innervation of the feline lower urinary tract. *Brain Res* 2008;1246:80–87
- Learmonth JR. Contribution to the neurophysiology of the urinary bladder in man. *Brain* 1931;54(02):147–176
- Learmonth JR. The value of neurosurgery in certain vesical conditions. *J Am Med Assoc* 1932;98(08):632–636
- Romanes GJ. *Cunningham's Textbook of Anatomy*, 10th ed. London, United Kingdom: Oxford University Press; 1964
- Liszka TG, Dellon AL, Manson PN. Iliohypogastric nerve entrapment following abdominoplasty. *Plast Reconstr Surg* 1994;93(01):181–184
- Dellon AL. Pelvic pain. In: *Pain Solutions*. 2nd ed. Lightning Source; 2007:328–330
- Doran FSA. The sites to which pain is referred from the common bile-duct in man and its implication for the theory of referred pain. *Br J Surg* 1967;54(07):599–606
- Rab M, Ebmer And J, Dellon AL. Anatomic variability of the ilioinguinal and genitofemoral nerve: implications for the treatment of groin pain. *Plast Reconstr Surg* 2001;108(06):1618–1623
- Lee CH, Dellon AL. Surgical management of groin pain of neural origin. *J Am Coll Surg* 2000;191(02):137–142
- Langley JN, Anderson HK. The Innervation of the Pelvic and adjoining Viscera: Part VII. *Anatomical Observations*. *J Physiol* 1896;20(4-5):372–406
- Piri G. *Clinical Contributions to the Surgery of the Autonomic Nervous System IV. The Cure of Tuberculous Cystitis*, *Italian Arch Surg* 1930;27:454–482
- Dellon AL, Amadio PC, James R, Learmonth: the first peripheral nerve surgeon. *J Reconstr Microsurg* 2000;16(03):213–217
- Talaat M. Afferent impulses in the nerves supplying the urinary bladder. *J Physiol* 1937;89(01):1–13
- Scott WJM, Schroeder CF. Denervation of the bladder for intractable pain. *Ann Surg* 1938;108(04):730–740
- Warren JW, Langenberg P, Greenberg P, Diggs C, Jacobs S, Wesselman U. Sites of pain from painful Interstitial Cystitis/Bladder Pain Syndrome. *J Urol* 2008;180(04):1373–1377
- Lai HH, Gardner V, Ness TJ, Gereau RW IV. Segmental hyperalgesia to mechanical stimulus in interstitial cystitis/bladder pain syndrome: evidence of central sensitization. *J Urol* 2014;191(05):1294–1299
- Mui J, Allaire C, Williams C, Yong PJ. Abdominal wall pain in women with chronic pelvic pain. *J Obstet Gynaecol Can* 2016;38(02):154–159
- Kyloh M, Nicholas S, Zagorodnyuk VP, Brookes SJ, Spencer NJ. Identification of the visceral pain pathway activated by noxious colorectal distension in mice. *Front Neurosci* 2011;5:16
- Spencer NJ, Zagorodnyuk V, Brookes SJ, Hibberd T. Spinal afferent nerve endings in visceral organs: recent advances. *Am J Physiol Gastrointest Liver Physiol* 2016;311(06):G1056–G1063