


Oral Administrations of *Hancornia speciosa* Gomes Latex Do Not Increase Bone Neof ormation*

Administrações Oraís do Látex da *Hancornia speciosa* Gomes não aumentam a neof ormação óssea

Francielly Andressa Felipetti¹  Rafaela Mariano Bereta² Sônia Maria Stefano Piedade³
Pedro Duarte Novaes¹

¹Department of Morphology, Faculdade de Odontologia de Piracicaba, Universidade Estadual de Campinas, Piracicaba, SP, Brazil

²Department of Oral Health, Escola Técnica Qualificar, Florianópolis, SC, Brazil

³Department of Exact Sciences, Escola Superior de Agricultura Luiz de Queiroz, Universidade de São Paulo, Piracicaba, SP, Brazil

Address for correspondence Francielly Andressa Felipetti, Rua Eugênio de Bona Castelan, 120, apto 502, Criciúma, SC, 88801-640, Brazil (e-mail: fafelipetti@gmail.com).

Rev Bras Ortop 2019;54:692–696.

Abstract

Objective The present work aimed to evaluate the systemic effect of *H. speciosa* latex on bone neof ormation.

Methods For this, the latex was collected and diluted to 3% and 50%. A total of 28 Wistar rats were submitted to surgery to create a 5 mm diameter defect in the parietal bone. This experiment was conducted in 2 different periods: 1 and 2. For each period, the rats were divided into 3 groups: Control Group, Latex3 Group, and Latex50 Group, which received, respectively, daily administrations of 0.5 mL of distilled water, latex to 3% and latex to 50% by gavage, orally. The rats of periods 1 and 2 were euthanized, respectively, 15 and 30 days after the surgery, and the calvaria was collected. The results were analyzed using the ANOVA and Tukey tests; the significance level was 0.05.

Results We show that, in each analyzed period, the experimental groups had the same amount of newly formed bone in the calvaria defect.

Conclusion We conclude that daily and oral administrations of *H. speciosa* latex to 3% and to 50% over a period of 15 and 30 days does not contribute to the increase of the area of the newly formed bone in the calvaria defect.

Keywords

- ▶ apocynaceae
- ▶ hematoxylin
- ▶ histology
- ▶ latex
- ▶ bone and bones
- ▶ complementary therapies

Resumo

Objetivo Este trabalho objetivou avaliar o efeito sistêmico do látex de *H. speciosas* obre a neof ormação óssea.

Métodos Para isso, o látex foi coletado e diluído a 3% e a 50%. Um total de 28 ratos Wistar foi submetido a cirurgia para a criação de um defeito de 5 mm de diâmetro no

* Study developed at the Department of Morphology, Faculdade de Odontologia de Piracicaba, Universidade Estadual de Campinas, Piracicaba, SP, Brazil.

Palavras-chave

- ▶ apocynaceae
- ▶ hematoxilina
- ▶ histologia
- ▶ látex
- ▶ osso e ossos
- ▶ terapias complementares

osso parietal. Esse experimento foi conduzido em dois períodos distintos: 1 e 2. Para cada período, os ratos foram divididos em 3 grupos: Grupo Controle, Grupo Látex3 e Grupo Látex50 que receberam, respectivamente, administrações diárias de 0,5 mL de água destilada, látex a 3% e látex a 50% por gavagem, via oral. Os ratos dos períodos 1 e 2 foram eutanasiados, respectivamente, 15 e 30 dias após a cirurgia e a calvária foi coletada. Os resultados foram analisados utilizando os testes ANOVA e Tukey; o nível de significância estabelecido foi 0,05.

Resultados Mostramos que, em cada período analisado, os grupos experimentais tiveram a mesma quantidade de osso neof ormado no defeito da calvária.

Conclusão Portanto, concluímos que administrações diárias e orais do látex de *H. speciosa* a 3% e a 50% durante um período de 15 e 30 dias não contribui para o aumento da área do osso neof ormado no defeito da calvária.

Introduction

Bone is a highly dynamic mineralized connective tissue. Major bone cells, such as osteoblasts, osteoclasts and osteocytes, are essential for their remodeling.^{1,2} In the early stages of bone production, osteoblasts deposit the organic matrix, release calcium (Ca)-containing vesicles and induce pyrophosphate degradation, releasing phosphate ions.²⁻⁴ Phosphate and Ca form hydroxyapatite crystals and mineralize the bone matrix, forming new bone.¹ Through this process of bone remodeling, bone can regenerate spontaneously after the incidence of fractures, injuries or defects.⁵ However, physiological regeneration is unable to restore bone integrity in extensive bone defects, where the repair process must be supported by some complementary therapies.^{6,7}

Latex obtained from the trunk of the *Hevea brasiliensis* (a native Brazilian tree known as “Seringueira”) can be an innovative biomaterial for bone repair. Some experiments that have been performed with this product include bone repair of dental cavities in rats,⁸ guided regeneration of rabbit calvaria,⁶ osseointegration of dental implants in dogs,⁹ and bone repair of a critical defect in rat calvaria.^{10,11}

Latex extracted from the trunk of *Hancornia speciosa* Gomes (another Brazilian native tree known as “Mangabeira”, belonging to the Apocynaceae family) also demonstrated bone repair potential. The research group of the Faculdade de Odontologia de Piracicaba (FOP, in the Portuguese acronym) of the Universidade Estadual de Campinas (UNICAMP, in the Portuguese acronym), demonstrated that topical application of *H. speciosa* latex on the defects on the skullcap of Wistar rats increased the area of the newly formed bone at the edges of the defect.¹²

Some communities located in northeastern Brazil produced a milky juice called “leite de mangaba” (mangaba milk) from the trunk latex of *H. speciosa*. Ethnobotanical surveys have confirmed the use of this milky juice for therapeutic treatment of bone fractures.¹³ However, to date, no studies have been conducted to confirm this effect.

In summary, these findings motivated us to investigate the therapeutic potential of *H. speciosa* latex. Therefore, the present study reports the systemic effect of *H. speciosa* latex in bone neof ormation in Wistar rats.

Materials and Methods**Latex Collection and Analysis**

Hancornia speciosa latex was collected at the city of Mata de São João, Bahia, Brazil (12°27'42"S 37°56'38"O 69NE) in summer. A sample of this was deposited in the Escola Superior de Agricultura Luiz de Queiroz (ESALQ, in the Portuguese acronym) da Universidade de São Paulo (USP, in the Portuguese acronym) and received the number ESA 121.402. After drilling ~ 10 tree trunks, 250 ml of the dripping latex was collected in a sterile container and mixed with distilled water to obtain a 3% latex solution and a 50% latex solution. The solutions were stored in syringes, protected from light and stored at 4°C.

Animals

A total of 28 Wistar rats (mean body weight: 390 g; age: 10 weeks) were used. The rats were housed in individual cages under controlled temperature and light conditions (12/12 h light/dark cycle). All of the animals received food and water *ad libitum*. Prior to the surgery, the rats were anesthetized with intraperitoneal injection of 80 mg/Kg of ketamine (Dopalen, Sespo Indústria e Comércio Ltda., Paulínia, SP) and 8 mg/Kg of Xylazine (Rompun, Bayer SA, São Paulo, SP, Brazil). The surgery consisted in the creation of a critical defect in the left parietal calvarial bone (5 mm diameter) using a dental trephine drill mounted on a low-speed dental motor. After the surgery, 2 mg/ml tramadol hydrochloride (Tramal, Grunenthal do Brasil Pharmaceutical Ltda, São Paulo, SP, Brazil) were administered intramuscularly to the rats and they rested for 24 hours. The present experiment was conducted in 2 distinct periods: 1 and 2. For period 1, the rats were divided into 3 groups: Control 1 Group (C1, $n = 4$), Latex 31 Group (L31, $n = 4$) and Latex 501 Group (L501, $n = 5$) who received, respectively, daily administrations of 0.5 mL distilled water, 3% latex, and 50% latex by gavage, orally, for 15 days. For period 2, the rats were divided into 3 groups: Control 2 Group (C2, $n = 5$), Latex 32 Group (L32, $n = 5$) and Latex 502 Group (L502, $n = 5$) who received, respectively, daily administrations of 0.5 ml distilled water, 3% latex, and 50% latex by gavage

orally for 30 days. The rats from periods 1 and 2 were euthanized, respectively, 15 days and 30 days after the surgery. After euthanasia, the calvaria was collected for analysis. All of the procedures were approved by the Animal Use Ethics Committee (CEUA, in the Portuguese acronym) with the protocol number 3427-1.

Histological Analysis

Samples Cleavage and Histological Processing

The calvaria was fixed in formalin solution and submitted to conventional histological processing.¹⁴ First, the calvaria was sectioned transversely and only the bone portion was obtained. Subsequently, the calvaria was decalcified with PLANK solution for 1 week with 2 daily changes. After decalcification, the calvaria was cleaved and only the bone defect region was preserved for further processing. Then, the calvaria bone defect was dehydrated, diaphanized and embedded in paraffin to obtain the blocks.¹⁴

Preparation of the Histological Slides

Once the paraffin blocks were obtained, coronal sections of the calvaria were collected. All of the sections had 6 μm of thickness. By default, eight consecutive sections of the calvaria blocks were first collected; 2 histological slides were prepared, and 15 sections were, finally, discarded; these steps were performed repeatedly until 20 slides were obtained. All of the slides were stained with hematoxylin and eosin and observed under a light microscope.

Descriptive and Histomorphometric Analysis

The slides were photographed using the software Optica View 7, and the images were recorded at 100x magnification for the entire calvaria bone defect. These images were analyzed by a single examiner using the software Image J (National Institutes of Health, Bethesda, MD, USA). Calvaria repair processes were demonstrated by descriptive analysis. The newly formed bone area throughout the calvaria bone defect was examined by histomorphometric analysis. For this, a millimeter ruler was first photographed at 100x magnification and then measured from end to end; the distance in pixels was recorded; the known distance was established according to the size of the ruler (1 mm); and the length unit was adjusted in millimeters. This information was recorded on each calvaria defect photo to define scale. Finally, a line was drawn marking all the newly formed bone within the calvaria defect, and then the area of the new bone was calculated. Quantified values were compared between groups.

Statistical analysis

Data were analyzed using the software R (R Core Team). The Bartlett and Shapiro-Wilk tests were used to verify the deviation of the assumptions. Once the homogeneity of variance and normal distribution were confirmed, the analysis of variance (ANOVA) and Tukey tests were used to compare the period 1 and 2 groups separately. The significance level was set at 5% ($p < 0.05$).

Results

Descriptive Histological Analysis of the Calvaria Bone Defect

Conventional histological technique using light microscopy is widely used for bone repair analysis. This technique allows a descriptive analysis of the tissue and the measurement of the area of the components of interest (histomorphometry).¹⁵ We used these analyses to evaluate the newly formed bone in the calvaria defect.

The descriptive analysis revealed a similar stage of bone repair between groups C1, L31 and L501 and between groups C2, L32 and L502 (**Figure 1**). Mineralized trabeculae of the newly formed bone extended from the edges of the basal bone toward the center of the defect. We observed several osteocytes trapped in the bone matrix and medullary spaces filled with blood cells along the trabeculae. Numerous active osteoblasts have been noted around the trabeculae. Abundant connective tissue, widely vascularized, filled the central portions of the defect.

Histomorphometric Histological Analysis of the Calvaria

The histomorphometric analysis of the calvaria is represented in **Figure 2**. We measured the area of newly formed bone in each group. Results showed that the amount of new bone in groups L31 and L501 was similar in group C1. Concurrently, the amount of new bone in groups L32 and L502 was similar in group C2. These data are consistent with those of the descriptive analysis.

Discussion

The present work investigated the systemic effect of *H. speciosa* latex on bone neof ormation in Wistar rats.

In short, bone is a highly dynamic mineralized connective tissue, and its main cells (osteoblasts, osteoclasts and osteocytes) are essential for its remodeling.^{1,2}

In the presence of a fracture, healing-related events result in the formation of a new bone.¹⁶ In the early stages of bone production, osteoblasts deposit the organic matrix, forming a tissue known as an osteoid. Then, osteoblasts release vesicles containing Ca reserves that are degraded by enzymes to release this ion into the newly deposited matrix. Osteoblasts also secrete alkaline phosphatase, an enzyme that degrades pyrophosphate, releasing phosphate ions.^{2,4,17} Phosphate and Ca form hydroxyapatite crystals and mineralize the bone matrix, forming new bone.¹ In the present study, the histological analysis showed newly formed bone trabeculae along the calvaria defect. According to the literature, in the presence of a fracture, healing-related events result in the formation of a bone callus that progresses to interconnect the two ends.¹⁶ These concepts explain why the process of bone repair began at the edges of the basal bone toward the center of the calvaria defect in all groups.

The histomorphometric analysis revealed that oral administration of latex at 3% and 50% did not increase the area of newly formed bone in the calvaria defect even after 15 and

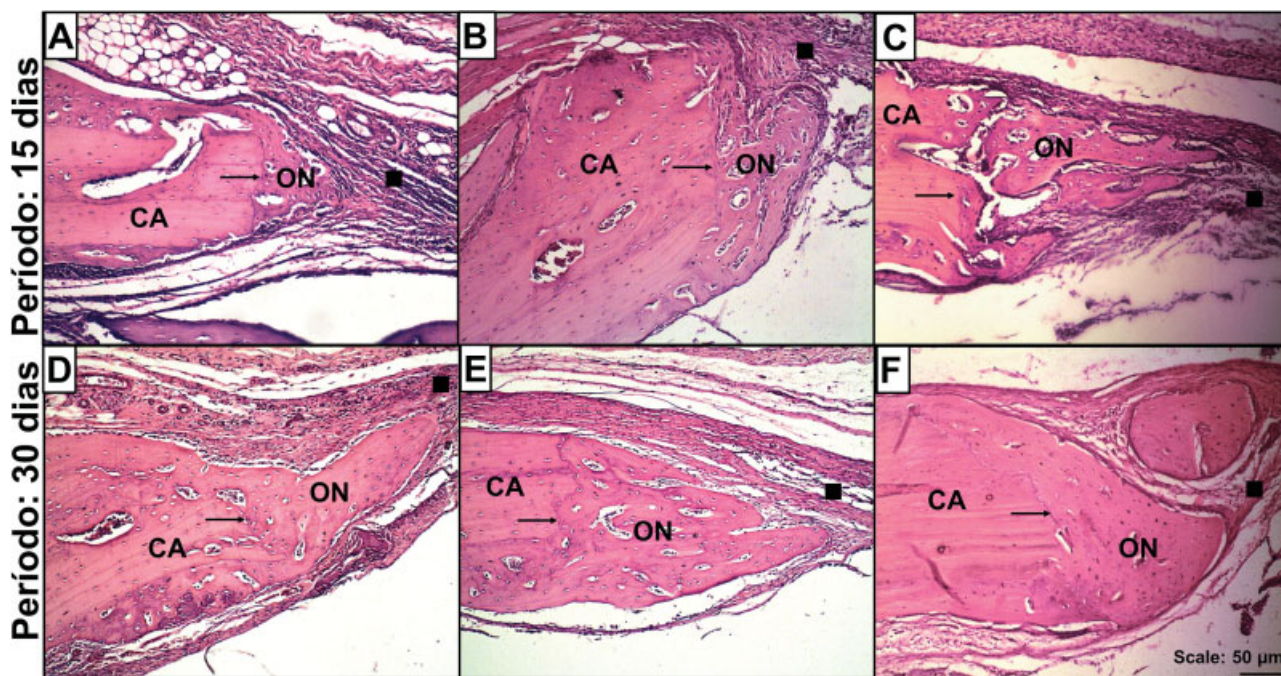


Fig. 1 Bone neoformation in the calvaria defect. Source: From the author himself. Note: These are representative images of one of the edges of the calvaria defect, analyzed over 15- and 30-day periods. Coronal cut. Images A, B and C represent, respectively, groups C1, L31 and L501. Images D, E and F represent, respectively, groups C2, L32, L502. Note the newly formed bone extending from the edges toward the center of the defect in all groups. CA, calvaria; ON, new bone; →, defect. edges; ■, connective tissue itself (Hematoxylin and Eosin, 100X).

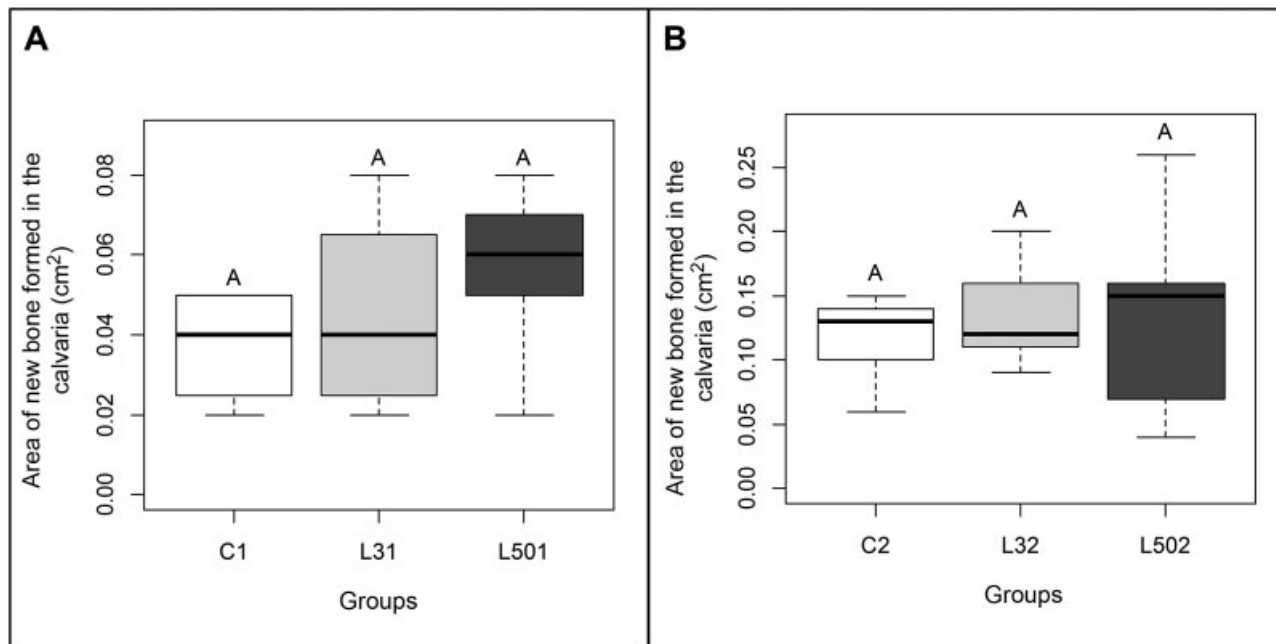


Fig. 2 New bone area formed in rat calvaria defect. Source: From the author himself. Note: Graph A illustrates the area of newly formed bone in calvaria defect after period 1 (15 days). C1, Control Group; L31, Latex Group 3%, L501, Latex Group 50%. Graph B illustrates the area of newly formed bone at calvaria defect after period 2 (30 days). C2, Control Group; L32, Latex Group 3%, L502, Latex Group 50%. Equivalent letters indicate that there is no statistically significant difference between the groups, according to the analysis of variance test, with $p < 0.05$.

30 days of treatment. On the other hand, the literature confirms that there is an increase in the area of the newly formed bone both in the calvaria¹² and in the mandible socket⁸ of rats treated with natural latex using local product applications. This effect can be attributed to the presence of some phytochemicals in the latex. Dos Santos Neves et al¹² identified that

H. speciosa latex contains chlorogenic acid and naringenin-7-O-glycoside. There is evidence that these compounds stimulate osteoblastic activities.^{18,19} Active osteoblasts secrete a large amount of alkaline phosphatase and osteocalcin, important molecules for Ca deposition and bone mineralization (Florence et al., 2017). Thus, these phytochemicals can increase

bone mineral density and improve bone microarchitecture.^{18,19} Possibly, our results are different from those found in the literature because of the different routes of product administration. In the present study, we evaluated the effect of the orally-administered product, whereas studies described in the literature demonstrate product results when administered topically. To confirm the effect of oral latex administration on bone neof ormation, further doses need to be evaluated in future studies. Also, the chemical composition of newly formed bone also needs to be analyzed to understand the popular belief about the benefit of consuming mangaba milk daily for the treatment of fractures.³

Conclusion

In the present article, we have found that daily and oral administrations of 3% and 50% *H. speciosa* latex over a 15- and 30-day period did not contribute to the increased area of newly formed bone in the calvaria defect. To confirm other effects of this latex on bone mass, different doses of the product need to be tested and the chemical composition of newly formed bone needs to be evaluated in future studies. In this way, we will be able to understand the popular belief about the benefit of consuming mangaba milk daily for fracture treatment.

Conflicts of Interests

The authors have no conflicts of interests to declare.

Acknowledgments

The authors would like to acknowledge the National Council for Scientific and Technological Development (CNPq, in the Portuguese acronym), number 141226/2014-5, for the support given to the present study.

References

- Raggatt LJ, Partridge NC. Cellular and molecular mechanisms of bone remodeling. *J Biol Chem* 2010;285(33):25103–25108
- Valenti MT, Dalle Carbonare L, Mottes M. Osteogenic Differentiation in Healthy and Pathological Conditions. *Int J Mol Sci* 2016;18(01):E41
- Florence NT, Huguette ST, Hubert DJ, et al. Aqueous extract of *Peperomia pellucida* (L.) HBK accelerates fracture healing in Wistar rats. *BMC Complement Altern Med* 2017;17(01):188
- Guyton AC, Hall JE. Text book of medical physiology. 11th ed. Philadelphia: Elsevier Saunders; 2006
- Thurairajah K, Broadhead ML, Balogh ZJ. Trauma and Stem Cells: Biology and Potential Therapeutic Implications. *Int J Mol Sci* 2017;18(03):E577
- Ereno C, Guimarães SA, Pasetto S, et al. Latex use as an occlusive membrane for guided bone regeneration. *J Biomed Mater Res A* 2010;95(03):932–939
- Walmsley GG, Ransom RC, Zielins ER, et al. Stem Cells in Bone Regeneration. *Stem Cell Rev* 2016;12(05):524–529
- Balabanian CA, Coutinho-Netto J, Lamano-Carvalho TL, Lacerda SA, Brentegani LG. Biocompatibility of natural latex implanted into dental alveolus of rats. *J Oral Sci* 2006;48(04):201–205
- Manfrin Arnez MF, Xavier SP, Pinto Faria PE, et al. Implant osseointegration in circumferential bone defects treated with latex-derived proteins or autogenous bone in dog's mandible. *Clin Implant Dent Relat Res* 2012;14(01):135–143
- Issa JP, Defino HL, Pereira YC, et al. Bone repair investigation using rhBMP-2 and angiogenic protein extracted from latex. *Microsc Res Tech* 2012;75(02):145–152
- Issa JP, Defino HL, Sebaldo W, et al. Biological evaluation of the bone healing process after application of two potentially osteogenic proteins: an animal experimental model. *Gerodontology* 2012;29(04):258–264
- Dos Santos Neves J, Franchin M, Rosalen PL, et al. Evaluation of the osteogenic potential of *Hancornia speciosa* latex in rat calvaria and its phytochemical profile. *J Ethnopharmacol* 2016;183:151–158
- Silva JF Junior. A cultura da mangaba. *Rev Bras Frutic* 2006;26(01):1–192
- Molinari EM, Caputo L, Amendoeira R. Conceitos e Métodos para a formação de profissionais em laboratórios de saúde. Rio de Janeiro EPSJV2009. [acesso em 2018 maio 31]. Disponível em: www.fiocruz.br/ioc/media/Livropoli.pdf
- Gomes PS, Fernandes MH. Rodent models in bone-related research: the relevance of calvarial defects in the assessment of bone regeneration strategies. *Lab Anim* 2011;45(01):14–24
- Lin Z, Fateh A, Salem DM, Intini G. Periosteum: biology and applications in craniofacial bone regeneration. *J Dent Res* 2014;93(02):109–116
- Florencio-Silva R, Sasso GR, Sasso-Cerri E, Simões MJ, Cerri PS. Biology of Bone Tissue: Structure, Function, and Factors That Influence Bone Cells. *BioMed Res Int* 2015;2015:421746
- Li F, Sun X, Ma J, et al. Naringin prevents ovariectomy-induced osteoporosis and promotes osteoclasts apoptosis through the mitochondria-mediated apoptosis pathway. *Biochem Biophys Res Commun* 2014;452(03):629–635
- Zhou RP, Lin SJ, Wan WB, et al. Chlorogenic Acid Prevents Osteoporosis by Shp2/PI3K/Akt Pathway in Ovariectomized Rats. *PLoS One* 2016;11(12):e0166751