

# Submucosal Myoma Treatment for Women Who Wish to have Children in the Future Nodule Dissection Centripetal Cutting Method of TCR (Transcervical Resection)

Shigeo Inoue, MD<sup>1</sup>

<sup>1</sup>Uterine Myoma Endoscopic Surgery Center, Institute of Minimally Invasive Endoscopic Care, Sano Hospital, iMEC, Hyogo, Japan

Surg J 2020;6(suppl S1):S58–S70.

Address for correspondence Shigeo Inoue, MD, Uterine Myoma Endoscopic Surgery Center, Institute of Minimally Invasive Endoscopic Care, Sano Hospital, iMEC, 2-5-1 Shimizugaoka Tarumi-ku, Kobe-shi, Hyogo-ken 655-0031 Japan (e-mail: inoueshigeo@msn.com).

## Abstract

Due to the recent trend to marry later, patients with uterine myoma, and who wish to preserve their uterus have increased, are leading to greater demand for minimally invasive myomectomies. For intramural myomas and submucosal myomas, which are located near the uterine cavity, which are high risk for sterility or infertility, incision of the myometrium, and suture to the uterine cavity during laparoscopic myomectomy is required, and Caesarean section is frequently selected as the child delivery method. Hysteroscopic myomectomy is advantageous for persons wishing for pregnancy. The abdominal wall is not damaged, and there is less pain and a shorter hospital stay. Hysteroscopic myomectomy does not cause postoperative intraperitoneal adhesion, contraceptive period is shorter, and vaginal delivery is also possible. Since expensive disposal surgical instrument, surgery assistants are not needed, it also contributes to medical economy, and its widespread is desired. On the other hand, learning the technique is difficult, since unique complications may occur and only an endoscope in the specific field of vision, the uterine cavity is used for this procedure. If only cases with small submucosal myoma are indicated for hysteroscopic myomectomy, technical improvement and wider adoption will not occur. However, if the indication can be correctly recognized and a safe and accurate technique be acquired, adoption of hysteroscopic myomectomy could actually be widened. It is an excellent technique which can become mainstream for fibroid treatment.

## Keywords

- ▶ transcervical resection
- ▶ hysteroscopic myomectomy
- ▶ sterility
- ▶ infertility

## Surgical Steps

1. Dilatation of the cervix.  
↓
2. Confirmation of myoma nodules and Fallopian ostia.  
↓
3. Dissection of myoma nodules.  
↓
4. Excision of myoma nodules.  
↓
5. Stop bleeding (coagulation/manual compression).  
↓
6. Confirmation by ultrasound.

## Preoperative Evaluation and Imaging

Understanding the three-dimensional structure of the myoma node, myometrium and endometrium are important to prevent perforation and any remaining myoma. For submucosal myomas with a low-protrusion rate and large sized, the myometrium on the serosal side is stretched and thinned. Consequently, a magnetic resonance imaging (MRI) which clearly visualizes the border of the myoma node and myometrium is essential. Take images in three directions, the sagittal, axial, and coronal planes, for reference, when considering surgical indication and intraoperative orientation. Contrast-enhanced MRI is usually not needed, but carcinosarcomas and endometrial stromal sarcomas tend to protrude into the uterine cavity, so it may be taken. For small submucosal

myomas which are pedunculated or with a high-protrusion rate, transvaginal ultrasound, sonohysterogram, and diagnostic hysteroscope also can be used.

### Selection of Surgical Technique, Indications, and Contraindications

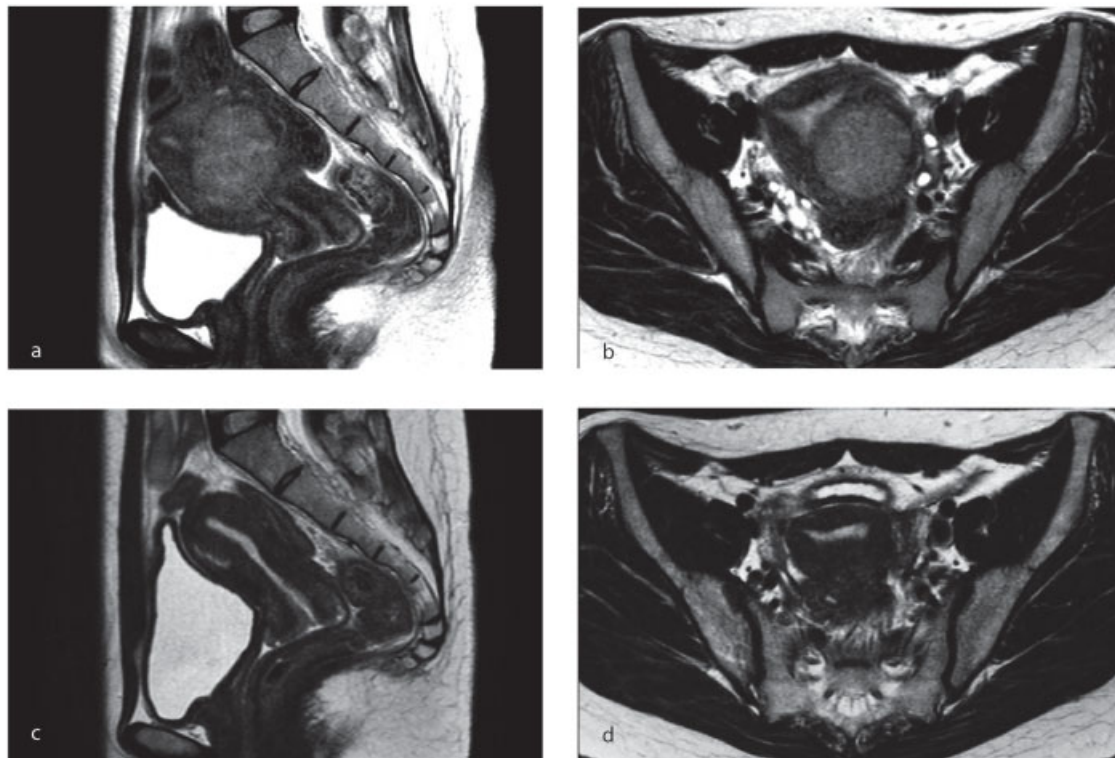
Hypermenorrhea and myoma with anemia are indications. Generally, transcervical resection (TCR) can be used for submucosal myoma, as well as intramural myoma, which are large and multiple, cases where the myometrium on the serosal side is thin and cases caused inner cavity deformity and expansion, depending on operator technique and experience. Myoma dimensions and protrusion rate are the most important factors affecting operation time. Since risk of complication increases as surgery time increases, correctly evaluating one's own techniques and myoma conditions is important when determining indications. It is not unusual for myomas with a maximum diameter exceeding 10 cm to become less than 5 cm with the administration of GnRH $\alpha$  (gonadotropin-releasing hormone agonist). The author administered six doses of 3.75 mg of leuprorelin acetate to patients with large myomas, greatly increasing the number of cases which satisfy as indications. GnRH $\alpha$  definitely reduces endometrium. Usability is

very high, such as to ensure the visual field and to reduce contact bleeding when inserting the scope.

Malignant diseases are a contraindication of TCR. However, cases which are detected by biopsy but cannot be confirmed by other tests are not considered to be a contraindication. In cases with endometritis or salpingitis, there is a possibility of increased inflammation and peritonitis. Hydrosalpinx is not a contraindication if signs of infection are not observed. However care is needed to avoid postoperative infection. Even if the protrusion rate is high, it is not rare to have myometrium on the endometrial side. In such cases, laparoscopic resection is recommended, even when TCR is possible ( $\blacktriangleright$  Fig. 1)

### Preparation Prior to Surgery

- Clinical path ( $\blacktriangleright$  Fig. 2).
- Equipment used, materials ( $\blacktriangleright$  Fig. 3).
  - Resectoscope ( $\blacktriangleright$  Figs. 4 and 5), monopolar, and bipolar, 24- and 26-Fr diameters.
  - Video system (light source and camera) possible use with laparoscope.
  - High-frequency current generator (electric scalpel), general-purpose equipment is possible but specialized equipment is needed for bipolar.



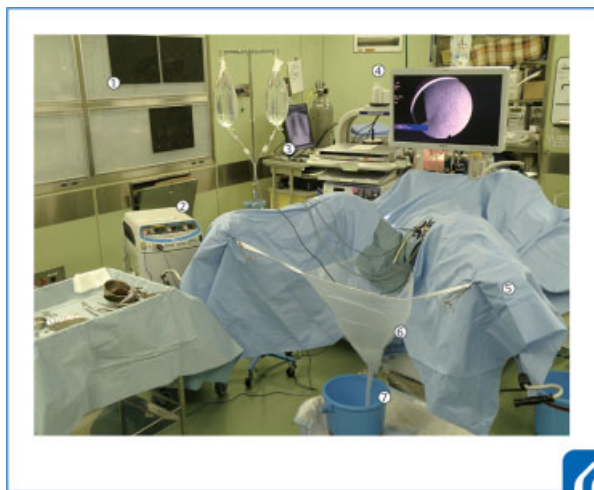
**Fig. 1** Example of laparoscopic excision in cases where TCR is possible, and future childbirth is desired. (A, B) Presurgery MRI. The myometrium can be confirmed on the endometrial side. (C, D) After TCR MRI, the myometrium is restored. (Reproduced with permission from Inoue S. In: Hiramatsu Y, Konishi I, Sakuragi N, Takeda S, eds. *Mastering the Essential Surgical Procedures OGS Now*, No.13. *Function-preserving surgery (Japanese)*. Tokyo: Medical View; 2013:40–53. Copyright © Medical View.) MRI, magnetic resonance imaging; TCR, transcervical resection.

<b>First examination</b>	Surgical method is determined by MRI. Pre-surgery administration of GnRH $\alpha$ for 2-6 months
<b>Hospitalization one day prior to surgery</b>	One Laminaria rod is inserted. Antibiotic agent internal use Antibiotic IV
<b>30 minutes before surgery</b>	General anesthesia, lumbar anesthesia, or intravenous anesthesia
<b>The following morning</b>	If no abnormalities are observed in the blood test or transvaginal ultrasound, the patient is discharged. Antibiotics and analgesics are not prescribed in principle.
<b>One week postoperation</b>	Outpatient examination

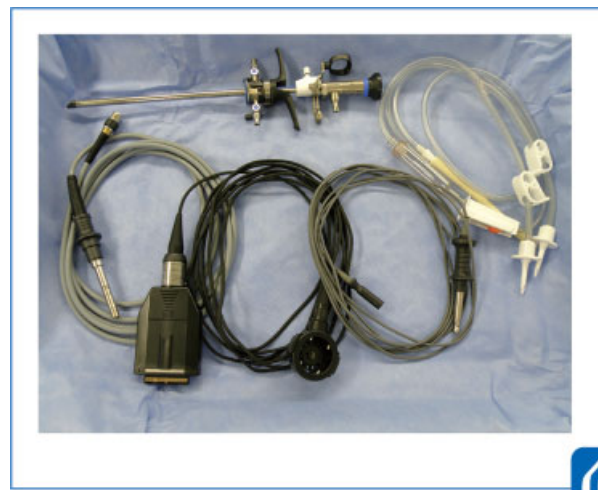(Reproduced with permission from Inoue S. In: Hiramatsu Y, Konishi I, Sakuragi N, Takeda S, eds. Mastering the Essential Surgical Procedures OGS Now, No.13 (Japanese). Tokyo: Medical View; 2013: 40–53. Copyright © Medical View.)



**Fig. 2** Clinical path. (Reproduced with permission from Inoue S. In: Hiramatsu Y, Konishi I, Sakuragi N, Takeda S, eds. Mastering the Essential Surgical Procedures OGS Now, No.13. Function-preserving surgery (Japanese). Tokyo: Medical View; 2013: 40–53. Copyright © Medical View.) GnRH $\alpha$ , gonadotropin-releasing hormone agonist; IV, intravenous; MRI, magnetic resonance imaging.



**Fig. 3** Equipment used. Placement of devices and equipment (lighting is dimmed during surgery). The MRI image: ① is placed where it can be easily referenced at any time. High frequency current generator, ② Irrigation fluid bag, ③ and video system, ④ should be gathered on the left side if the surgeon is right handed. Put the ultrasound on the right side. Placement of the monitor above the patient is ideal. The electric scalpel indicator should be placed where the operator can easily see it. Discharge from Irrigation fluid drains into the pocket ⑥ in the drape ⑤ and is stored in the bucket ⑦. (Reproduced with permission from Inoue S. In: Hiramatsu Y, Konishi I, Sakuragi N, Takeda S, eds. Mastering the Essential Surgical Procedures OGS Now, No.13. Function-preserving surgery (Japanese). Tokyo: Medical View; 2013: 40–53. Copyright © Medical View.)

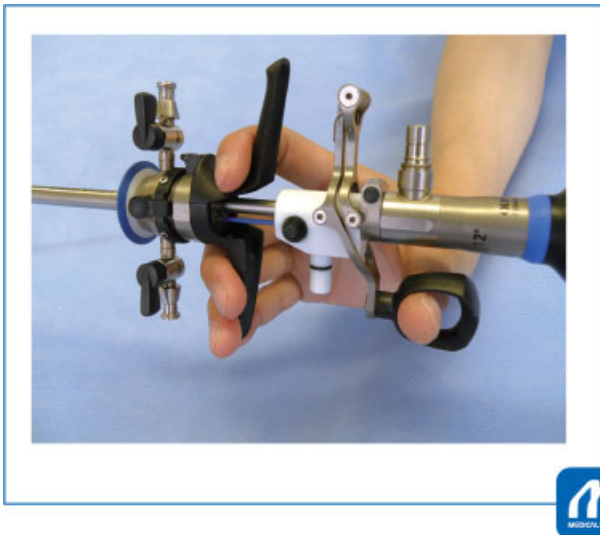


**Fig. 4** Resectoscope cable tube. Although the camera cable can be used in common with laparoscope etc., the camera head for the hysteroscope shown in the photograph has a small diameter cable so it is lightweight and has excellent operability. (Reproduced with permission from Inoue S. In: Hiramatsu Y, Konishi I, Sakuragi N, Takeda S, eds. Mastering the Essential Surgical Procedures OGS Now, No.13. Function-preserving surgery (Japanese). Tokyo: Medical View; 2013: 40–53. Copyright © Medical View.)

**Irrigation FLUID UROMARIC**

Consumable items are electrodes for excision and coagulation, and irrigation fluid. monopolar electrodes can be reused if they are not broken.

Multiple cables (electric scalpel cable, camera cable, light source fiber, and irrigation fluid tube) are connected to the



**Fig. 5** Resectoscope (handle part). (Reproduced with permission from Inoue S. In: Hiramatsu Y, Konishi I, Sakuragi N, Takeda S, eds. *Mastering the Essential Surgical Procedures OGS Now, No.13. Function-preserving surgery (Japanese)*. Tokyo: Medical View; 2013: 40–53. Copyright © Medical View.)

resectoscope, and these cables should be gathered together to either the right or the left. If the surgeon is right-handed, maintain the Tsukahara vaginal forceps in the left hand, and control the scope with the right hand, and control the foot switch with the left foot. The equipment should be located on the left side. To observe the monitor for a long time is tiring and the surgeon must look up and maintain a posture while bending his/her neck. It is easy to lose concentration. If the monitor can be moved by an extension arm, place it on the



**Fig. 6** Resectoscope (tube connector part) inflow and outflow of irrigation fluid. (Reproduced with permission from Inoue S. In: Hiramatsu Y, Konishi I, Sakuragi N, Takeda S, eds. *Mastering the Essential Surgical Procedures OGS Now, No.13. Function-preserving surgery (Japanese)*. Tokyo: Medical View; 2013: 40–53. Copyright © Medical View.)

operating table, and adjust it to the height of the surgeon's line of sight.

- Anesthesia

Choose from general anesthesia, lumbar anesthesia, and intravenous (IV) anesthesia according to difficulty and required time of the surgery.

At the author's facility, there are many cases of large and multiple myoma, but the patient can be discharged on the following day. General anesthesia is chosen for the following reasons at the author's facility:

- Cases where cervical dilatation is difficult, response by IV anesthesia and lumbar anesthesia is not possible.
- Severe headache continues after early discharge from the hospital in cases of lumbar anesthesia.
- Obturator nerve reflexes are not suppressed by lumbar anesthesia.
- In an emergency, if general anesthesia is performed, immediate transfer to laparoscopic myomectomy is possible.
- For IV anesthesia and lumbar anesthesia performed by the surgeon, response to irregular heartbeat when using pitressin is of concern.
- Risk of general anesthesia by laryngeal mask is low.

#### Informed consent

**Bleeding:** there is a possibility of hemorrhage, blood transfusion, discontinuation of surgery, and conversion to laparoscopic or laparotomy surgery when bleeding cannot be stopped.

**Perforation:** rarely, damage to other organs may occur. Conversion to laparoscopic or laparotomy surgery requiring suture repair.

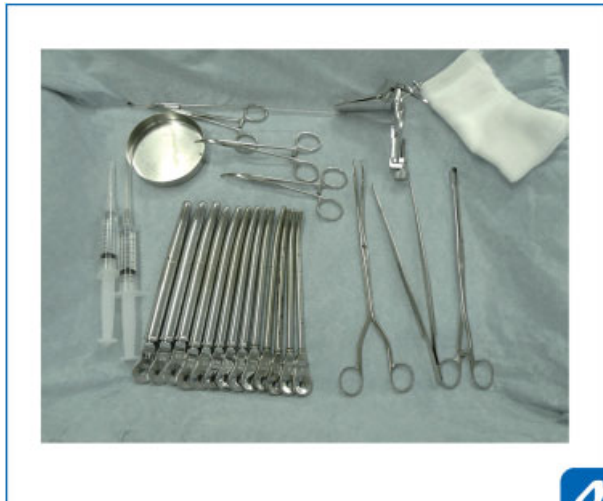
**Recurrence:** there is the possibility of remaining myomas, increase in the number of targeted myomas, remaining/increase of myomas other than those targeted, possibility of new occurrence.

**Water intoxication:** frequency is very low, but when prolonged surgery is expected, the risks are explained.

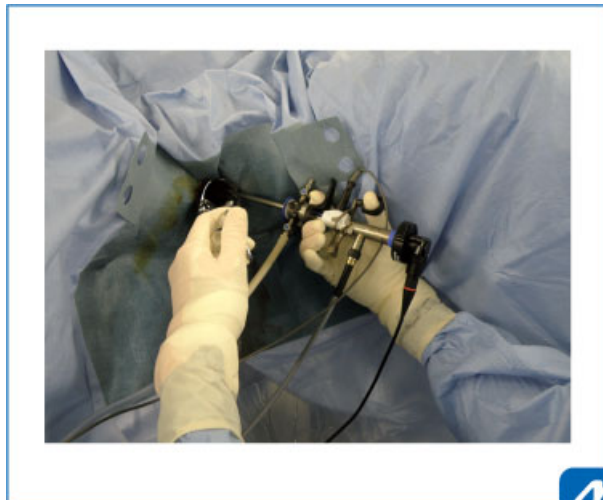
#### In-Depth Explanation

##### Cervical Dilatation

Wear Sakurai's colposcope to confirm the opening of uterus. Nip and hold the posterior lip of the cervical duct using Tsukahara's vaginal forceps, and dilate the cervical canal using Hegar's cervical dilators (no. 17 for 26-Fr scope and up to no. 15 for 24 Fr). The author fully extends the cervical duct to a degree where irrigation fluid can flow out from the gap between the cervical duct and the scope sheath. In cases of cervical duct dilatation without outflow, smooth operation of the scope is difficult, and surgeries with a high degree of difficulty cannot be performed (► **Figs. 7** and **8**). Even in nulliparous cases, expanding up to Hagar's no. 17 by laminaria insertion on previous day is possible. For cases without sexual experience, expansion under full-anesthesia is performed and cervical laceration may occur.<sup>1,2</sup> Bleeding should not be severe, and can be easily stopped by suture by Vicryl 4–0.



**Fig. 7** Required instruments—Hegar dilator, placental forceps, Sakurai Vaginal Speculum, Tsukahara forceps etc. (Reproduced with permission from Inoue S. In: Hiramatsu Y, Konishi I, Sakuragi N, Takeda S, eds. *Mastering the Essential Surgical Procedures OGS Now*, No.13. *Function-preserving surgery (Japanese)*. Tokyo: Medical View; 2013: 40–53. Copyright © Medical View.)



**Fig. 8** Scope insertion. For efficient dissection, the insertion direction of the scope should be adjusted according to the shape of myoma. Sufficient cervix dilation is important to ensure free movement of the scope. (Reproduced with permission from Inoue S. In: Hiramatsu Y, Konishi I, Sakuragi N, Takeda S, eds. *Mastering the Essential Surgical Procedures OGS Now*, No.13. *Function-preserving surgery (Japanese)*. Tokyo: Medical View; 2013: 40–53. Copyright © Medical View.)

## Tips and Warnings

### Electric Scalpel

Place the foot switch and indicator of electric scalpel in a location where the surgeon can visually confirm them. Switching between coagulation mode and cutting mode is frequent and as a result, the electrode is sometimes pressed into the myometrium in the cutting mode, in-

stead of coagulation mode. This may result in perforation. To avoid this, visually confirm the indicator regularly. Start with a lower voltage at approximately 30-W coagulation, 60-W cutting, and use the lowest voltage possible to excise the myoma smoothly. Myomas, which soften due to edema and degeneration, can be cut at a lower voltage but hard myomas with abundant fiber components cannot be cut without increasing voltage to 70 W. Myomas sometimes become calcified. Highly-calcified myomas cannot be cut even if the voltage is increased. For large myomas, at the stage where one is confident that “the part I am cutting now is definitely a myoma,” voltage can be increased in consideration of efficiency. However, when close to the serosal side, do not increase the voltage because a sharp cut may be deeper than expected. When cutting the edge of a pedunculated myoma, the electrode may slip due to unexpected myoma movement, damaging the myometrium on the other side. However, if voltage is not too high, damage will be minor. Generally, electrodes of a resectoscope are used when TCR is monopolar. The current is carried between the counter electrode and electrode, so an electrolyte solution cannot be used for the irrigation fluid. Therefore, TCR may have unique complications, including obturator nerve reflex and water intoxication. To prevent these, a bipolar resectoscope has been developed, and is marketed by Olympus and Stolz. However, an exclusive generator is required and the electrodes, which are consumables, are expensive. Occurrence frequency of obturator nerve reflex is higher than water intoxication, and unpredictable body movement can cause of perforation, for which there are reported cases. This can be suppressed by obturator nerve block; however, occurrence at low voltage is rare.

## Tips and Warnings

### Irrigation Fluid

For the resectoscope, the tube connector has an in and out, as a tract for inflow of irrigation fluid and outflow from uterine cavity (► **Figs. 5** and **6**). If the in/out are connected incorrectly, irrigation cannot be performed well. If a good visual field cannot be ensured after starting surgery, check this. As the route of irrigation fluid flowing out of the body, besides the route from inside the scope, there is natural outflow from the gap between the cervical duct and the scope sheath when the scope is removed. Consequently, the author does not connect the tube on the outside and closes the cock to increase operability. To prevent water intoxication, irrigation volume (reflux pressure) should be at minimum so that blood can be flushed out and the visual field can be ensured. The irrigation fluid inflow cock (► **Fig. 6**) should be opened and closed depending on bleeding and adjusted accordingly. In cases of heavy bleeding, a large amount of irrigation fluid will be needed, but on average, one

pack (approximately 3,000 mL) is consumed in 15 minutes.

## Tips and Warnings

### Intraoperative Ultrasound to Prevent Water Intoxication and Perforation

Water loading that exceeds kidney function causes water intoxication, so irrigation fluid usage “in” and discharge “out” should be measured as a countermeasure. This is useful to estimate the amount of irrigation fluid which enters the body. However, TCR surgery often causes more bleeding per unit time than expected and blood is mixed in the discharge fluid, so it is difficult to identify. In cases of severe bleeding, the influx of irrigation fluid into the body is often underestimated. The most reliable countermeasure is electrolyte determination in surgery.

The inflow path of the irrigation fluid into the body is considered as follows: (1) inflow from cut blood vessels (especially veins); (2) it flows into the abdominal cavity through the fallopian tube or perforation site and is absorbed from the peritoneum; (3) cut arteries that bleeding are closed by coagulation hemostasis. However, veins are easily overlooked because they do not bleed due to irrigation pressure. Veins should also be coagulated. Fluid accumulation is often observed around the uterus by intraoperative ultrasound. A rapid increase strongly suggests perforation of the uterus. Perforation of the uterus does not always cause a rapid, worsening visual field, so this observation is important. Considering the dimensions and permeability of peritoneum, flow of irrigation fluid into abdominal cavity can be presumed to be a major cause of

water intoxication. In other words, perforations of uterus that go unnoticed can cause water intoxication.

If possible, have the assistant perform intraoperative continuous monitoring by transabdominal ultrasound. Clear perforations, such as “the resectoscope is sticking out of the abdominal cavity,” are thought to be rare. Perforations can also be avoided by warnings such as “I’m excising in a thin area in the myometrium,” or “I don’t think I’m excising myoma.”

1. Confirmation of myoma nodules and Fallopian ostia (► **Figs. 9–11**):(see video Roller ball hysteroscopic technique for fundal submucous myoma at: <https://www.youtube.com/watch?v=jiTcrYdAwj4&t=20s>.<sup>3</sup> 10 cm type-2 fibroid hysteroscopic resection. <https://www.youtube.com/watch?v=K8nmkR99GXA&t=7s>.<sup>4</sup> Hysteroscopic resection of a huge myoma weighing 360 g is available at: [https://www.youtube.com/watch?v=\\_kHBAzIORAU&t=173s](https://www.youtube.com/watch?v=_kHBAzIORAU&t=173s).<sup>5</sup>)

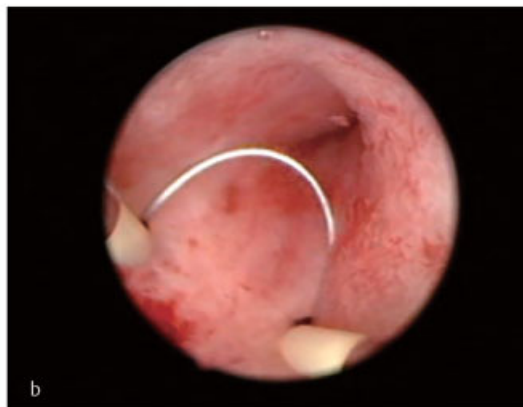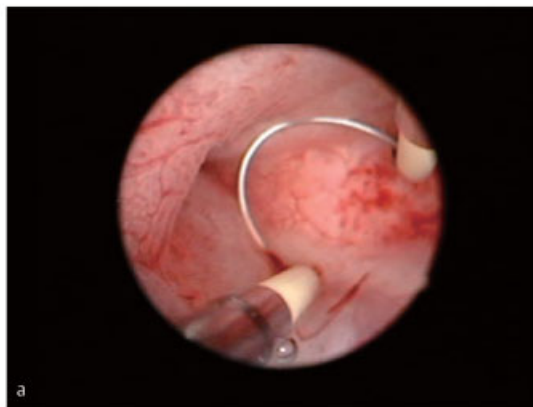With the electrode in the sheath, insert the scope into the uterine cavity at maximum irrigation flow. Remove any blood clots by operating the handle, confirm the uterine ostium of the fallopian tube on both sides, and confirm the number and locations of myomas. Remove the scope once, then locally inject saline-diluted pitressin to reduce bleeding from the myoma and myometrium connected to the myoma.

2. Dissection of myoma nodules (► **Fig. 11**):

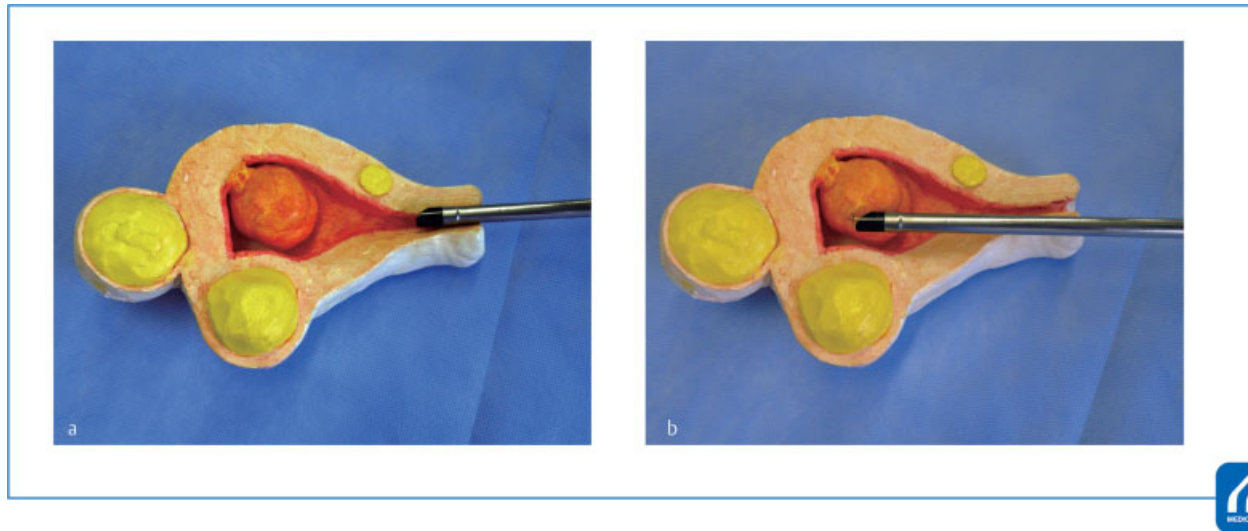
Reinsert the scope, and continue dissection by moving the loop electrode at 200-W coagulation mode along the myoma attachment site.

3. Excision of myoma nodules (► **Figs. 11–14**):

The myoma nodule can be excised even when the resectoscope is rotated 180 degrees and turning the loop electrode downward (► **Fig. 12**). However, dissection is more effective



**Fig. 9** Confirmation of both sides of Fallopian ostium. (Reproduced with permission from Inoue S. In: Hiramatsu Y, Konishi I, Sakuragi N, Takeda S, eds. *Mastering the Essential Surgical Procedures OGS Now*, No. 13. Function-preserving surgery (Japanese). Tokyo: Medical View; 2013: 40–53. Copyright © Medical View.)



**Fig. 10** Resectoscope insertion. Insert the scope into the uterine cavity with the electrode stored inside the sheath. (Reproduced with permission from Inoue S. In: Hiramatsu Y, Konishi I, Sakuragi N, Takeda S, eds. *Mastering the Essential Surgical Procedures OGS Now*, No.13. *Function-preserving surgery* (Japanese). Tokyo: Medical View; 2013: 40–53. Copyright © Medical View.)

when the electrode is in the upward direction. For myomas attached to the posterior wall, proceed with the myoma dissection prior to excision, excision of only myomas can be safely performed using the electrode in an upward direction.

As the myoma is excised, protrusions will disappear. Then once again, proceed with dissection (→**Fig. 11f**). In myoma nodule dissection by laparotomy, the dissecting layer can be observed macroscopically. But precise dissection is possible because the image from the hysteroscope can be enlarged. If the loop electrode cannot be inserted, separate the nodule with the ball electrode. If blunt dissection is easy, do not use the electrical current. However, if there are blood vessels and funicular tissue, pass the current in coagulation mode. If myoma protrusion appears during dissecting operation, excise it with the loop electrode in cutting mode. When inserting the scope into the back, move the loop electrode in coagulation mode forward and backward in small strokes. In this way, if the loop can reach deep within the myoma, a hooking “response” on the myoma protrusion can be felt. If it is small stroke in low-voltage coagulation mode, there is no risk of perforation even if the electrode contacts the myometrium, and in cases where the bleeding point is not clearly identified, a coagulation effect can be achieved. When you can feel the loop electrode caught on the myoma, lightly pull the electrode, and switch to cutting mode to excise the myoma, using caution not to contact the myometrium in the back.

If the myoma has a high-protrusion ratio, dissection may be possible by searching for the boundary of the myoma in the myometrium after shaving up to the height of the surrounding myometrium, but when excising a large myoma, sometimes you do not know “where the electrode is and what is being cut now.” If dissection is performed first, losing sight of the dissection site does not occur, and excising only the myoma is possible. This is a safe procedure.

As the volume of the myoma nodule decreases, the myometrium shrinks and pushes out any remaining myomas. This is promoted by dissection operation. The myome-

trium which was stretched and thinned due to the myoma, shrinks as the myoma volume decreases, and becomes thicker, reducing the risk of perforation.

If slices have not been removed and remain in the cavity, remove them using a placental forceps. The last remaining myoma can be removed as dissection operation continues, but it can be quickly resected by drawing it with placental forceps.

## Tips and Warnings

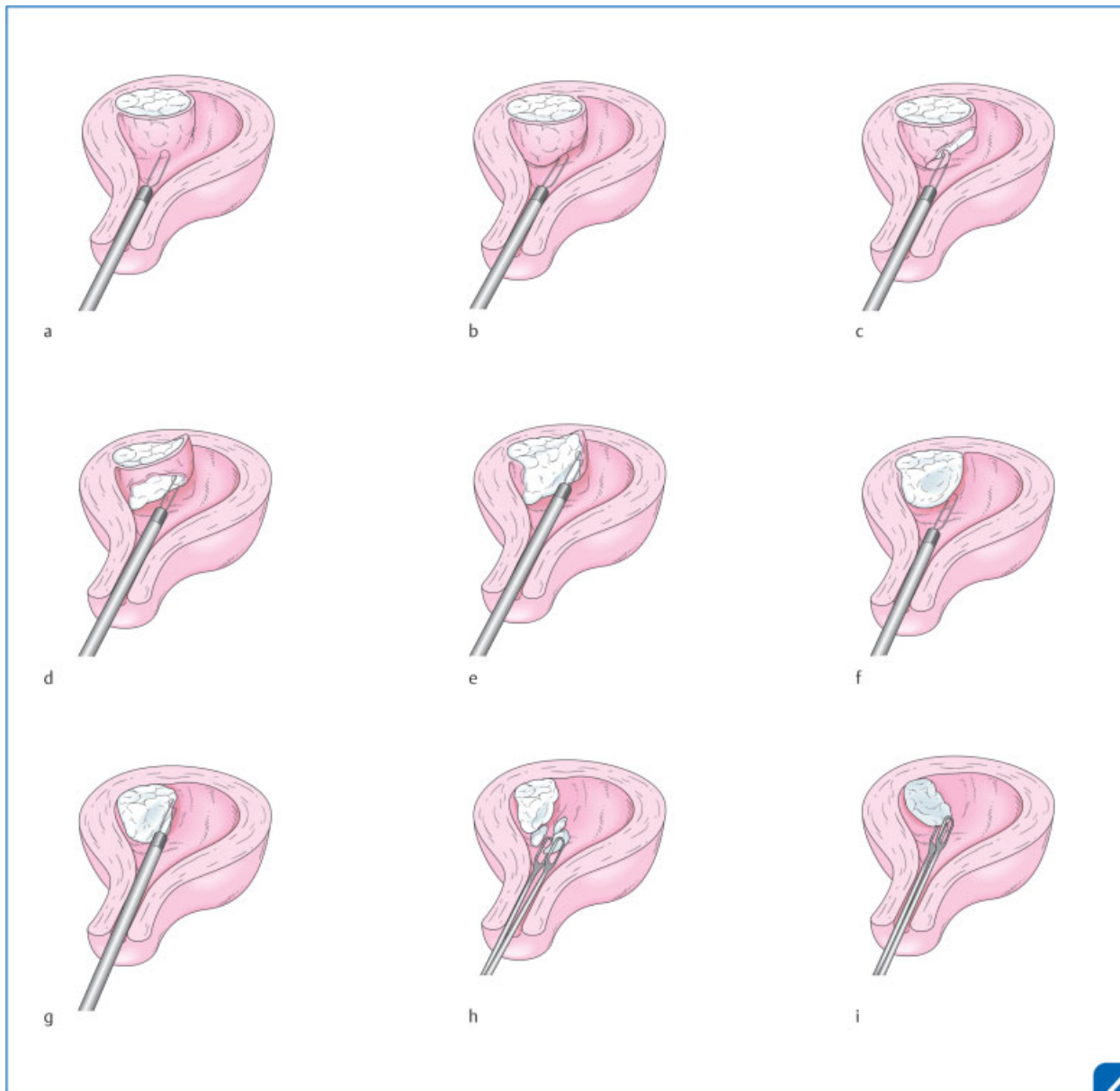
### Recommendation for Successive Removal

Avoid waste due to cutting a separated slice twice, and try to perform successive removal by taking out each myoma slice one by one, to promote myometrium shrinkage as the inner cavity volume is reduced (→**Fig. 14**). Just before excision is finished, turn off the foot switch, release the scope handle, and take out the slice from the uterine cavity as if lightly tearing it off. And place it in the pocket of the drape collecting irrigation fluid. Once accustomed, a slice can be released by lightly shaking the scope outside the body. In this way, excision and removal can be performed in one stroke, and at the same time, the traction effect of the myoma node occurs.

## Tips and Warnings

### Scope Insertion in the Dark

During endoscopic surgery, the lights in the room are dimmed to increase visibility of the monitor screen. Although newer equipment has better definition, a detailed feel and visual recognition of blood vessels are needed for better surgery, so a darker room is recommended. During hysteroscopic myomectomy, the scope is repeatedly removed and inserted. However, if the external os of uterus



**Fig. 11** Myoma on the right posterior wall with a wide base. Excision method that focuses first on dissection of myoma nodules. (A) Dissect the edges of the myoma in coagulation mode, (B) point the loop toward the myoma, move back and forth, (C) excise in cutting mode with the myometrium in the back, (D) dissection can be done efficiently with the loop in the upward direction. (E) Continue to excise the protrusion (f) When the protrusion has been eliminated, dissect it again. (G) The myometrium contracts thickly and the myoma starts to stick out (H) If the section has accumulated, remove with placental forceps (I) Dissect the last slice, and remove it with a forceps also. (Reproduced with permission from Inoue S. In: Hiramatsu Y, Konishi I, Sakuragi N, Takeda S, eds. *Mastering the Essential Surgical Procedures OGS Now*, No.13. *Function-preserving surgery (Japanese)*. Tokyo: Medical View; 2013: 40–53. Copyright © Medical View.)

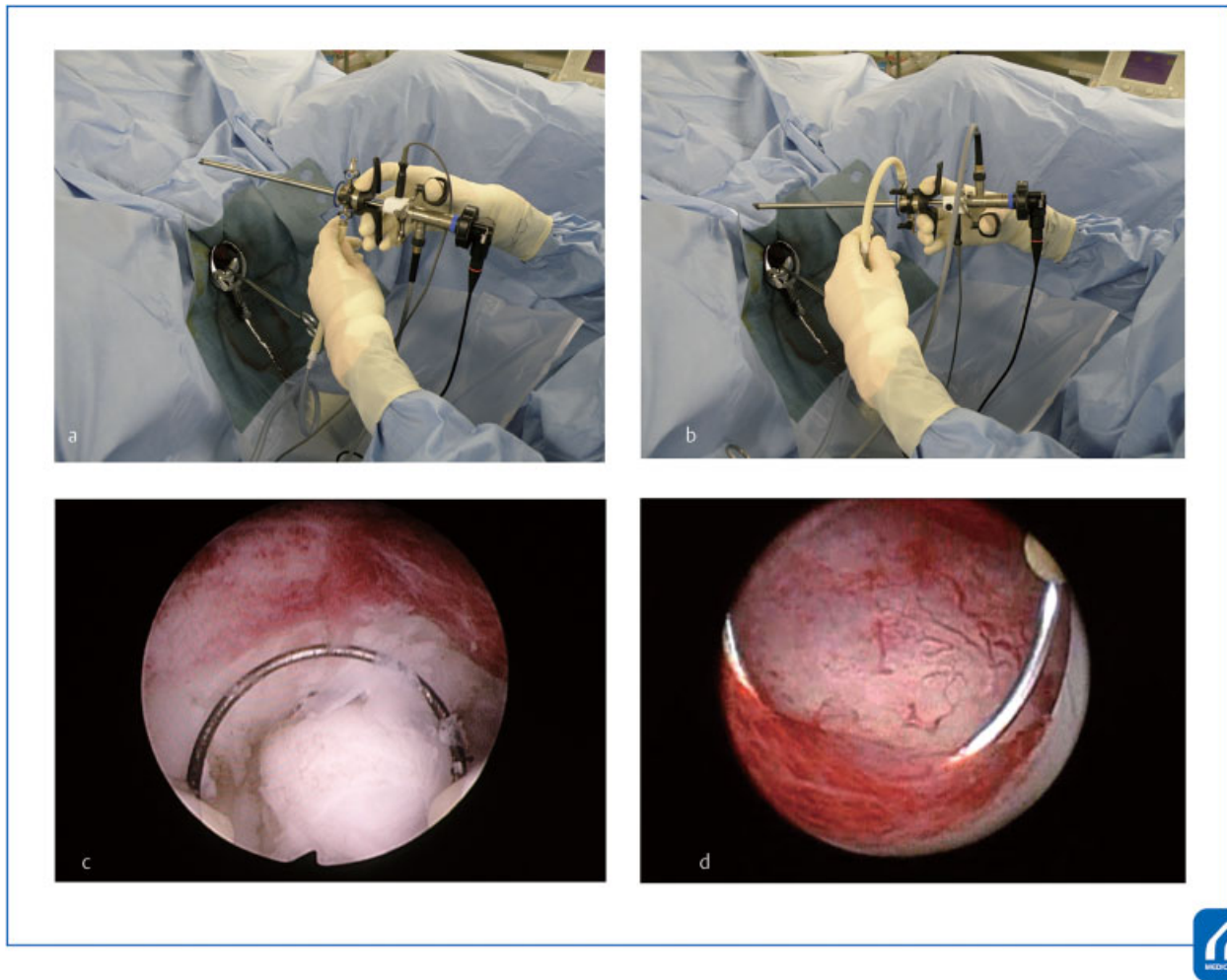
must be confirmed in the dark each time, surgical time will be longer. To smoothly insert the scope, sufficient cervical dilatation is important. Shrinkage sometimes occurs during surgery, so using Hegar's cervical dilators to reextend it when changing electrode or when using placental forceps is recommended. The scope can be inserted without taking one's eyes off to the monitor, by placing the scope on the Tsukahara vaginal forceps, which can grip and hold the cervicovaginal posterior lip.

#### **Tips and Warnings How to Use Placental Forceps**

When taking out a remaining slice in the uterine cavity using placental forceps, uncut myoma is sometimes pulled out. This encourages protrusion of myoma in the uterine cavity, just as pulling a myoma node in laparoscopic myomectomy is important.

Placental forceps can effectively remove myomas. However, forcibly excising a myoma that is solidly





**Fig. 12** Insert the scope upside down. When the scope is rotated 180 degrees, the electrode and the handle are turned upside down. However, the irrigation fluid tube can be rotated, so point it downward. Even if the camera cable is rotated, the top and bottom on the monitor screen will not change. When current is applied in cutting mode, always point the loop electrode toward the myoma. (Reproduced with permission from Inoue S. In: Hiramatsu Y, Konishi I, Sakuragi N, Takeda S, eds. *Mastering the Essential Surgical Procedures OGS Now*, No.13. *Function-preserving surgery (Japanese)*. Tokyo: Medical View; 2013: 40–53. Copyright © Medical View.)

attached to the myometrium, carries the risk of uterine inversion, rupture of the thinned part, damage on the uterine ligament, subserous hematoma of the uterus, etc. Caution is required, especially in cases with a history of myomectomy and Caesarean section. Grab out with placental forceps of only that which can be lightly held is safer.

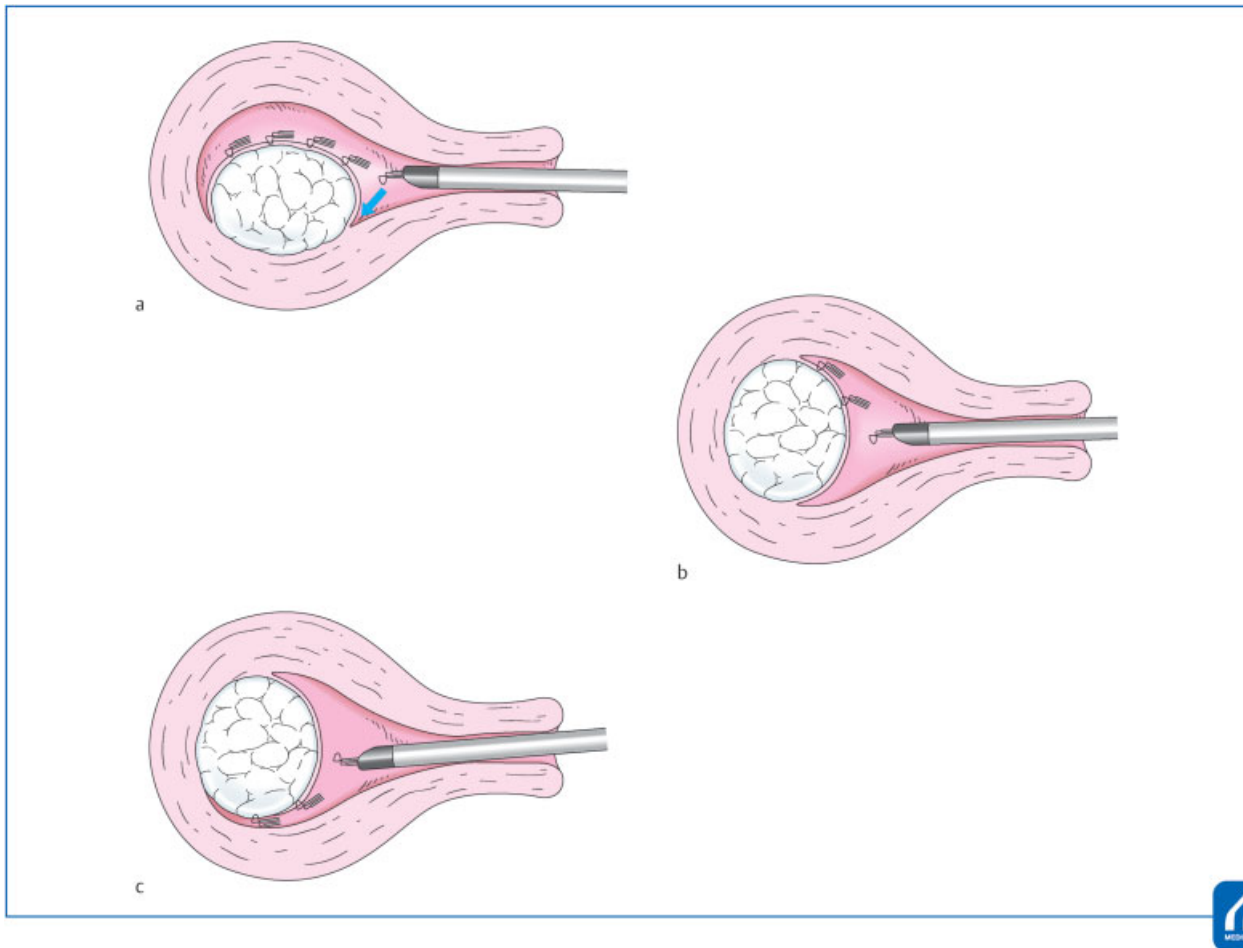
### Tips and Warnings

#### Excision without Perforation

Even if the cardinal rule of “only pass a current when performing loop operation from back to front” is observed, perforation may occur (–Fig. 15). The surrounding condition in the back cannot be fully understood, and

it is difficult to determine where the electrode is within the whole uterus, so cuts in the myometrium may perforate. On the other hand, in the cervical duct and nearby areas, surrounding conditions can be observed within the visual field. So, if an excision is made here, risk of cutting into the other side is reduced. By focusing on dissection, the myoma will come out in front, making this possible.

Identify the myometrium and myoma by the color tone, texture, and feel from the electrode. Try to grasp the slice by hand. Generally, a myoma is harder than the myometrium. However, degenerated myoma is soft, and the myometrium affected by adenomyosis is hard, so it is sometimes difficult to differentiate. Even with years of experience in places, such as the surrounding area of a lobulated myoma, one will sometimes wonder “am I cutting myoma?” At such a time, consult the ultrasound and MRI. Prepare the MRI image in the operation room so that it can be easily reviewed.

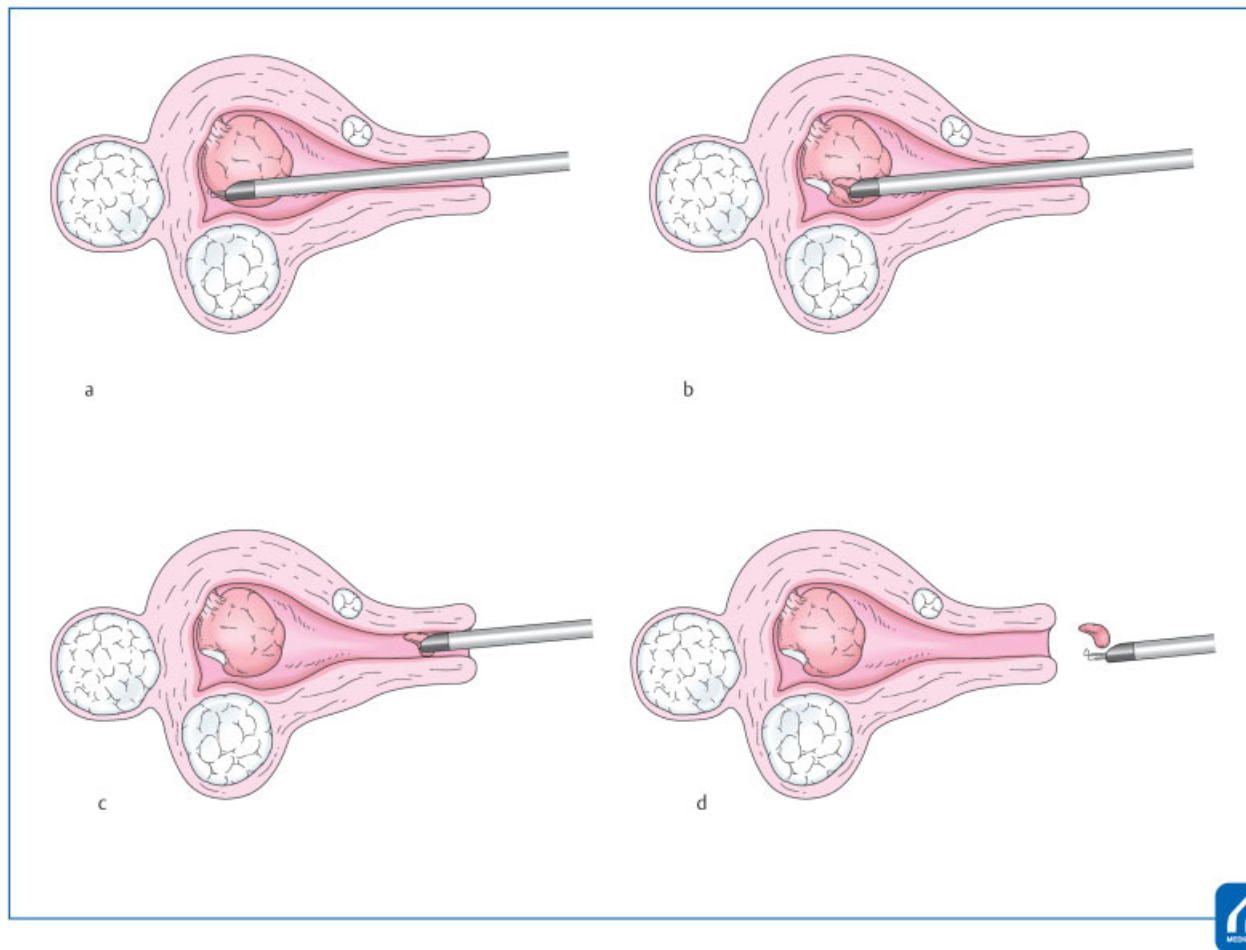


**Fig. 13** Broad based myoma. Myoma nodules before dissection method. (A) If the electrode can be inserted deep into the myoma, excision in large strokes is possible. If the points indicated by the arrow can be dissection points before excision, only the myoma can be excised. (B) Excision efficiency of the bottom of the myoma is poor since the large strokes with the electrode are not possible. (C) As the myoma nodules continue to be dissected, the electrode can enter deep inside the myoma. Excision of the myoma can be safely performed in the direction toward the center of the uterine cavity with the myometrium in the back. (Reproduced with permission from Inoue S. In: Hiramatsu Y, Konishi I, Sakuragi N, Takeda S, eds. *Mastering the Essential Surgical Procedures OGS Now*, No.13. *Function-preserving surgery* (Japanese). Tokyo: Medical View; 2013: 40–53. Copyright © Medical View.)

#### 4. Stop bleeding (coagulation/manual compression):

As irrigation inner pressure increases, bleeding from minute blood vessels temporarily stop. This is useful to ensure the visual field during operation. However, as pressure decreases, bleeding will occur, so this cannot be called a hemostatic method. Cases of bleeding during TCR which are difficult to stop include (1) large intramural myomas (large contact dimensions with the myometrium, and rich vascular network around the myoma), (2) Multiple intramural myomas (poor myometrial contraction), (3) When cutting into the myometrium of the uterine side where branches of uterine artery are located, etc. In such cases, uterine contraction is important as a hemostatic mechanism. Compression on the cavity using a balloon is not recommended because it hinders uterine shrinkage. Basics of hemostasis are suture and compression. However, in TCR, the same manner as uterine bleeding at delivery/recover, compression is basic. After ergometrine and a hemostatic agent are intravenously injected and urethral catheterization, insert two/three pieces of gauze into the vagina, and

press the uterus from the vagina and abdominal wall using a pelvic examination procedure (bimanual compression of the uterus → **Fig. 16**). Change the gauze approximately in every 10 minutes and confirm hemostasis. Once bleeding has decreased, insert the laparoscope, and coagulate the blood vessel using the ball electrode as much as possible, and continue compression. If bleeding still does not decrease, inject prostaglandin F<sub>2α</sub> in the uterine corpus locally, and continue compression. If bleeding still does not stop, prepare for a blood transfusion, and consider suturing with the laparoscope. If the bleeding is caused by perforation, suturing is effective for hemostasis. For bleeding which was not caused by perforation, uterine artery embolization is useful. However, emergency performance is not always possible. In a case where bleeding without perforation and which did not stop even after suturing the uterine wall, the author could stop the bleeding by tying off both sides of the uterine artery. In this case, menstrual period started again. Patients who wish to have hysteroscopic myomectomy and have a strong desire to



**Fig. 14** Successive removal of myoma slices. (A) The electrode is exposed deep inside of myoma. While turning on the cutting mode with the foot switch, move the scope to the front and excise the myoma. (B) The electrical current is stopped just before finishing excision. Grasp the excised myoma slice between the electrode and the sheath, and then pull the scope forward. (C) Remove the scope while holding the excised myoma slice. (D) Extend the electrode outside the tissue body and remove the myoma. (Reproduced with permission from Inoue S. In: Hiramatsu Y, Konishi I, Sakuragi N, Takeda S, eds. *Mastering the Essential Surgical Procedures OGS Now*, No.13. *Function-preserving surgery* (Japanese). Tokyo: Medical View; 2013: 40–53. Copyright © Medical View.)

preserve their uterus, avoiding a total hysterectomy is desired as much as possible.

Vasopressin is widely used to control bleeding during laparoscopic myomectomy. Although there is no evidence of bleeding control in TCR, the author has transcervically injected it in almost all cases. Almost no uterine contraction is expected. Side-effects include irregular pulse, cardiac arrest, and pulmonary edema. Increased risk of water intoxication due to antidiuretic effect is also present. For cases with asthma, use is not recommended.

If PGF $2\alpha$  (ProstaglandinF $2\alpha$  [Dinoprost]) is used in the myoma with lower protrusion rate after excision of a protrusion, myoma nodules protrude due to strong contraction of the myometrium, making excision easier. Ergometrine is used for the same purpose as PGF $2\alpha$ , but with lower effect. It is not locally injected, but administered by IV. It can be used in cases with asthma.

##### 5. Confirmation by ultrasound:

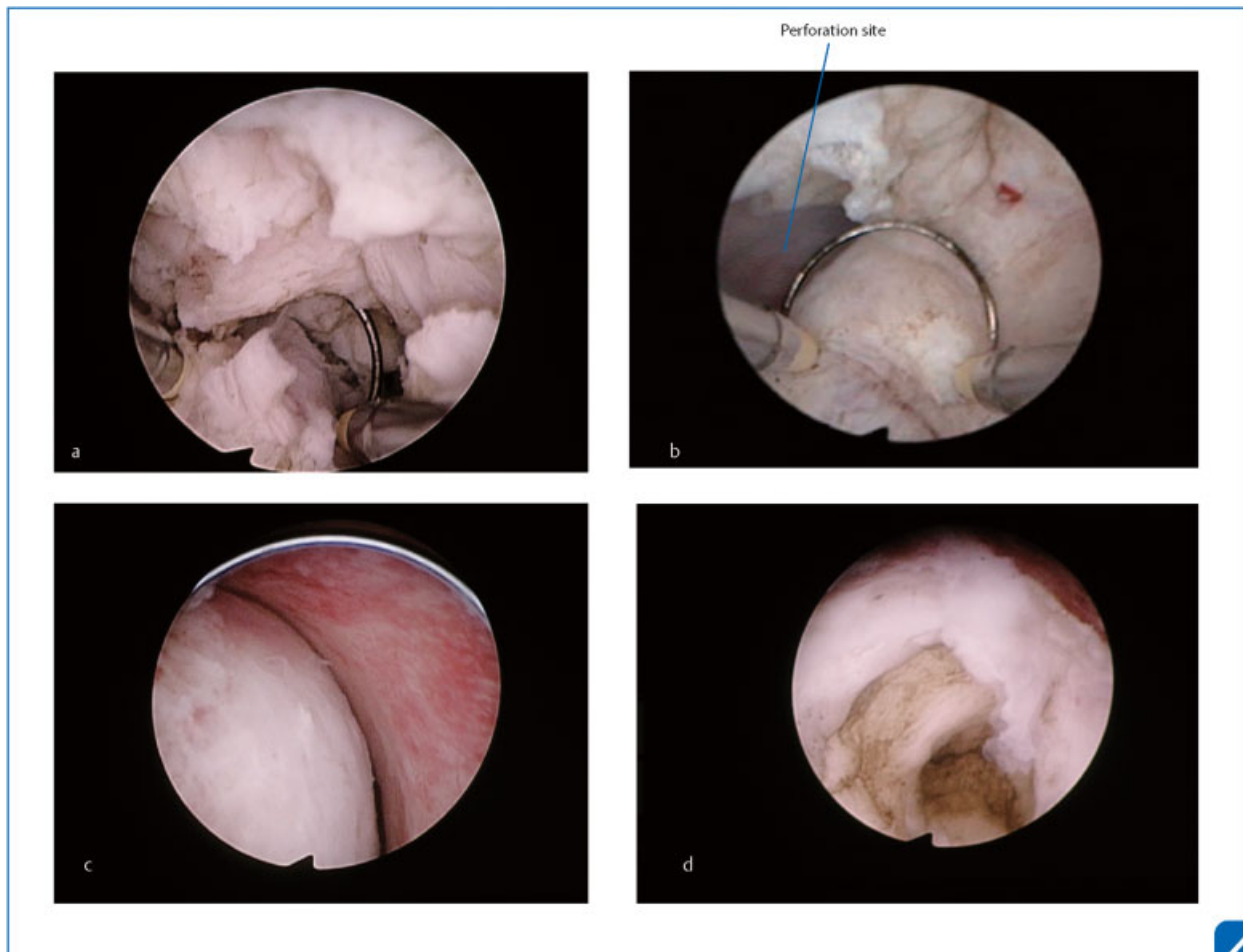
Transvaginal injection is better than transabdominal. Even if the monitor is omitted during surgery, postoperative confirmation by ultrasound is recommended. Record any remaining myomas and fluid accumulation around the uterus.

## Tips and Warnings

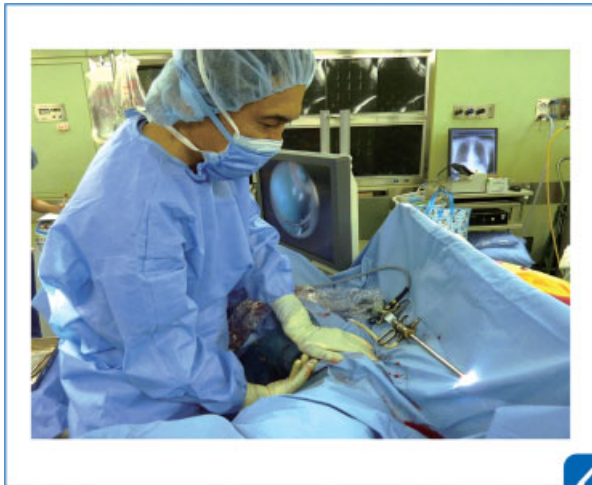### Prevention of Postoperative Adhesion

One opinion is to “insert intrauterine device (IUD) to prevent intrauterine adhesion, and enhance regrowth of the endometrium by estrogen.” However, there is no evidence to this. In most cases where the author has performed TCR for large myomas, IUD is thought to drop rapidly, so it is not performed. In addition, preoperative pseudomenopause therapy with GnRHa is performed in almost all cases, although hurried regrowth the endometrium is not considered to have any significance. Approximately 10 weeks after the final GnRHa injection, menstrual period starts again. Sexual intercourse is not restricted during that time but birth-control is recommended.

Even in cases where a thinned myometrium on the serosal side was observed by preoperative MRI, restoration of myometrium can be confirmed by postoperative



**Fig. 15** Excision without perforation. (A, B) In deep sections, positional relationship with the myometrium is difficult to determine, and perforation while trying to excise the myoma may occur. (C, D) When myoma protrudes from a shallow area where the relationship with the myometrium can be determined as the myoma nodules are dissected, the myoma alone can be excised. (Reproduced with permission from Inoue S. In: Hiramatsu Y, Konishi I, Sakuragi N, Takeda S, eds. *Mastering the Essential Surgical Procedures OGS Now*, No.13. *Function-preserving surgery (Japanese)*. Tokyo: Medical View; 2013: 40–53. Copyright © Medical View.)



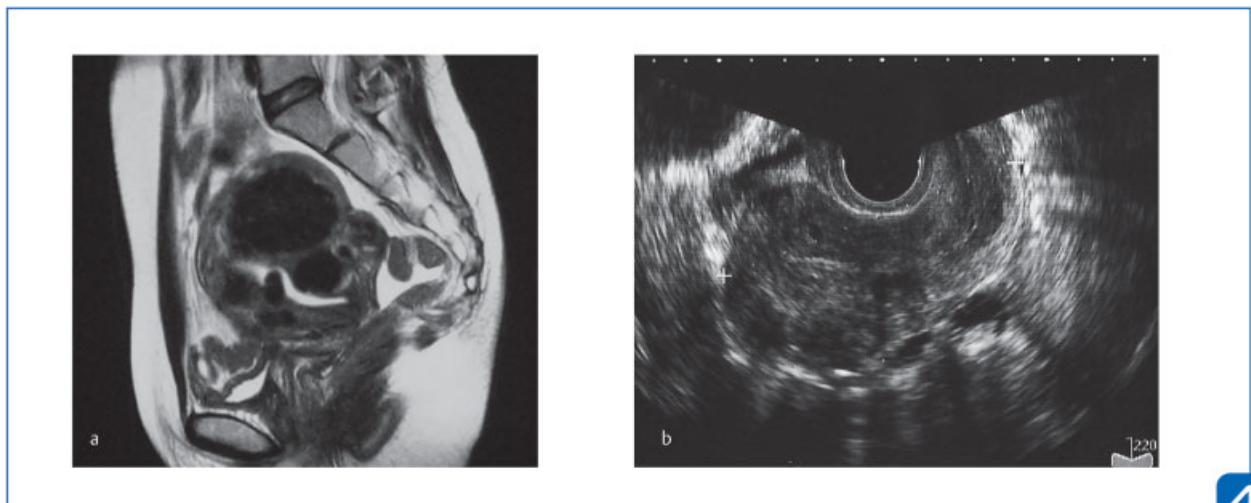
**Fig. 16** Bimanual compression of the uterus. (Reproduced with permission from Inoue S. In: Hiramatsu Y, Konishi I, Sakuragi N, Takeda S, eds. *Mastering the Essential Surgical Procedures OGS Now*, No.13. *Function-preserving surgery (Japanese)*. Tokyo: Medical View; 2013: 40–53. Copyright © Medical View.)

MRI (→ Fig. 17). If the myometrium is not excised or ruptured, vaginal delivery is considered possible. However, in cases indicated for TCR, avoiding damage to the endometrium cannot be completely ensured, so an explanation that “defective endometrium can be regrown and recover, but there is a risk of placental polyps and placenta accreta.” HSG is recommended to prevent adhesion. Minor adhesions can be resolved by inserting a “Hyscath” (catheter for fallopian tube patency test) and injecting a contrast agent.

## Tips and Warnings

### How to Improve TCR Techniques

To improve TCR techniques, become accustomed to the three-dimensional movement of the scope, taking the



**Fig. 17** Cases of baby achievement. (A) TCR performed for submucosal myoma, and laparoscopic surgery for subserosal and intramuscular myomas at the same time. (B) Eighty days after surgery transvaginal ultrasound. (Reproduced with permission from Inoue S. In: Hiramatsu Y, Konishi I, Sakuragi N, Takeda S, eds. *Mastering the Essential Surgical Procedures OGS Now*, No.13. *Function-preserving surgery* (Japanese). Tokyo: Medical View; 2013: 40–53. Copyright © Medical View.)

sheath in and out, stepping on and off the foot pedal to switch between coagulation and cutting modes, which is determined according to the monitor image and feeling of the electrode, and the smooth collaborative coordination of these movements. TCR greatly differs from abdominal surgery and laparoscopic surgery only in the fact that surgery is performed in a smaller visual field, which is usually the uterine cavity, only using the scope. Laparoscopic surgery is similar to endoscopic surgery, but when using a laparoscope, such as in abdominal surgery, the overall visual field can be seen and cutting, dissecting, disconnecting, suturing, and tying are possible.

In TCR, an overall visual field is difficult, and suturing and tying are not possible. In TCR, the three-dimensional structure of MRI equipped in the head, the image on the monitor screen, and the feel of the tissue obtained from the electrode must be relied on. The author reviews the MRI image after each surgery, and considers the structure captured prior to surgery, whether the operation devel-

oped as expected, and seeks to improve MRI image interpretation ability.

**Conflict of Interest**  
None.

#### References

- 1 Inoue S. Safe and certain procedure of hysteroscopic myomectomy: myoma nodule, dissection centripetal cutting method. *Acta Obstet Gynecol Jpn* 2015;67(05):1420–1427
- 2 Inoue S. Hysteroscopic myomectomy TCR (transcervical resection). *Standard Methods for Obstetric and Gynecologic Operations*. 2nd ed. Medical View Co Ltd.; 2017:188–195
- 3 Roller ball hysteroscopic technique for fundal submucous myoma <https://www.youtube.com/watch?v=jiTcrYdAwj4&t=20s>
- 4 10 cm type2 fibroid hysteroscopic resection. <https://www.youtube.com/watch?v=K8nmkR99GXA&t=7s>
- 5 Hysteroscopic resection of a huge myoma weighing 360 g [https://www.youtube.com/watch?v=\\_kHBAzi0RAU&t=173s](https://www.youtube.com/watch?v=_kHBAzi0RAU&t=173s)