




# Retrocondylar Far-Lateral Approach for Resection of a Craniocervical Junction Hemangioblastoma

Alexander X. Tai<sup>1</sup> Kathleen Knudson<sup>2</sup> Walter C. Jean<sup>2</sup> 

<sup>1</sup>Department of Neurosurgery, Georgetown University, Washington, District of Columbia, United States

<sup>2</sup>Department of Neurosurgery, George Washington University, Washington, District of Columbia, United States

**Address for correspondence** Alexander X. Tai, MD, Department of Neurosurgery, Georgetown University Hospital, 3800 Reservoir Road Northwest, 7th Floor PHC, Washington, DC 20007, United States (e-mail: Axt2@georgetown.edu).

J Neurol Surg B 2019;80(suppl S4):S349–S351.

## Abstract

We present a case in which a retrocondylar far-lateral approach was utilized to resect a hemangioblastoma at the craniocervical junction. The patient was a 33-year-old man presenting with 2 months of symptoms referable to compression at the craniocervical junction (i.e., dizziness and gait instability). Though neurologically intact on exam, his imaging demonstrated a highly vascular cystic lesion dorsolateral to the medulla on the left consistent with a hemangioblastoma. Virtual reality software was critical to visualize the patient's lesion in relationship to the vertebral artery and draining vein (► **Fig. 1**). A far-lateral retrocondylar suboccipital craniectomy with a C1 hemilaminectomy permitted resection of this lesion. The operative strategy was to address the lesion similar to an arteriovenous malformation by detaching the lesion from its arterial feeders first, and then addressing the lesion's draining vein (► **Fig. 2**). Postoperative imaging demonstrated a gross-total resection and the patient had an uncomplicated postoperative course. This case demonstrates not only the lateral reach of a retrocondylar far-lateral approach; but also, clearly demonstrates an effective dissection strategy when approaching a hemangioblastoma.

The link to the video can be found at: <https://youtu.be/M0szMODhjfE>.

## Keywords

- far-lateral approach
- craniocervical junction
- hemangioblastoma
- retrocondylar



[www.thieme.com/skullbasevideos](http://www.thieme.com/skullbasevideos)

[www.thieme.com/jnlsbvideos](http://www.thieme.com/jnlsbvideos)

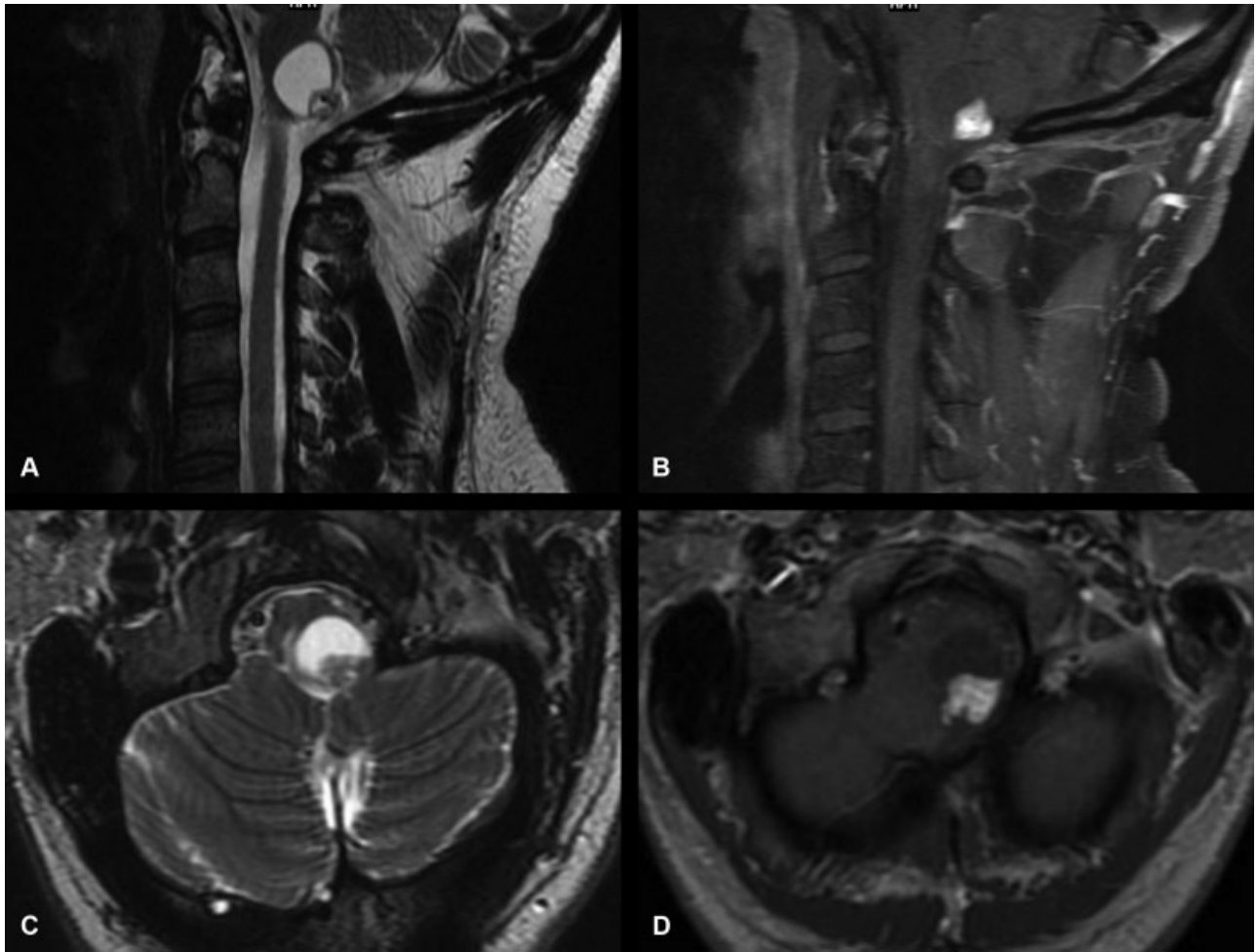
received  
February 28, 2019  
accepted  
August 25, 2019  
published online  
October 22, 2019

DOI <https://doi.org/10.1055/s-0039-1698821>.  
ISSN 2193-6331.

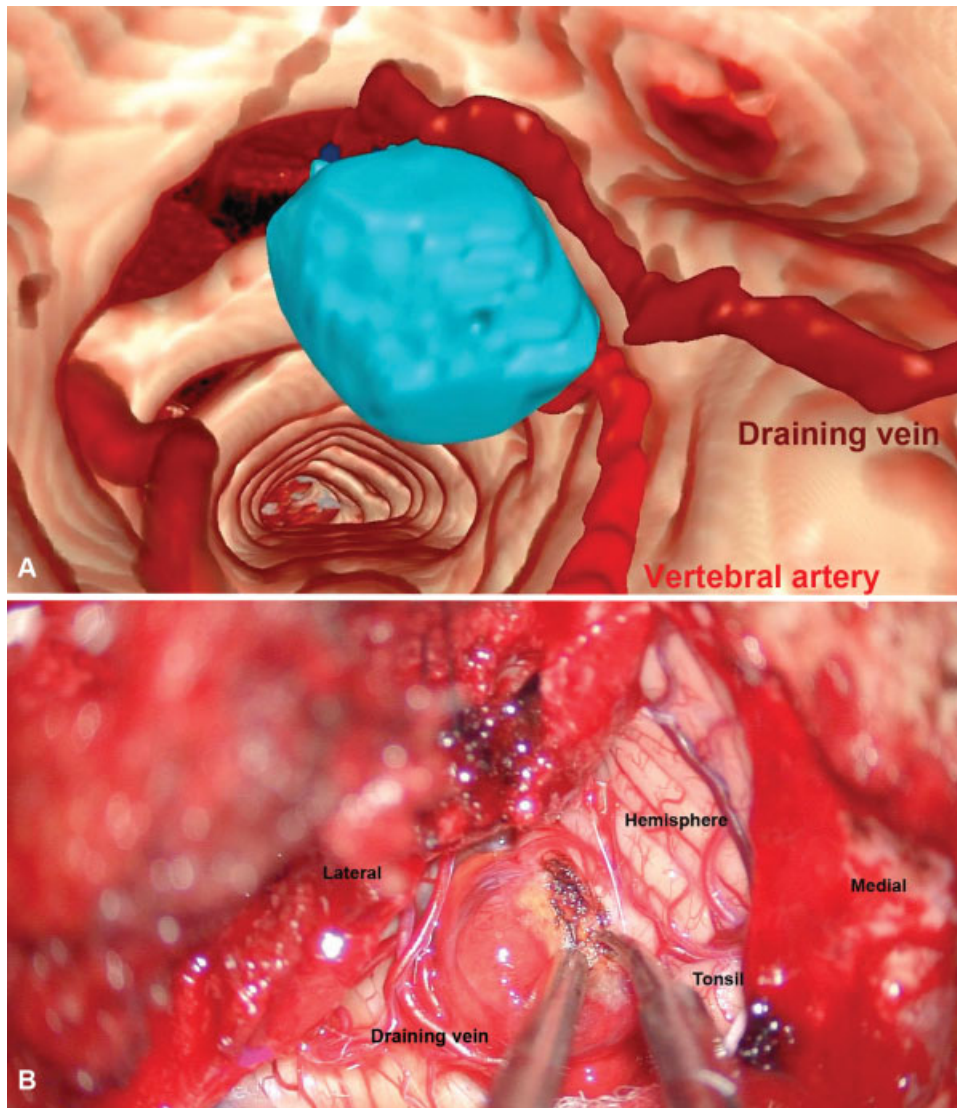
© 2019 Georg Thieme Verlag KG  
Stuttgart · New York

License terms





**Fig. 1** Preoperative imaging of a craniocervical hemangioblastoma. (A, C) T2-weighted axial and sagittal MRI imaging demonstrates a cystic lesion dorsolateral to the medulla causing medullary compression. (B, D) T1-weighted postcontrast sagittal and axial MRI imaging demonstrates the cystic lesion has a peripherally enhancing mural nodule. MRI, magnetic resonance imaging.



**Fig. 2** Three-dimensional modeling and intraoperative images of craniocervical hemangioblastoma. (A) Using virtual reality software, a three-dimensional model of the lesion and associated cerebrovasculature was recreated. (B) intraoperative imaging demonstrates the relationship of anatomic structures to the lesion and the draining vein.

### Publication Comment

The authors present a video of a patient with a craniocervical junction hemangioblastoma which was treated with a far-lateral retrocondylar approach. During this video the authors clearly exhibit the use of virtual reality to explain the adequate concepts of the surgical strategy. I commend the authors for the good result.

Diego Mendez Rosito, MD  
CMN 20 de Noviembre  
Mexico City, Mexico

### Disclosures

None.

### Conflict of Interest

None declared.