

Case Report

Nevus Sebaceous: Response to Erbium YAG laser ablation

Vijay Aithal

Department of Dermatology, St. John's Medical College and Hospital, Bangalore, India

Address for correspondence: Dr. Vijay Aithal, Department of Dermatology, St. John's Medical College and Hospital, Sarjapur Road, Bangalore - 34, India. E-mail: vijay_aithal@hotmail.com

ABSTRACT

The potential of nevus sebaceous to undergo malignant change has prompted many physicians to undertake surgical excision of these lesions. Debulking surgery would leave an ugly scar, cosmetically not acceptable. Our aim was to find the therapeutic outcome and the final cosmetic appearance with Erbium YAG Laser ablation. A 19 year old boy with histologically proven Nevus Sebaceous over the forehead was taken up for ablation using Erbium YAG Laser. We also analyzed the post-operative results in another 6 patients who underwent Laser ablation of Nevus Sebaceous. All 7 patients did well, with no signs of recurrence. Also, all of them had a scar over the ablated area, which was cosmetically acceptable to them. Surgical excision with or without flap rotation, electro fulguration and Cryotherapy are other modalities to treat these lesions. However, they are either too expensive or leave a telltale scar. Erbium YAG Laser ablation is safe, effective and cosmetically acceptable in the treatment of Nevus Sebaceous.

KEY WORDS

Nevus Sebaceous, Erbium YAG Laser

INTRODUCTION

The potential of nevus sebaceous to undergo malignant change has prompted many physicians to undertake surgical excision of these lesions. Debulking surgery would leave an ugly scar, cosmetically not acceptable. Our aim was to find the therapeutic outcome and the final cosmetic appearance with Erbium YAG Laser ablation.

CASE REPORT

A 19 year old boy presented with a boggy asymptomatic

swelling over the left side of his forehead, present since childhood with an increase to the present size since 12 years.

It measured about 8 cm. in length and 6 cm. in width. The surface looked hyperpigmented and had a cobble stone appearance. Few areas of atrophy were noted [Figure 1]. A skin biopsy was done and subjected to histopathological examination. It confirmed the diagnosis of Sebaceous Nevus [Figure 2].

After proper counseling and a written informed consent from the patient, he was taken up for Laser ablation using

the Erbium YAG 2.94 machine. Before the complete ablation, a small area of about 1 cm. diameter in the retro-auricular area was tested with the Erb. YAG machine for any complications. It was noted that there was no post-operative pigmentation or scarring in this test area, after which he was taken up for complete ablation.

Lignocaine with Adrenaline was injected into and around the base of the lesion, to acquire sufficient anesthesia and hemostasis. Starting with a spot size of 2 mm and 0.6J strength, we went on to 3.5 mm spot size and 1.2J strength, requiring totally 8 to 10 passes for complete ablation. Patient tolerated the procedure well; excessive bleeding was controlled with Adrenaline soaks and pressure. A pressure bandage was given after dressing the raw area with antibiotic cream and paraffin embedded

gauze. Since the area ablated was bleeding excessively, dressing was changed once in 2 days only.

The ablated site healed with complete epithelization after two weeks. Two months after the surgery, there was minimal erythema and a puckered scar [Figure 3]. The erythema disappeared completely after 6 months. The thickness and area of the scar also reduced considerably after 6 months [Figure 4].

DISCUSSION

Nevus Sebaceous of Jadassohn is a hamartoma arising from the sebaceous glands. Tumors both benign and malignant have been reported to arise from the Sebaceous Nevus, some of the commoner ones being Basal cell

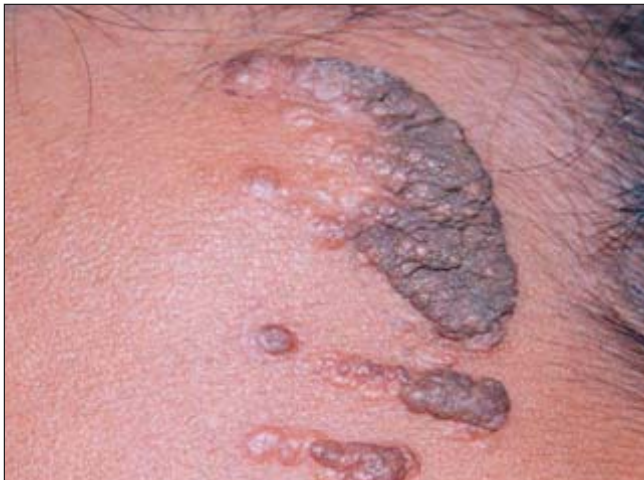

Figure 1: Pre-operative photographs

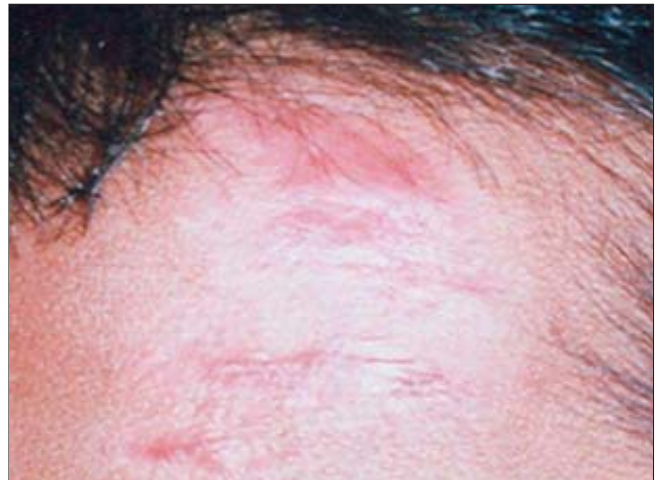


Figure 3: Post-operative, after 2 months

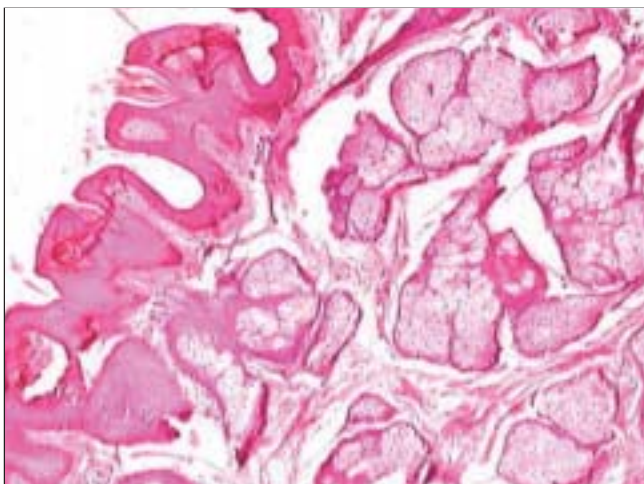


Figure 2: Histopathological examination, confirming Nevus Sebaceous (H/E, x100)

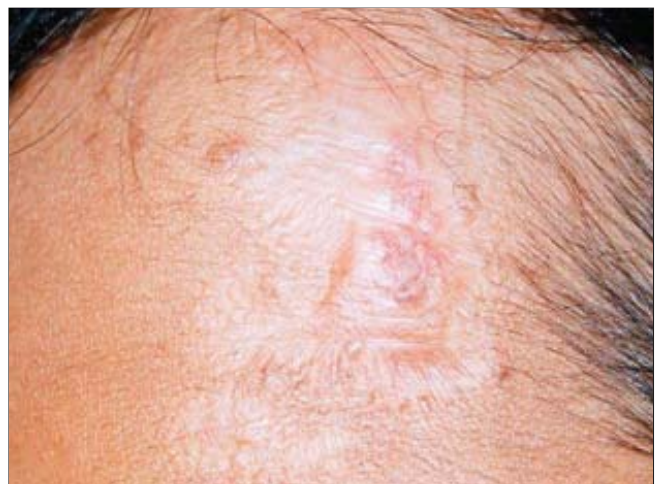

Figure 4: Post-operative, after 6 months

epithelioma^{4,5,7} and Syringocystadenoma papilliferum.^{6,7} Other rare tumors that have been described include Malignant melanoma,¹ Squamous cell carcinoma,^{3,4,7} Keratoacanthoma,^{5,7} Trichilemmal cyst,⁶ Syringomata⁷ and Osteomata.⁷

Due to the high malignant potential, early recognition and excision is recommended.

Various techniques including cold steel surgery, Cryotherapy, Electrocautery Radio frequency surgical ablation and Laser excision have been described. Laser surgery has revolutionized the excision of these tumors. There are however, still a few people, who feel surgical excision is mandatory, in order to examine the specimen for any histological changes suggestive of malignancy.⁵

Commonly, Argon and CO₂ Lasers are frequently used. The advantages with these machines are faster removal and lesser bleeding. However, the amount of scarring that occurs is also more. We have successfully ablated a huge Sebaceous Nevus using the Erbium YAG Laser machine. Another 6 patients with smaller lesions over the forehead and scalp also benefited from this technique.

Erbium YAG Laser with a wavelength of 2940 nm is used as an ablative machine for many dermatological conditions like Seborrheic keratosis, actinic keratosis, epidermal nevus, lentigenes etc. It does not have a hemostatic effect and hence is restricted to lesions situated in the epidermis; or at the most in the papillary dermis. Sebaceous Nevus is quite deep seated in the dermis and occurs in areas rich in Sebaceous gland distribution, like face and scalp. These areas are

particularly difficult to treat, owing to their high vascularity. We too had difficulty in controlling the post-operative bleeding, but were finally able to do so with pressure bandage. To the best of our knowledge, ablation using an Erbium YAG Laser has not been described so far.

Most of the procedures described above leave a definite tell-tale sign, which is aesthetically unappealing. The scar left behind when using an Erbium YAG Laser is very superficial, and with adequate measures like silastic gel sheet occlusion, can be easily flattened to look insignificant.

REFERENCES

1. Abe S, Yamamoto Y, Uno S, Andou M, Akasaka T, Mihm MC. Malignant melanoma arising in a sebaceous nevus of the scalp. *Br J Plast Surg* 2003;56:171-3.
2. Marlowe FI, Cron C. Linear nevus sebaceous of Jadassohn. *Laryngoscope* 1979;89:666-70.
3. Hidvegi NC, Kangesu L, Wolfe KQ. Squamous cell carcinoma complicating naevus sebaceous of Jadassohn in a child. *Br J Plast Surg* 2003;56:50-2.
4. Dunkin CS, Abouzeid M, Sarangapani K. Malignant transformation in congenital sebaceous naevi in childhood. *J R Coll Surg Edinb* 2001;46:303-6.
5. Beer GM, Widder W, Cierpka K, Kompatscher P, Meyer VE. Malignant tumors associated with nevus sebaceous: therapeutic consequences. *Aesthetic Plast Surg* 1999;23:224-7.
6. Stavrianeas NG, Katoulis AC, Stratigeas NP, Karagianni IN, Patertou-Stavrianea M, Varelzidis AG. Development of multiple tumors in a sebaceous nevus of Jadassohn. *Dermatology* 1997;195:155-8.
7. Jones EW, Heyl T. Naevus Sebaceous: A report of 140 cases with special regard to the development of secondary malignant tumours. *Br J Derm* 1970;82:112-7.
8. Margulis A, Bauer BS, Corcoran JF. Surgical management of the cutaneous manifestations of linear nevus sebaceous syndrome. *Plast Reconstr Surg* 2003;111:1043-50.