

## Case Report

# Lingual cysticercosis

**S. C. Pandey, \*S. D. Pandey**

Dental Surgeon, Provincial Medical and Health Services of the State of U.P., \*Professor Emeritus ; King George's Medical University, Lucknow.

**Address for correspondence:** Dr. S.C. Pandey, "PANDEYS", B-83/B; Nirala Nagar, (Opposite Ram Krishna Math), Lucknow –226020.  
E-mail: [sharadchpandey@yahoo.co.in](mailto:sharadchpandey@yahoo.co.in)

### ABSTRACT

A fortyfive year old male presented with a painless solitary nodular swelling near left lateral border of the tongue of two months duration. Fine needle aspiration cytology lead to no conclusion. Excisional biopsy was done. Histopathology revealed Cysticercosis cellulosae and the parasite could be visualised in the slide along with the tongue muscles.

### KEY WORDS

Lingual, Cysticercosis, Oral, Tongue, Taenia, Cellulosae

### INTRODUCTION

Cysticercosis presenting as a nodule or mass in the tongue is a very rare occurrence. Only thirty four cases have been reported in the world literature. This is therefore a diagnostic and therapeutic dilemma for clinicians. Solitary nodular swelling over tongue is usually not suspected clinically for cysticercosis. The diagnosis is usually made on histopathological examination. The ensuing clinical disorder is named after the name given to the organism at this larval stage, Cysticercosis cellulosae, Larvae of pork tapeworm *Taenia Solium*.

### CASE HISTORY

A forty five year male, non vegetarian, presented with a painless solitary nodular swelling near the left lateral border of his tongue of two months duration. The nodule was gradually increasing in size and had lately caused discomfort while eating and talking. Examination revealed a 1cm x 1cm well defined pink, smooth, moveable, non tender swelling at the junction of anterior one third and posterior two third of the tongue. General and systemic examination was within normal limits. Fine needle aspiration cytology was

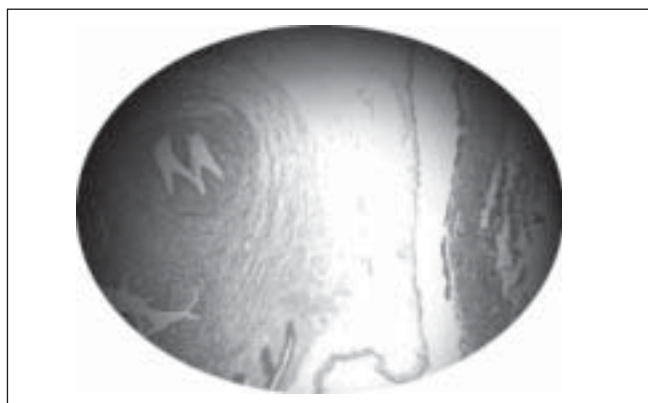
non conclusive. Under local anaesthesia excision was carried out. On excision it was a smooth well-encapsulated cystic mass, with yellowish pale fluid.

The histopathological examination revealed cysticercosis cellulosae in the tongue musculature [Figure 1]. It was characterised by a scolex and epithelium lined tortuous body canal continuous with outer cystic layer [Figure 2]. The cyst was enclosed by a thick fibrous capsule infiltrated with lymphocytes, plasma cells, eosinophils and giant cell granulations. The postoperative period was uneventful. The patient is being followed up regularly and is monitored for any neurological or ophthalmic signs and symptoms. He was given Albendazole 200mg TDS for thirty days.

### DISCUSSION

*Taenia solium* passes its life cycle in two hosts. The definitive host is human who harbours the adult worm and intermediate host is pig which harbours the larval stage. The adult worm lives in the small intestine of man. Usually one adult worm is present which lives for years. It is about three meters long with 1000 proglotids, the gravid segments with about 50,000 eggs in each gravid segment.

The worm sheds gravid segments laden with eggs in the stool which infect pigs. On reaching the alimentary canal of the intermediate host these eggs rupture and oncospheres are liberated. They penetrate the gut wall and reach the systemic circulation and are lodged in the different organs and muscles of the intermediate host. Here, they develop into larvae referred to as cysticercosis cellulosa. Human beings are infected through eating undercooked contaminated pork or infected vegetables, where it develops into the adult tapeworm in the jejunum. The worms shed gravid segments laden with eggs in the stool; which reinfect pigs, thus completing the cycle. Autoinfection of man may occur by contaminated fingers or by reversal of peristaltic movement of intestine whereby the gravid segments are thrown back to the stomach, equivalent to ingestion of thousands of eggs. These are partially digested in the stomach, evolving to oncospheres and subsequently penetrating the small intestine mucosa to disseminate throughout the body via arteriovenous channels and lymphatics, frequently encysting in subcutaneous tissue; striated muscles, brain and ocular tissue.



**Figure 1:** Cysticercosis cellulosa in the tongue musculature



**Figure 2:** Cysticercosis - Scolex and epithelium lined tortuous body canal continuous with outer cystic layer

Clinical manifestations of intestinal infection by *Taenia solium* could be asymptomatic or may present with epigastric pain, nausea and loose motions. In cysticercosis manifestations are different and depends on the location of cysticercosis in the body, not only this but also the number of cysticercosis at a particular site and the associated inflammatory response or scarring decides the clinical presentation. In 87% of cases cysticercosis presents as solitary lesion. Presentation as subcutaneous nodule on trunk, upper arm, eyes, neck, tongue, face and breast has been reported in this order of frequency. Neurocysticercosis is most often presented with seizures and may be associated with subcutaneous nodules comprised of extraneural cysts.

In a large series of 450 cases of cysticercosis Dixon and Lipscomb<sup>1</sup> detected 1.8 % suffering from lingual cysticercosis in 1961. Ortiz<sup>2</sup> 1963, Celissanfeli<sup>3</sup> 1965, Pupkin<sup>4</sup> 1967, Lafont<sup>5</sup> 1971, Sharma<sup>6</sup> 1986, Gupta<sup>7</sup> 1995, Roth<sup>8</sup> 2003, Nigum<sup>9</sup> 2003 have reported a total of 34 cases of lingual cysticercosis. Our case is one more addition to this series of rare manifestation of Cysticercosis.

## CONCLUSION

A case of lingual cysticercosis with review, etiopathogenesis, histopathological images, diagnostic criteria and treatment is discussed. It suggests the need of considering cysticercosis along with other causes of cystic lesions of the tongue.

## REFERENCES

1. Dixon HBF, Lipscomb FM. Cysticercosis, an analysis and follow up of 450 cases. Privy Council, Med. Res. Council, Special Report series No. 299. Her Majesty's Stationary Office, London 1961
2. Ortiz Ledesma E. Cysticercosis of the Tongue ADM 1963; 20:680-2.
3. Celissanfeli A, Sanmiguelbertrand L. Cysticercosis of Tongue (Clinical Case report) An Esp. Odontoestomatol 1965;24:35-40.
4. Pupkin J, Apt W, Rivera H. Cysticercosis of the tongue. Bol Chil Parasitol 1967;22:66-8
5. Lafont Quintero Gonzalez J. Tongue Cysticercosis. Rev Latinoam Patol. 1971;10:151-3.
6. Sharma AK, Misra RS, Mukherjee A, Ramesh V, Jain RK. Oral Cysticercosis. International J Oral Maxillofac Surg 1986;15:349-51. please write names of all the authors
7. Gupta SC, Gupta SC. Cysticercosis of the tongue. Ear Nose Throat J 1995;174:177-78.
8. Roth B, Gocht A, Metternich FU. Cysticercosis as a rare cause of a tumor of tongue. Laryngorhinootologie 2003;82:564-7.
9. Author Misssing. Lingual Cysticercosis. Indian J Patholo Microbiol 2003;46:149.