

# The reclusive patient—a case report & clinical review of Merkel cell carcinoma

**C. Ramanathan, W. G. P. Eardley, S. Nagarajan\***

Department of Plastic & Reconstructive Surgery, \*Pathology, The James Cook University Hospital, Middlesbrough, U.K.

**Address for correspondence:** Mr. C.Ramanathan, Consultant Plastic Surgeon, The James Cook University Hospital, Middlesbrough, United Kingdom TS4 3BW. E-mail: [c.ramanathan@ntlworld.com](mailto:c.ramanathan@ntlworld.com)

---

## ABSTRACT

Advanced Merkel Cell Carcinoma with intra – hepatic metastases in a reclusive gentleman is described. We present an interesting case with learning points and a review of this uncommon malignancy.

## KEY WORDS

Merkel Cell Carcinoma, Intra-Hepatic, Metastasis, Neuro-endocrine

## CASE REPORT

**M**r AM presented to the Plastic Surgery Department via Accident & Emergency in early October 2003. He is a retired 58-year-old radiographer having worked in the petrochemical industry in the tropics. He had a large, foul smelling, fungating lesion occupying the entire dorsum of his right hand [Figure 1 & 2]. This was of six months duration with massive right cervical & axillary lymphadenopathy [Figure 3]. The extent of the axillary lymphadenopathy was such that his right arm was kept in permanent abduction at 35 degrees. Initial impression was that of a fungating Squamous Cell Carcinoma.

The gentleman had discovered a scabbing lesion on the MCPJ region of his right hand 'some years back' although unfortunately had declined any investigation of this. He lived essentially as a recluse and it wasn't until his landlord noticed the odour emanating from his gloved hand that he sought medical attention.

On admission, examination was otherwise unremarkable apart from a suggestion of mild jaundice. Blood tests done at the time revealed a hypochromic, microcytic anaemia and deranged liver function tests of a mixed picture (elevated ALP, ALT, bilirubin & gGT).

### Initial Management

The fungating tumour on the dorsum of the hand required to be removed urgently. This was for diagnosis and treatment as well as because it was foul smelling. The patient underwent excision biopsy of the lesion and split skin grafting with FNA sampling of both the axillary and cervical nodes. Though there was initial partial skin graft loss, the hand subsequently healed well [Figure 4].

### Histo-pathology

Naked eye examination showed an oval piece of skin measuring 95x85mm including underlying soft tissue to a depth of 5mm. The surface bore an ulcerated tumour measuring 83x80mm. The lesion extended to within 5mm of the closest excision margins (distal and lateral).

Microscopic sections [Photomicrograph 1 & 2] showed an ulcerated tumour composed of small to medium sized, round to oval cells of fairly uniform size. These cells had vesicular nuclei with small nucleoli. There was abundant mitotic activity and numerous apoptotic bodies were seen. The tumour cytoplasm was scanty and amphophilic. The

cells were arranged in sheets and solid nests and infiltrate deeply into the subcutis and abutted the deep fascial margin. Lympho-vascular channel invasion was readily identified and the tumour extended to within 1 mm of the closest (lateral) circumferential resection margin.

Merkel cell carcinoma is an uncommon tumour, with a close histological differential of metastasis of small cell carcinoma (from Lung), cutaneous lymphoma, cutaneous small cell melanoma. Immunohistochemistry is important to make this diagnosis. The tumour was strongly positive for Cytokeratin AE1/AE3 [Photomicrograph 3], Epithelial membrane antigen [Photomicrograph 4] and negative for CD45 (leukocyte common antigen) ruling out lymphoma and negative for S-100 ruling out melanoma. There was no clinical and CT evidence for pulmonary small cell carcinoma and the focal positivity for CK20 [Photomicrograph 5] would favour Merkel cell carcinoma. An additional immunohistochemical stain, thyroid transcription factor (TTF-1), has been performed. The tumour cells are negative for this marker adding weight to this lesion being a primary neuro-endocrine carcinoma of skin (Merkel cell carcinoma).

### Cytology

**Fine Needle Aspiration Left Neck** showed Lymphoid cells and abundant undifferentiated malignant cells. The origin of these malignant cells was unclear and there were no specific features to suggest melanoma.

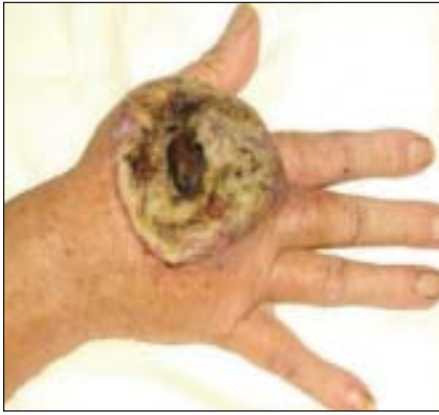### Fine Needle Aspiration Right Chest Wall

Predominately lymphoid cells with an occasional mildly atypical cell were seen the nature and significance of which was unclear.

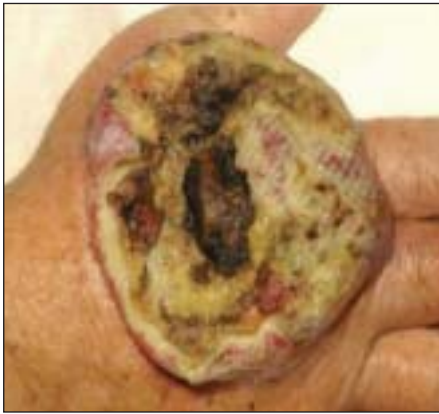### Further Management

Further investigations included a CT scan of neck, chest and abdomen. Subsequent blood tests revealed a further derangement in liver function. The CT was reported to have multiple right and left axillary, left submandibular and intra-abdominal lymphadenopathy, and no organ involvement. There was no evidence of tumour in the lungs (to rule out small cell carcinoma of the lung). Whilst on the ward, with the preliminary report of the normal CT with a background of deranged liver function, it was postulated that this could be secondary to alcohol abuse. With his social history this seemed to fit the picture.

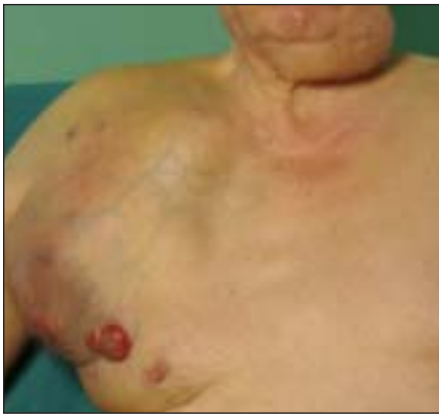A week later a second opinion was requested on the CT films, the final report being of intra-hepatic biliary dilatation



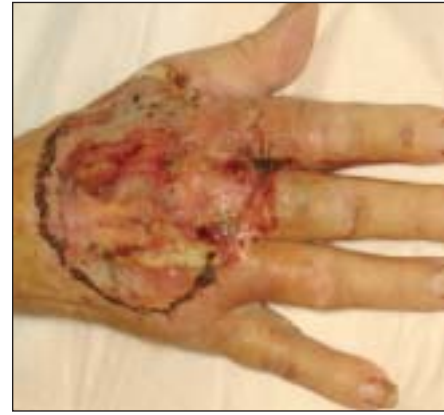**Figure 1:** Fungating lesion on dorsum of hand



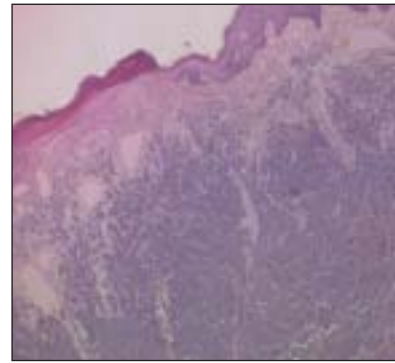
**Figure 2:** Close up of lesion on dorsum of hand



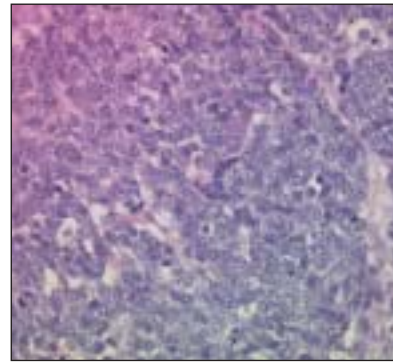
**Figure 3:** Marked right axillary and left cervical lymphadenopathy



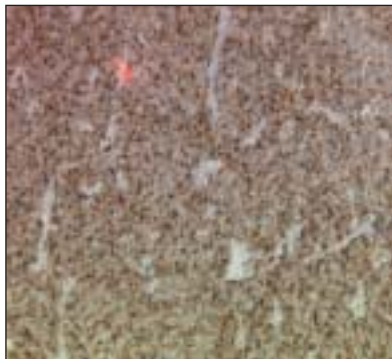
**Figure 4:** Immediate Post-op Dorsum of Hand



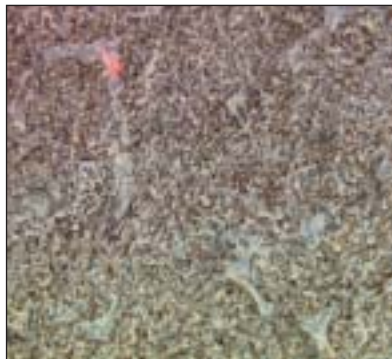
**Photomicrograph 1:** Merkel Cell Tumour X Haematoxylin and Eosin stained section at low power (25x) showing an ulcerated cellular skin tumour



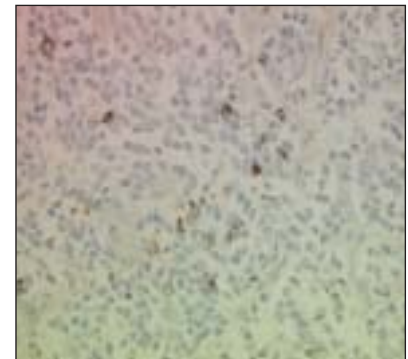
**Photomicrograph 2:** Merkel Cell Tumour X Haematoxylin and Eosin stained section at high power (400x) showing the tumour composed of small malignant cells with numerous mitotic figures



**Photomicrograph 3:** Merkel Cell Tumour EMA stain (200x)



**Photomicrograph 4:** Merkel Cell Tumour CYK stain (200x)



**Photomicrograph 5:** Merkel Cell Tumour CK 20 stain (400x)

with accompanying metastatic disease in the head of the pancreas. He subsequently underwent an ERCP for stenting, which was unfortunately unsuccessful due to the tight nature of the stricture. The obstruction was eventually relieved by percutaneous stenting.

### Palliative Chemotherapy

The patient, with extensive metastatic disease, was not suitable to undergo regional lymphadenectomy and morbidity and mortality would have been very high and affected the quality of his remaining life significantly. This was agreed by our Medical Oncology and Radiotherapy colleagues. Following the relief of biliary obstruction, the LFTs fell back into normal range. The Medical Oncologist, then discussed with the patient the options of palliative systemic chemotherapy and local radiotherapy for lymphadenopathy. As the general condition showed improvement, the patient was willing to go through Chemotherapy which consisted of Cyclophosphamide, Adriamycin and Vincristine. The first course of chemotherapy did not make any difference to his massive lymphadenopathy. Though it was felt by the Oncologist that the patient should receive at least three courses before deciding about the degree of response, further courses of chemotherapy were not started because the patient could not tolerate the side effects.

### Palliative Radiotherapy

With no response to Chemotherapy and increasing bulky lymphadenopathy with ulceration of the axillary mass, the option of palliative radiotherapy was considered with the patient and the patient received the same. There had not been any worthwhile response to radiotherapy. His general condition was very poor and hence no further active treatment was contemplated and symptomatic palliative care was offered in the community. The patient died six months after his initial presentation to the hospital.

## DISCUSSION

Merkel cells are Type 1 mechanoreceptors located in sites of high tactile sensitivity. Friedrich S Merkel first documented them in 1875 as 'Tastzellen' (touch cells), clear staining cells situated at the dermal-epidermal junction which were intimately associated with myelinated nerve fibres. Merkel cells appear in around the eighth week of gestation and are present in large numbers on the lip, hard palate, and finger pads. They are found both in hairy skin and in the glabrous skin of the digits, lips, oral cavity and

the outer root sheath of hair follicles.

Functionally, Merkel cells make synaptic contacts with nerve endings to form the Merkel cell-neurite complex. The cells contain dense neurotransmitter-like substances. It is also thought that Merkel cells may function as targets for the siting of nerve endings during foetal and embryonic development.

Following Toker's work of 1972, it became clear that Merkel cell carcinoma belongs to the broad spectrum of tumours of the neuroendocrine system – hence they were termed cutaneous neuroendocrine carcinoma.<sup>1</sup>

Clinically, Merkel Cell Carcinomas (MCC) arise predominantly in the head and neck region (>50%). They are seen at all ages but are rare under 60 years, with an equal sex distribution. These lesions appear as pink-brown subcutaneous nodules, usually with intact covering skin. Postulated causes of MCC include UV A exposure and immunosuppression.<sup>2</sup>

Differential diagnoses of MCC include malignant melanoma, malignant lymphoma, neuroblastoma and skin metastasis of small cell carcinoma.

MCCs are high-grade malignant tumours with local recurrences and metastases as common features. Overall survival rate at two years is 72%, with 40% of patients developing local recurrence following excision. Regional nodal metastases are found in 60% of patients with 30% of patients developing distant metastases. Distant metastatic sites include lungs, liver, bones & brain.<sup>3</sup>

Management options for these cancers include primary surgical resection, regional radiotherapy & nodal dissection. Chemotherapeutic regimes similar to those used for small cell carcinoma of the lung are also used.<sup>3</sup>

## REFERENCES

1. Haake AR, Holbrook K. The Structure & Development of Skin. *In: Freedberg IM, Eisen AZ, Wolff K, Austen KF, Goldsmith LA, Katz SI, et al, editors. Fitzpatrick's Dermatology in General Medicine. 5<sup>th</sup> edn. McGraw – Hill; 1993. p. 82-4.*
2. O'Rourke MGE. Merkel cell or neuroendocrine tumour of the skin. *In: Emmett AJJ, O'Rourke MGE, editors. Malignant Skin Tumours. 2<sup>nd</sup> edn. Churchill Livingstone; 1991. p. 157-61.*
3. Kerl H, Hoffmann-Wellenhof R. Cutaneous neuroendocrine Carcinoma: merkel Cell Carcinoma. *In: Freedberg IM, Eisen AZ, Wolff K, Austen KF, Goldsmith LA, Katz SI, et al, editors. Fitzpatrick's Dermatology in General Medicine. 5<sup>th</sup> edn. McGraw – Hill; 1993. p. 914-8.*