

Original Article

Four cases of variations in the forearm extensor musculature in a study of hundred limbs and review of literature

Mohandas K. G. Rao, Venkata Ramana Vollala, Seetharama M. Bhat, Sreenivas Bolla, Vijay Paul Samuel, Narendra Pamidi

Department of Anatomy, Melaka Manipal Medical College (Manipal Campus), Manipal, India

Address for correspondence: Dr. Mohandas Rao KG, Department of Anatomy, Melaka Manipal Medical College (Manipal Campus), International Centre for Health Sciences, Manipal - 576104, Karnataka, India. E-mail: mohandas.rao@manipal.edu

ABSTRACT

All surgeons must bear in mind the existence of muscular variations when performing common tendon transfers. Presence of additional bellies and tendons of existing muscles or presence of additional muscles in unusual locations might misguide a surgeon, during surgery and also during diagnosis. In the present paper we are reporting four cases of variations encountered during the study of extensor muscles of the forearm in 100 limbs. In Case 1, additional bellies of extensor carpi radialis longus and extensor carpi radialis brevis and multiple tendons of insertion of abductor pollicis longus were observed in a single limb. In Case 2, an additional belly of the abductor pollicis longus was observed. In Case 3, a short muscle on the dorsum of the hand going to the index finger [extensor indicis brevis (EIB)] was found in addition to the normal extensor indicis (EI). It was also observed that some of the most superficial fleshy fibers of EIB were getting inserted into the tendon of EI. In Case 4, a rare incidence of extensor digiti medii proprius was observed. Further, the related literature is reviewed and the clinical and surgical importance of these muscular variations in diagnosis and proper planning of treatment is discussed.

KEY WORDS

Abductor pollicis longus, extensor carpi radialis brevis, extensor carpi radialis longus, extensor digiti medii proprius, extensor indicis brevis

INTRODUCTION

Proper knowledge of muscular variations is essential not only for anatomists but also for surgeons. Additional bellies and the tendons of the muscles are surgically noteworthy. Such variant structures can lead to error in both diagnosis and treatment. Forearm extensors are known to exhibit such variations. Some of the reported variations are brachioradialis tendon dividing into two to three slips,

accessory brachioradialis (brachioradialis brevis), abductor manus, trigastric extensor carpi radialis longus, extensor carpi radialis intermedius, extensor carpi radialis accessorius, splitting radial carpal extensors into two to three slips, additional slip of extensor digitorum to the thumb, double belly of extensor digiti minimi, an ulnar slip of extensor digiti minimi going to the fifth metacarpal bone, double extensor carpi ulnaris, ulnaris digiti minimi, extensive cleavage of tendon and belly of abductor pollicis longus, doubling of extensor pollicis

longus, an additional extensor between extensor indicis and extensor pollicis longus, abductor pollicis tertius, two heads or complete doubling of extensor indicis, double tendons of extensor indicis, extensor brevis manus and extensor digiti medii proprius.^[1] In the present study, we studied 100 upper limbs and looked for variations in the muscles of the extensor compartment of the forearm and hand. The unusual cases of additional bellies and tendons were observed in relation with radial carpal extensors and abductor pollicis longus muscles. We also observed two cases of additional muscles, an extensor indicis brevis (EIB) and an extensor digiti medii proprius (EDMP).

MATERIALS AND METHODS

Hundred upper limbs from 50 cadavers were used in the present study. The study was carried out at the Department of Anatomy, Melaka Manipal Medical College, Manipal. The extensor compartment of the forearm and dorsum of the hand were carefully dissected and investigated for the muscular variations.

Observations

Out of 100 limbs dissected by us major variations were observed in only four cases.

Case 1

This limb belonged to the left side of an approximately 50-year-old male cadaver. In this limb additional bellies of the extensor carpi radialis longus (ECRL) and extensor carpi radialis brevis (ECRB) muscles were observed. In the same limb multiple tendons of the abductor pollicis longus (APL) were also observed.

The additional belly of the ECRL was found on the radial side of the main belly of ECRL and was having common origin with it. This additional belly had a long slender tendon which was formed about an inch proximal to the tendon of the main muscle and continued distally on the lateral side of the tendon of the main muscle (ECRL) and was getting merged with it deep to the belly of APL [Figure 1]. The additional belly of ECRB was found deep to the ECRL on the lateral side of the main belly of ECRB. Though the additional belly had a common origin with the main muscle, when traced distally it was clearly distinct from the belly of ECRB. The thin elongated tendon of this additional belly passed distally superficial to the supinator, after crossing the shaft of the radius

from the lateral to medial side, it passed deep to the main tendon of the ECRB and entered the fourth compartment of the extensor retinaculum. The tendon ended by getting inserted into the base of the third metacarpal bone and adjoining carpal bones [Figure 2]. In the same limb, the APL muscle showed three tendons of insertion. The two additional tendons were seen on the lateral and medial sides of the main tendon. The one on the lateral side was relatively thin and was arising from a partially separated additional belly of the muscle. It passed ventrally towards the palmar aspect of the hand outside the first compartment of the extensor retinaculum where it ended by merging with the flexor retinaculum close to the origin of thenar muscles. The thicker medial tendon had a course and insertion that is similar to the main tendon of the APL [Figure 1]. It was interesting to note that only the main and medial tendons passed through the first compartment of the extensor retinaculum.

Case 2

A case of additional belly of the abductor pollicis longus (APL) muscle was observed in the left upper limb of about a 45-year-old male cadaver.

The additional belly was arising from the lateral aspect of the distal portion of the normal APL muscle just proximal to the formation of its tendon [Figure 3]. The tendon of this additional muscle belly extended from the belly of the APL, coursed superficial to the ECRL and ECRB tendons and attached to the abductor pollicis brevis, opponens pollicis and flexor pollicis brevis muscles.

Case 3

In another limb belonging to the left side of an approximately 60-year-old male cadaver we noticed an unusual case of the presence of short (intrinsic) muscle, EIB, in the dorsum of the hand going to the index finger in addition to the normal extensor indicis muscle (EI) [Figure 4].

The fleshy fibers were taking their origin within the fourth compartment of the extensor retinaculum from the dorsal surface of the ligaments covering the capitate and adjoining carpal bones. The muscle belly was measuring about 7.5 cm in length and about 1.5 cm in width. Its tendon was getting inserted to the dorsal surface of the base of the proximal phalanx of the index

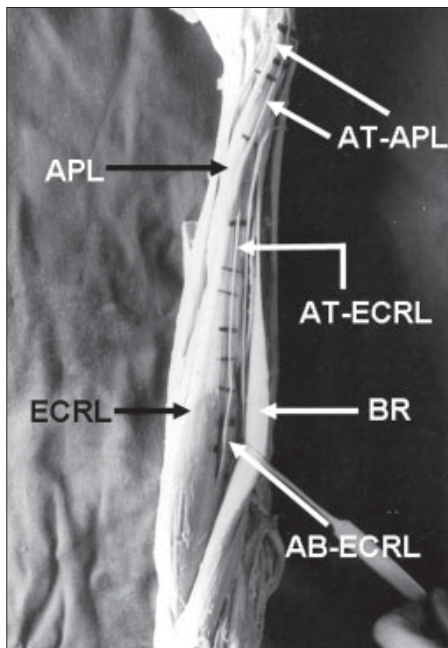


Figure 1: Additional belly of extensor carpi radialis longus (AB-ECRL) can be seen along with the main muscle belly of extensor carpi radialis longus (ECRL). Also seen are the abductor pollicis longus (APL) and its additional tendons (AT-APL). AB-ECRL- Tendon of the additional belly, BR- Brachioradialis

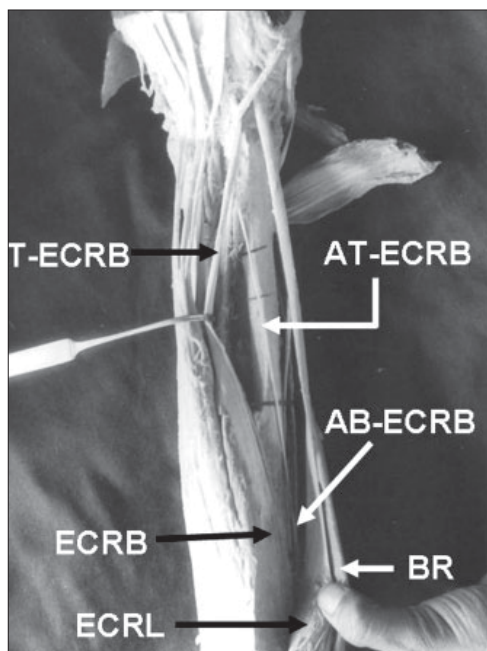


Figure 2: Additional belly of extensor carpi radialis brevis (AB-ECRB) can be seen along with the main muscle belly of extensor carpi radialis brevis (ECRB). Also seen are extensor carpi radialis longus (ECRL), Tendon of the additional belly of extensor carpi radialis brevis (AT- ECRB) and brachioradialis (BR).

finger [Figure 4]. The muscle was innervated by the posterior interosseous nerve near its proximal end. A more interesting and unique observation made by us is that a significant number of fleshy fibers originating from the floor of the fourth compartment of the extensor retinaculum, along with the EIB, passed over its

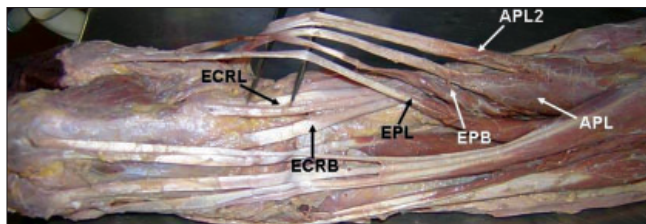


Figure 3: Showing the normal belly and its tendon of the abductor pollicis longus (APL) along with the additional belly and its tendon (APL2). Also seen are extensor pollicis brevis (EPB), extensor pollicis longus (EPL), extensor carpi radialis longus (ECRL) and extensor carpi radialis brevis (ECRB).

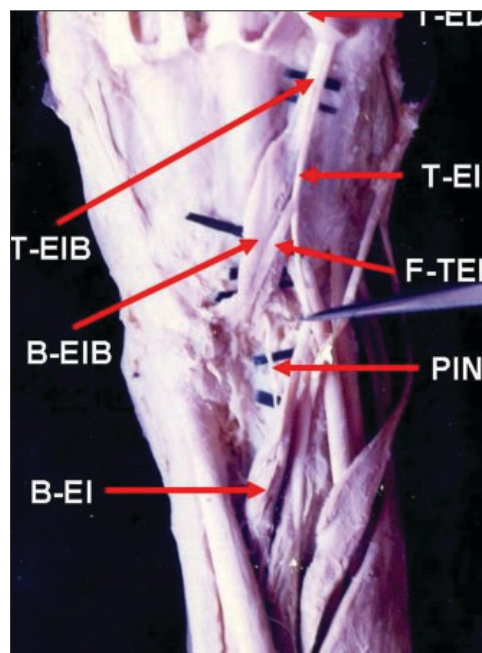


Figure 4: Showing extensor indicis brevis (B-EIB: belly; T- EIB: tendon) in the dorsum of the hand in addition to a normal extensor indicis (longus) muscle (B-EI: belly; T- EI: tendon) and the fleshy fibers of the extensor indicis brevis (F-TEI) joining the tendon of extensor indicis (T- EI). PIN: posterior interosseous nerve; T-ED: indicial finger tendon of the extensor digitorum cut and reflected

superficial surface to join the tendon of EI on its medial aspect in the proximal part of the dorsum of the hand [Figure 4]. Other features of EI and the indicial tendon of the extensor digitorum were normal.

Case 4

This case of additional muscle whose tendon was going to the dorsum of the middle finger was observed in the left forearm of a 50-year-old male cadaver.

The fleshy fibers of this muscle were arising from the posterior surface of the lower part of the ulna and adjoining interosseous membrane. A thin slender tendon was beginning from the small belly of the muscle in the distal part of the forearm. It then passed distally through the fourth compartment of the extensor retinaculum to

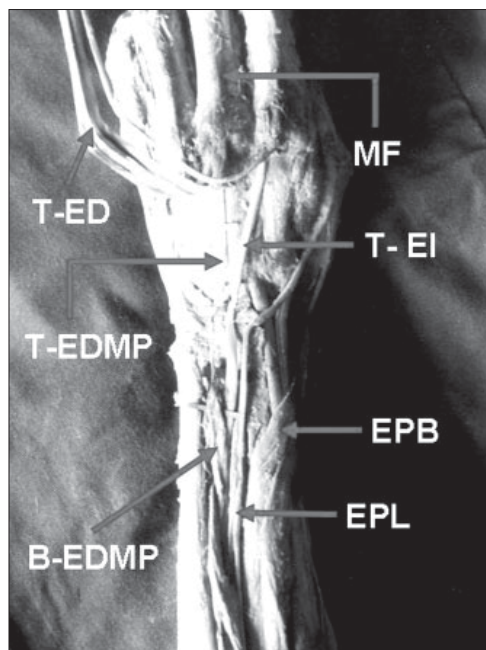


Figure 5: Showing extensor digitorum medius proprius (B-EDMP: belly; T-EDMP: tendon). EPL: extensor pollicis longus, EPB: extensor pollicis brevis, T-ED: tendon of the extensor digitorum cut and reflected, MF: middle finger

enter the dorsum of the hand where it was found medial to the tendon of extensor indicis. The tendon ended by getting inserted to the dorsal surface of the base of the proximal phalanx of the middle finger deep to the tendon of the extensor digitorum of the middle finger [Figure 5]. The muscle was innervated by the posterior interosseous nerve. Based on the attachments, the muscle was identified as extensor digiti medii proprius (EDMP).

In none of the above 4 cases did the contralateral upper limbs show any muscular variations.

DISCUSSION

Case 1

Many variations in the bellies and tendons of radial carpal extensors have been reported before. An anatomical study of the ECRL and ECRB in 173 upper limbs by Albright and Linburg^[2] demonstrated abnormalities in 50% of cases. Interconnecting tendons between the longus and brevis were found in 35% of limbs. In about 26% of cases, a tendon was arising proximally from the ECRL and was getting inserted distally with the ECRB. In about 24% of cases an extra muscle (the extensor carpi radialis intermedius) was present. It can be noted that none of these cases were similar to our observations in the present case. Claassen and Wree^[3] have reported a case

where ECRL gave origin to an accessory head, the tendon of which passed through a separate tunnel in the extensor retinaculum and inserted in the middle of the first metacarpal bone. In the same limb they also observed an accessory tendon of ECRB lying underneath the main tendon of the muscle. This accessory tendon joined with the main tendon just when undercrossing APL. In contrast, in the present case, such a phenomenon was observed with the additional tendon of the ECRL. Melling *et al.*^[4] have reported an accessory muscle in the forearm and hand region, which branched off from the ECRB muscle. Its tendon crossed over the extensor retinaculum and attached to the dorsal digital expansion of the index finger. A bilaterally well developed, bicipital and bipinnate accessory extensor carpi radialis muscle has been reported. The muscle was arising between the origins of the ECRL and ECRB and inserted by two tendons into the first and second metacarpal bones.^[5]

Variations in the APL are also not uncommon. Akan *et al.*^[6] have observed a case where the APL tendon was divided into five sections shortly after exiting the first compartment of the extensor retinaculum. A study conducted by Roh *et al.*^[7] in 68 specimens has revealed that 35 (51%) of APL tendons had a thenar insertion. Out of 66 specimens studied by Gonzalez *et al.*^[8] multiple slips of the APL tendon were noted in 38 cases. These accessory slips inserted into the trapezium and thenar musculature. It can be noted that in the present case, only one of the two additional tendons had thenar insertion. In another variation reported by Aydinlioglu *et al.*^[9] both APL and ECRB tendons together inserted into the inferior side of the base of the first metacarpal bone, instead of the dorsal side.

Variant radial carpal extensors are of importance for the clinicians and surgeons. Malaviya Govind^[10] has reported a case where the elongation of ECRL tendon was performed using the radial half of the parent tendon in 12 patients. He has suggested that splitting of the ECRL tendon to use one half as a tendon graft can be considered in patients in whom ECRL transfer is planned to correct finger clawing. In such cases, if the surgeon is aware of the probable variations of radial carpal extensors like additional bellies and tendons as reported in this case, such tendons can be used for grafting instead of splitting the parent tendon. Albright and Linburg^[2] have also supported this by reporting that among the many variant tendons observed by them during the study of 173 upper limbs, many were large enough to activate

a tendon transfer and the extra muscles found in this region can be useful in the surgical rehabilitation of patients with paralytic disorders.

Case 2

As mentioned earlier most of the reported variations of APL are about the variations in its tendons and their insertion.^[6-9] A case of additional belly of APL with a separate tendon is not reported in literature so far. Reports in the literature suggest that variations in the numbers of APL tendons, the tendons' distal attachment sites and the structure of the APL can have clinical relevance. It has been suggested that variations in the number of APL tendons and corresponding osseofibrous canals are involved in the etiology and subsequent surgical decompression of DeQuervains Syndrome.^[11-13] An incomplete understanding of the possible variations in the dorsolateral forearm can lead to inadequate surgical decompression of DeQuervains Syndrome.^[12] Patel and Desai^[14] describe a case report of a patient with an extension of the APL muscle belly into the first dorsal compartment under the extensor retinaculum producing wrist and thumb pain with activity. Additionally, Martinez and Omer^[15] describe a case where the tendons of the APL inserted into the fascia of the abductor pollicis brevis resulting in laxity and repeated subluxation of the trapezometacarpal joint bilaterally. It has also been shown that the confining nature of the intersection area where the APL and extensor pollicis brevis cross over the tendons of the ECRL and ECRB in the dorsolateral forearm can contribute to intersection Syndrome or peritendinitis crepitans.^[16-18] One can only speculate regarding the mechanical significance of the current finding. Further significance may lie in the ability of an APL tendon to contribute as a stabilizer of the CMC joint.^[19,20] In surgery, the APL tendon can be used for interposition arthroplasty in cases of osteoarthritis of the first carpometacarpal joint,^[21] as a tendon transfer to restore extension of the thumb^[22] or to restore the first dorsal interosseous muscle^[23] and for tendon translocation for chronic subluxation of the carpometacarpal joint of the thumb.^[24] Additional clinical significance lies in the understanding of the prevalence of the current finding to aid in a more complete and accurate description of the dorsolateral compartment of the distal forearm for surgical approaches. The APL is an important muscle for the function of the human thumb and hand and knowledge of its function is important in clinical assessment and reconstructive surgery.

Case 3

Reports of a short additional muscle of the index finger (EIB) are limited. One such case has been reported by Gahhos and Ariyan,^[25] where EIB was originating from the ligament over the scaphoid bone. Another case of such a muscle was discovered accidentally during surgical operation for suspected synovial cyst of the left hand by Della Vella and De Giovannini.^[26] Voigt and Breyer^[27] have reported a case of occurrence of EIB muscle in a 27-year-old man who had a swelling over the back of his right hand that was painful on exertion. According to them frequency of this variant at autopsies is markedly below one per cent. el-Badawi *et al*^[28] have reported a case of EIB replacing the proper muscle. An anomalous indicis proprius muscle that was manifested as a painful dorsal hand mass is also reported.^[29] Kraus *et al*^[30] have reported a case where an EIB muscle was causing a lesion of the radialis dorsalis manus of ulnar nerve. Occurrence of EIB reported in the present case is similar to the previously reported cases in some aspects. But, a significant number of the fleshy fibers of EIB joining the tendon of EI in the dorsum of the hand reported in the present case has not been reported before.

Presence of the additional muscles in unusual locations is always misleading for the clinicians and surgeons. Hence, the proper knowledge of such anatomical variations is important in diagnosing dorsal hand masses and in planning tendon transfers. The complaint of dorsal hand pain is common among such patients seen in a primary care practice. The differential diagnosis of such dorsal masses includes tenosynovial disease, ganglion, trauma and soft-tissue tumors, synovialitis of the extensors or ganglion cysts.^[27,29] Presence of abnormal, additional muscles in the fourth compartment of the extensor retinaculum as in the present case may also lead to a condition called "fourth-compartment syndrome" manifested by chronic dorsal wrist pain of the fourth compartment. The pain is due to the increased pressure within the fourth compartment ultimately compressing the posterior interosseous nerve directly or indirectly.^[31]

During surgical reconstruction of the APL tendon, the interposition of a tendon graft is considered as the best method. Functional considerations make the EI muscle the best substitution for the APL.^[32] Similarly, for restoring the opposition of the thumb in lesions of the median nerve, opponensplasty is done using the tendon of the EI with good success.^[33] In such surgeries, it is

very essential for the surgeons to be aware of the variations of this muscle and the possibility of the presence of an additional muscle close to its tendon in the hand.

From the review of the literature it is quite evident that occurrence of short muscles of the index finger in the dorsum of the hand is not uncommon. Its significance in practicing hand surgery must be known to the surgeons. It cannot be foreseen. When found at random during operation, it may be often neglected. But, it is sometimes the cause of different syndromes such as disability of some artist's hands, painful wrists in sportsmen, nerve compression simulating a carpal tunnel syndrome, camptodactylia, etc. It may also necessitate a modification of planning tendon transfers or grafting.

Case 4

Extensor digiti medii proprius observed in the present study is similar to the previously reported cases. It is a rare variation found in only about 10% of cadavers.^[1] This has been further supported by Schroeder and Botte^[34] who have studied 58 adult hands to determine the incidence of EDMP. In a study on extensor digitorum profundus conducted using 832 Japanese upper limbs the cases of EDMP were observed in 67 (8.1%) limbs.^[35] Cigali *et al*^[36] have reported a case of EDMP in both the upper limbs of a male cadaver.

CONCLUSION

We would like to state that the additional muscle bellies and presence of additional tendons of the muscles is common among the extensors of the forearm. However, there are minor differences between the reported variations. The observations made by us in the present study will supplement our knowledge of variations in this region, which should be quite useful in forearm and hand surgery.

REFERENCES

- Bergman RA, Thompson SA, Afifi AK, Saadeh FA. Compendium of Human Anatomic Variation. Urban and Schwarzenberg. Munich: Baltimore; 1988. p. 14-7.
- Albright JA, Linburg RM. Common variations of the radial wrist extensors. *J Hand Surg Am* 1978;3:134-8.
- Claassen H, Wree A. Multiple variations in the region of Mm. extensores carpi radialis longus and brevis. *Ann Anat* 2002;184:489-91.
- Melling M, Steindl M, Wilde J, Karimian-Teherani D. An anatomical variant of the extensor carpi radialis brevis muscle. *Wien Klin Wochenschr* 2001;113:960-3.
- Khaledpour C, Schindelmeiser J. Atypical course of the rare accessory extensor carpi radialis muscle. *J Anat* 1994;184:161-3.
- Akan M, Gideroglu K, Cakir B. Multiple tendons of the abductor pollicis longus muscle. *Hand Surg* 2002;7:289-91.
- Roh MS, Strauch RJ, Xu L, Rosenwasser MP, Pawluk RJ, Mow VC. Thenar insertion of abductor pollicis longus accessory tendons and thumb carpometacarpal osteoarthritis. *J Hand Surg Am* 2000;25:458-63.
- Gonzalez MH, Sohlberg R, Brown A, Weinzweig N. The first dorsal extensor compartment: An anatomic study. *J Hand Surg Am* 1995;20:657-60.
- Aydinlioglu A, Tosun N, Keles P, Akpinar F, Diyarbakirli S. Variations of abductor pollicis longus and extensor pollicis brevis muscles: Surgical significance. *Kaibogaku Zasshi* 1998;73:19-23.
- Malaviya GN. Radial half of extensor carpi radialis longus tendon as graft to elongate muscle tendon unit for correction of finger clawing. *Plast Reconstruct Surg* 2003;111:1914-7.
- Stein AH Jr. Variations of the tendons of insertion of the abductor pollicis longus and the extensor pollicis brevis. *Anat Rec* 1951;110:49-55.
- Giles KW. Anatomical variations affecting the surgery of de Quervain's disease. *J Bone Joint Surg* 1960;42:352-5.
- Jackson WT, Viegas SF, Coon TM, Stimpson KD, Frogameni AD, Simpson JM. Anatomical variations in the first extensor compartment of the wrist. A clinical and anatomical study. *J Bone Joint Surg* 1986;68:923-6.
- Patel MR, Desai SS. Anomalous muscles of the first dorsal compartment of the wrist. *J Hand Surg Am* 1988;13:829-31.
- Martinez R, Omer GE Jr. Bilateral subluxation of the base of the thumb secondary to an unusual abductor pollicis longus insertion: A case report. *J Hand Surg Am* 1985;10:396-8.
- Allison DM. Pathologic anatomy of the forearm: Intersection syndrome. *J Hand Surg Am* 1986;11:913-4.
- Grundberg AB, Reagan DS. Pathologic anatomy of the forearm: Intersection syndrome. *J Hand Surg Am* 1985;10:299-302.
- Wood MB, Linscheid RL. Abductor pollicis longus bursitis. *Clin Orthop Relat Res* 1973;93:293-6.
- Imaeda T, An KN, Cooney WP 3rd. Functional anatomy and biomechanics of the thumb. *Hand Clin* 1992;8:9-15.
- Kauer JM. Functional anatomy of the carpometacarpal joint of the thumb. *Clin Orthop* 1987;220:7-13.
- Saehle T, Sande S, Finsen V. Abductor pollicis longus tendon interposition for arthrosis in the first carpometacarpal joint: 55 thumbs reviewed after 3 (1-5) years. *Acta Orthop Scand* 2002;73:674-7.
- Chitnis SL, Evans DM. Tendon transfer to restore extension of the thumb using abductor pollicis longus. *J Hand Surg Br* 1993;18:234-8.
- Neviaser RJ, Wilson JN, Gardner MM. Abductor pollicis longus transfer for replacement of the first dorsal interosseous. *J Hand Surg Am* 1980;5:53-7.
- Cho KO. Translocation of the abductor pollicis longus tendon. A treatment for chronic subluxation of the thumb carpometacarpal joint. *J Bone Joint Surg Am* 1970;52:1166-70.
- Gahhos FN, Ariyan S. Extensor indicis brevis: A rare anatomical variation. *Ann Plast Surg* 1983;10:326-8.
- Della Vella P, De Giovannini E. A case of extensor indicis brevis manus muscle. *Chir Ital* 1985;37:214-8.
- Voigt C, Breyer HG. The extensor indicis brevis muscle-A rare anatomic variant. A case example and critical review of the literature. *Handchir Mikrochir Plast Chir* 1989;21:276-8.

28. el-Badawi MG, Butt MM, al-Zuhair AG, Fadel RA. Extensor tendons of the fingers: Arrangement and variations-II. Clin Anat 1995;8:391-8.
29. Reeder CA, Pandeya NK. Extensor indicis proprius syndrome secondary to an anomalous extensor indicis proprius muscle belly. J Am Osteopath Assoc 1991;91:251-3.
30. Kraus E, Schon R, Boller O, Nabavi A. Muscle anomalies of the upper extremity as an atavistic cause of peripheral nerve disorder. Zentralbl Neurochir 1993;54:84-9.
31. Hayashi H, Kojima T, Fukumoto K. The fourth-compartment syndrome: Its anatomical basis and clinical cases. Handchir Mikrochir Plast Chir 1999;31:61-5.
32. Bindl G. Extensor indicis muscle as a replacement for the abductor pollicis longus muscle. A case report Handchir Mikrochir Plast Chir 1990;22:312-5.
33. Vossman H, Zellner PR. Opponens plastic surgery using the tendon of the m. extensor indicis. Handchirurgie 1981;13:52-5.
34. Von Schroeder HP, Botte MJ. The extensor medii proprius and anomalous extensor tendons to the long finger. J Hand Surg Am 1991;16:1141-5.
35. Yoshida Y. Anatomical study on the extensor digitorum profundus muscle in the Japanese. Okajimas Folia Anat Jpn 1990;66:339-53.
36. Cigali BS, Kutoglu T, Cikmaz S. Musculus extensor digiti medii proprius and musculus extensor digitorum brevis manus: A case report of a rare variation. Anat Histol Embryol 2002;31:126-7.

Notices

The Association of Plastic Surgeons of India and ETHICON

welcomes APSI members and bonafide M.Ch/DNB students for its first

Microsurgery Accreditation Course

Duration: 5 days

Location: Ethicon Institute for Surgical Education, Mahim, Mumbai,

Dates: 8th Jan 2007 to 12th Jan 2007.

The Course is endorsed by ISRM

Costs: Course fee is Rs.7500/-, to be paid in advance but totally refundable (minus 5% handling charges) to those who attend the course. No cancellation requests will be entertained.

The delegates will be fully sponsored by Ethicon Division of Johnson and Johnson.

Admission will be on 'first come first served' basis only.

Only 12 candidates can be accommodated in this course.

Course content: The course includes a 5 day intensive workshop with one day 'dry lab' and 4 days live animal lab, videos and lectures of flap harvest and clinical applications.

The faculty: Will be eminent surgeons from all over India

Like APSI President Dr. Mukunda Reddy, Dr. S. R. Tambwekar, Dr. Rajeev Ahuja, Dr. Mukund Thatte etc.,

Course convener: Dr. Bimal Mody

All applications and Bank Drafts should be sent to Dr. Bimal Mody

(B -3 Silver apartments, shankar ghanekar marg, behind siddhi vinayak temple, Prabhadevi, Mumbai - 400028.)

(DD in of favor of Johnson and Johnson Limited, payable at Mumbai)

with full contact particulars (including E-mail and mobile number)

E-mail: bmody@vsnl.com , Fax: 022 24222215. Tel: 24311065

Contact Person at Ethicon, Mr. Kutty,

(Direct: 022 24467438, Telefax: 022 24444883, mobile: 9323964646,

E-mail: meise@jnjin.jnj.com <<mailto:meise@jnjin.jnj.com>>