

Original Article

Role of tunica vaginalis interposition layer in hypospadias surgery

Yog Raj Handoo

Deendayal Upadhyay Hospital, Hari Nagar, New Delhi, India

Address for correspondence: Yog Raj Handoo, 87/Samaj Kalyan Apartments, Vikaspuri, Delhi - 110 018, India.
E-mail: yograjhandoo@yahoo.co.in

ABSTRACT

Hypospadias surgery has evolved with more than 150 procedures for surgical correction of single anomaly. urethro-cutaneous fistula continues to be single most common complication of regardless of location of meatus, procedure performed and experience of surgeon. Every effort goes in prevention of this complication including overlapping suture line. Two stage repair, burying repaired urethra in scrotum, dartose flap. Parietal layer of tunica vaginalis from testis as a water proofing layer over reconstructed neo urethra decreasing fistula rate. Unlike dissection of dartose layer which can damage blood supply of overlying skin with impaired wound healing, tunica vaginalis brings vascular supply from outside source hence helping in healing of suture line of neo-urethra. Study of effectiveness of tunica vaginalis flap covering different hypospadias procedures in 126 cases over 6 years is presented with inference of significant decrease of urethra-cutaneous fistula rate.

KEY WORDS

Hypospadias, fistula, tunica vaginalis flap

INTRODUCTION

Hypospadias repair continues to be a singularly demanding form of surgical expression with considerable artistic latitude.^[1] Hypospadias surgery has evolved with more than 150 procedures described for surgical correction of a single anomaly.^[1] Urethro-cutaneous fistula in hypospadias surgery occur regardless of the location of the meatus, procedure performed or experience of the surgeon.^[2] The commonest complication of hypospadias surgery is fistula formation which almost always requires repeat and equally demanding surgery.^[3] Hence, every effort is made to prevent this complication. Many efforts for prevention of fistulae are undertaken like overlapping suture lines, two-stage repair, burying repaired urethra

in scrotum,^[4] dartos flap,^[5] overlapping denuded subcutaneous tissue,^[6] rotating skin flaps etc. Tunica vaginalis flap from the parietal layer of testis cover of anastomosis of urethroplasty is one more option which helps in the reduction of urethro-cutaneous fistulae.

MATERIALS AND METHODS

One hundred and twenty-six patients of hypospadias underwent repair from the year 1999 to 2004. The operative method chosen for hypospadias was determined by the type of hypospadias, urethral plate, shape of glans and chordee. After hypospadias repair if

Presented at the National conference of Plastic surgeons of India at Jaipur, India, September 2004.

the suture line of the urethra was visible even after overlapping with adjacent tissue, then tunica vaginalis flap cover was used [Figure 1]. Also included were patients with a large fistula or multiple fistulae where interposition layer was considered desirable on the operation table after the repair of fistula. Results were compared to the results of patients operated earlier by the same surgeon where cases were comparable but without interposition of tunica vaginalis layer as an additional water-proofing layer. All operations were done by the same surgeon. If after urethral reconstruction, space between the reconstructed urethra and glanular tissue was considered inadequate to accommodate additional tunica flap, it was tucked just above the corona by few sutures. The testis was delivered into the operative field from the same incision as used for urethral reconstruction [Figure 2]. After delivering the testis into the operative field, parietal layer of tunica vaginalis of the testes was harvested as a square flap held by two stay sutures. The length and breadth of the flap in most instances was adequate to cover from the tip of the shaft to perineal urethra and almost half of the circumference of the penile shaft [Figure 3]. Tunica vaginalis flap was sutured into place by 6-0 interrupted vicryl suture (polyglactin 910 Ethicon India Ltd). The tunica vaginalis flap was covered by dartos and skin. Silicone Catheter was inserted and removed after two weeks. Fistula rate prior to usage of tunica vaginalis flap was compared for similar type of hypospadias surgery but without flap. Patients were followed up on an average for one year [Figures 4-5].

RESULTS

One hundred and twenty-six hypospadias procedures were performed; 63% (56/126 patients) had distal hypospadias and 37% (46/126 patients) were of the proximal variety [Table 1]. Thirty-two patients who underwent Mathieu's repair were excluded from the study as no tunica vaginalis flap was used in any case [Table 2]. Twenty-eight patients underwent TIP procedure (Snodgrass procedure) twenty without tunica vaginalis cover, in which three developed fistula, while out of eight with tunica vaginalis cover one patient had fistula. All eight patients were of mid penile hypospadias in which preputial skin graft was applied after incising urethral plate.

Thirty-two cases (25.7%) underwent two-stage surgery,

in first stage chordee correction and transfer of preputial skin (Byar's flap) was done and six months later, skin tubularisation urethroplasty was done. Three of 12 patients without tunica vaginalis cover developed fistula while one of 20 patients with tunica vaginalis cover had fistula. In two-stage hypospadias repair there was significant reduction of fistula rate from 25 to 5% with usage of tunica vaginalis cover [Table 3]. Two patients had a skin tube constructed from full thickness non-hair bearing groin skin (Horton-Devine repair), both developed fistula. Twelve patients had miscellaneous procedures like one-stage urethroplasty with parametarial foreskin flap Type I and Type II, with three developing fistula. Two patients (5%) in whom tunica vaginalis flap was harvested had tenderness of testis postoperatively for about a week which was managed conservatively.

Patients' follow-up was from three months to five years with average of one year follow-up. Comparison of testicular level and mobility in scrotal sacs was noted on two sides. In one patient, a testis was hanging at a different level on standing position which was unacceptable to the patient. Since the patient also had a pinpoint fistula, he underwent purse string suturing of fistula and on exploration testis was found to be tethered at higher level by pedicle of the tunica vaginalis flap, which could not be identified as separate layer. Incising this fibrosed tissue restored parity of level with opposite testis. Testicular mobility in scrotal sac was found to be normal in follow-up as compared with normal sides. While incidence of fistula of all types on 14th day was 17/

Table 1: Distribution of types of hypospadias. No patient of glanular hypospadias was seen probably because lack of awareness in public

<i>Distribution of hypospadias</i>	<i>n = 126</i>	<i>(%)</i>
Glanular	0	0
Coronal	24	20.5
Distal penile	56	44.5
Mid-penile	14	11
Proximal penile	16	12
Peno-scrotal	16	12

Table 2: Hypospadias surgery distribution

<i>Hypospadias repair</i>	<i>n = 126</i>	<i>(%)</i>
Mathieu's	32/	25.3
Snodgrass	28	22.2
Theirsh-duplay	20	15.8
Tube flap	32	25.7
Devine-horton	2	1.5
Miscellaneous	12	9.5

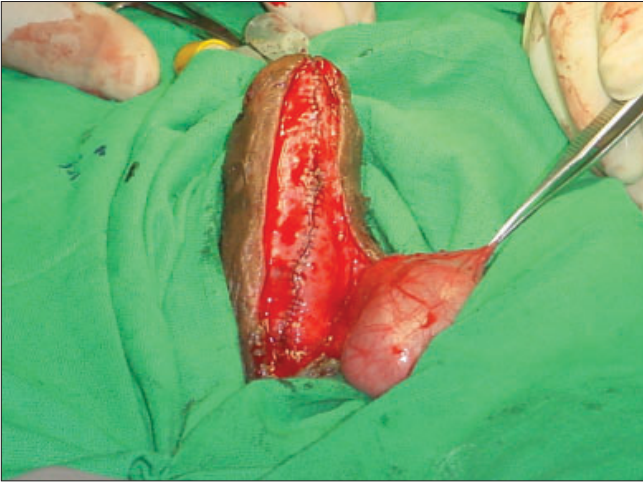


Figure 1: Testis delivered into operative field through same incision

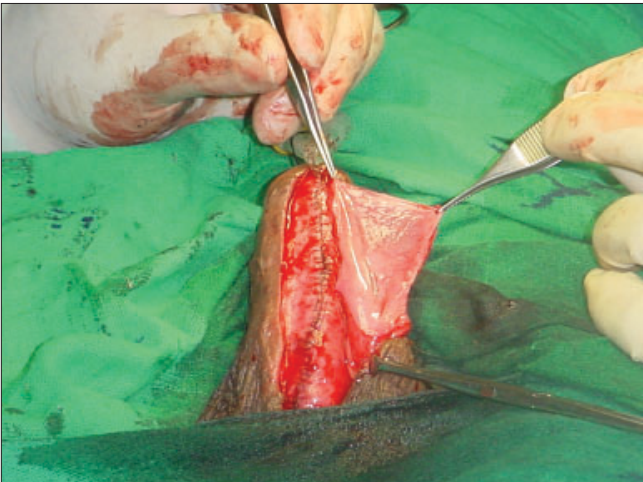


Figure 2: Tunica vaginalis flap harvested and ready for inseting

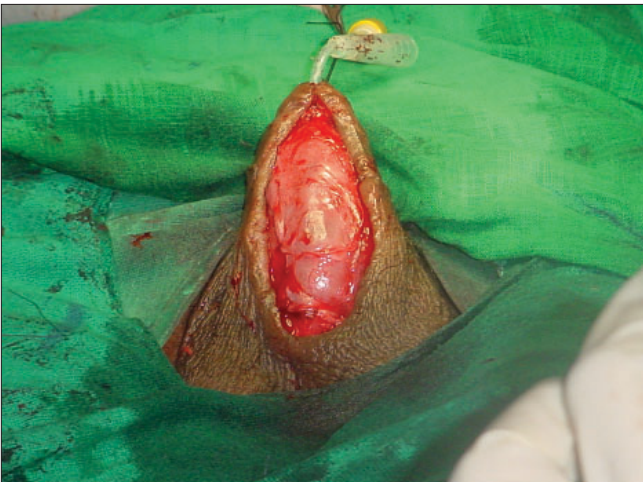

Figure 3: Tunica vaginalis flap enough to cover whole length of shaft

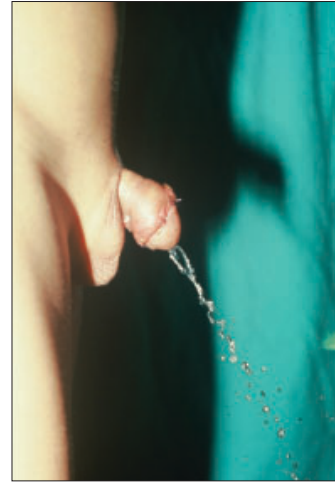


Figure 4: Urine stream through neo-meatus



Figure 5: frontal view after one year

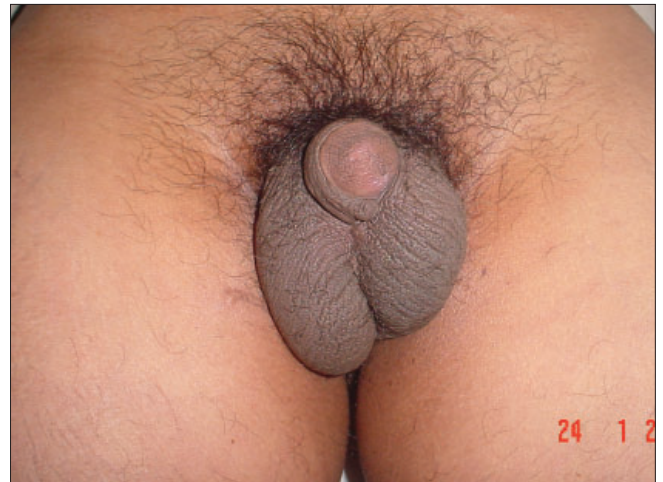

Figure 6: Showing testicular tethering

126 [Table 3], 10 patients developed pinpoint fistula which was repaired by purse string suture without catheterization with two recurrences. In two patients,

fistula healed within one month without recurrence. Five patients were successfully operated for fistula with tunica vaginalis flap cover after six months.

Table 3: Comparison fistulae rate of procedures with and without tunica vaginalis interposition layer. Statistical analysis by Fisher test shows significance when P value <0.5

Procedure	Patients	Fistula		% fistula
		No fistula	Fistula	
Snodgrass without	20	17	3	15%
Snodgrass with Tvbw	8	7	1	12.5%
		Exact test P value = 0.68		
Total	28		4	14.5%
Two stage without	12	9	3	25%
With Tvbw	20	19	1	5%
		Exact test P value = 0.13		
Total	32		4	21.8%
Miscellaneous without tvbw	3	0	3	100%
With tvbw	9	9	0	0%
		Exact test P value = 0.004		
Total	12		3	25%
Fistula repair without	10	8	2	20%
Fistula repair with Tvbw	5	5	0	0%
		Exact test P value = 0.42		
Total	15		2	13.3%

DISCUSSION

Hypospadias is one of the most common anomalies in boys with urethro-cutaneous fistula being the most common postoperative complication. Better suture materials, use of magnification, dorsal subcutaneous flap, silicone stents and catheters have all contributed to a decrease in fistula rate.^[7] The incidence of fistula can be used to judge the success of hypospadias surgery.^[8] Durham Smith in a study of hypospadias surgery noted varied fistula rates for different procedures.^[9] Flip-flap repair varied from 2.2 to 35%, island pedicle tube flap 4 to 35%, free graft tube flap had a fistula rate of 15 to 50%.^[9] Durham Smith had a fistula rate of 3% in 500 cases.^[10]

In this series, the overall fistula rate was 13% [Table 4] hypospadias surgery has zero tolerance rate for errors hence routinely performed procedures have reasonable fistula rate compared to rare procedures. Of 15 fistulae, two healed spontaneously in one month, while ten required operative intervention (purse string suture) without catheterization as day care procedure, with two recurrences. Five fistulae were closed successfully requiring equally demanding surgery along with tunica

vaginalis cover without recurrence. Shanker *et al*^[11] had a similar experience with the use of tunica vaginalis flap for fistula surgery. They reported a success rate of 50% with fistula of >2 mm but without the use of tunica vaginalis and had only one recurrence in six cases when tunica was used in a third attempt for fistula repair. They reported success in 71% cases in first attempt for fistula repair, 70% in second attempt and 50% in third and subsequent repairs.^[12] In our experience the use of tunica vaginalis as waterproofing cover in the first instance decreases fistula rate coupled with the fact that the fistulae are small in size and are easily manageable.

Introduction of this flap is credited to Snow^[13] *et al* in 1986. Tunica vaginalis as graft supplement for deficient tunica albuginea in occasional case of severe chordee has been used since a long time. It was in fact preferred by Baskin *et al*, for its elastic nature, an advantage over lyophilized dura or dermis.^[14] It has a dependable blood supply from the cremasteric vessels and its pedicle length can safely be increased up to the external inguinal ring. Care must be taken while increasing pedicle length as the tissue becomes more flimsy proximally and at the same time inadequate pedicle length can cause tethering of the testis at a higher level compared to the normal side in an erect position as was the case in one of our patients [Figure 6], where on exploration for correction of tethering effect, tunica vaginalis could not be identified as separate layer but as fibrous tissue. Similar findings have been reported by Das *et al* in experimental animals.^[15]

Two of our patients had a catheter block on Day 4 and

Table 4: Fistula rate with different procedures

Complications of different procedures:		
Type of surgery	Fistula/number of pts	Percentage
Mathieu's repair	2/32	6.25
Theirsh-duplay repair	2/20	10
Snodgrass repair	4/28	14.25
Tube flap repair	4/32	12.5
Miscellaneous repair	3/12	25
Devine-horton repair	2/2	100

Day 9 respectively where the catheter had to be removed. Surgeons usually resort to suprapubic cystostomy for diversion of urine in the event of catheter blockage or extrusion in immediate postoperative period. In our case, having an additional layer on the neo-urethra gave confidence in allowing the patient to void through neo-meatus and ultimately repair healed without fistula.

Ten patients had wound healing problems because of skin excoriation and wound dehiscence but had complete healing without fistula formation because of vascular tunica vaginalis interposition layer acting as barrier.^[16] Dartos flap interposition layer when separated from the overlying skin can also be rotated and placed over neo-urethra but may be associated with torsion of penis and an increased incidence of wound healing problems in the form of small eschar, edema and skin dehiscence. John Duckett has ascribed it to hypovasularity of the overlying skin when dartos is separated from skin.^[17]

Scrotal hematoma and scrotal abscess can occur but fortunately did not occur in our series.

CONCLUSIONS

Tunica vaginalis flap as interposition cover of neo-urethral tube helps in reduction of fistulae rate in all hypospadias procedures with minimal complication rate. Suture line breakdown also heals without fistula formation if otherwise meticulous repair has been done which is the prerequisite for hypospadias surgery. It gives the surgeon extra confidence that fistula will not occur in an unlikely event of early catheter extrusion or catheter blockade without having to resort to suprapubic cystostomy. This study again confirms interposition layer as a must

for reduction of fistulae in hypospadias surgery.

REFERENCES

- Hodgson NB. History of hypospadias repair, *Reconstructive and plastic surgery of the external genitalia adult and pediatric*. WB Saunders Company; 1999. p. 16.
- Belman AB. *In: Kelalis PP, King LR, Belmanab, (editors) Urethra, Clinical Paediatric Urology, 2nd ed. WB Saunders;* 1985. p. 781.
- Culp OS. Experience with 200 hypospadias: Evolution of a therapeutic plan. *Surg Clin North Am* 1959;39:1007-23.
- Retic AB, Mandell J, Bauer SB, Atala A. Meatal based hypospadias repair with use of dartos sub-cutaneous flap to prevent urethra-cutaneous fistula. *J Urol* 1994;152:1229-31.
- Gittes RF, McLaughlin AP 3rd. Injection technique to induce penile erection. *Urology* 1974;4:473-4.
- Smith ED. Durham smith repair of hypospadias. *Urol Clinic North Am* 1981;8:451-5.
- Retic AB, Keating M, Mandell J. Complications of hypospadias repair. *Urol Clin North Am* 1988;15:223-6.
- Durham SE. Hypospadias. *In: Ashcraft K (editor): Pediatric urology*. WB Saunders: Philadelphia; 1990. p. 353-95.
- Shapiro SR. History of hypospadias repair, *reconstructive and plastic surgery of the external genitalia adult and pediatric*. WB Saunders Company; 1999. p. 132.
- Smith ED. Durham smith repair of hypospadias. *Urol Clin North Am* 1981;8:451-5.
- Shanker KR, Losty PD, Hopper M, Wong L, Rickwood AM. Outcome of hypospadias fistula repair. *BJU Int* 2002;89:103-5.
- Richter F, Pintopa, Stock JA, Hanna MK. Management of recurrent urethral fistulas after hypospadias repair. *Urology* 2003;61:448-51.
- Snow BW, Cartwright PC, Unger K. Tunica vaginalis blanket wrap to prevent urethra-cutaneous fistulas an eight year experience. *J Urol* 1995;153:472-3.
- Baskin S. Laurencepenile curvature reconstructive and plastic surgery of the external genitalia adult and pediatric. WB Saunders Company; 1999. p. 23.
- Das S, Maggio AJ. Tunica vaginalis autografting for Peyronie's disease. An experimental study. *Invest Urol* 1979;17:186-7.
- Snow BW, Cartwright PC. Tunica Vaginalis Blanket wrap, reconstructive and plastic surgery of the external genitalia adult and paediatric. WB Saunders Company; 1999. p. 112.
- Duckett JW. *Campbell's urology, 7th ed. WB Saunder Company;1998. p. 2114.*