

## Review Article

# Reconstructive foot and ankle surgeries in diabetic patients

**Ajit Kumar Varma**

Department of Endocrinology, Diabetic Lower Limb and Podiatric Surgery, Amrita Institute of Medical Sciences and Research Center, Ponekkara, P.O. Kochi, Kerala, India

**Address for correspondence:** Dr. Ajit Kumar Varma, Department of Endocrinology, Diabetic Lower Limb and Podiatric Surgery, Amrita Institute of Medical Sciences and Research Center, Ponekkara, P.O. Kochi, Kerala - 682 041, India. E-mail: [ajitkumarvarma@aims.amrita.edu](mailto:ajitkumarvarma@aims.amrita.edu)

### ABSTRACT

Diabetic foot and ankle deformities are secondary to long-standing diabetes and neglected foot care. The concept of surgical correction for these deformities is quite recent. The primary objective of reconstructive foot and ankle surgery is the reduction of increased plantar pressures, reduction of pain and the restoration of function, stability and proper appearance. Foot and ankle deformities can result in significant disability, loss of life style, employment and even the loss of the lower limb. Therefore, restoration of normal, problem free foot function and activities will have a significant impact on peoples' lives. Reconstructive surgical procedures are complex and during reconstruction, internal and external fixation devices, including pins, compression screws, staples, and wires, may be used for repair and stabilization. The surgeries performed depend on the type and severity of the condition. Surgery can involve any part of the foot and ankle, and may involve tendon, bone, joint, tissue or skin repair. Corrective surgeries can at times be performed on an outpatient basis with minimally invasive techniques. Recovery time depends on the type of condition being treated.

### KEY WORDS

Diabetic foot; foot deformities; foot reconstruction; planter pressure points

### INTRODUCTION

Today, in India, there are more than 45 million diabetes patients and an estimated 50,000 amputations occurring every year due to diabetes-related foot problems.<sup>[1]</sup> India had the largest number of diabetic patients in the world till the year 2006 as claimed in the 'International Diabetic Federation' conference at Copenhagen, in November 2006. Latest statistics however

state that China has overtaken India as the Diabetic capital of the world. The commonest cause of diabetic foot is the infected neuropathic foot, which is potentially preventable. There are very few organised diabetic foot screening programs and Podiatric services available only in major centres in India but a multidisciplinary team approach is mostly lacking. Proper diabetic orthotics is not easily available.

### REVIEW OF LITERATURE

Socioeconomic factors like barefoot walking, inappropriate footwear usage, lack of awareness of the seriousness of diabetic foot problems among doctors and patients and hence, late reference to specialty centres are too matters of concern. 70% of the population in India lives in the rural area and 40% stay in one-room tenements.

#### Access this article online

Quick Response Code:



Website:

[www.ijps.org](http://www.ijps.org)

DOI:

10.4103/0970-0358.90806

Inadequate sanitation, improper foot offloading due to lack of facilities and awareness are common.<sup>[2]</sup> Diabetic foot conditions develop from a combination of the twin causes of poor circulation and neuropathy. Diabetic neuropathy can cause insensitivity or a loss of ability to feel pain, heat and cold.<sup>[3]</sup> Diabetics suffering from neuropathy can develop minor cuts, scrapes, blisters or pressure sores that they may not be aware of due to the insensitivity. If these minor injuries are left untreated, complications may result and lead to ulceration and possibly even amputation.<sup>[4]</sup> Neuropathy can also cause deformities such as Bunions, Hammer Toes and Charcot's Foot. These are resulting from undue bony prominences with high pressure points, leading to callosities and ulcerations.<sup>[5]</sup> These are small portals for bacterial entry, leading to the development of serious limb and life-threatening infections in these immunocompromised patients.

The concept of surgical correction for the diabetic foot and ankle deformity has evolved as a means to correct foot deformities secondary to long-standing diabetes.<sup>[6]</sup> This reshaping of a deformed foot or toes by surgical correction is presently being done routinely only in a few selected centres worldwide, as in the U.S, U.K, Russia, Germany, Spain and Australia, to name a few. These surgeries help to normalise raised plantar pressures and thus prevent the formation of callus and ulcers of the foot and thus prevent amputations in diabetics.<sup>[7]</sup> Overriding of the big toe and crowding of toes can cause skin breakdown, thus resulting in ulcers and infection. Corrective surgery is done to bring the toes to their normal position. If the foot is not properly aligned, then again high pressures build up in the soles causing ulceration.<sup>[8]</sup> 'Charcot's Foot' is a severe complication of diabetes, which leads to erosions and collapse of the foot and ankle bones and the planter arches, which in turn lead to marked deformities, raised plantar pressures and thus formation of ulcers.<sup>[9]</sup> Different types of surgical corrections are carried out so as to normalise the shape and function of these grossly deformed feet.

Pinzur *et al.* collected data over a 10-year period on treating Charcot arthropathy of the foot and ankle. According to the data, 48.5% of patients were treated with conservative therapy, while 50.6% of patients underwent surgery. The surgical procedures included 21 major limb amputations, 29 ankle fusions, 26 hind foot fusions, 23 exostectomies and 23 debridements for osteomyelitis. Conservative management of Charcot

deformities (stage I or stage II), in the form of total contact casts, bracing devices and/or accommodative footwear, is approximately 75% effective.<sup>[10]</sup>

Myerson and Edwards found that surgical correction resulted in lower-extremity stabilisation in 93% of patients who presented with severe foot and ankle deformity.<sup>[11]</sup>

## DIABETIC FOOT RECONSTRUCTIVE SURGERIES

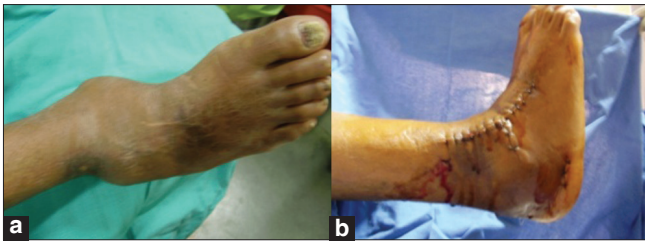
Charcot's destruction does not occur in the absence of peripheral neuropathy and approximately 30 to 50% of patients with diabetes have peripheral neuropathy. Unfortunately, there is a significant discrepancy in the literature when it comes to the incidence of Charcot in patients with diabetes as the incidence ranges from 0.2 to 29%.<sup>[12]</sup>

Although Charcot represents one end of the spectrum of diabetic foot deformities, longstanding, motor-sensory neuropathy secondary to diabetes represents the other end of the spectrum. On average, a majority of the mild to moderate foot deformities is amenable to accommodative footwear, conservative management and/or bracing.<sup>[13]</sup>

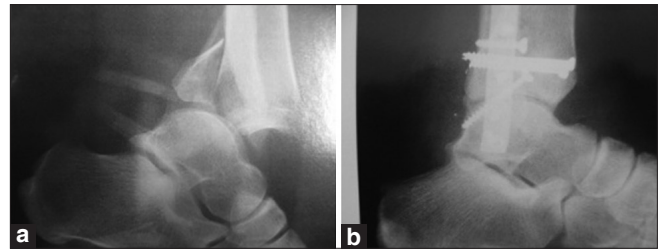
In recent years, reconstructive foot surgery has assumed an important role in the management of Charcot feet that cannot be effectively treated by casting, bracing or footwear therapy.<sup>[14]</sup> Although the appropriateness of reconstructive surgery during the acute phase is still a matter of debate,<sup>[15]</sup> surgery on the chronically deformed or unstable quiescent Charcot foot has become rather common in current practice. The majority of operations consist of plantar exostectomies in combination with Achilles tendon lengthening to remove bony prominences associated with recurrent ulcers and high plantar foot pressures.<sup>[16]</sup>

Complex reconstructive procedures with arthrodeses are more frequently reserved for realignment and stabilisation of severely deformed feet or ankles in an effort to avoid amputation<sup>[17]</sup> [Figures 1-3].

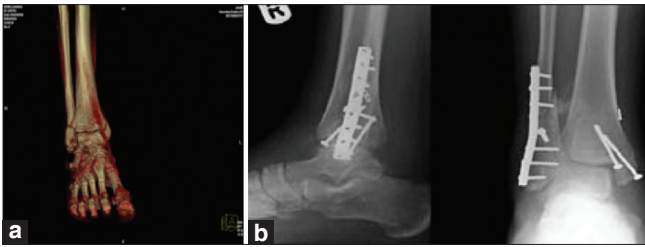The choice of internal or external fixation depends on the quality of the bone. Generally, in Charcot syndrome, the bone stock is poor and external fixation provides better compression with fewer fixation failures. When internal fixation is used, locking plates may prevent backing out



**Figure 1:** Midfoot Charcot reconstruction photos (a) Pre operative (b) Post operative



**Figure 2:** Charcot ankle fracture, internal fixation (a) Pre operative (b) Post operative



**Figure 3:** Trimalleolar Charcot ankle fracture, reconstruction (a) Pre operative C. T. scan (b) Post operative X ray

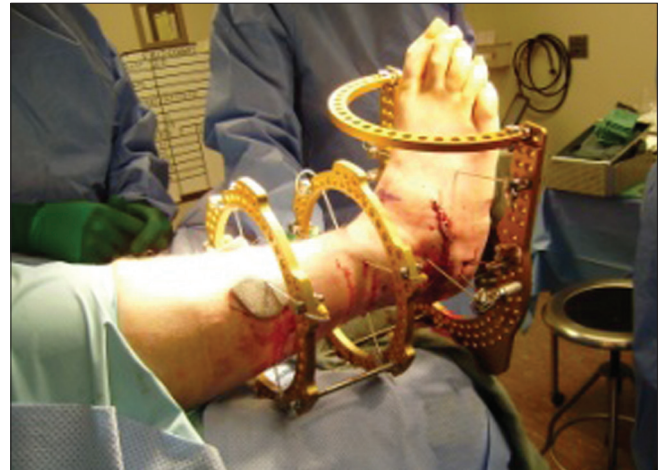of hardware. Due to its ability to correct multiplanar deformities in osteopenic bone even in the presence of open wounds, the Ilizarov external fixation is routinely used in Charcot foot reconstructions.

External fixation is associated with a high rate of complications (pin tract infections and wire breakage),<sup>[17,18]</sup> but if recognised early, these can be easily treated and are non-limb-threatening. Nonetheless, the surgeon should not apply these frames without anticipating such complications at the outset and be prepared to manage them accordingly. The use of silver-impregnated foam as a pin site dressing can help to prevent pin tract infections [Figure 4].

The post-treatment prevention of recurrence, contralateral Charcot's joint and ulceration is equally as important as the treatment phase. Once the foot becomes stable through medical or surgical means, the emphasis must be on prevention of recurrent ulcers. Custom braces and orthoses such as the Charcot restraint orthotic walker (CROW) can be an effective method to brace a deformed extremity.<sup>[19]</sup>

In general, custom-fabricated patellar tendon-bearing braces, CROW devices or ankle-foot orthoses are advised for at least 12 months after reconstructive surgery; some patients may require the device for their lifetime.<sup>[20]</sup>

Critically important, appropriately designed or fitted shoes with weight-dispersing accommodative insoles



**Figure 4:** Ilizarov external fixator

are necessary for protection and gentle support. These patients are at high risk for subsequent ulceration and therefore require close follow-up and life-long surveillance.

Early diagnosis is a key factor in the management of the Charcot foot and plays a central role in the prevention of severe deformity. If diagnosed early, medical and conservative measures will usually suffice in this regard. Surgery is most often reserved for those patients with severe or unstable deformities that are not amenable to long-term bracing or footwear therapy alone. A team approach is recommended to prevent patients with these high-risk foot deformities from succumbing to limb loss.

Adult-acquired flatfoot deformity or posterior tibial tendon dysfunction is a gradual but progressive loss of one's arch. The posterior tibial muscle is a deep muscle in the back of the calf. It has a long tendon that extends from above the ankle and attaches into several sites around the arch of the foot. The muscle acts like a stirrup on the inside of the foot to help support the arch. The posterior tibial muscle stabilises the arch and creates a rigid platform for walking and running. If the posterior tibial tendon becomes damaged or tears, the

arch loses its stability and as a result, collapses causing a flatfoot.<sup>[21]</sup> Adult flatfoot deformity can occur in people of all ages and gender; however, it occurs most commonly in sedentary middle-aged to elderly females. There are several risk factors for posterior tibial tendon dysfunction that include diabetes, obesity, steroid use and systemic inflammatory diseases such as rheumatoid arthritis, trauma and congenital low arch. It occurs most commonly in one foot; however, it can occur in both feet, especially in people with systemic diseases such as diabetes and rheumatoid arthritis. Surgical correction is dependent on the severity of symptoms and the stage of deformity. The goals of surgery are to create a more functional and stable foot.<sup>[22]</sup> There are multiple procedures like fixation with compression screws, placement of subtalar titanium implant, with or without soft tissue reconstructions which are available to the surgeon and it may take several sittings to correct a flatfoot deformity [Figure 5].

Hallux valgus is a condition where the great toe is deviated laterally at the metatarsophalangeal joint. This causes raised plantar pressure at the region of the metatarsal head, leading to the formation of callosities and subsequent ulcers. Surgical correction of this deformity is thus important [Figure 6]. A bunion actually refers to the bony prominence or exostosis on the side of the big toe. A large sac of fluid, known as a bursa, can form over the enlarged joint, which can then become inflamed and painful. Surgery to remove the bony prominence is called a bunionectomy.<sup>[23]</sup> Smaller bunions can also develop on the outside of the little toe joint, these are known as Tailors bunions and are also treated surgically.

Hallux limitus or rigidus of the big toe joint can cause pain and loss of motion. Walking requires the big toe to bend upward or dorsiflex. Without this movement, the big toe joint wears out or may even seize up completely. The condition can be treated using a variety of surgical techniques like metatarsal head resection or arthroplasty.<sup>[24]</sup> It is essential to find the true cause of

the condition. The condition is known to be caused by a long metatarsal, or by a number of other biomechanical imbalances.

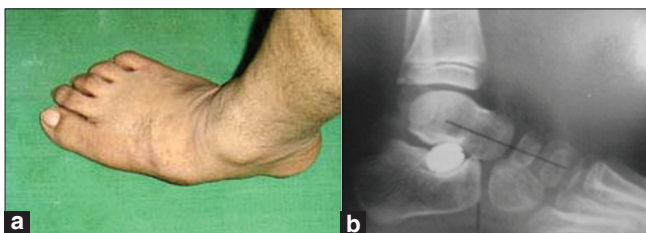
Prosthetic joints can be used to treat the condition if the joint is beyond repair. These can be made of silastic rubber, titanium or even ceramic. The choice of the type of implant depends on the individual patient's needs.

Arthritis of the joints of the arch of the foot often goes unnoticed until it has become quite advanced. There are many types of arthritis but osteoarthritis is the most common type to affect these joints. Early symptoms can include 'aches' within the joints, often occurring after activity. In later stages, there may be persistent swelling around the joint or hard lumps around the edge of the joints. In some patients, these lumps (called 'osteophytes') are the cause of additional symptoms because they cause pressure on adjacent soft tissue structures. Removal of the osteophytes or surgical fusion of the damaged joints is the usual surgical treatment.<sup>[25]</sup>

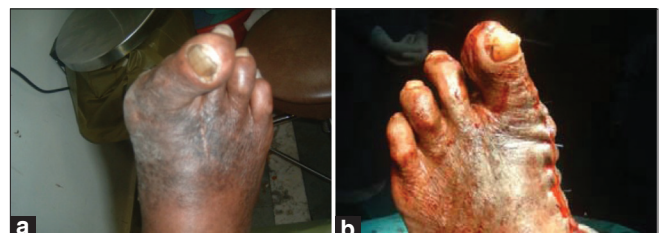Hammer, Mallet and Claw toes are deformities of the lesser toes usually caused by tendon or joint imbalance. Hammer toes can be painful and unsightly. Surgery to correct the hammer, mallet or claw toe deformity will usually permanently cure the formation of painful corns on skin overlying these joints.<sup>[24]</sup>

Neuromas are enlarged nerves, usually between the third and fourth toes, caused by nerve irritation and entrapment between bones.<sup>[26]</sup> Ablative surgery under magnification generally result in permanent resolution of this sometimes extremely painful condition.<sup>[27]</sup>

Plantar Fasciitis is an inflammation of the connective tissue found on the underside of the foot. Most patients respond to non-surgical treatment such as the prescription of orthoses, but on occasion, surgery is required. Keyhole techniques are also used to treat this condition.<sup>[28]</sup>



**Figure 5:** (a) Pre-operative photo (b) post-operative x-ray showing subtalar implant for correction of adult flatfoot deformity



**Figure 6:** Hallux Valgus (reconstruction) (a) Pre operative (b) Post operative

Haglund's Deformity is an enlargement of the bone at the back of the heel, which can encourage bursitis to develop. Various operations are utilised, ranging from bone removal to the 'tilting' of bones into a better position to alleviate the problem.<sup>[29]</sup>

Bone spurs are excessive growth of bone causing pain or limitation of movement. Spurs can develop at the edges of joints, tendons and ligaments.<sup>[30]</sup> Their removal can usually be undertaken under local anaesthetic.

### Achilles tendon problems

Usually, this is due to contracture of the tendon. This causes raised forefoot plantar pressures, resulting in callosities and ulcerations. Most patients respond to non-surgical treatment with physiotherapy and proper footwear.<sup>[31]</sup> Occasionally, surgical intervention is required where the tendon is stripped of its inflamed thickened tissue. However, this may at times lead to the tendon getting adhered to the surrounding soft tissues. Many a times, tendon lengthening, by various techniques, is required to treat the condition.<sup>[32]</sup>

### Tendon transfer surgeries

Commonly carried tendon transfer surgery is the Tibialis anterior total or split transfer in the correction of usually occurring equinovarus deformity after a transmetatarsal or a chauparts midfoot amputation. Many other such tendon transfer surgeries are recommended for the correction of various foot and ankle deformities.<sup>[33]</sup>

### CONCLUSIONS

The department of Endocrinology, Diabetic lower limb and Podiatric surgery, Amrita Institute of Medical Sciences And Research Center, Kochi, Kerala, is the only centre in India where these reconstructive and corrective surgeries are being performed in large numbers, exclusively in high-risk diabetic foot patients. By employing these surgical techniques, a large number of amputations in patients with diabetic foot ulcers and deformed diabetic feet are being prevented. To avoid the serious complications of pin tract infections, wire breakage and others associated with the application of Ilizarov frames and other types of external fixators in diabetic patients, we have devised a novel technique of foot and ankle stabilisation, 'The Amrita Sling Technique'.<sup>[34]</sup> By comprehensive management, we have been able to maintain a limb salvage rate of 91.5%, in diabetic foot and ankle diseases, comparable to the best centres in the world.

### REFERENCES

1. Definition, diagnosis and classification of diabetes mellitus and its Complication. Report of consultation. Geneva: WHO; 1999 Report 250.
2. Vijay V, Snehalatha C, Ramachandran A. Socio-cultural practices that may affect the development of the diabetic foot. 'International Diabetic Federation' Bulletin 1997;42:10-2.
3. Morbach S, Lutale JK, Viswanathan V, Mollenberg J, Ochs HR, Rajashekar S, *et al.* Regional differences in risk factors and clinical presentation of diabetic foot lesions. *Diabet Med* 2004;21:91-5.
4. Armstrong DG, Wrobel J, Robbins JM. Guest Editorial: Are diabetes-related wounds and amputations worse than cancer? *Int Wound J* 2007;4:286-7.
5. Rogers LC. Preventing amputation in patients with diabetes. *Podiatry Today* 2008;21:44-50.
6. Banks AM, McGlamry ED. Charcot foot. *J Am Podiatr Assoc* 1979;5:213-35.
7. Apelqvist J, Larsson J, Agardh C. Changing Perspectives in Diabetic Foot Ulcer Management. Long-term prognosis for diabetic, patients with foot ulcers. *J Intern Med* 1993;233:485-91.
8. Kelly M. William Musgrave's De Arthritide Symptomata (1703). *Bull Hist Med* 1963;37:372-6.
9. Brower AC, Allman RM. The neuropathic joint. *Radiol Clin North Am* 1981;19:571-9.
10. Pinzur MS, Anderson RB, Cantrall R, Lamborn K. The American Orthopaedic Foot and Ankle Society Diabetes 2000 Foot Screen. Vail, CO: Annual Summer Meeting of the American Orthopaedic Foot and Ankle Society; 2000.
11. Myerson MS, Edwards WH. Management of Neuropathic Fractures in the Foot and Ankle. *J Am Acad Orthop Surg*. 1999;7:8-18.
12. Infante AF Jr, Heier K, DiPasquale T, Herscovici D Jr, Walling A, Sanders RW. Operative treatment of 635 displaced intra-articular calcaneal fractures. Orlando, FL: Annual Meeting of the American Academy of Orthopaedic Surgeons; 2000.
13. Rippstein P. Agility ankle prosthesis: Results of 27 cases. Vail, CO: Annual Summer Meeting of the American Orthopaedic Foot and Ankle Society; 2000.
14. Frykberg RG, Zgonis T, Armstrong DG, Driver VR, Giurini JM, Kravitz SR, *et al.* Diabetic foot disorders. A clinical practice guideline (2006 revision). *J Foot Ankle Surg* 2006;45: S1-66.
15. Roukis TS, Zgonis T. The management of acute Charcot fracture-dislocations with the Taylor's spatial external fixation system. *Clin Podiatr Med Surg* 2006;23:467-83.
16. Catanzariti AR, Mendicino R, Haverstock B. Ostectomy for diabetic neuroarthropathy involving the midfoot. *J Foot Ankle Surg* 2000;39:291-300.
17. Wukich DK, Belczyk RJ, Burns PR, Frykberg RG. Complications encountered with circular ring fixation in persons with diabetes mellitus. *Foot Ankle Int* 2008;29:994-1000.
18. Rogers LC, Bevilacqua NJ, Frykberg RG, Armstrong DG. Predictors of postoperative complications of Ilizarov external ring fixators in the foot and ankle. *J Foot Ankle Surg* 2007;46:372-5.
19. Bevilacqua NJ, Dankert JP, Rogers LC, Armstrong DG. A technique to protect external fixation devices. *J Foot Ankle Surg* 2008;47:172-4.
20. Mendicino RW, Catanzariti AR, Saltrick KR, Dombek MF, Tullis BL, Statler TK, *et al.* Tibiotalocalcaneal arthrodesis with retrograde intramedullary nailing. *J Foot Ankle Surg* 2004;43:82-6.
21. Fleischli JE, Anderson RB, Davis WH. Dorsiflexion metatarsal osteotomy for treatment of recalcitrant diabetic neuropathic ulcers. *Foot Ankle Int* 1999;20:80-5.

22. Tanaka Y, Takakura Y, Sugimoto K, Kumai T, Sakamoto T, Kadono K. Precise anatomic configuration changes in the first ray of the hallux valgus foot. *Foot Ankle Int* 2000;21:651-6.
23. Coughlin MJ, Dorris J, Polk E. Operative repair of the fixed hammertoe deformity. *Foot Ankle Int* 2000;21:94-104.
24. Taranow WS, Bisignani GA, Towers JD, Conti SF. Retrograde drilling of osteochondral lesions of the medial talar dome. *Foot Ankle Int* 1999;20:474-80.
25. Morscher E, Ulrich J, Dick W. Morton's intermetatarsal neuroma: Morphology and histological substrate. *Foot Ankle Int* 2000;21:558-62.
26. Colgrove RC, Huang EY, Barth AH, Greene MA. Interdigital neuroma: Intermuscular neuroma transposition compared with resection. *Foot Ankle Int* 2000;21:206-11.
27. Zingas CN, Collon D, Anderson K. Shock wave therapy for plantar fasciitis. Vail, CO: Annual Summer Meeting of the American Orthopaedic Foot and Ankle Society; 2000.
28. Eichenholtz SN. Charcot Joints. Springfield: Charles C. Thomas; 1966.
29. Rogers LS, Frykberg RG. A Guide to Early Intervention for the Charcot foot. *Podiatry Today* 2008;21:66-72.
30. Guyton GP, Mann RA. Flexor digitorum longus transfer and medial displacement calcaneal osteotomy for posterior tibial tendon dysfunction: A middle-term clinical follow-up. Vail, CO: Annual Summer Meeting of the American Orthopaedic Foot and Ankle Society; 2000.
31. Mosier-LaClair S, Pomeroy G, Manoli A. Immediate follow-up on the durable osteotomy and tendon transfer procedure for grade II posterior tibial tendon insufficiency. Vail, CO: Annual Summer Meeting of the American Orthopaedic Foot and Ankle Society; 2000.
32. Song S, Deland JT. The use of the peroneus brevis tendon transfer in posterior tibial tendon insufficiency. Orlando, FL: Annual Winter Meeting of the American Orthopaedic Foot and Ankle Society; 2000.
33. Mizel MS, Temple HT, Scranton PE Jr, Gellman RE, Hecht PJ, Horton GA, *et al*. Role of the peroneal tendons in the production of the deformed foot with posterior tibial tendon deficiency. *Foot Ankle Int* 1999;20:285-9.
34. Varma AK, Mangalanandan TS, Kumar H. Amrita Sling Technique: A novel method of foot and ankle stabilization in the deformed Charcot foot. *J Diabet Foot Complications* 2009;1:1-7.

**How to cite this article:** Varma AK. Reconstructive foot and ankle surgeries in diabetic patients. *Indian J Plast Surg* 2011;44:390-5.

**Source of Support:** Nil, **Conflict of Interest:** None declared.

### Author Help: Online submission of the manuscripts

Articles can be submitted online from <http://www.journalonweb.com>. For online submission, the articles should be prepared in two files (first page file and article file). Images should be submitted separately.

1) **First Page File:**

Prepare the title page, covering letter, acknowledgement etc. using a word processor program. All information related to your identity should be included here. Use text/rtf/doc/pdf files. Do not zip the files.

2) **Article File:**

The main text of the article, beginning with the Abstract to References (including tables) should be in this file. Do not include any information (such as acknowledgement, your names in page headers etc.) in this file. Use text/rtf/doc/pdf files. Do not zip the files. Limit the file size to 1024 kb. Do not incorporate images in the file. If file size is large, graphs can be submitted separately as images, without their being incorporated in the article file. This will reduce the size of the file.

3) **Images:**

Submit good quality color images. Each image should be less than **4096 kb (4 MB)** in size. The size of the image can be reduced by decreasing the actual height and width of the images (keep up to about 6 inches and up to about 1800 x 1200 pixels). JPEG is the most suitable file format. The image quality should be good enough to judge the scientific value of the image. For the purpose of printing, always retain a good quality, high resolution image. This high resolution image should be sent to the editorial office at the time of sending a revised article.

4) **Legends:**

Legends for the figures/images should be included at the end of the article file.