

Original Article

Closure and augmentation of bladder exstrophy using rectus abdominis musculo-peritoneal flap

P. Agarwal

Plastic Surgery Unit, Department of Surgery, N.S.C.B. Government Medical College, Jabalpur, Madhya Pradesh, India

Address for correspondence: Dr. Pawan Agarwal, 292/293 Napier Town, Jabalpur – 482 001, Madhya Pradesh, India.

E-mail: drpawanagarwal@yahoo.com

ABSTRACT

Background: The aim of this study was to investigate the efficacy of the rectus abdominis myo-peritoneal flap (RAMP) technique for the closure and augmentation of small, non-elastic, non-compliant bladder exstrophies. **Materials and Methods:** The RAMP technique was used in three boys with bladder exstrophy who presented late with small, non-elastic, non-compliant bladder. The clinical outcome, imaging, cystoscopy, biochemical and microbiological studies were assessed during a follow-up of 36 months. **Results:** Bladder closure and augmentation was achieved in all patients without any complications. There were no urinary tract infections, metabolic problems or electrolyte disturbances and the kidney function remained normal in all patients. Radiography confirmed intact function and anatomy of the urinary tract and cystoscopy showed complete coverage of the inner peritoneal layer of RAMP with uroepithelium. No stone formation or mucous production was detected. **Conclusions:** The RAMP technique is a good alternative for closing bladder exstrophies and achieves an increase in bladder capacity and compliance. The technique is indicated in the closure of large bladder defects, bladder exstrophies with small, inelastic, non-compliant bladder remnants and failed primary closures.

KEY WORDS

Augmentation of bladder, bladder exstrophy, rectus abdominis musculo-peritoneal flap

INTRODUCTION

Bladder exstrophy is a rare malformation, with the incidence of 1 in every 30,000–40,000 births. It occurs when the abdominal wall and underlying structures, including the ventral wall of the bladder, fail to fuse in utero.^[1] As a result, the lower urinary tract is exposed, and the everted bladder appears through

the abdominal opening. Various surgical interventions have been employed with variable success in the hope of achieving complete dryness, control over delivery of urine, freedom from catheters, and a protected upper urinary tract. The most popular surgical approach is the primary bladder closure with secondary bladder neck reconstruction. But this approach is not suitable for the delayed presentation and non-elastic, non-compliant squamous epithelial metaplasia and polypoid transformation of bladder.^[2] The use of isolated intestinal segments is the most common method of augmenting bladder capacity. Incorporation of bowel segments in the genitourinary tract is associated with several metabolic consequences and late surgical complications. The gastrointestinal tract is a relatively poor substitute

Access this article online

Quick Response Code:



Website:

www.ijps.org

DOI:

10.4103/0970-0358.90817

for urothelium and its semipermeability permits non-physiological fluid and electrolyte abnormalities.^[3]

The ability to perform a successful augmentation cystoplasty using non-intestinal tissue would decrease the morbidity and postoperative complications. We studied the use of skeletal muscle based parietal peritoneal in augmentation cystoplasty. The results of a new technique of bladder closure and augmentation in children born with bladder exstrophy are reported.

MATERIALS AND METHODS

Bladder closure and augmentation was performed in three children born with bladder exstrophy, using the rectus abdominis myo-peritoneal flap (RAMP) flap. Before commencement of the study, institutional ethical committee approval was taken. Age of the patients

ranged from 6 to 14 years, with a mean age at operation of 8 years. All patients had small, inelastic bladder with polypoidal transformation of mucosa [Figure 1]. The surface area of bladder ranged from 10 to 24 cm². None of them had undergone any previous attempt to close the bladder. After preoperative preparation, the procedure was started with incision at the junction of bladder mucosa and abdominal skin, and mobilisation of bladder plate was achieved. Both the ureteric orifices were catheterised using 6 number feeding tubes. A left rectus abdominis island flap containing rectus muscle, posterior rectus sheath and peritoneum was prepared based on inferior epigastric artery [Figure 2]. The size of flap varied from 8 × 5 to 12 × 8 cm depending upon the size of the existing bladder plate. This flap was rotated to cover the bladder defect and peritoneum was sutured with the edges of bladder defect [Figure 3]. The fascia and rectus muscle was sutured with

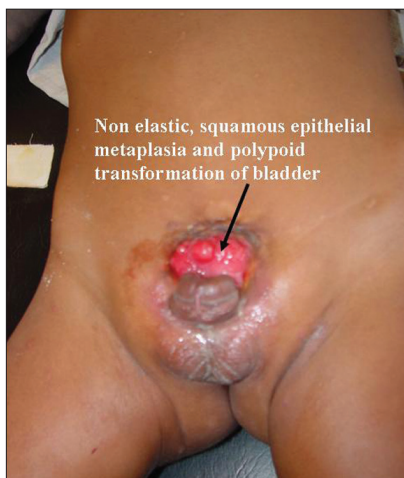

Figure 1: Preoperative photo showing non-elastic, squamous epithelial metaplasia and polypoid transformation of bladder

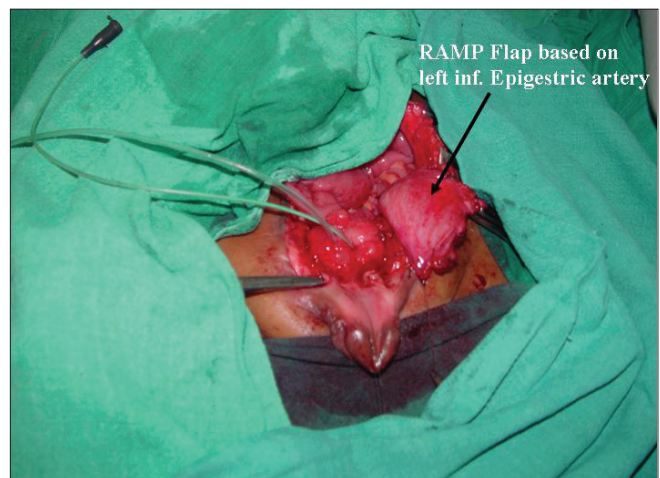


Figure 2: RAMP flap based on left inferior epigastric artery raised

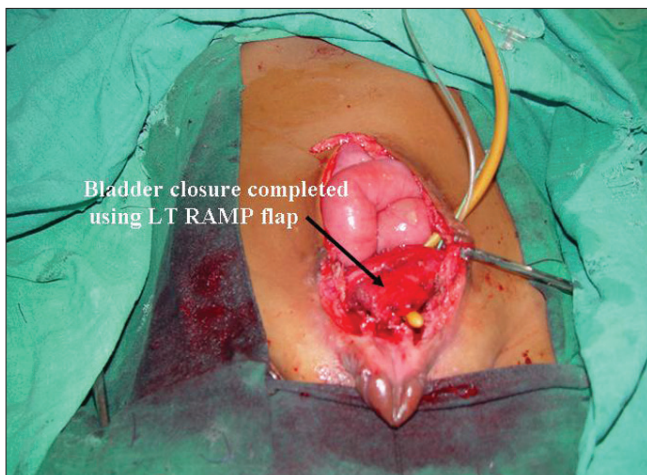


Figure 3: Bladder closure completed using LT RAMP flap

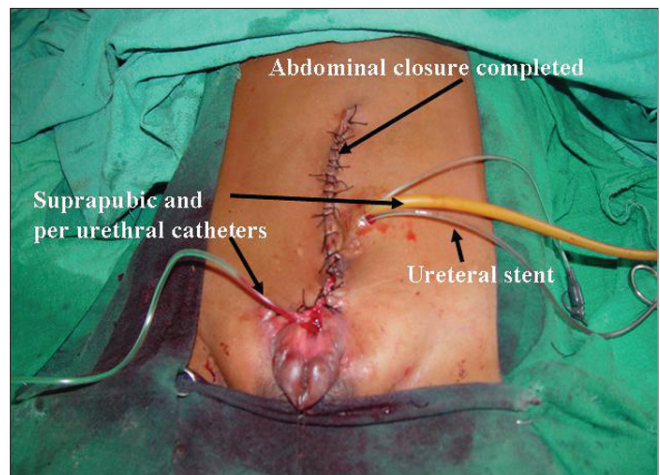


Figure 4: Abdominal closure completed

sero-muscular layer of bladder. Bladder was drained using a 10 number Foleys catheter per urethral. A suprapubic catheter was also kept. Peritoneum was left open and anterior rectus sheath and abdomen was closed with 3-0 nylon [Figure 4]. No iliac osteotomy was performed in any of the cases. Epispadias was not repaired, but bladder neck tightening was performed in all cases using the remains of muscle fibres around the bladder neck. Postoperatively, urethral, ureteric and suprapubic intravesical catheters were removed on 7th, 10th and 14th day. Urine analysis was done and serum creatinine and electrolyte levels were measured on 7th day. Intravenous pyelography (IVP) and micturating cysto-urethrography (MCU) and bladder volume measurement by ultrasound was done at 6 weeks and cystoscopy was performed at 2 months postoperatively.

RESULTS

Abdominal wall and bladder closure was achieved in all patients without any complications like wound dehiscence or hernia. Postoperatively, there were no urinary tract infections or electrolyte disturbances and the kidney function remained normal in all patients. IVP confirmed intact function and anatomy of the upper urinary tract and normal shape of the bladder. MCU showed grade II reflux with mild dilatation of upper tract in one patient. Ultrasound at 6 weeks showed adequate bladder capacity ranging from 120 to 230 ml [Table 1]. Cystoscopy, performed 2 months postoperatively, revealed no mucous production, no stone formation and the inner peritoneal layer completely replaced by transitional bladder epithelium. These patients were followed up for an average 3 years and their voiding pattern was determined by direct observation and parental information. None of the patients required intermittent catheterisation, and these patients remained dry for 4 hours but occasionally wetted at night. According to the Gearhart continence scale,^[4] all the three patients were in group 3 (dry for more than 3 hours during day and occasionally wet at night).

Table 1: Patient's details

S no	Age (years)	Sex	Surface area of exstrophic bladder (cm ²)	Size of RAMP flap (cm)	Volume of neobladder (ml) at 1 year
1	6	Male	10	8 × 5	120
2	8	Male	16	10 × 6	150
3	14	Male	24	12 × 8	230

DISCUSSION

Augmenting the bladder is a widely used method in children with exstrophy. It is an invaluable tool for protection of upper urinary tract and achievement of urinary continence. However, it remains a major surgical undertaking with significant morbidity. Vesical augmentation may be accomplished by using small bowel, large bowel or stomach, and by detrusor myotomy technique.^[5] The use of intestinal segments is associated with variable mucous production, electrolyte absorption and the risk of malignant transformation.^[6] Bladder myomectomy is resection of a part of bladder muscle with preservation of bladder mucosa to achieve bladder expansion, called auto-augmentation.^[7] The resultant bladder diverticulum might give a significant improvement in compliance and capacity. But it may be associated with complications like perforation, rupture, fibrosis and adhesion, leading to restriction in capacity of bladder. Another technique which eliminates some of these complications of auto-augmentation involves protecting the bladder mucosa with rectus muscle.^[8] Bladder augmentation using ureteral patch can be used only in cases of associated ureteral dilatation, and in most cases, it is inadequate.^[9]

Bladder augmentation using musculo-epithelial flap was tried in many experimental studies. All these studies indicate that the RAMP technique is a suitable alternative for the management of large bladder defects and bladder exstrophies.^[10,11]

Pien *et al.* compared the histological differences between a rectus abdominis muscle flap and a musculo-peritoneal flap, used as a urinary bladder wall substitute in 24 Wistar albino rats. They concluded that urothelium or peritoneum lining is not needed to protect a muscle flap against contact with urine. Histologically, the presence of peritoneum in the early postoperative period had a positive effect on the quality of neo-urothelium.^[12]

Wu Chih-Wei *et al.* managed post-traumatic defect of urinary bladder using the pedicled vastus lateralis myocutaneous flap. They concluded that it as an ideal option for post-traumatic bladder reconstruction and soft tissue coverage of the lower abdomen or perineum.^[13]

In this study, we have used the inferiorly based island RAMP for bladder augmentation. The idea is to reduce

the complications after augmentation technique. The advantages of this technique include no major operation on GI tract, no electrolyte abnormalities, urosepsis, or excessive mucous production and reduced chances of bladder diverticulum formation and no risk of malignancy.^[14] Augmented bladder contains well-vascularised, elastic and contractile tissue which is capable of further expansion. Additionally, secondary surgical procedures like ureteric reimplantation for reflux are possible through the flap without compromising its blood supply. For major augmentation procedure, bilateral flaps can be used. This technique is easy to perform, and rapid with a low complication rate. Tension-free bladder closure is achieved without osteotomy. Peritoneum of flap serves as a template for urothelial regeneration which was observed on cystoscopy. RAMP technique can also be used for closure of large bladder defects, failed primary closures and in cases of major bladder excision due to malignant tumours.

CONCLUSIONS

This pilot study highlights that the RAMP technique is a good alternative for closure of bladder exstrophies with small, inelastic, non-compliant bladder remnants. This is a very simple, reproducible technique which gives acceptable bladder capacity. More clinical studies with more patients are required to establish this technique for bladder exstrophy.

REFERENCES

1. Rickham PP. The Incidence and Treatment of Ectopia Vesicæ [Abridged] Proc R Soc Med 1961;54:389-92.
2. Buyukunal SN, Kaner G, Celayir S. An alternative treatment modality in closing bladder exstrophy: Use of rectus abdominis muscle flap--preliminary results in a rat model. J Pediatr Surg 1989;24:586-9.
3. Kilic N, Celayir S, Elicevik M, Sarimurat N, Soylet Y, Buyukunal C, *et al*. Bladder augmentation: Urodynamic findings and clinical outcome in different augmentation techniques. Eur J Pediatr Surg 1999;9:29-32.
4. Gearhart JP. Bladder and urechal abnormalities: The exstrophy-epispadias complex. In: Clinical pediatric urology. 3rd ed. Kelalis PP, King LR, Belman AB, editors. Vol. 1, Chapt. 15. Philadelphia: WB Saunders Co; 1992. p. 579-619.
5. Sanni-Bankole R, Masson J, Di Benedetto V, Coquet M, Monfort G. Gastrocystoplasty in the treatment of bladder exstrophy. Eur J Pediatr Surg 1995;5:342-7.
6. Pinter AB, Vajda P, Juhasz Z. Bladder augmentation in childhood: Metabolic consequences and surgical complications – review and own investigations. J Pediatr Surg Spec 2008;2:62-7.
7. Perovic SV, Djordjevic ML, Kekic ZK, Vukadinovic VM. Bladder autoaugmentation with rectus muscle backing. J Urol 2002;168:1877-80.
8. Erol A, Ozgur S, Erol U, Ozgur F, Akman Y, Ozguven V, *et al*. Partial bladder reconstruction with pedicled rectus and gracilis muscle flaps: An experimental study in dogs. Br J Urol 1994;74:775-8.
9. Bellinger MF. Ureterocystoplasty: A unique method for vesical augmentation in children. J Urol 1993; 149:811-3.
10. Celayir S, Kilic N, Dervisoglu S, Buyukunal C. Rectus abdominis muscle flap technique for the management of large bladder defects: Urodynamic findings in a rabbit model. Br J Urol 1996; 78:294-7.
11. Sadove RC, Rodgers JB, Fink BF, McRoberts JW. Experimental rectus abdominis myocutaneous and rectus abdominis myoperitoneal flaps as urinary bladder wall substitutes in miniature swine. Plast Reconstr Surg 1993; 91:511-21.
12. Pien SA, Schwencke-König J, Hage J, Kon M. Comparison of rectus abdominis muscle and musculo-peritoneal flap in closure of urinary bladder defects in a rat model. Eur J Plast Surg 2004; 27:233-7.
13. Wu CW, Lin CH, Lin CH. One-stage posttraumatic bladder reconstruction and soft-tissue coverage of the lower abdomen or perineum. Ann Plast Surg 2010; 64:65-8.
14. Buyukunal SN. Interim report in humans of a previously described technique in an animal model: Closure of bladder exstrophy with rectus abdominis muscle flap-II. J Urol 1994; 152:706-9.

How to cite this article: Agarwal P. Closure and augmentation of bladder exstrophy using rectus abdominis musculo-peritoneal flap. Indian J Plast Surg 2011;44:444-7.

Source of Support: Nil, **Conflict of Interest:** None declared.

Announcement

Android App



Download
**Android
application**

FREE

A free application to browse and search the journal's content is now available for Android based mobiles and devices. The application provides "Table of Contents" of the latest issues, which are stored on the device for future offline browsing. Internet connection is required to access the back issues and search facility. The application is compatible with all the versions of Android. The application can be downloaded from <https://market.android.com/details?id=comm.app.medknow>. For suggestions and comments do write back to us.