

Original Article

Anatomical study of superficial fascia and localized fat deposits of abdomen

Pramod Kumar, Arvind K. Pandey¹, Brijesh Kumar¹, Shrinivas K. Aithal²

Departments of Plastic Surgery and Burns, ¹Anatomy, Kasturba Medical College, ²Physics, Manipal Institute of Tehnology, Manipal University, Manipal, Karnataka, India

Address for correspondence: Dr. Pramod Kumar, Department of Plastic Surgery and Burns, Kasturba Medical College, Manipal - 576 104, Manipal University, Karnataka, India. E-mail: pkumar86@hotmail.com

ABSTRACT

Background: The development of liposuction and abdominoplasty has renewed interest in the anatomy of the localized fat deposits (LFD) areas of the abdomen. This study aims at ascertaining the gross anatomy of superficial fascia and the localized fat deposits of abdomen. **Materials and Methods:** Eight adult cadavers (four males and four females) were dissected. Attachments, number of layers of fascia and colour, shape and maximum size of the fat lobules in loin, and upper and lower abdomen were noted. Thickness of deep membranous layer of superficial fascia of upper abdomen and lower abdomen were measured by metal casing electronic digital calipers, with resolution being 10 μ m. The independent sample *t*-test, ANOVA for comparison and Pearson coefficient for correlation were used. **Results:** Superficial fascia of the abdomen was multilayered in the midline and number of layers reduced laterally. The shape, size, color, and arrangement of fat lobules were different in different locations. The thickness of the fascia of the lower abdomen in males (mean 528.336 \pm SE38.48) was significantly ($P < 0.041$) more than that in females. (Mean 390.822 \pm SE36.24). Pearson correlation between thickness of the membranous layer of the upper and lower abdomen revealed moderately positive correlation ($r = 0.718$; $P < 0.045$). **Conclusions:** The LFD in the central region of the abdomen corresponds to the area of multilayered fascia with smaller fat lobules. The relatively thinner supporting fascia of the lower abdomen in females may be responsible for excessive bulges of the lower abdomen. The fat lobule anatomy at different sites under study was different.

KEY WORDS

Abdominal obesity; localized fat deposits; superficial fascia abdomen

INTRODUCTION

Certain localized fat deposits (eg, loin) over abdomen are difficult to lose. This difference appears to be due to location and anatomy of the fat and fascia.

The superficial fat lies just below the skin between the skin and superficial fascia. There has been considerable controversies in the existing literature with respect to the number of layers/subdivision and attachments of superficial fascia of the abdomen.^[1-15] Also, there are controversies about the terminology; the same term is used in different ways at different places.^[9,16] Various authors^[1-5] suggest that the superficial fascia differentiates into two layers (superficial and deep layer) in the lower part of the abdomen. Contrary to them, Last's anatomy text book^[8] describes the differentiation of these layers in the lower part of the thoracic wall in front of midaxillary lines.

Access this article online	
Quick Response Code: 	Website: www.ijps.org
	DOI: 10.4103/0970-0358.90828

Deep fat lies between the superficial fascia and deeper muscular fascia or muscle. The upper extent of deep fat is up to an imaginary line extending from one iliac crest to another passing through the umbilicus. As compared to superficial fat, deep fat is extremely difficult to lose.^[14]

Since the development of liposuction and abdominoplasty, a renewed interest in anatomy of localized fat deposit (LFD) areas has appeared in the plastic surgical literature.^[9,10,17-20] This study was undertaken to understand facts related to the controversies and doubts related to the gross anatomy of superficial fascia of the abdomen and to study the gross anatomy of LFDs of the abdomen.

MATERIALS AND METHODS

Cadaver dissection

Eight formalin-fixed adult cadavers of South Indian origin (four males and four females) with mean height 158.5 cm (range 150–161 cm), mean waist circumference (at the level of anterior superior spine) 74.5 cm (range 60–81 cm) and mean chest circumference (at the level of xiphoid) 75 cm (range 61.5–81 cm) were studied.

Three vertical and two horizontal lines [Figures 1a and b] were drawn over the trunk, then along these lines 2 cm wide skin strip along with fascia and fat (up to the muscles) were removed to study the anatomy of the fascia and subcutaneous fat.

Vertical incisions

1. *Vertical incision at the midclavicular line:* Incision extending from the inframammary line to 1 cm below the inguinal ligament was made [Incision aa' in Figure 1a].

2. *Vertical paramedian incision between the midclavicular line and the midline of the abdomen:* Incision extending from the inframammary line to 1 cm below the inguinal ligament was made [Incision bb' in Figure 1a].
3. *Vertical line over the loin:* Incision extending from the point between the lower angle of scapula and the posterior axillary line to the posterior superior iliac spine was made [Incision cc' in Figure 1b].

Horizontal incisions

1. Transverse incision at the level of umbilicus, starting from umbilicus to posterior midline [incision dd' in Figure 1a and d'd'' in Figure 1b].
2. Transverse incision from an anterior superior iliac spine to the anterior midline [incision ee' in Figure 1a].

Data collection

The following points regarding superficial fascia were recorded.

1. Superior attachment
2. Inferior attachment
3. Lateral attachment
4. Medial attachment
5. Number of layers of superficial fascia in different part of the abdomen.

The size, shape, arrangement, and color of the subcutaneous fat were recorded.

Measurement of the thickness of fascia

The fascia was multilayered in the midline. The thickness of the deepest layer of superficial fascia was measured 3 cm above and 3 cm below the umbilicus in the region

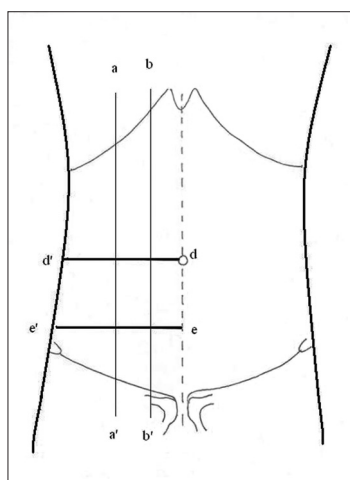


Figure 1a: Incisions over front of the trunk: Vertical incisions aa' and bb' and horizontal incisions dd' and ee'

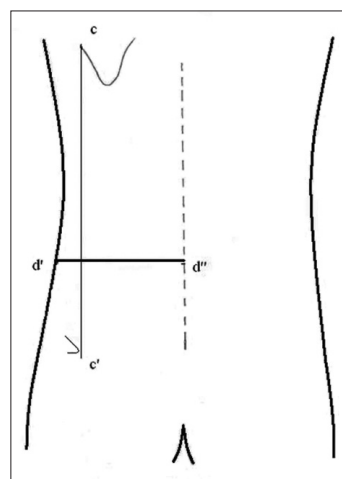


Figure 1b: Incisions over the back of the trunk. Vertical incisions cc' and horizontal incisions d'd'' as a continuation of incision dd' on the front side of the trunk

of the midclavicular line using Metal Casing Electronic Digital Calipers (series-sc02, Guilin Gunglv measuring instrument Co. Ltd, Guilin, China); resolution 10 μm.

Recorded data were analyzed using SPSS version 11.5. Data were expressed as mean and standard error of the mean (SE). The independent sample *t*-test was used to determine the significance of differences between mean thicknesses of two groups of measurement. One-way analysis of variance (ANOVA) was used for the comparison of several groups of mean thickness measurement (*P* value < 0.05 was considered statistically significant).

OBSERVATIONS AND RESULTS

Superficial fascia of the abdomen had four attachments [Table 1 and Figure 2]. It was multilayered (three to seven layers) in the midline and number of layers reduced laterally due to gradual merging with each other. The color, shape, size, and arrangement of fat lobules were different at different locations [Figure 2a and Table 2].

The thickness of the deepest layer of superficial fascia [Tables 3 and 4] was more in the lower abdomen as compared to that in the upper abdomen. The thickness of fascia in the upper abdomen in males (mean 364.165 ± SE22.49) was more than that in females (mean 315.822 ± SE56.93) but it was statistically not significant (*P* < 0.46) [Figure 3]. The thickness of the fascia of the lower abdomen in males (mean 528.336 ± SE38.48) was significantly (*P* < 0.041) more than that in females (mean 390.822 ± SE36.24) [Figure 3].

Pearson correlation between thickness (μm) of the upper and lower abdominal fascia revealed significant (two-tailed) moderately positive correlation (*r* = 0.718; *P* < 0.045) [Figure 4].

DISCUSSION

A study of the anatomy of the superficial fascia in fresh and embalmed cadavers, cross-sectional cadaver segments, and patients with body contour deformities was conducted by Lockwood.^[10] He found that superficial fascia consists of one to several thin, horizontal membranous sheets separated by varying amount of fat with interconnecting vertical or oblique fibrous septae. Other authors have also described the superficial fascia to be one layered,^[11-13,15] two layered,^[1-9] three layered,^[14] or even more.^[10,21]

Table 1: Attachments of fascia

Attachment of fascia	Description	Number of cadavers
Upper attachment	1. Line extending from a point over costal margin between the anterior axillary and midclavicular line to 2 cm below umbilicus.	Seven cadavers (Three male + four female)
	2. Line extending from a point over the costal margin between anterior axillary and midclavicular line to midpoint between umbilicus and pubic symphysis.	One male cadavers
Lower attachment	Medially multilayered fascia crossed symphysis and the medial part of the inguinal ligament and condensed over the fascia lata and few upper layer merged with superficial fascia of the thigh. In midinguinal region two layers of fascia after crossing the inguinal ligament merged with fascia lata and superficial fascia of the thigh.	Eight cadavers (four male + four female)
Medial attachment	Multi layered fascia in midline fuses with other side corresponding fascia and relatively thick deeper layer along with opposite side corresponding fascia merged to the abdominal wall in midline	Eight cadavers (Four male + four female)
Lateral attachment	Multilayered fascia started fusing with each other one by one laterally till it became three distinct layers near midaxillary line and then reduced to two layers just before merging with the abdominal wall between the midaxillary and anterior axillary line.	Eight cadavers (four male + four female)

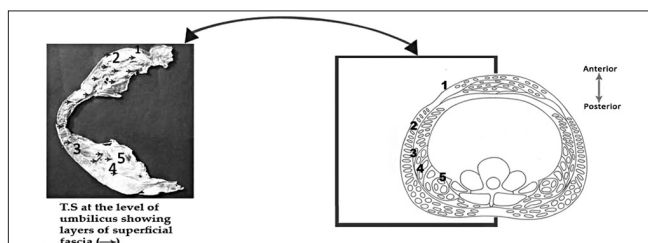


Figure 2a: Line diagram showing details of the layers of superficial fascia of abdomen and its relation to subcutaneous fat lobules. Cross-sectional anatomy at the level of umbilicus, 1. skin, 2. superficial fat, 3. superficial layer of superficial fascia, 4. deep fat, 5. deepest layer of superficial fascia

In this study, we found that superficial fascia of the abdomen was multilayered in the midline and number of

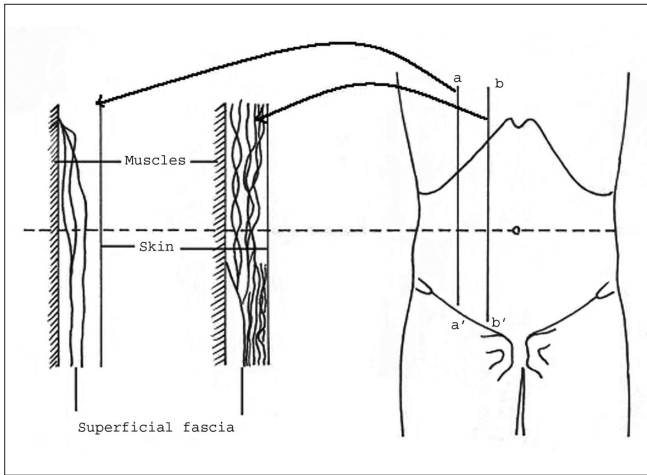


Figure 2b: Line diagram showing details of the layers of superficial fascia of abdomen and its relation to subcutaneous fat lobules. Layers of fascia at vertical midclavicular (line a-a') and paramedian (line b-b') line

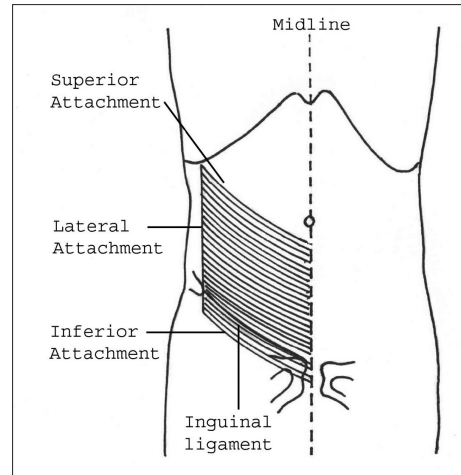


Figure 2c: Line diagram showing details of the layers of superficial fascia of abdomen and its relation to subcutaneous fat lobules. Front view showing attachments of fascia (refer the text for details)

Table 2: Subcutaneous fat observation

Region	Shape and arrangement of the fat lobule	Size of fat lobules	Color of fat
Upper abdomen	Superficial layer of lobules were elongated and arrange perpendicular to skin. Deeper layer of lobules were rounded in the shape.	Max size 0.2 cm × 0.5 cm	Dark yellowish in color
Lower abdomen	Lobules were elongated and arranged perpendicular to skin. Most dependant lobules were larger in size.	Max size 0.5 cm × 2 cm	Yellowish in color. Deeper fat lobules were comparatively pallor
Loin fat	Fat superficial to deep fascia: Fattened elongated fat lobules arranged parallel to skin posteriorly. In the posterior axillary line gradually fat lobules become rounded From posterior axillary line to the anterior abdomen arrangement progressively becomes vertical perpendicular to skin. Fat deep to deeper fascia: Fat lobule arrangement was in eccentric fashion around few large round lobules that were placed relatively in the deeper layer. Towards periphery fat lobules were progressively flatter and smaller. Deeper most lobule layer contained smallest fat lobules.	Max size 0.2 cm × 0.5 cm Max diameter of lobules 1 cm	Superficial fat was yellowish in color. Deeper layer of lobules were pallor. Yellowish

Table 3: Comparison of deepest layer of superficial fascia thickness (µm) of the upper abdomen in males and females

Statistical data	Male	Female
Mean thickness	364.165	315.822
Range	310–420	173.33–436.66
SE	22.49	56.93
95% CI for mean	292.56–435.79	134.63–497.01
P value	0.46	

Table 4: Comparison of the deepest layer of superficial fascia thickness (µm) of the lower abdomen in males and females

Statistical data	Male	Female
Mean thickness	528.336	390.822
Range	440–616.66	296.66–473.33
SE	38.78	36.24
95% CI for mean	404.88–651.77	275.47–506.17
P value	0.041	

layers reduced laterally as various layers gradually merged with each other [Figure 2]. Hence, the controversies [1-16,21] regarding number of the layers of the superficial fascia may be the representation of number of layers at their dissection sites.

Thickness of the deepest layer of superficial fascia showed difference in the upper and lower abdomen. The mean thickness of the fascia of the lower abdomen was more than the upper abdomen though it was statistically not significant. Mean thickness of fascia of both the lower and

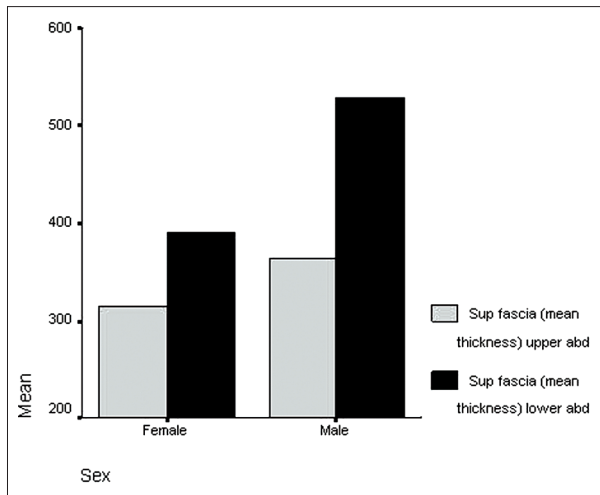


Figure 3: Line diagram showing comparison of the mean thickness (μm) of deepest layer of superficial fascia of the upper abdomen and lower abdomen in males and females

upper abdomen was higher in males than females. Pearson correlation sig. (two-tailed) shows moderate positive correlation ($r=0.718$; $P<0.045$) between thickness of the fascia of the upper and lower abdomen. Literature review^[9,10,14] reveals that the superficial fascia is the supporting structure for subcutaneous fat of the abdomen and lower abdominal obesity is more common in female.^[20] The excessive bulges and lower abdomen obesity in females could be explained due to relatively thinner supporting fascia of the lower abdomen (this study).

We found size of the fat lobules of the lower abdomen was larger than the upper abdomen [Table 2]. Similar findings were reported by Yves Illouz.^[14]

Illouz has^[14] described the resistant nature (to absorption) of the loin LFD. This study reveals that anatomy of fat lobules and its arrangement was markedly different than other areas of the abdomen. Our study revealed triangular-shaped fat deposit in this resistant loin area [Figure 2a and Table 2] with the larger lobules placed in the relatively deeper layer. The size and arrangement of fat lobules in this area was distinctly different from other areas of the abdomen that has less resistant fat deposits. We could not find detailed anatomy of the loin fat in the available literature for comparison.

The common presentation of LFD in the central region of the abdomen is less resistant to absorption as compared to loin LFD, and shows strong correlation with cardiovascular disease.^[22] Our study shows that this area corresponds to the area of multilayered fascia with smaller fat lobules [Figure 2a].

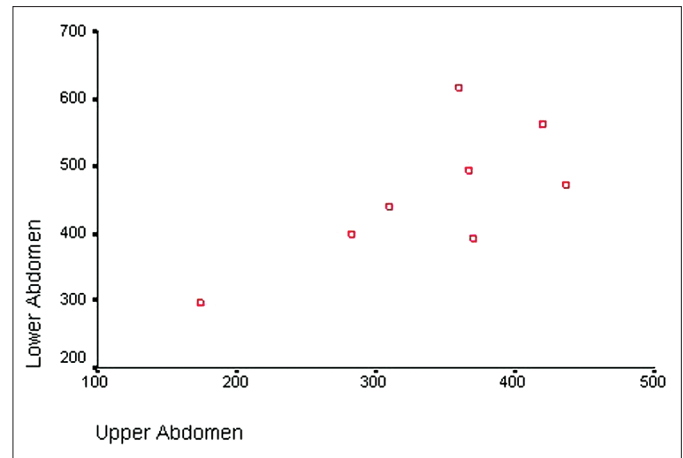


Figure 4: Scatter plot showing significant positive correlation between thicknesses (μm) of the deepest layer of superficial fascia of the upper and lower abdomen (Pearson correlation $r=0.718$; $P<0.045$)

Limitations of the study

This study was performed in formalin fixed cadavers that was available to us during our study; hence, actual measurements may differ in living population. This is particularly relevant when involving measurement of the size of fat lobules that may be affected by fixation with formalin. Hence, further study using fresh cadavers will probably give a different set of measurements.

Future scope

This study was done on the preserved cadavers due to nonavailability of fresh cadavers to the authors. The study gives a lead to further work on different shapes of fat lobules in different parts of the abdominal wall. The study on fresh cadavers and comparison with this study and correlation between obesity, vascularity, and sex viz a viz shapes of lobules may be interesting.

REFERENCES

1. Borley NR. Anterior abdominal wall. In: Standring S, editor. Gray's anatomy. The anatomical basis of clinical practice. 40th ed. Philadelphia: Churchill Livingstone; 2008. p. 1060.
2. Moore KL, Dalley AF, editors. Clinically oriented anatomy. 5th ed. Philadelphia: Lippincott, Williams and Wilkins; 2006. p. 196-8.
3. Romanes GJ, editor. Cunningham's text book of anatomy. 12th ed. Oxford: Oxford University Press; 1981. p. 275.
4. Basmajian JV, editor. Grant's method of anatomy. 10th ed. Baltimore: Willams and Wilkins; 1980. p. 123.
5. Hall-Craggs EC, editors. Anatomy as a basis for clinical medicine. 2nd ed. Baltimore-Munich: Urban and Schwarzenberg; 1990. p. 225.
6. Hollinshed WH, Rosse C, editors. Text book of Anatomy. 4th ed. Philadelphia: Harper and Row; 1985. p. 581.
7. Snell RS, editor. Clinical anatomy for medical students. 5th ed. Boston: Little, Brown and Co.; 1995. p. 136.
8. Sinnatamby CS, editor. Last's anatomy, regional and applied. 11th ed. Edinburgh: Churchill Livingstone; 2006. p. 185.
9. Abu-Hijesh MF, Roushier AL. The membranous layer of

- superficial fascia: Evidence for its widespread of the body. *Surg Radiol Anat* 2006;28:606-19.
10. Lockwood TE. Superficial fascial system (SFS) of the trunk and extremities: A new concept. *Plastic Reconstr Surg* 1991;87:1009-18.
 11. Forster DS. A note on scarpa's fascia. *J Anat* 1937;72:130.
 12. Howell AB. Anatomy of the inguinal region. *Surgery* 1939;6:653.
 13. Tobin CE, Benjamin JA. Anatomical and clinical re-evaluation of Camper's, Scarpa's and Colles's fasciae. *Surg Gynecol Obstet* 1949;88:545-59.
 14. Yves Illouz, editor. *Body Sculpturing by lipoplasty*. Edinburgh: Churchill Livingstone; 1989.
 15. Markman B, Barton FE Jr. Anatomy of the subcutaneous tissue of the trunk and lower extremity. *Plast Reconstr Surg* 1987;80:248-54.
 16. Wendell-Smith CP. Fascia: An illustrative problem in international terminology. *Surg Radiol Anat* 1997;19:273-7.
 17. Bjorntorp P. Adipose tissue distribution and function. *Int J Obes* 1991;15 Suppl 2:67-81.
 18. Fried SK, Kral JG. Sex differences in regional distribution of fat cell size and lipoprotein lipase activity in morbidly obese patients. *Int J Obes* 1987;11:129-40.
 19. Avelar J. Regional distribution and behavior of the subcutaneous tissue concerning selection and indication for liposuction. *Aesthetic Plast Surg* 1989;13:155-65.
 20. Champe PC, Harvey RA, editors. *Lippincott's Illustrated Reviews: Biochemistry*. 4th ed. Philadelphia: Lippincott William and Wilkins; 2008. p. 350.
 21. Wigley Caroline. Cells, tissue and systems. In: Standring S editor. *Gray's anatomy. The anatomical basis of clinical practice*. 40th ed. Philadelphia: Churchill Livingstone; 2008. p. 39-40.
 22. Rosengren A, Howken S, Ounpuu S, Sliwa K, Zubaid M, Almahameed WA, *et al.* Effect of Potentially modifiable risk factors associated with Myocardial Infarction in 52 countries. *Lancet* 2004;364:937-52.

How to cite this article: Kumar P, Pandey AK, Kumar B, Aithal SK. Anatomical study of superficial fascia and localized fat deposits of abdomen. *Indian J Plast Surg* 2011;44:478-83.

Source of Support: Nil, **Conflict of Interest:** None declared.