

Case Report

Paediatric Dupuytren's disease

Pradeoth Mukundan Korambayil, Anto Francis Padikala

Consultant Plastic Surgeon, Sushrutha Institute of Plastic Reconstructive and Aesthetic Surgery, Elite Mission Hospital, Thrissur, Kerala, India

Address for correspondence: Dr. Pradeoth M. Korambayil, Consultant Plastic Surgeon, Sushrutha Institute of Plastic Reconstructive and Aesthetic Surgery, Elite Mission Hospital, Koorkenchery, Thrissur – 680 007, Kerala, India. E-mail: Pradeoth@gmail.com

ABSTRACT

Dupuytren's disease of the hand has only been rarely reported in children and is rarer still in infants. Only a few histologically confirmed diagnoses are found in literature. We report a case in a 4-month-old infant with Dupuytren's disease of palm and thumb who required surgery at 6 months of age. Histology confirmed the diagnosis of Dupuytren's disease. The purpose of this report is to show the importance of differential diagnosis of nodules and fibrotic bands in children's hands as paediatric patients may be seen by a variety of treating physicians, not only plastic surgeons or pathologists.

KEY WORDS

Dupuytren's disease, palm nodule, infant, thumb

INTRODUCTION

Dupuytren's disease commonly affects men over the age of 40 years. It is very rare to find it in the paediatric age group. A 14-year-old boy with flexion contractures of the ring and little fingers with a similar affection in the plantar fascia was the first reported case of histologically proven Dupuytren's disease in a child.^[1] Urban *et al.*,^[2] in their study on nine cases, proved eight cases of Dupuytren's disease histologically. The youngest case in this study was 9 years of age. Only two cases of Dupuytren's occurring in an infant have been reported.^[3] One was in a 10-month-old boy with a flexion deformity of the distal interphalangeal joint progressively involving proximal interphalangeal joint. The surgery was performed at 18 months of age

and histology of the excised tissue showed features of Dupuytren's disease. The other was a 6-month-old child, with Dupuytren's disease involving the ring finger.^[4] We report a case of histologically proven Dupuytren's in a 4-month-old male child.

CASE REPORT

A 4-month-old male child was referred with a swelling in the left palm and an associated palmar cord to the thumb. There was no family history of Dupuytren's disease. Examination revealed a palpable plaque of tissue deep to the skin at the base of the thumb, with a cord extending distally to the radial side of the proximal phalanx. There were multiple shallow skin pits visible in the palm [Figure 1]. The thumb could not be extended passively. The features were thought to be similar to Dupuytren's in an adult. The child did not have any other associated features of fibromatosis in other sites. The boy was reviewed 2 months later and the disease was progressively increasing in intensity. The parents noticed a slight reluctance by the boy to use the thumb. The infant underwent an excision biopsy at 6 months of age.

Access this article online

Quick Response Code:



Website:

www.ijps.org

DOI:

10.4103/0970-0358.90846

An incision along the palmar crease was used in the palm and another incision onto the thumb [Figures 2 and 3]. The mass was excised [Figures 4–6]. It did not involve the digital nerves or the vessels. The excised mass was sent for histological examination which demonstrated hypercellular fibromatosis, typical of Dupuytren's disease [Figure 7]. There were no malignant changes. The hand was immobilised for 2 weeks and subsequently treated by mobilisation and an extension night splint.

DISCUSSION

Dupuytren's disease is a benign, progressive, fibro-proliferative, chronic disorder that results in abnormal scar-like tissue in the palmar fascia of the hand. Extension to the digits causes progressive digital flexion contractures. Limited fasciectomy and limited dermofasciectomy are the techniques mostly

used.^[5] Dupuytren's disease in children is a rare entity. In a review of 66 excised childhood fibrous tumours, only three proved to be palmar fibromatosis, but no further specific details were mentioned.^[6] One study identified 108 cases of fibromatosis in children in a 25-year period, from which there were only three cases of Dupuytren's disease.^[7] Several studies have, however, identified certain features in respect of the appearance of this disease in childhood.^[2,4,8,9]

Dupuytren's disease in infants is exceedingly rare. There are only three recorded histologically proven cases in children less than 9 years of age, of which only two were infants.^[4] Other causes of flexion contracture of the fingers include camptodactyly, burns, congenital ulnar drift^[10] and infantile digital fibromatosis.^[11,12]

Fibrous tissue tumours are more commonly reported

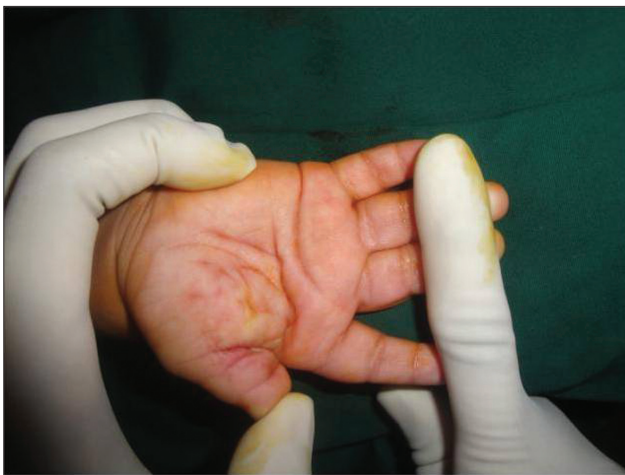

Figure 1: Preoperative picture showing pits over the thenar eminence

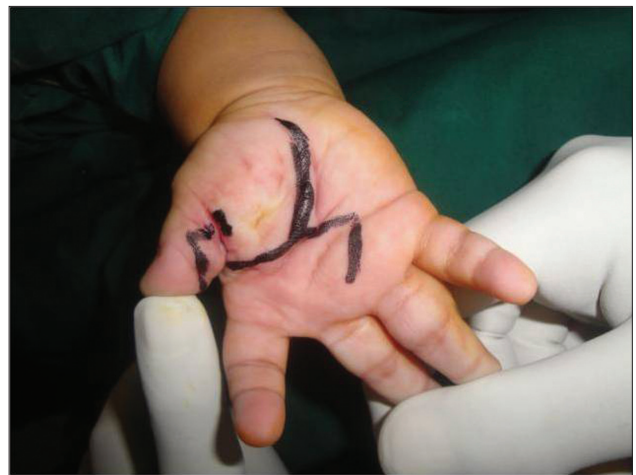

Figure 2: Plan of incision along the palmar crease

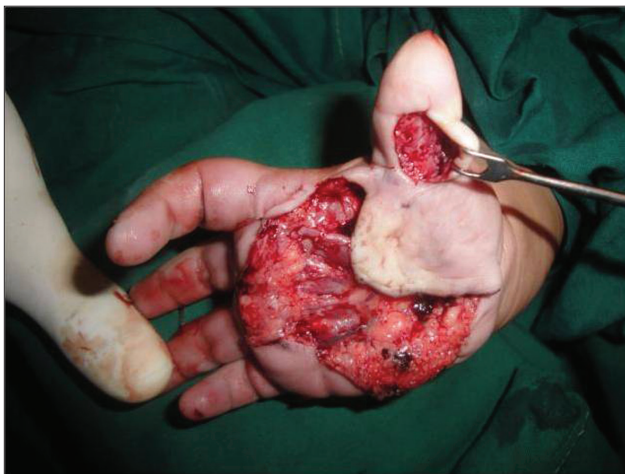


Figure 3: Incision over the thumb to release the interphalangeal and metacarpophalangeal joint

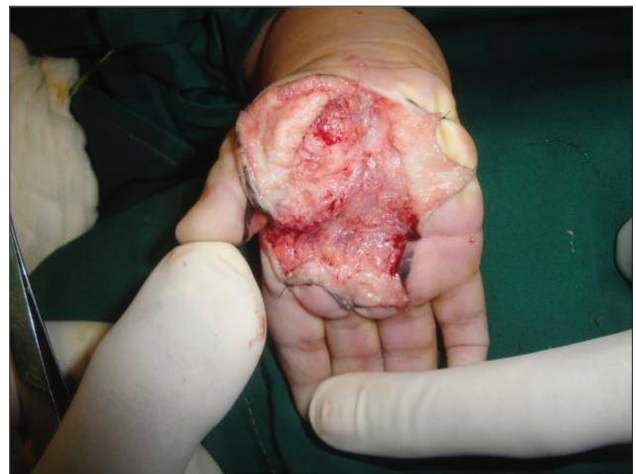

Figure 4: Picture showing the thickened palmar fascia

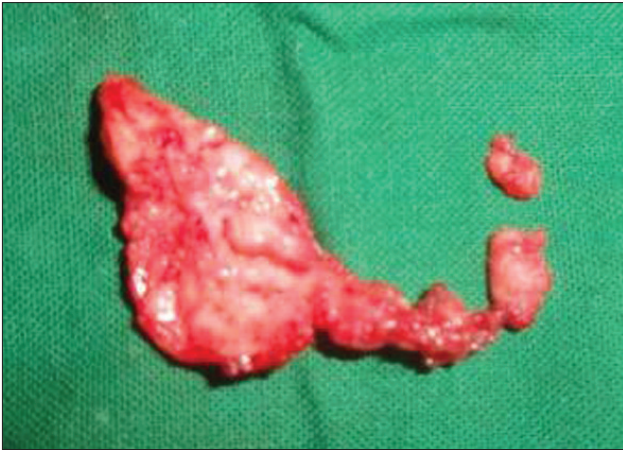


Figure 5: Picture showing the excised tissue

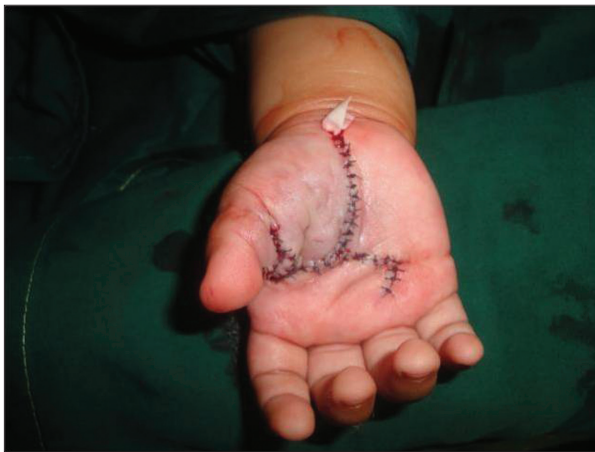

Figure 6: Immediate postoperative picture

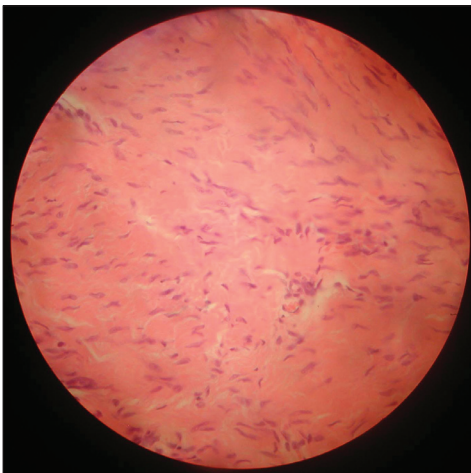


Figure 7: High-power view of the histology confirming fibrosis due to Dupuytren's disease

than other causes of contracture.^[3] A diagnosis of Dupuytren's disease is usually confirmed by histology. Differential diagnosis for Dupuytren's disease include extra-abdominal fibromatosis, calcifying aponeurotic

fibroma,^[12,13] infantile fibrosarcoma,^[12] fibroma of the tendon sheath,^[12,14] localised nodular tenosynovitis (giant cell tumour of the tendon sheath),^[12,15] fibrous hamartoma of infancy^[16] and infantile myofibromatosis.^[16]

Calcifying fibroma affects mainly children and adolescents and presents as a relatively small mass most often located in the palm.^[17,18] Histologically, more significant difference is the invariable presence of calcified foci surrounded by plumper cells.

Giant cell tumour of tendon sheath is more cellular and contains multiple multinucleated giant cells, foamy histiocytes, and haemosiderin.

Fibrous hamartoma of infancy usually occurs in the first 2 years of life and presents as a painless solitary nodule/plaque in the upper extremity. Histologically, finger-like projections of fibrous tissue extend into the fatty tissue, with small round to ovoid nests of undifferentiated spindle or stellate cells.

Infantile digital fibromatosis typically presents in the first year of life as a single, firm, pink or red nodule on the dorsum of the fingers or toes. These nodules have the characteristic histological appearance of eosinophilic inclusion bodies in the cell cytoplasm.^[11,12,19]

In its early, proliferative phase with many fibroblasts, Dupuytren's disease can resemble the early appearance of an epithelioid sarcoma.^[9] Tumour shows conspicuous inflammatory cell infiltrate composed of lymphocytes and histiocytes surrounding the tumour nodule with intercellular dense hyalinised collagen.

The aetiology of Dupuytren's disease is multifactorial. Aggressive dermofasciectomy is suggested to be the treatment of childhood Dupuytren's disease.^[2] In a study by Urban *et al.*,^[2] a 9-year-old boy was treated initially by fasciectomy, but required a dermofasciectomy for recurrence by 19 months of age. Other reported case in an infant was treated by fasciectomy and no recurrence was noted at 27 months' follow-up.^[3] We treated our case with fasciectomy. Timing for surgery for Dupuytren's disease in infancy has not yet been established. Currently, surgery remains the mainstay of treatment. Appropriate studies have not been performed on the relationship of age to the effects of steroid, collagenase and enzyme injection in the paediatric population. Safety and efficacy for these conservative measures have not been established.

CONCLUSIONS

Dupuytren's disease in infants is exceedingly rare, and diagnosis of Dupuytren's disease is usually confirmed by histology. This case is being reported to show the plethora of possibilities that can form the differential diagnosis of nodules and fibrotic bands in infant's hand, and in all this Dupuytren's disease, though rare, should not be forgotten.

REFERENCES

1. Goetsee AE, Williams HO. A case of Dupuytren's contracture involving the hand and foot in a child. *Br J Surg* 1954;42:417-20.
2. Urban M, Feldberg L, Janssen A, Elliot D. Dupuytren's disease in children. *J Hand Surg [Br]* 1996;21-B:112-6.
3. Foucher G, Lequeux C, Medina J, Navorro Garcia R, Nagel D. A congenital hand deformity: Dupuytren's disease. *J Hand Surg* 2000;26-A:515-7.
4. Bebbington A, Savage R. Dupuytren's disease in an infant. *J Bone Joint Surg* 2005;87B:111-3.
5. McFarlane R, McGrouther DA, Flint MH, editors. Dupuytren's Disease. Edinburgh: Churchill Livingstone; 1990.
6. Dehner LP, Askin FB. Tumours of fibrous tissue origin in childhood: A clinicopathologic study of cutaneous and soft tissue neoplasms in 66 children. *Cancer* 1975;38:888-900.
7. Cheryl M, Coffin MD, Dehner LP. Fibroblastic–myofibroblastic tumours in children and adolescents: A clinicopathological study of 108 examples in 103 patients. *Pediatr Pathol* 1991;11:559-88.
8. Mandalia VL, Lowdon IM. Dupuytren's disease in a child: A case report. *J Pediatr Orthop* 2003;12:198-9.
9. Rhomberg M, Rainer C, Gardetto A, Piza-Katzer H. Dupuytren's disease in children – differential diagnosis. *J Pediatr Surg* 2002;37:E7.
10. Zancolli EA, Zancolli ER. Congenital ulnar drift and camptodactyly produced by malformation of the retaining ligaments of the skin. *Bull Hosp Jt Dis Orthop Inst* 1984;44:558-76.
11. Reye RD. Recurring digital fibrous tumours of childhood. *Arch Pathol* 1965;80:228-31.
12. Chinyama CN, Roblin P, Watson SJ, Evans DM. Fibromatosis and related tumours of the hand in children: A clinicopathologic review. *Hand Clin* 2000;16:625-35.
13. Adeyemi-Doro HO, Olude O. Juvenile aponeurotic fibroma. *Br J Hand Surg* 1985;10:127-8.
14. Greene TL, Strickl JW. Fibroma of tendon sheath. *Am J Hand Surg* 1984;9:758-60.
15. Moore RJ, Weiland AJ, Curtis RM. Localized nodular tenosynovitis: Experience with 115 cases. *Am J Hand Surg* 1984;9-A:412-7.
16. Enzinger FM, Weiss SW. Fibrous tumours of infancy and childhood. In: Weiss SW, Goldblum JR, editors. *Enzinger and Weiss's soft tissue tumours*. 4th ed. St Louis: Mosby; 2001. p. 347-408.
17. Gengler C, Guillou L. Solitary fibrous tumour and haemangiopericytoma: Evolution of a concept. *Histopathology* 2006;48:63-74.
18. Young RH, Clement PB, McCaughey WT. Solitary fibrous tumors (fibrous mesotheliomas) of the peritoneum. A report of three cases and a review of the literature. *Arch Pathol Lab Med* 1990;114:493-5.
19. Moloney SR, Cabbabe EB, Shively RE, deMello DE. Recurring digital fibroma of childhood. *Am J Hand Surg* 1986;11:584-7.

How to cite this article: Korambayil PM, Padikala AF. Paediatric Dupuytren's disease. *Indian J Plast Surg* 2011;44:521-4.

Source of Support: Nil, **Conflict of Interest:** None declared.