

CASE REPORT

Missed Duodenal Web with Foreign Body Impaction in an Operated Case of Midgut Malrotation with Down's Syndrome – A Diagnosis delayed by Endoscopy

Krushnakumar Kesan, Abhaya Gupta, Rahul Kumar Gupta, Paras Kothari, Ritesh Ranjan, Parag Karkera, Kedar Mudkhedkar

Department of Pediatric Surgery, LTMMC & LTMGH, Sion, Mumbai, India

ABSTRACT

“Always look for duodenal obstruction in a case of malrotation”, this dictum has to be followed. The patient was operated for midgut malrotation at day 2 of life followed by foreign body removal by upper gastrointestinal endoscopy at 2 years of age. We report a two and half year male child with Down's syndrome who presented to us with history suggestive of recurrent upper gastrointestinal tract obstruction. During surgery a post sphincteric duodenum web was confirmed and foreign body (berry seed) which had impacted proximal to it was removed. The web was excised and the duodenum, split longitudinally, sutured transversely. The postoperative course was uneventful and patient is asymptomatic at follow up. This case illustrates that diagnosis was delayed for 2½ years after initial presentation in early neonatal age. (*Dig Endosc* 2013;4(1):10-12)

Key Words: Duodenal web – Foreign body – Midgut malrotation – Down's syndrome – Upper gastrointestinal endoscopy.

Introduction

Congenital duodenal obstruction (atresia or stenosis) is associated with various congenital anomalies.¹ Midgut malrotation is the most common association and refers to either lack of or incomplete rotation of the fetal intestines around the axis of the superior mesenteric artery during fetal development.^{2,3} Most patients present with bilious vomiting in the first month of life because of duodenal obstruction or a volvulus, but diagnosis of duodenal obstruction may be delayed in some of the cases especially in Down's syndrome.⁴⁻⁶ Patient usually presents with recurrent upper gastrointestinal tract obstruction due to congenital duodenal diaphragm which may be associated with foreign body impaction.⁷ We present a case of Down's syndrome and malrotation with features of obstruction and who was operated at age of 2 days. He continued to complain of recurrent vomiting suggestive of upper small intestinal obstruction and underwent removal of foreign body at upper gastrointestinal endoscopy at age of 2 years. In view of persistent symptoms of vomiting, he was discovered to

have duodenal web with impacted foreign body at age of 2½ years and underwent another surgery with success.

Case Report

A two and half year old male child presented to us with the complaint of vomiting which was bilious in nature, on and off since birth. Patient was operated for midgut malrotation at day 2 of life. Exploratory laparotomy with Ladd's procedure was done then. The patient had also undergone duodenal foreign body removal by upper gastrointestinal endoscopy at 2 years of age. On examination the child was found to be having features of Down's syndrome.

Reprints requests and correspondence:

Dr. Krushnakumar V Kesan, Registrar
Mch Pediatric Surgery, Department of Pediatric Surgery,
LTMMC and LTMG Hospital Sion, Mumbai, Maharashtra, INDIA
Tel: +91-8097964430
E-mail: krishnakesan@rediffmail.com

On per abdominal examination, distension of upper abdomen was present. There were no visible bowel loops.

Haematological and biochemical investigations were normal. X ray abdomen was normal (Figure 1). Ultrasonography abdomen revealed over distended stomach and 1st part of duodenum. Upper gastrointestinal contrast study done at the time of presentation to us revealed obstruction at second part of duodenum (Figure 2).

The patient underwent abdominal exploration and was found to have a massively dilated stomach and proximal duodenum. There was external narrowing just distal to second part of duodenum (Figure 3a). On opening the duodenum longitudinally, a foreign body (Berry seed) was evident which was removed (Figure 3b). A post sphincteric duodenal web was

present which was excised and the duodenum was sutured transversely (Figure 3c). There were no surgical complications and the patient made a full and uneventful recovery. The patient is asymptomatic at 6 months of follow-up.

Discussion

Duodenal obstruction is the result of atresia, stenosis, duodenal web and annular pancreas; commonly associated with incomplete intestinal rotation. Major associated anomalies are present in about 50% of cases. Approximately 25 - 30% of patients have Down's syndrome. Other anomalies include esophageal atresia, congenital heart disease, imperforate anus, small bowel atresia, biliary atresia, annular pancreas, and renal anomalies.

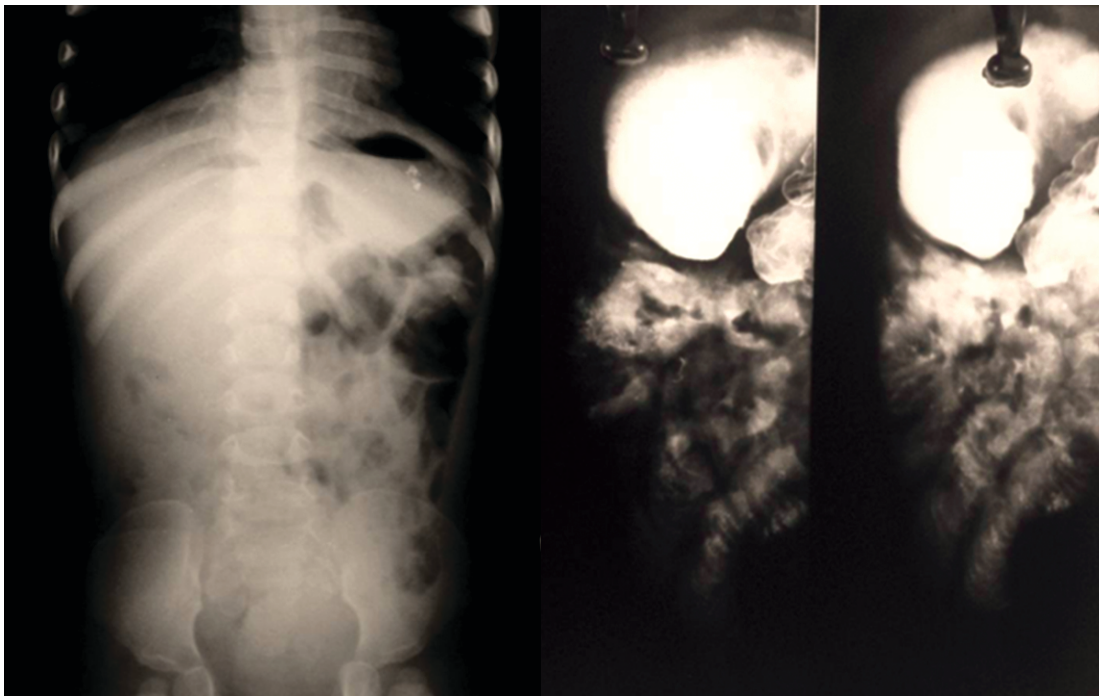


Figure 1: X ray abdomen PA view

Figure 2: Upper gastrointestinal contrast study done at presentation to us

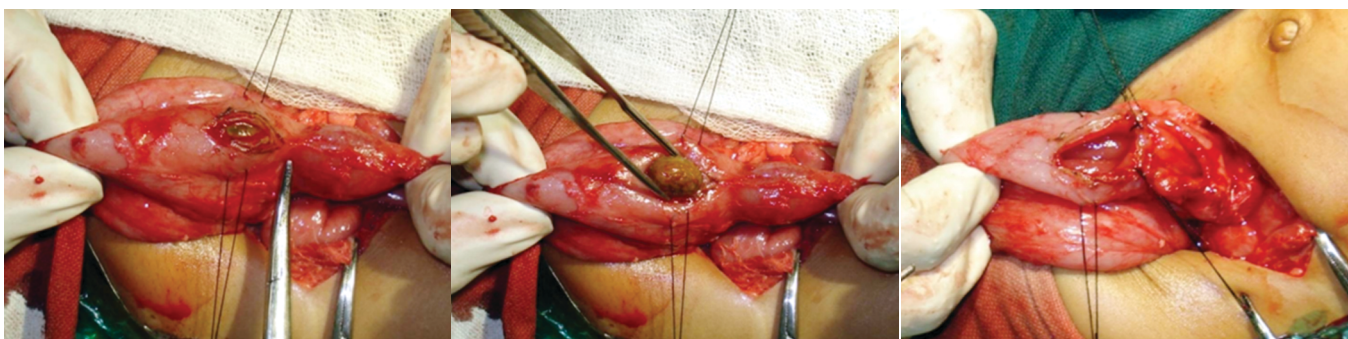


Figure 3a: External narrowing just distal to second part of duodenum

Figure 3b: On opening duodenum longitudinally foreign body (Berry seed) was evident

Figure 3c: Duodenal web

Partial duodenal obstruction may be produced by duodenal stenosis, duodenal web, Ladd bands and midgut volvulus. Chronic duodenal obstruction related to a congenital web is a rare anomaly that is sometimes difficult to diagnose preoperatively. A case of partial duodenal obstruction (secondary to congenital duodenal web) may present with recurrent upper gastrointestinal tract obstruction which may be associated with foreign body impaction.⁸

The pathogenesis of duodenal obstruction remains somewhat unclear. Early in fetal life the duodenum undergoes a proliferation which causes complete obliteration of the lumen in the 5th to 6th week of fetal life. This is followed by recanalization in the 8th to 10th week of fetal development. The lack of complete recanalization produces an atresia or stenosis.

The clinical presentation depends on the degree of atresia or stenosis that is present. The majority of obstructions are distal to the ampulla of Vater. Biliious vomiting without abdominal distention is the cardinal sign in the patient with a duodenal obstruction. High grade obstructions will obviously present within the first few days of life. Less severe obstructions may allow a child to go several months or even years prior to diagnosis. Diagnosis of duodenal obstruction is especially delayed in Down's syndrome. Symptoms such as vomiting and growth retardation might be ignored in a child with Down's syndrome.⁹

In our case duodenal web was associated with malrotation and Down's syndrome. Duodenal web was missed during the first surgery done in neonatal life. The patient had recurrent episodes of upper gastrointestinal tract obstruction due to congenital duodenal diaphragm which was associated with foreign body impaction.

Abdominal x-rays typically show the double bubble picture with air trapped in the first portion of the duodenum and stomach. Abdominal x-rays may be normal in partial duodenal obstruction. Upper gastrointestinal contrast study usually confirms the diagnosis. It also differentiates between a complicated malrotation (midgut volvulus) and partial duodenal obstruction caused by a web or stenosis.

The surgical procedures available for treating patients with congenital duodenal obstruction are well established and yield predictably good results.¹⁰ Our patient was managed with exploration, removal of foreign body and excision of web and is asymptomatic at follow up.

Conclusion

"Always look for duodenal obstruction in a case of malrotation", this dictum has to be followed. Congenital duodenal diaphragm should be kept in mind as a possibility whenever chronic obstruction of the duodenum in childhood is diagnosed. This case illustrates that diagnosis was delayed for 2½ years after initial presentation in early neonatal age.

References

1. Bailey PV, Tracy TF Jr, Connors RH, Mooney DP, Lewis JE, Weber TR. Congenital duodenal obstruction: a 32-year review. *J Pediatr Surg* 1993;28:92-5.
2. Zissin R, Rathaus V, Oscadchy A, Kots E, Gayer G, Shapiro-Feinberg M. Intestinal malrotation as an incidental finding on CT in adults. *Abdom Imaging* 1999;24:550-5.
3. Jun Gong, Zhen-Jiang Zheng, Gang Mai. Malrotation causing duodenal chronic obstruction in an adult. *World J Gastroenterol* 2009;15:1144-6.
4. Matsukawa Y, Inomata Y, Yamamoto E, Fujimura N. Clinical features of delayed diagnosis in congenital duodenal obstruction. *Nihon Geka Hokan* 1991;60:80-5.
5. Smith GV, Teele RL. Delayed diagnosis of duodenal obstruction in Down syndrome. *Am J Roentgenol.* 1980; 134: 937-40.
6. Daum R. Delayed diagnosis of congenital membranous stenosis of the duodenum (author's transl). *Klin Padiatr* 1975; 187:81-3.
7. Zhou W, Wang X, Li L, Mou Y, Cai X. Upper gastrointestinal tract obstruction due to congenital duodenal diaphragm. *Surg Radiol Anat* 2006;28:325-7.
8. Park WH, Choi SO, Hwang JB. Congenital Duodenal Web Associated with a Foreign Body (Go Stone) in a 10-Year-Old Girl. *J Korean Assoc Pediatr Surg* 2005;11:171-74.
9. Stanley P, Law BS, Young LW. Down's syndrome, duodenal stenosis/annular pancreas, and a stack of coins. *Am J Dis Child* 1988;142:459-60.
10. Harberg FJ, Pokorny WJ, Hahn H. Congenital duodenal obstruction. A review of 65 cases. *Am J Surg* 1979;138:825-8.

Source of support: Nil; Conflict of interest: none declared