

Total Gluteal Reconstruction with “IGA-based V–Y Myocutaneous Advancement Flap”

Madhubari Vathulya¹ Amborish Nath¹ Manish Jagtap¹ Rajkumar Kottayasamy Seenivasagam²

¹Department of Burns and Plastic Surgery, All India Institute of Medical Sciences, Rishikesh, Uttarakhand, India

²Department of Oncosurgery, All India Institute of Medical Sciences, Rishikesh, Uttarakhand, India

Address for correspondence Madhubari Vathulya, MS, MCh, Department of Burns and Plastic Surgery, All India Institute of Medical Sciences, Rishikesh, Uttarakhand, India–249203 (e-mail: madhubari@yahoo.co.in).

Indian J Plast Surg 2019;52:355–357

Abstract

Keywords

- ▶ gluteal reconstruction
- ▶ musculocutaneous flap
- ▶ pedicle flap
- ▶ post oncological defect

Introduction A 44-year-old man was presented with chronic discharging multiple perianal fistula and squamous cell carcinoma of the left buttock.

Report The patient was subjected to wide local excision of the entire left gluteal and adjacent sacral regions and reconstruction with extended island inferior gluteal artery based V–Y myocutaneous advancement flap.

Result and Conclusion Extended island inferior gluteal based V–Y flap can be a good option for extensive defects involving the gluteal region and the sacrum.

Introduction

Patients with multiple chronic discharging sinus in the perianal region rarely present with squamous cell carcinoma in the gluteal region. Worldwide there have been around 65 cases reported which are mostly attributed to Crohn's disease. The post-excisional defects of these patients are generally vast and require large flaps to reconstruct.

Report

A 44-year-old male presented with multiple chronic discharging sinus in the perianal region, with some scarring over the right gluteal region. On the left gluteal region, the sinuses coexisted with a histologically proven squamous cell carcinoma (photo 1). A proctocolonoscopy examination didn't reveal any significant findings apart from a low-rectal fistula. The biopsy of the fistula didn't reveal any malignant changes. A wedge biopsy of the ulcer showed squamous cell carcinoma. After a temporary diversion colostomy, the patient underwent wide local excision. The postexcision defect involved the whole of the left side gluteal region and the sacral region. A modified island inferior gluteal thigh flap (▶ Figs. 1 and 2) was planned, extending from the inferior gluteal crease to the upper two thirds of the thigh. The flap was raised in the subfascial plane initially until the inferior

gluteal crease. Thereafter, to achieve further advancement of the flap, the gluteus maximus fibers from the inferior part were released from the tensor fascia lata attachment (▶ Figs. 3–6). The flap was then advanced in a V–Y fashion. The flap could reach up to the iliac crest of the same side and could also be medially used to resurface the sacral region. The blood supply of the flap was based on the descending branch of the inferior gluteal artery (IGA). The detachment of the fibers of the inferior part of the muscle helped in further advancement of the flap. The flap was sensate as the sensory supply of the inferior gluteal thigh flap territory is preserved along with the vessel. The gait of the patient was not affected much, as part of the muscle was still attached in the superior part. The histopathology report revealed moderately differentiated squamous cell carcinoma

Discussion

When defects of the gluteal and sacral region include the entire anatomical site (entire gluteus or sacral region), the reconstruction becomes complex. The etiology of such complex defects are mainly pressure sores and posttumor excision defects. The occurrence of carcinoma in patients with perianal fistula is around 0.7%¹ in patients with Crohn's disease. According to the authors, the incidence of carcinoma, especially a squamous type in non–Crohn's disease is hardly

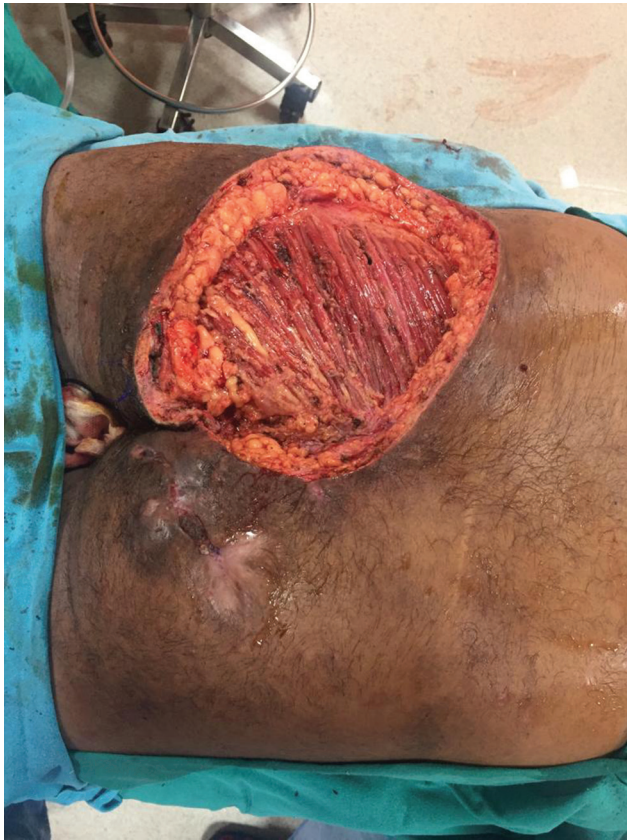

Fig. 1 Posttumor excision defect.

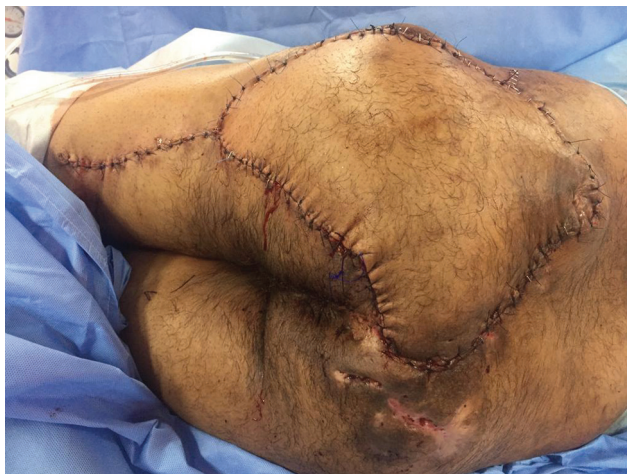

Fig. 2 Flap in situ.

mentioned in the literature. The primary intention of this article is to reveal the occurrence of such rare malignancies in patients with simple chronic perianal fistulas within a short span of time. One of the reasons for the occurrence of such malignant transformation can be chronic irritation² due to the continuous effluent bathing the external skin region from the fistulous tract.

The flaps that have been utilized commonly for gluteal defects are tensor fascia lata³ and anterolateral thigh⁴ pedicled flap. The inferior gluteal thigh flaps are traditionally suggested to resurface ischial and trochanteric ulcers⁵ and rarely used in resurfacing a part of the gluteal region.⁶ The flaps are

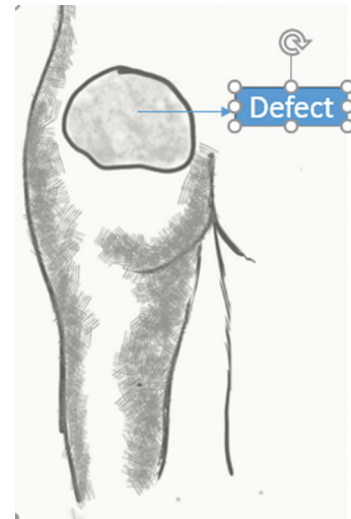


Fig. 3 Schematic diagram of the defect.

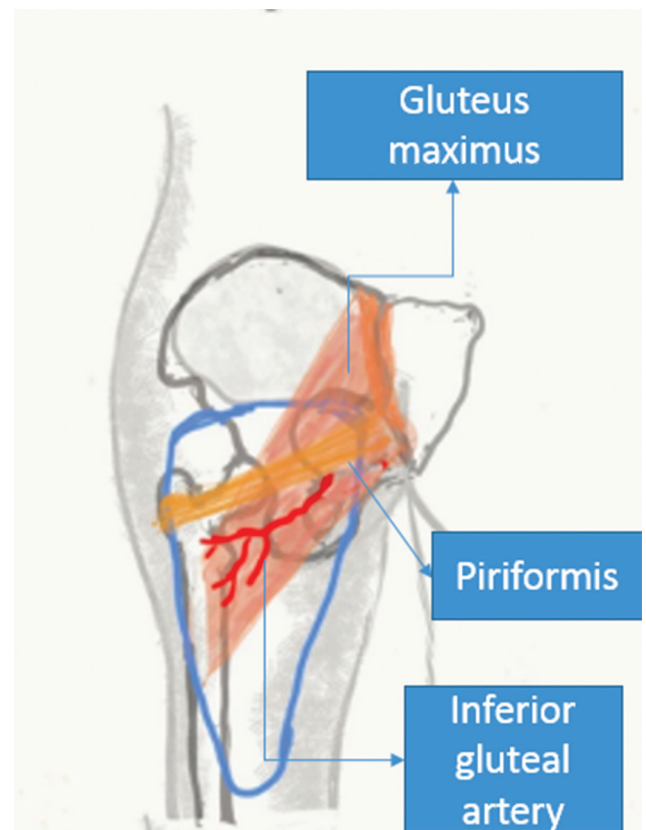


Fig. 4 Flap planning.

sensate as the branches of the posterior femoral cutaneous nerves are in close proximity to the descending branch of the IGA.⁷ Low-back defects have also been addressed with latissimus dorsi flaps by increasing the reach using vein grafts.⁸ The other options for a large gluteal defect are a free tissue transfer⁹ in the form of anterolateral thigh, latissimus dorsi flap, transverse rectus abdominis myocutaneous (TRAM), IGA free flap, and deep inferior epigastric artery perforator flaps.

The use of extended IGA flap incorporating the inferior fibers of gluteus maximus had been earlier used for obliteration of a

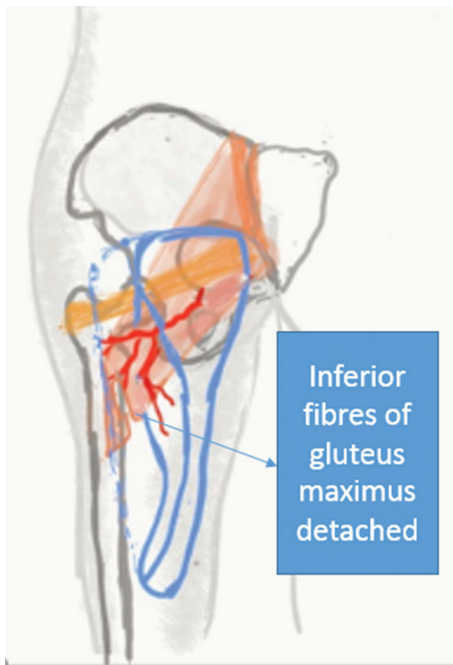


Fig. 5. Detachment of gluteus maximus fibers as shown.

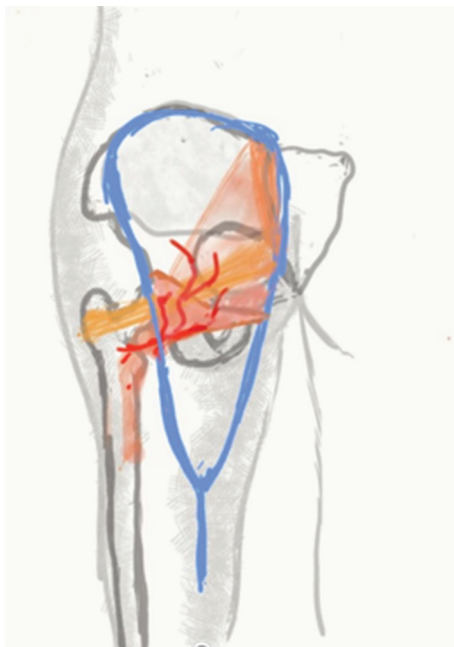


Fig. 6. V-Y advancement of the flap.

pelvic defect.¹⁰ In the article, the author has detached the inferior fibers from both the origin and insertion to increase the reach of the flap. The current article is novel in the following ways:

1. The authors have only detached the gluteus maximus insertion partially to keep the rest of the muscle function intact.

2. The compound flap has been used in total gluteal reconstruction, as well as sacral reconstruction.
3. The flap design has been used in V-Y pattern for the first time for this particular defect.

Conclusion

The conjoint inferior gluteal artery flap can be a good flap option for reconstructing huge gluteal defects. The V-Y design also is technically good for covering such huge dimensions. The added step of detaching the inferior fibers of gluteus maximus provides extra advancement of the flap up to the iliac crest.

References

- 1 Sjødahl RI, Myreid P, Söderholm JD. Anal and rectal cancer in Crohn's disease. *Colorectal Dis* 2003;5(5):490–495
- 2 Benjelloun B, Abkari M, Ousadden A, Ait Taleb K. Squamous cell carcinoma associated anal fistulas in Crohn's disease unique case report with literature review. *J Crohn's Colitis* 2013;7(6):e232–e235
- 3 Chao AH, Kearns PN. Reconstruction of radiated gluteal defects following sarcoma resection with pedicled sensate tensor fascia lata flaps. *Case Rep Oncol Med* 2015;2015:971037
- 4 Ding Q, Zang M, Yu S, Zhao Z, Zhu S, Liu Y. Nearly total unilateral buttock reconstruction with a proximally pedicled anterolateral thigh flap: a case report. *J Plast Reconstr Aesthet Surg* 2013;66(6):e166–e168
- 5 Rubayi S, Chandrasekhar BS. Trunk, abdomen, and pressure sore reconstruction. *Plast Reconstr Surg* 2011;128(3):201e–215e
- 6 Windhofer Ch, Michlits W, Gruber S, Papp Ch. Reconstruction in the buttock region using the local fasciocutaneous infragluteal (FCI) flap. *J Plast Reconstr Aesthet Surg* 2010;63(1):126–132
- 7 Windhofer C, Brenner E, Moriggl B, Papp C. Relationship between the descending branch of the inferior gluteal artery and the posterior femoral cutaneous nerve applicable to flap surgery. *Surg Radiol Anat* 2002;24(5):253–257
- 8 Pannucci CJ, Gerety PA, Nelson JA, Fischer JP, Kovach SJ. Use of intercostal perforating veins and long arterial grafts for latissimus myocutaneous free flap reconstruction of radiated low back wounds. *J Reconstr Microsurg* 2015;31(5):396–400
- 9 Aggarwal S, Pennington D. Reconstruction of gluteal defects using free flaps. *J Plast Reconstr Aesthet Surg* 2013;66(8):1149–1152
- 10 Friedman JD, Reece GR, Eldor L. The utility of the posterior thigh flap for complex pelvic and perineal reconstruction. *Plast Reconstr Surg* 2010;126(1):146–155