


Tuberosity Healing after Reverse Shoulder Arthroplasty for Proximal Humerus Fractures: Is there Clinical Improvement?

Consolidação dos tubérculos na artroplastia reversa do ombro após fratura proximal do úmero: Existe melhoria nos resultados funcionais?

Luís Henrique Barros¹  Sérgio Figueiredo² Manuel Marques³ Claudia Rodrigues¹ Joaquim Ramos¹ Rui Claro¹

¹Department of Orthopaedics, Centro Hospitalar e Universitário do Porto, Porto, Portugal

²Department of Orthopaedics, Centro Hospitalar de Leiria, Leiria, Portugal

³Department of Orthopaedics, Centro Hospitalar do Litoral Alentejano, Santiago do Cacém, Portugal

Address for correspondence: Luís Henrique Barros, MD, Centro Hospitalar e Universitário do Porto, Avenida da República, 855, 1º direito, Vila Nova de Gaia, 4430-040, Portugal (e-mail: luisbarros8@gmail.com).

Rev Bras Ortop 2020;55(6):748–754.

Abstract

Objective To compare the functional results of patients with complex proximal humerus fracture submitted to total shoulder reverse arthroplasty with and without tuberosity healing. The secondary goal was to know the tuberosity healing rate after reverse shoulder arthroplasty with our surgical technique.

Methods A retrospective, cohort type study, with a prospective database collection. In total, 28 patients fulfilled the inclusion criteria: age ≥ 65 years, reverse shoulder arthroplasty for complex proximal humerus fracture (type-3 or -4, according to Neer), and a minimum of 24 months of follow-up. At six months of follow-up, all of the patients were evaluated radiographically for tuberosity, and then they were divided into 2 groups: those with healed tuberosities and those with non-healed tuberosities. A clinical evaluation using the Constant score, active range of motion and the Visual Analog Scale (VAS) at the last follow-up was also performed.

Results Tuberosity healing occurred in 21 patients (76.3%). There were statistically significant differences in the Constant scoring system ($p < 0.001$), forward elevation ($p = 0.020$), internal rotation ($p = 0.001$) and external rotation ($p = 0.003$) when comparing the group of healed tuberosities with the group of non-healed tuberosities. No differences were found regarding the VAS score.

Conclusion Tuberosity healing results in an improvement of the functional outcomes of patients submitted to reverse shoulder arthroplasty as a treatment for complex proximal humeral fractures in the elderly.

Keywords

- ▶ reverse shoulder arthroplasty
- ▶ tuberosity healing
- ▶ elderly fracture
- ▶ proximal humeral fracture

Resumo

Objetivo Comparar os resultados funcionais entre pacientes com fratura complexa do úmero proximal submetidos a artroplastia reversa com tubérculos consolidados e

received
January 9, 2019
accepted
August 15, 2019

DOI <https://doi.org/10.1055/s-0039-3402459>.
ISSN 0102-3616.

Copyright © 2020 by Sociedade Brasileira de Ortopedia e Traumatologia. Published by Thieme Revinter Publicações Ltda, Rio de Janeiro, Brazil

License terms



tubérculos não consolidados. O objetivo secundário foi determinar a taxa de consolidação dos tubérculos com este tipo de prótese.

Métodos Estudo de tipo coorte, retrospectivo, com coleta prospectiva de dados. No total, 28 pacientes cumpriram os critérios de inclusão: idade superior a 65 anos, prótese reversa do ombro por fratura complexa do úmero proximal (3 ou 4 partes, segundo Neer), e tempo de seguimento mínimo de 24 meses. Aos seis meses, todos os pacientes foram avaliados radiograficamente quanto à consolidação dos tubérculos e divididos em dois grupos: grupo com tubérculos consolidados e grupo com tubérculos não consolidados. A avaliação funcional realizou-se segundo o sistema de pontuação de Constant, da amplitude de movimento ativo, e da Escala Visual Analógica (EVA) à data da última consulta. Registaram-se todas as complicações.

Resultados A consolidação dos tubérculos ocorreu em 21 pacientes (76,3%). Verificou-se diferenças estatisticamente significativas no sistema de pontuação de Constant ($p < 0.001$), elevação anterior ($p = 0.020$), rotação interna ($p = 0.001$) e externa ($p = 0.003$), quando se comparou o grupo dos tubérculos consolidados com o grupo dos tubérculos não consolidados. Não houve diferenças significativas na EVA entre os 2 grupos.

Conclusão A consolidação dos tubérculos traduz uma melhoria dos resultados funcionais em pacientes submetidos a artroplastia reversa do ombro como tratamento de fraturas complexas do úmero proximal em idosos.

Palavras-chave

- ▶ artroplastia reversa do ombro
- ▶ consolidação dos tubérculos
- ▶ fratura em idade geriátrica
- ▶ fratura do úmero proximal

Introduction

The last 20 years witnessed an increased incidence of proximal humerus fractures (PHFs), representing 5% of all fractures; currently, this is the third most frequent fracture among the elderly.^{1,2} Moreover, fractures in this population tend to be more complex, such as three- or four-part fractures and dislocated fractures.³ These data show that PHF is a public health problem that tends to get worse as the population ages.

In most PHFs, especially the simpler ones, conservative treatment remains the therapy of choice, with good results.^{4,5} However, the optimal treatment for three- or four-part fractures in the elderly remains questionable. Decisions must be individualized, depending on the comorbidities, functional needs, bone quality and surgeon experience.⁶ Several studies suggest that open reduction and osteosynthesis (ORO) and hemiarthroplasty (HA) are not recommended in large comminution fractures and in patients with osteoporotic bone.⁷ In such cases, ORO is associated with high rates of humeral head avascular necrosis, loss of glenoid reduction and screw-induced destruction. The results of the HAs are unpromising and unpredictable⁸: a randomized trial⁹ demonstrated a functional outcome similar to that of the conservative treatment. The bimodal distribution of the HA results, that is, either excellent or very poor, depends on tuberosity healing,¹⁰ which is usually decreased in patients with osteoporotic bone and/or comminuted fractures, as in the elderly.^{11,12}

Thus, reverse shoulder prostheses (RSPs) have gained popularity in the treatment of these fractures because their results are more consistent and predictable.⁸ Garrigues

et al.¹³ concluded that patients with RSP present better functional outcomes than patients with HA. Since RSPs were designed not to require the rotator cuff, tuberosity healing was not a concern in the initial studies.¹⁴ However, the absence of the rotator cuff, especially the infraspinatus and the minor teres, is associated with worse results (decreased external rotation). Subsequent studies have shown that tuberosity healing leads to superior functional outcomes in both RSP and HA.^{8,15,16} Although we are aware of the significance of tuberosity healing in obtaining better functional results, few studies show its clinical impact on the patient.

The main objective of the present study was to compare the functional results of patients with complex PHF submitted to RSP and healed or non-healed tuberosities. The secondary objective was to determine the rate of tuberosity healing with this type of prosthesis.

Material and Methods

Study Design

After approval by the institutional Ethics Committee, a retrospective cohort study with prospective data collection was performed between January 2011 and December 2015, aiming to evaluate tuberosity healing in patients aged ≥ 65 years undergoing RSP for PHF treatment. The inclusion criteria were patients aged ≥ 65 years, submitted to RSP placement due to complex PHF in 3 or 4 parts according to the Neer classification,⁵ with or without dislocation, and a minimum follow-up time of 24 months. Patients with previous local surgery and time from traumatic event to surgery

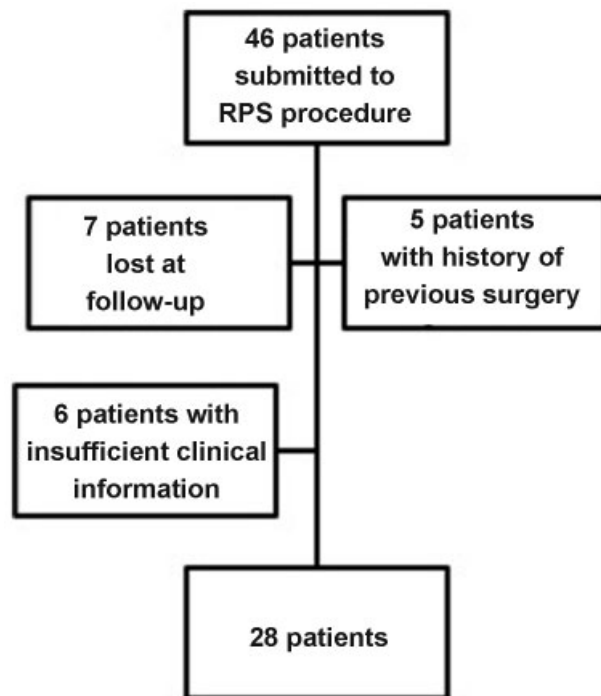


Fig. 1 Patients included in the study after the application of the inclusion and exclusion criteria. Abbreviation: RPSs.

longer than four weeks were excluded. Surgeries were performed by two senior orthopedists dedicated to shoulder pathology, after the patient's consent.

During the study period, 46 patients underwent RSP for PHF treatment. After applying the inclusion and exclusion criteria, 28 patients were included in the study (→ **Figure 1**).

Surgical Technique

The surgeries were performed under general anesthesia with the patients in the “beach chair” position and using the deltopectoral approach. The prosthesis was always the same (Aequalis Reversed Fracture, Tornier, Edina, MN, US).

The following signs of fracture irreparability were also evaluated intraoperatively: a) tuberosity comminution; b) indistinguishable fragments; c) osteoporotic bone; d) marked fracture deviation with calcar comminution.

The long portion of the biceps (LPB) tendon and its gutter served as references for the attachment of the tuberosities. The LPB tenodesis and supraspinatus tendon excision were performed systematically. Tuberosity fixation was prepared with four non-absorbable sutures (Ethibond no. 5; Ethicon, Somerville, New Jersey, US), two through the infraspinatus tendon and two through the minor teres. Two additional sutures were passed through the subscapularis tendon in four-part fractures.

After channel preparation, the stem height was measured using the calcar and tuberosity reduction as references. If the calcar was absent, the soft tissue tension after prosthesis reduction was evaluated: deltoid muscle and joint tendon tension, as well as the distance between the upper edge of the

pectoralis major muscle and the acromion, which should be of about 5.6 cm.¹⁷ The prosthesis version used the system guide with the forearm as reference, using 20° of retroversion to provide greater stability.¹⁸

The glenoid was prepared and the definitive components were placed. The stems were cemented distally to the metaphyseal region, enabling a hybrid fixation. After the cement dried, the prosthesis was reduced, the soft tissue height and tension were evaluated again, and the size of the polyethylene was chosen. The soft parts were properly tensioned when it was difficult to achieve dislocation with axial and lateral forces.¹⁹

Tuberosity fixation was performed according to Pascal Boileau,²⁰ using the previously placed non-absorbable sutures and adding another two similar sutures passed through two holes in the humeral shaft prior to cementation. Thus, after tuberosity reduction, the infraspinatus, minor teres and subscapular tendon sutures fix the tuberosities as horizontal cerclages, and the wires passing through the diaphysis neutralize the construction as two vertical tension bands (one for each tuberosity).

Postoperatively, the limb was immobilized with support for 3 weeks, and then pendular movements were allowed. Elevation and abduction movements were only allowed after six weeks, followed by appropriate rehabilitation.

Radiological Evaluation

Tuberosity healing was assessed radiographically using neutral, internal and external rotation and lateral views six months after surgery.¹¹ Tuberosities above the polyethylene, more than 1 cm away from their anatomical position or not present were considered non-healed. In case of doubt, a computed tomography (CT) scan was requested at six months after surgery as an additional tool, enabling the evaluation of bone continuity between the diaphysis and the tuberosities. The classification of the fractures and tuberosity healing were determined by two shoulder surgeons, and all divergences were solved with the opinion of a third shoulder surgeon.

Functional Evaluation

All patients were evaluated at 2, 6 and 12 weeks, 6 and 12 months and then annually. The functional results were determined using the Constant scoring (CS) system and recording active mobility in forward elevation (FE), abduction, external rotation (ER) and internal rotation (IR). The range of motion was measured in degrees with a goniometer, and the rotations were performed with the elbow close to the body. The Visual Analogue Scale (VAS) was also used. Intra- and postoperative complications were recorded. The results of the patients with healed and non-healed tuberosities were compared.

Statistical Analysis

The mean values of the CS, range of motion and VAS were compared using the nonparametric Mann-Whitney U test due to the sample size. The Pearson Chi-squared test was used in binomial variables to safeguard cell counts ≥ 5 .

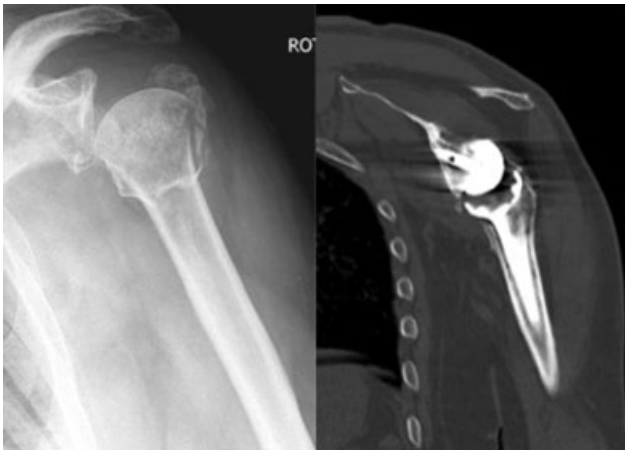

Fig. 2 Computed tomography demonstrating tuberosity healing.

Results

Epidemiological Data

In total, 28 patients were included, 22 (78.6%) females and 6 (21.4%) males, with a mean age of 70.1 years (ranging from 65.2 to 89.8 years). There were 5 3-part fractures and 23 4-part fractures. The mean follow-up was of 58.4 months (ranging from 32.5 to 88.2 months).

Tuberosity Healing

Healing was observed in 21 (75%) patients (►Figure 2). In total, 3 patients had tuberosity resorption, and 4 had tuber-

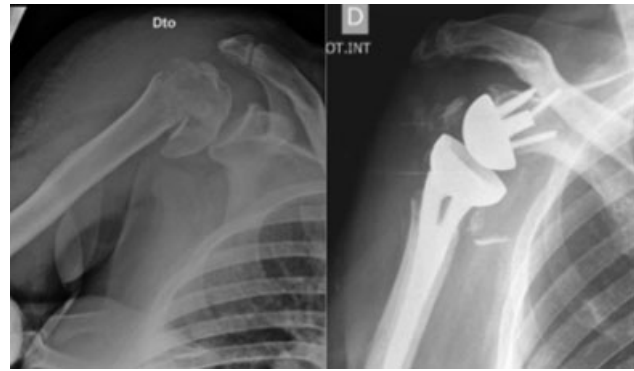


Fig. 3 Radiograph showing non-healed tuberosities.

osity migration, representing a total of 7 (25%) patients with non-healed tuberosities (►Figure 3). ►Table 1 shows the distribution of independent variables in both groups.

Functional Results

Most patients (75.0%) presented no pain at rest and during their daily activities.

The differences in the functional outcomes of patients with healed and non-healed tuberosities are described in ►Table 2. Statistically significant differences were observed regarding the CS, FE, IR and ER. ►Figures 4–8 demonstrate the variable distribution in both groups.

In the multivariate analysis of the potential influence of gender and/or age on outcomes, a statistically significant

Table 1 Tuberosity healing and distribution of independent variables in both groups

Variable	Tuberosity healing		p-value
	Yes (n = 21)	No (n = 7)	
Female gender (%)	16 (76.2%)	6 (85.7%)	0.595*
Median age ¹ [minimum-maximum]	73.6 [60.2–82.1]	70.9 [60.7–89.8]	0.876**
Median follow-up period (months) [minimum-maximum]	56.5 [33.2–88.2]	46.8 [32.5–73.1]	0.140**

Notes: Distribution of independent variables by study group and respective statistical comparison; no statistical differences were observed for any variable. *Chi-squared test. **Mann-Whitney U test.

Table 2 Comparison of functional results in both groups (healed versus non-healed tuberosities)

Functional evaluation	Tuberosity healing		p-value
	Yes (n = 21)	No (n = 7)	
Constant score	79.0 (5;0)	55.0 (11;0)	p < 0.001*
Forward elevation	135.0° (46;0°)	90.0° (70;0°)	p = 0.02*
Abduction	105.0° (45;0°)	75.0° (60;0°)	p = 0.435
Internal rotation	60.0° (45;0°)	30.0° (0;0°)	p = 0.01*
External rotation	60.0° (32;5°)	30.0° (0;0°)	p = 0.03*
Visual Analog Scale score	1.0 (0;5)	1.0 (1;0)	p = 0.836

Note: Continuous variables were presented as median values and the respective 25th percentile-75th percentiles. *p < 0.05.

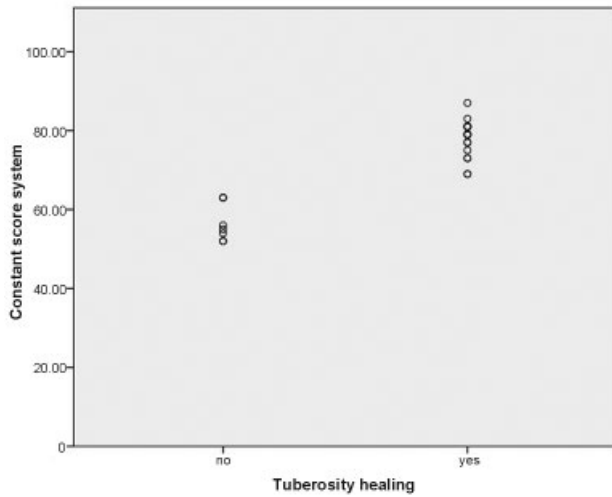


Fig. 4 Constant score distribution by groups (healed versus non-healed tuberosities).

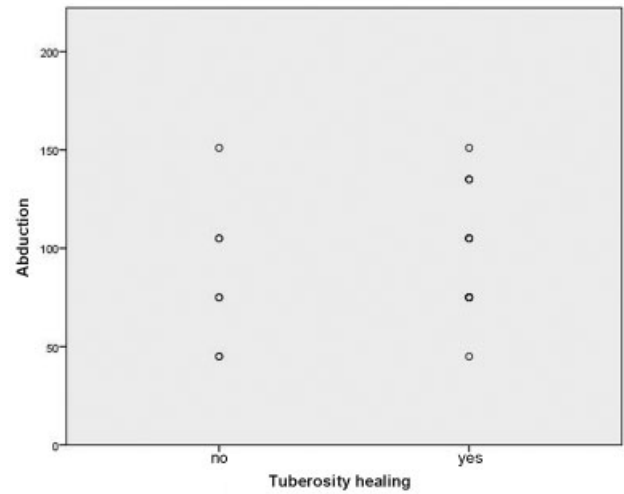


Fig. 6 Shoulder abduction distribution by groups (healed versus non-healed tuberosities).

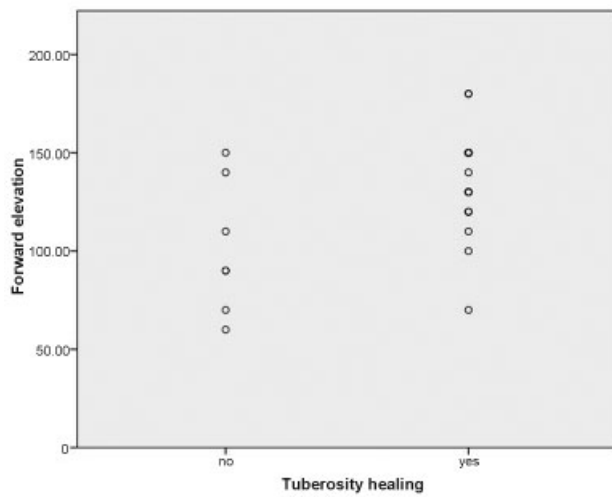


Fig. 5 Distribution of forward shoulder elevation by groups (healed versus non-healed tuberosities).

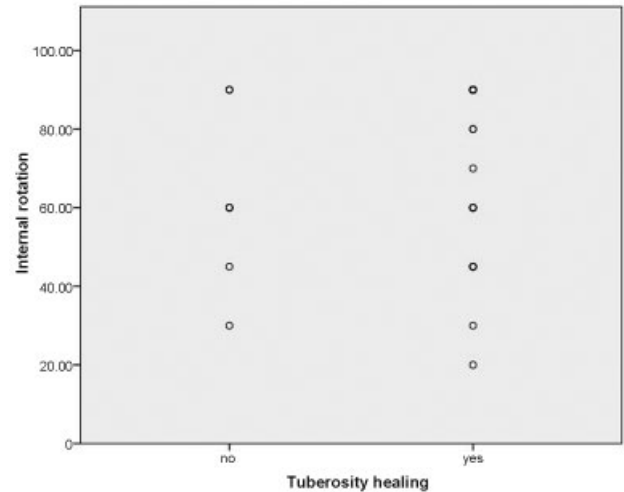


Fig. 7 Distribution of internal shoulder rotation by groups (healed versus non-healed tuberosities).

non-interference was found for the CS ($p=0.630$ and $p=0.868$ respectively), FE ($p=0.157$ and $p=0.853$ respectively), abduction ($p=0.566$ and $p=0.497$ respectively), IR ($p=0.431$ and $p=0.601$ respectively), ER ($p=0.239$ and $p=0.526$ respectively) and VAS ($p=0.164$ and $p=0.722$ respectively). However, when healing was isolated as a variable in the model, only the CS ($p < 0.001$) and IR ($p=0.002$) sustained a statistically significant relationship.

Complications

There were no episodes of dislocation or instability.

There was an acute superficial infection that was submitted to debridement and corresponded to one of the cases of non-healed tuberosity.

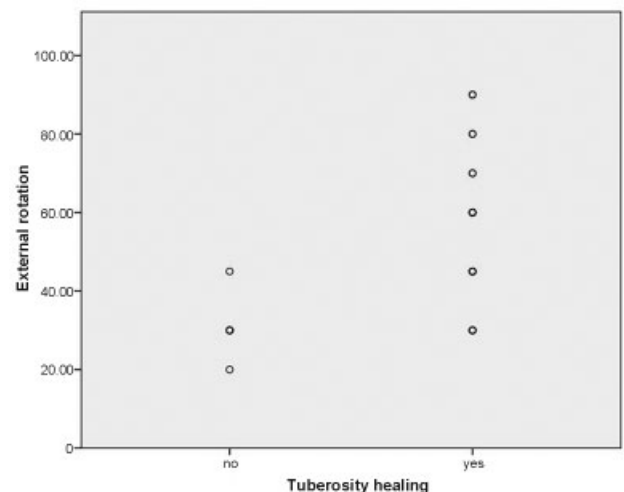


Fig. 8 Distribution of external shoulder rotation by groups (healed versus non-healed tuberosities).

Discussion

Reverse shoulder prostheses are increasingly used in patients with PHF, especially in the elderly. Initially, the longevity of these prostheses was a concern, but good outcomes from medium- and long-term studies have expanded their use. Du et al.²¹ reported that RSPs were associated with a significant increase in CS and decreased re-interventions compared to HA. In addition, Klein et al.¹⁶ reported improvements in the CS and a short-form health survey. In a prospective study evaluating patients with complex PHF undergoing RSP, Bufquin et al.¹⁵ concluded that tuberosity non-healing does not necessarily lead to a poor outcome. Torrens et al.²² stated that clinical results are superimposable, not depending on tuberosity healing. Reverse shoulder prostheses are based on the classical principles of the prosthesis developed by Grammont: a) a semi-constrictive fixed point (fulcrum) prosthesis enabling the deltoid to elevate the arm in a way that does not require rotator cuff action, and b) a lower, medialized center of rotation, which enables deltoid extension and thus decreases the force required for arm abduction.^{23,24} As such, RSPs can lead to good outcomes even without tuberosity healing. However, more recent studies suggest that tuberosity integration and proper rotator cuff function have a functional benefit for patients, increasing range of motion, especially in rotation. Our study found a statistically significant improvement in FE (127.5° versus 101.4), ER (60° versus 30°) and IR (64.8° versus 34.3°). These results reinforce the data reported in the literature. Lenarz et al.²⁵ described an FE of 139° and an ER of 27°, whereas Valenti et al.²⁶ obtained a CS of 55, 112° of FE, 97° of abduction and 12.7° of ER. Gallinet et al.⁸ demonstrated 104° of FE and 33° of ER. A recent systematic review²⁷ summarizes well the results of these studies, concluding that tuberosity healing seems to translate into superior functional outcomes, especially regarding rotations. In addition, a slight improvement in the range of motion of the patients can translate into a real improvement in their quality of life. We observed that increased patient mobility corresponded to CS improvement (79 versus 55). Boileau et al.²⁸ summarize their study by stating that tuberosity healing not only improves FE and ER, but also the patients' quality of life.

As for the second objective of the study, tuberosity healing occurred in 76.3% of the patients. This percentage is in line with more recent studies,^{22,29,30} and it is superior to older works. Boileau et al.²⁸ describe a higher healing rate, of 84%, arguing that tuberosity healing in fractures submitted to RSP is a reproducible procedure even in the elderly. In addition, new developed prostheses, designed specifically for fractures and presenting a window in the metaphyseal region, enable better tuberosity integration and healing.

Some studies advocate that all plans are improved by tuberosity healing.²⁹ We had no significant improvement in abduction (106° versus 83°), but this measure was superior in patients with healed tuberosities. The VAS scores were similar in both groups, showing that the tuberosity healing does not interfere with pain.

The procedure showed low incidence of complications, with only one infection, which was completely eliminated

with debridement and antibiotic therapy. There were no dislocations, instabilities or neurological injuries.

The limitations of the present work are those inherent to retrospective studies. Furthermore, the use of nonparametric tests, due to the relatively small sample size, does not enable a wide discrimination in the data analysis despite the statistical significance of the results. Further randomized studies are required to definitively prove the superiority of the functional outcomes associated with tuberosity healing.

In conclusion, our study showed the superiority of the CS, FE, ER and IR when the tuberosities were healed, which occurred in 78.6% of the cases.

Conflict of Interests

The authors have no conflict of interests to declare.

References

- Sanders RJ, Thissen LG, Teepen JC, van Kampen A, Jaarsma RL. Locking plate versus nonsurgical treatment for proximal humeral fractures: better midterm outcome with nonsurgical treatment. *J Shoulder Elbow Surg* 2011;20(07):1118–1124
- Khatib O, Onyekwelu I, Zuckerman JD. The incidence of proximal humeral fractures in New York State from 1990 through 2010 with an emphasis on operative management in patients aged 65 years or older. *J Shoulder Elbow Surg* 2014;23(09):1356–1362
- Court-Brown CM, Garg A, McQueen MM. The epidemiology of proximal humeral fractures. *Acta Orthop Scand* 2001;72(04):365–371
- Court-Brown CM, Garg A, McQueen MM. The translated two-part fracture of the proximal humerus. Epidemiology and outcome in the older patient. *J Bone Joint Surg Br* 2001;83(06):799–804
- Neer CS II. Displaced proximal humeral fractures. I. Classification and evaluation. *J Bone Joint Surg Am* 1970;52(06):1077–1089
- Maier D, Jaeger M, Izadpanah K, Strohm PC, Suedkamp NP. Proximal humeral fracture treatment in adults. *J Bone Joint Surg Am* 2014;96(03):251–261
- Jobin CM, Galdi B, Anakwenze OA, Ahmad CS, Levine WN. Reverse shoulder arthroplasty for the management of proximal humerus fractures. *J Am Acad Orthop Surg* 2015;23(03):190–201
- Gallinet D, Clappaz P, Garbuio P, Tropet Y, Obert L. Three or four parts complex proximal humerus fractures: hemiarthroplasty versus reverse prosthesis: a comparative study of 40 cases. *Orthop Traumatol Surg Res* 2009;95(01):48–55
- Boons HW, Goosen JH, van Grinsven S, van Susante JL, van Loon CJ. Hemiarthroplasty for humeral four-part fractures for patients 65 years and older: a randomized controlled trial. *Clin Orthop Relat Res* 2012;470(12):3483–3491
- Sirveaux F, Roche O, Molé D. Shoulder arthroplasty for acute proximal humerus fracture. *Orthop Traumatol Surg Res* 2010;96(06):683–694
- Boileau P, Winter M, Cikes A, et al. Can surgeons predict what makes a good hemiarthroplasty for fracture? *J Shoulder Elbow Surg* 2013;22(11):1495–1506
- Boileau P, Krishnan SG, Tinsi L, Walch G, Coste JS, Molé D. Tuberosity malposition and migration: reasons for poor outcomes after hemiarthroplasty for displaced fractures of the proximal humerus. *J Shoulder Elbow Surg* 2002;11(05):401–412
- Garrigues GE, Johnston PS, Pepe MD, Tucker BS, Ramsey ML, Austin LS. Hemiarthroplasty versus reverse total shoulder arthroplasty for acute proximal humerus fractures in elderly patients. *Orthopedics* 2012;35(05):e703–e708
- Cazeneuve JF, Cristofari DJ. The reverse shoulder prosthesis in the treatment of fractures of the proximal humerus in the elderly. *J Bone Joint Surg Br* 2010;92(04):535–539

- 15 Bufquin T, Hersan A, Hubert L, Massin P. Reverse shoulder arthroplasty for the treatment of three- and four-part fractures of the proximal humerus in the elderly: a prospective review of 43 cases with a short-term follow-up. *J Bone Joint Surg Br* 2007;89(04):516–520
- 16 Klein M, Juschka M, Hinkenjann B, Scherger B, Ostermann PA. Treatment of comminuted fractures of the proximal humerus in elderly patients with the Delta III reverse shoulder prosthesis. *J Orthop Trauma* 2008;22(10):698–704
- 17 Murachovsky J, Ikemoto RY, Nascimento LG, Fujiki EN, Milani C, Warner JJ. Pectoralis major tendon reference (PMT): a new method for accurate restoration of humeral length with hemiarthroplasty for fracture. *J Shoulder Elbow Surg* 2006;15(06):675–678
- 18 Nalbone L, Adelfio R, D'Arienzo M, et al. Optimal positioning of the humeral component in the reverse shoulder prosthesis. *Musculoskelet Surg* 2014;98(02):135–142
- 19 Lädermann A, Edwards TB, Walch G. Arm lengthening after reverse shoulder arthroplasty: a review. *Int Orthop* 2014;38(05):991–1000
- 20 Pascal Boileau GW, Sumant G, Krishnan. Tuberosity Osteosynthesis and Hemiarthroplasty for Four-Part Fractures of the Proximal Humerus. *Techniques in Shoulder and Elbow Surgery* 2000
- 21 Du S, Ye J, Chen H, Li X, Lin Q. Interventions for Treating 3- or 4-part proximal humeral fractures in elderly patient: A network meta-analysis of randomized controlled trials. *Int J Surg* 2017;48:240–246
- 22 Torrens C, Alentorn-Geli E, Mingo F, Gamba C, Santana F. Reverse shoulder arthroplasty for the treatment of acute complex proximal humeral fractures: Influence of greater tuberosity healing on the functional outcomes. *J Orthop Surg (Hong Kong)* 2018;26(01):2309499018760132
- 23 Henninger HB, Barg A, Anderson AE, Bachus KN, Tashjian RZ, Burks RT. Effect of deltoid tension and humeral version in reverse total shoulder arthroplasty: a biomechanical study. *J Shoulder Elbow Surg* 2012;21(04):483–490
- 24 Boileau P, Watkinson DJ, Hatzidakis AM, Balg F. Grammont reverse prosthesis: design, rationale, and biomechanics. *J Shoulder Elbow Surg* 2005;14(1, Suppl S):147S–161S
- 25 Lenarz C, Shishani Y, McCrum C, Nowinski RJ, Edwards TB, Gobezie R. Is reverse shoulder arthroplasty appropriate for the treatment of fractures in the older patient? Early observations. *Clin Orthop Relat Res* 2011;469(12):3324–3331
- 26 Valenti P, Katz D, Kilinc A, Elkholti K, Gasiunas V. Mid-term outcome of reverse shoulder prostheses in complex proximal humeral fractures. *Acta Orthop Belg* 2012;78(04):442–449
- 27 Jain NP, Mannan SS, Dharmarajan R, Rangan A. Tuberosity healing after reverse shoulder arthroplasty for complex proximal humeral fractures in elderly patients-does it improve outcomes? A systematic review and meta-analysis. *J Shoulder Elbow Surg* 2019;28(03):e78–e91
- 28 Boileau P, Alta TD, Decroocq L, et al. Reverse shoulder arthroplasty for acute fractures in the elderly: is it worth reattaching the tuberosities? *J Shoulder Elbow Surg* 2019;28(03):437–444
- 29 Garofalo R, Flanagan B, Castagna A, Lo EY, Krishnan SG. Reverse shoulder arthroplasty for proximal humerus fracture using a dedicated stem: radiological outcomes at a minimum 2 years of follow-up-case series. *J Orthop Surg Res* 2015;10:129
- 30 Formaini NT, Everding NG, Levy JC, Rosas S. Tuberosity healing after reverse shoulder arthroplasty for acute proximal humerus fractures: the “black and tan” technique. *J Shoulder Elbow Surg* 2015;24(11):e299–e306