

Severe Osteoarthritis of the Elbow after a Non-Displaced Radial Head Fracture: Case Report*

Osteoartrite global do cotovelo após uma fratura não deslocada da cabeça radial: relato de caso

Lauro Augusto Veloso Costa¹  Bruno Cesar Pereira Brabo^{1,2} André Luís Marangoni²
Luiz Fabiano Presente Taniguchi¹

¹Hospital Municipal Dr. Moysés Deutsch, São Paulo, SP, Brazil
²Hospital Municipal Dr. Carmino Caricchio, São Paulo, SP, Brazil

Address for correspondence Lauro Augusto Veloso Costa, MD, MSc, Hospital Municipal Dr. Moysés Deutsch; Setor de Ortopedia e Traumatologia, Estrada do M'boi Mirim, n 5203, Jardim Ângela, São Paulo, SP, Brasil (e-mail: lauroavc@hotmail.com).

Rev Bras Ortop 2020;55(3):383–385.

Abstract

Fractures of the radial head account for over 50% of all fractures of the forearm. Broberg and Morrey (modification of the Mason classification) classify them in four types. Type 1 fractures are non-displaced or minimally displaced, considered stable and without mechanical joint blockage. In this type of fracture, a non-operative management with a short period of immobilization leads to a good clinical result without adverse outcomes. Clinically relevant associated lesions are not common. Because of this, arthritis of the radiocapitellar and ulnohumeral joint after the non-displaced radial head fracture is uncommon. This case report presents a young patient diagnosed with isolated non-displaced radial head fracture, that evolved 8 months later, to global arthritis of the elbow.

Keywords

- ▶ elbow
- ▶ osteoarthritis
- ▶ radius fractures

Resumo

As fraturas da cabeça radial representam mais de 50% de todas as fraturas do antebraço. Broberg e Morrey (modificação da classificação de Mason) as classificam em quatro tipos. As fraturas do tipo 1 são aquelas não deslocadas ou minimamente deslocadas, consideradas estáveis e sem bloqueio mecânico das articulações. Nesse tipo de fratura, um manejo não operatório com um curto período de imobilização permite bom resultado clínico sem desfechos adversos. Lesões associadas clinicamente relevantes não são comuns. Por esse motivo, a artrite da articulação radiocapitelar e ulnohumeral após a fratura da cabeça do rádio não deslocada é incomum. Este relato de caso apresenta um paciente jovem com diagnóstico de fratura isolada da cabeça radial não deslocada que evoluiu, 8 meses depois, para artrite global do cotovelo.

Palavras-chave

- ▶ cotovelo
- ▶ osteoartrite
- ▶ fraturas do rádio

Introduction

Fractures of the radial head account over 50% of all fractures of the forearm. These fractures occur with an indirect trauma

through the long axis of the radius during a fall with the forearm pronated and partially flexed.^{1,2} Broberg and Morrey classify them in four types (modification of the Mason classification). Type 1 fractures are non-displaced or minimally displaced (displaced by no more than 2 mm), and the size of the fragment should include up to 30% of the head

* Work developed at the Hospital Municipal Dr. Moysés Deutsch, São Paulo, SP, Brasil.

received
August 14, 2019
accepted
October 3, 2019

DOI <https://doi.org/10.1055/s-0039-3402468>.
ISSN 0102-3616.

Copyright © 2020 by Sociedade Brasileira de Ortopedia e Traumatologia. Published by Thieme Revinter Publicações Ltda, Rio de Janeiro, Brazil

License terms



(articular surface). If the fracture is displaced by 2 mm or more or involve 30% of the head, it is considered type 2. Type 3 are comminuted fractures. Finally, type 4 are the fractures with elbow dislocation.^{2,3}

Fractures type 1 are caused by low-energy trauma. They correspond to between 64 and 74% of all fractures of the radial head.^{1,4} Taking into account its characteristics, type 1 fractures are considered stable and do not present mechanical joint blockage. Also, clinically relevant associated lesions are not common.⁵ Because of all this, in this type of fracture, a non-operative management with a short period of immobilization leads to a good clinical result without adverse outcomes.⁴ Osteoarthritis of the radiocapitellar (RC OA) and ulnohumeral joint after the non-displaced radial head fracture is uncommon.⁶

This case report presents a young patient diagnosed with isolated and non-displaced radial head fracture that evolved 8 months later to global arthritis of the elbow. Through revision about non-displaced radial head fracture, this article highlights the importance of patient follow-up to recognize this possible complication, even in injuries considered simple.

Case Report

A 35-year-old man, doorman, had a fall during soccer game. Three days after the injury, the patient attended our hospital for medical care. In the physical examination, he presented unremarkable swelling in the elbow and tenderness over the radial head. Elbow stability was checked and ligament injury was not suspected. After radiography and computed tomography, the patient was diagnosed with non-displaced radial head fracture (►Fig. 1a, b and ►Fig. 2a, b).

The initial treatment was a long arm cast for immobilization. As the patient had no more pain after 7 days of immobilization, he stopped using the cast and returned to his job. Two months later, the patient performed a new radiograph, which showed consolidation with little deformity of the radial head and low degree of osteoarthritis (►Fig. 3a, b). However, just 6 months after that, the patient came to us with complaints of pain and limitation of movement. During the physical examination, the patient presented reduced range of motion (- 80° of extension and 110° of flexion) but had no important limitation to the forearm rotation. Then, the patient performed new radio-

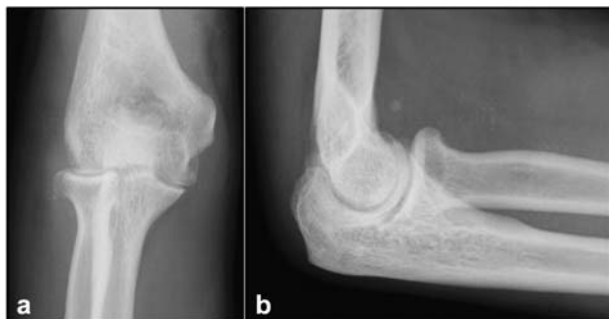

Fig. 1 Initial radiographs of the elbow: anteroposterior (a) and lateral (b) views.

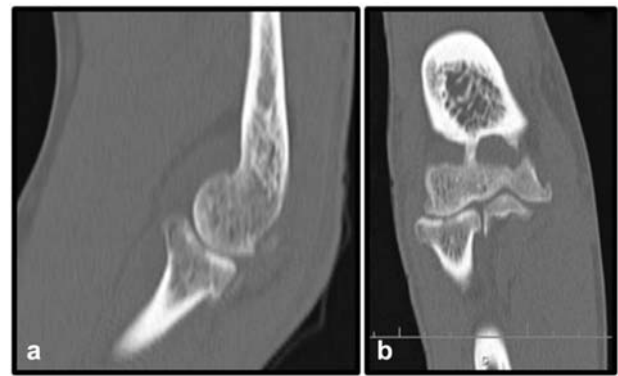


Fig. 2 Computed tomography showed a non-displaced and isolated radial head fracture: sagittal (a) and coronal (b) views.

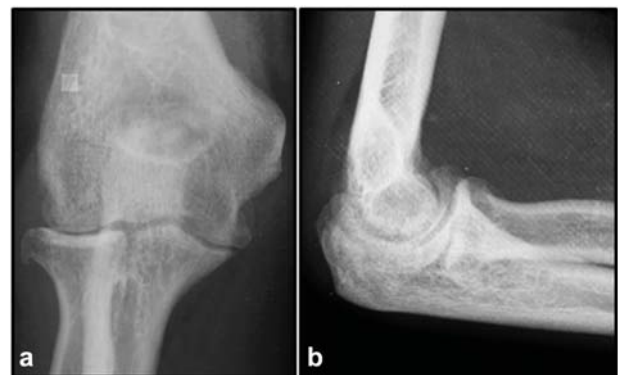

Fig. 3 Radiographs after 2 months of the injury showing fracture consolidation with little deformity of the radial head and low degree of osteoarthritis: anteroposterior (a) and lateral (b) views.

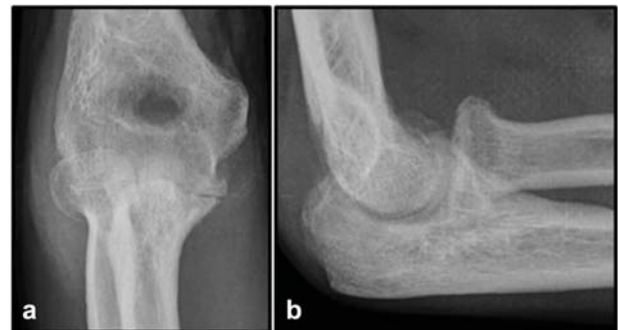

Fig. 4 Anteroposterior (a) and lateral (b) views of the elbow 8 months after the initial injury showing global and severe osteoarthritis.

graphs of the elbow that evidenced severe elbow osteoarthritis (►Fig. 4a, b). Then, he underwent arthroscopic debridement of the elbow, with an important improvement in the range of motion and pain.

Discussion

The main adverse outcomes related to non-displaced radial head fracture are elbow stiffness and occasional elbow pain.^{4,5,7} Elbow arthrosis after this type of fracture is rare.⁶

Herbertsson et al⁷ evaluated the long-term outcomes of 27 Mason type 1 fractures and they reported that although

injured elbows had more degenerative changes than uninjured elbows, these findings do not have clinical significance. The majority of the cases was free of pain and presented no loss of motion. They also reported that injured elbows had more radiologic deformities than uninjured elbows, but these deformities are not associated with osteoarthritis. Kachooei et al⁶ evaluated if patients after nonoperative treatment of an isolated radial head fracture had RC OA. Of the 54 patients evaluated, 1 had an isolated RC OA and 3 also had ulnohumeral osteoarthritis. They concluded, therefore, that RC OA is uncommon after these fractures, even with some degree of deformity of the radial head.

Elbow stability should be checked in the initial physical examination to evaluate ligamentous injuries, since the fracture of the radial head may be part of a complex injury of the elbow. Kaas et al⁵ reported associated lesions using magnetic resonance imaging (MRI) in 12 out of 17 patients with Mason type 1 fractures. In that study, they demonstrated that 47% of the patients diagnosed with this type of fracture also had injury of the lateral collateral ligament (LCL) and 2 out of 17 patients had chondral damage. Of these patients, 7 had a partial rupture and 1 had a complete rupture. Although these injuries are seen in MRI, they are rarely symptomatic. Besides the LCL injury, interosseous membrane (IOM) injuries are also commonly associated with Mason 1 fractures. Hausmann et al⁸ screened 14 patients with Mason type 1 fractures for additional occult IOM lesion. They reported that 9 out of 14 patients had additional lesions of the distal part of the IOM. Since the patients may have additional lesions, it is probable that elbow osteoarthritis after Mason 1 fracture had been part of a more complex ligamentous injury.

In the case herewith presented, the patient was diagnosed with severe posttraumatic arthrosis. However, in the initial physical examination, we did not suspect instability due ligament injury. Therefore, since the patient suffered a high-energy trauma, it is likely that he had a chondral lesion not diagnosed by the images. Another hypothesis is that the patient had an undiagnosed ligament injury at the initial physical examination, since examination for diagnosis of a

subtle elbow ligament injury is not easy to reproduce. In both hypotheses, an MRI of the elbow would probably have helped in this diagnosis and, therefore, may be necessary whenever there is a high-energy trauma.

In conclusion, Mason type 1 radial head fractures are fractures with low risk for developing osteoarthritis after conservative treatment. However, there is no guarantee of favorable outcome. Whenever there is strong clinical suspicion of a more complex injury, as in high-energy trauma, an MRI could be ordered, and the patient should be followed up to identify a possible complication earlier.

Conflict of Interests

The authors have no conflict of interests to declare.

References

- 1 Mahmoud SS, Moideen AN, Kotwal R, Mohanty K. Management of Mason type 1 radial head fractures: a regional survey and a review of literature. *Eur J Orthop Surg Traumatol* 2014;24(07): 1133–1137
- 2 Mason ML. Some observations on fractures of the head of the radius with a review of one hundred cases. *Br J Surg* 1954;42 (172):123–132
- 3 Broberg MA, Morrey BF. Results of treatment of fracture-dislocations of the elbow. *Clin Orthop Relat Res* 1987;(216):109–119
- 4 Duckworth AD, McQueen MM, Ring D. Fractures of the radial head. *Bone Joint J* 2013;95-B(02):151–159
- 5 Kaas L, van Riet RP, Turkenburg JL, Vroemen JP, van Dijk CN, Eygendaal D. Magnetic resonance imaging in radial head fractures: most associated injuries are not clinically relevant. *J Shoulder Elbow Surg* 2011;20(08):1282–1288
- 6 Kachooei AR, Ring D. Evaluation of Radiocapitellar Arthritis in Patients with a Second Radiograph at Least 2 Years after Nonoperative Treatment of an Isolated Radial Head Fracture. *Arch Bone Jt Surg* 2017;5(06):375–379
- 7 Herbertsson P, Josefsson PO, Hasserijs R, Karlsson C, Besjakov J, Karlsson MK. Displaced Mason type I fractures of the radial head and neck in adults: a fifteen- to thirty-three-year follow-up study. *J Shoulder Elbow Surg* 2005;14(01):73–77
- 8 Hausmann JT, Vekszler G, Breitensteiner M, Braunsteiner T, Vécsei V, Gäbler C. Mason type-I radial head fractures and interosseous membrane lesions—a prospective study. *J Trauma* 2009;66(02): 457–461