

# Shoulder Arthroplasty: Tenotomy of the Subscapularis Tendon versus the Lesser Tuberosity Osteotomy

## *Artroplastia de ombro: Tenotomia do subescapular versus osteotomia do tubérculo menor*

Flávio Oliveira França<sup>1,2,3</sup>  José Márcio Alves Freitas<sup>1,2,3</sup> Carlos Alberto Menezes Mariosa<sup>1,2,3</sup>  
 Carlos Eduardo Bastiani<sup>1,2,3</sup> Glaydson Gomes Godinho<sup>1,2,3</sup>

<sup>1</sup> Shoulder and Elbow Surgery Group, Hospital Ortopédico BH, Belo Horizonte, MG, Brazil

<sup>2</sup> Shoulder and Elbow Surgery Group, Hospital Lifecenter, Belo Horizonte, MG, Brazil

<sup>3</sup> Shoulder and Elbow Surgery Group, Hospital Belo Horizonte, Belo Horizonte, MG, Brazil

Address for correspondence Flávio de Oliveira França, MD, MSc, Hospital Belo Horizonte e Hospital Lifecenter, Rua Prof. Otávio Coelho de Magalhães, 111 - Mangabeiras, Belo Horizonte, MG, 30210-300, Brazil (e-mail: flavio.franca29@gmail.com).

Rev Bras Ortop 2020;55(4):463–469.

### Abstract

**Objective** To evaluate and compare subscapular muscle function among patients undergoing subscapular tenotomy (Group A) and lesser tuberosity osteotomy (Group B), in patients treated with total and partial anatomic shoulder arthroplasty for primary osteoarthritis.

**Methods** Retrospective study of patients with primary glenohumeral osteoarthritis surgically undergoing total or partial anatomic shoulder prosthesis implant, evaluated by clinical examination, imaging exams, analogue pain scale and Constant and Murley functional score. A total of 28 patients were evaluated, totalizing a sample of 32 operated shoulders. The minimum follow-up was of 12 months (mean 47.45 months).

**Results** Among patients submitted to subscapularis tendon tenotomy, 10 had an ultrasound with total rupture of its thickness (56%). All of the patients of the group B showed lesser tuberosity healing. There was no difference between groups comparing strength evaluated by Belly press and Bear hug tests as well as clinical outcome, through the Constant and Murley score.

**Conclusions** We did not find differences between Groups A and B evidenced by comparing strength in the Lift-off test, in the Belly press and Bear hug tests and through the Constant and Murley score.

### Keywords

- ▶ shoulder prosthesis
- ▶ arthrosis
- ▶ rotator cuff

### Resumo

**Objetivo** Avaliar e comparar a função do músculo subescapular entre os grupos submetidos a tenotomia do subescapular (Grupo A) e osteotomia do tubérculo menor (Grupo B), em pacientes tratados por artroplastia anatômica total e parcial de ombros apresentando osteoartrose primária.

**Métodos** Estudo retrospectivo de pacientes portadores de osteoartrose primária glenoumeral tratados cirurgicamente com prótese anatômica total ou parcial de ombro, avaliados por exame clínico, exames de imagens, escala visual analógica de

received  
 April 10, 2018  
 accepted  
 February 12, 2019

DOI <https://doi.org/10.1055/s-0039-3402469>.  
 ISSN 0102-3616.

Copyright © 2020 by Sociedade Brasileira de Ortopedia e Traumatologia. Published by Thieme Revinter Publicações Ltda, Rio de Janeiro, Brazil

License terms



**Palavras-chave**

- ▶ prótese de ombro
- ▶ artrose
- ▶ manguito rotador

dor e escore funcional de Constant e Murley. Foram avaliados 28 pacientes, totalizando uma amostra de 32 ombros operados. O seguimento mínimo foi de 12 meses (média 47,45 meses).

**Resultados** Nos pacientes submetidos à tenotomia do tendão subescapular, dez obtiveram resultado ultrassonográfico com ruptura de sua espessura total (56%). A consolidação ocorreu em todos pacientes submetidos a osteotomia do tubérculo menor. Não houve diferença entre os grupos na comparação do teste *Lift Off*, da força nos testes *Belly Press* e *Bear hug*, e no escore de Constant e Murley.

**Conclusões** Não encontramos diferença entre os grupos A e B na comparação do teste *Lift Off*, da força nos testes *Belly Press* e *Bear hug*, e no escore de Constant e Murley.

**Introduction**

Anatomic shoulder replacement surgery is an important therapeutic alternative for advanced cases of joint degeneration, especially in primary osteoarthritis (OA), with good functional results and pain relief.<sup>1</sup> In the deltopectoral surgical approach, subscapularis muscle tendon mobilization is required for adequate joint exposure. Traditionally, a subscapularis tenotomy is performed, but there are conflicting results regarding proper tendon healing, resistance and postoperative function.<sup>2-4</sup> Gerber et al.<sup>5</sup> proposed and described the technique of lesser tuberosity osteotomy, hypothesizing that bone healing (bone-to-bone healing) would decrease possible postoperative subscapular complications and dysfunction.<sup>5,6</sup> However, review studies still debate the best technique to do so.<sup>7-9</sup>

The present study aims to evaluate and compare the postoperative function of the subscapularis muscle in patients undergoing tenotomy or minor tubercle osteotomy in partial and total anatomical shoulder arthroplasty. In addition, subscapularis muscle tendon integrity in patients undergoing tenotomy and minor tubercle healing in patients submitted to osteotomy are assessed.

**Materials and Methods**

This is a retrospective study of patients with primary glenohumeral OA treated with total or partial arthroplasty by six shoulder specialist orthopedists through subscapularis tenotomy (Group A) or minor tubercle osteotomy (Group B). The present study was approved by the Research Ethics Committee under the number CAAE 83162017.7.0000.5126. Patients who agreed to participate in the study signed an Informed Consent Form.

The inclusion criteria were the following: patients with primary OA surgically treated with total or partial anatomic shoulder arthroplasty with a minimum follow-up period of 12 months. Patients with secondary OA, proximal humerus fracture, postoperative infection, unable to answer the functional assessment questionnaires or unable to attend outpatient reevaluation visits were excluded from the study.

**Surgical Technique**

The patient was placed in a “beach chair” position and submitted to general anesthesia and brachial plexus block. Through a deltopectoral approach, tenotomy and tenodesis of the long head of the biceps tendon, near the pectoralis major tendon, were performed.

In Group A, limits of the subscapularis tendon attachment at the lesser tuberosity were identified and tenotomy of its entire craniocaudal extension, one centimeter medial to the bicipital gutter, was performed; for final fixation, non-absorbable, high-resistance, tendon-to-tendon sutures were placed.

In Group B, the procedure was performed as described by Gerber et al.<sup>10</sup> using an osteotome positioned parallel and medial to the bicipital groove; osteotomy was performed in the craniocaudal direction from the rotator interval to the anterior circumflex vessels, towards the medial limit between the articular surface and the capsular attachment. A bone fragment of ~3 to 4 cm in vertical length, 5 to 8 mm in mediolateral length and 5 to 8 mm in thickness is targeted. Anatomical fixation of the bone fragment was performed with nonabsorbable, high-resistance sutures passed at the tendon-bone interface and intraosseously fixed laterally to the bicipital groove.

**Data Collection**

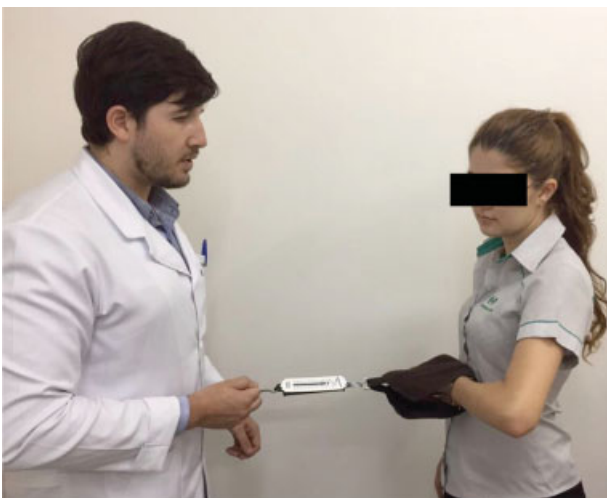Patients were invited for outpatient return visits for interview, assessment according to the visual analogue scale (VAS) for pain,<sup>11</sup> application of the Constant-Murley clinical-functional questionnaire,<sup>12</sup> physical examination, and imaging (radiograph and ultrasound). At the physical examination, the active and passive range of motion were evaluated, and specific maneuvers tested the subscapularis muscle (lift off test, belly press test and bear hug test).<sup>13-15</sup>

At the lift off test,<sup>13</sup> the back of the hand of the patient was positioned in the lumbar region, at the L3 level. Then, the patient was asked to move the hand away from the body with a medial rotation movement of the shoulder. The lift off test was considered positive if the patient was unable to move the back of the hand from the lumbar region or to actively keep the hand away from the body. Patients who presented medial rotation limitation and did not reach the L3 level were considered unable to perform the lift off test.

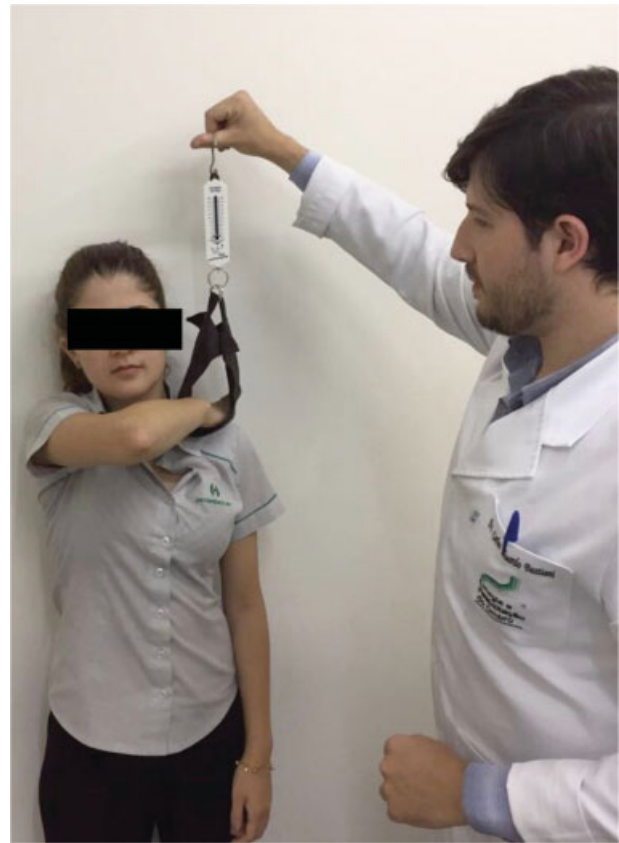The belly press<sup>14</sup> and bear hug<sup>15</sup> tests used a Performance Plus (Performance Plus. Indústria e Comércio Ltda, RJ, Brazil) domestic spring scale with a maximum load of 20 kg to assess the subscapularis muscle strength. For the belly press test, the patient was asked to place the palm of the hand at the abdomen while keeping the elbow in front of the body with the wrist aligned at 180 degrees and to perform a medial rotation movement, pressing the hand against the abdomen (► **Figure 1**). Force was determined with the spring scale cuff between the palm of the hand and the abdomen, while the examiner performed progressively increased force contrary to the medial rotation of the patient. The maximum medial rotation force during the test was determined when the patient could not maintain the hand supported close to the abdomen or the elbow in front of the trunk, resulting in arm extension and wrist flexion, indicating of loss of medial rotation force. At the bear hug test, the patient was asked to place the palm of the involved side on the opposite shoulder with the fingers extended, and keeping the shoulder flexed at 90 degrees. The scale cuff was then placed on the forearm of the affected side and a force perpendicular to it was performed by the examiner to detach the hand of the patient from the shoulder (► **Figure 2**). The patient was asked to resist the maneuver. Maximum strength was measured when the patient could not keep the hand close to the shoulder or when the arm was not flexed at 90 degrees, with wrist flexion and shoulder extension.

All of the patients underwent control radiographs on true anteroposterior views (in neutral, medial rotation and lateral rotation) and axillary and scapular lateral views to assess implant placement and possible loosening of prosthesis components. In Group B, bone healing was assessed through an axillary lateral radiography, which allows a better visualization of the cortical continuity between the lesser tuberosity and the humeral head<sup>5</sup> (► **Figure 3**).

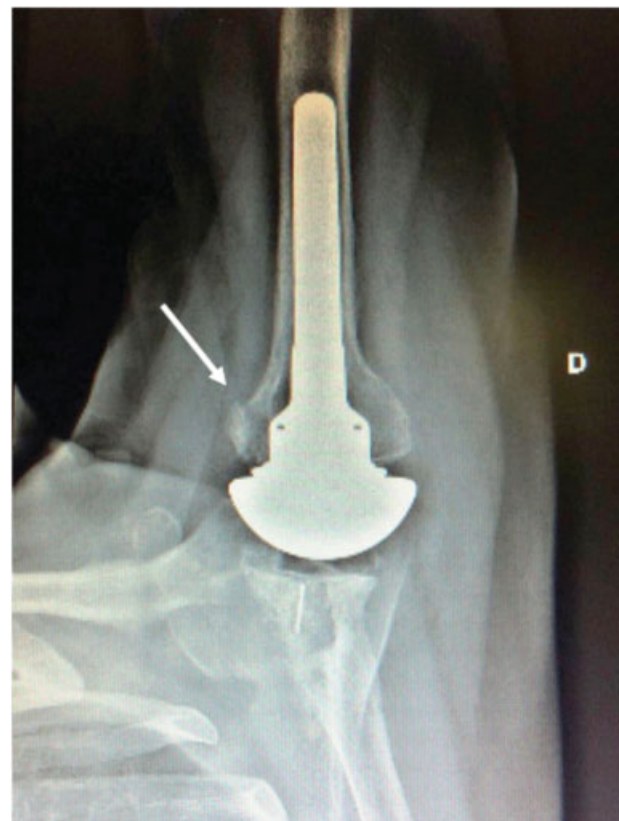Group A patients were submitted to an ultrasound examination to assess the integrity of the subscapularis muscle tendon, which was defined as normal tendon (► **Figure 4A**), tendon with full thickness rupture not affecting the whole craniocaudal extension, or tendon with full extension rupture



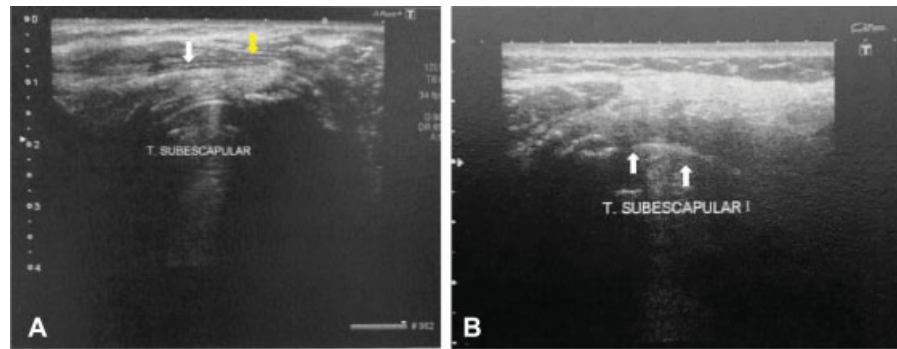
**Fig. 1** Strength measurement at the belly press test.



**Fig. 2** Strength measurement at the bear hug test.



**Fig. 3** Axillary lateral radiography showing lesser tuberosity healing after total shoulder arthroplasty.



**Fig. 4** Ultrasound examination for subscapularis muscle tendon integrity evaluation. (A) Preserved thickness, regular contours, and usual hypoechogenic appearance of the subscapular tendon; (B) tendon not individualized, with an anechoic area in its topography.

involving the entire craniocaudal extension (► **Figure 4B**). All of the ultrasound examinations were performed by the same ultrasound radiologist experienced in musculoskeletal evaluation.

Postoperative results from tenotomy and osteotomy were compared using the Student t-test for independent samples and the chi-squared or Fisher exact test. When no statistical difference was found, Cohen  $d^{16}$  (average values comparison) and Cramer  $V$  (percentages comparison) were performed in an attempt to show effect size through a magnitude scale. The following classification was adopted: Cohen  $d$ , small, 0.20 to 0.49, moderate, 0.50 to 0.79 and elevated,  $\geq 0.80$ ; Cramer  $V$ : small, 0.10 to 0.29, moderate, 0.30 to 0.49 and elevated,  $\geq 0.50$ .<sup>16</sup> All of the analyzes were performed in IBM SPSS Statistics for Windows, Version 20 (IBM Corp., Armonk, NY, USA). Statistical significance was determined as  $p \leq 0.05$ .

## Results

A total of 18 patients who met the inclusion criteria were evaluated between May and November 2017, forming a total sample of 32 operated shoulders. Group A consisted of 16 patients (18 shoulders) and group B had 13 patients (14 shoulders). The average age was 72 years old (range: 44–82 years old); most patients were female (75%). Most surgeries were performed on the right shoulder ( $n = 21$ ; 65.6%). Four patients (8 shoulders) underwent bilateral procedures (14.2%), with five shoulders undergoing tenotomy and three for osteotomy. The median follow-up period was 3.52 years (range: 1–11 years). Total arthroplasty was the most performed procedure (93.3%). All of the patients were diagnosed with primary OA.

Demographic data are expressed in ► **Table 1**. There was no significant difference between groups regarding gender, age and side ( $p > 0.05$ ). However, the postoperative evaluation time was longer in patients of Group A.

Imaging data (radiographs and ultrasounds) are shown in ► **Table 2**. All of the Group B patients were submitted to axillary radiographies, and all presented lesser tuberosity healing. It is noteworthy that 56% of Group A patients presented full thickness rupture of the subscapularis tendon.

**Table 1** Demographic data from patients submitted to tenotomy or osteotomy

Variables	Tenotomy (n = 18) (%)	Osteotomy (n = 14) (%)	p-value	TE
<i>Gender</i>				
Female	12 (67.0)	12 (86.0)	0.410	0.22
Male	6 (33.0)	2 (14.0)		
Age (years old)	72.4 ± 6.5	71.6 ± 9.2	0.770	0.10
<i>Side</i>				
Right	11 (61.0)	6 (43.0)	0.310	0.30
Left	2 (11.0)	5 (36.0)		
Both	5 (28.0)	3 (21.0)		
Follow-up (months)	62 ± 38	22 ± 8	0.001*	–

Abbreviation: TE, size effect.

Mean ± standard deviation for quantitative variables.

Absolute frequency (%) for qualitative variables.

**Table 2** Radiographic and ultrasonographic results in patients submitted to tenotomy or osteotomy

	Tenotomy (Group A) (n = 18) (%)	Osteotomy (Group B) (n = 14) (%)	p-value	TE
<i>Radiography</i>				
Lesser tuberosity in normal position	18 (100.0)	14 (100.0)	–	–
<i>Ultrasound</i>				
Partial Rupture	0 (0.0)	1 (12.0)	–	–
Total Rupture	10 (56.0)	2 (25.0)	–	–

Abbreviation: TE, size effect.

Mean ± standard deviation for quantitative variables.

Absolute frequency (%) for qualitative variables.

► **Table 3** presents clinical and functional results. There were no statistically significant differences between Groups A and B regarding these indicators ( $p > 0.05$ ).

► **Table 4** shows Constant-Murley functional scores (total and weighted values), with no statistically significant difference between groups.



► **Table 5** shows sonographic findings from Group A patients and correlates them to physical examination findings and total and weighted Constant-Murley scores. Patients with total subscapularis tendon rupture presented lower active anterior elevation (EAA) when compared with patients with normal tendon ( $p = 0.03$ ) (► **Figure 5**).

Complications occurred in five procedures (15.62%), four from Group A and one from Group B. Aseptic implant loosening was the most common complication in Group A (two cases), followed by posterior dislocation of the head (one case) and periprosthetic fracture (one case). In Group B,

**Table 3** Comparison of postoperative clinical outcomes in patients submitted to tenotomy or osteotomy

Variables	Tenotomy (Group A) (n = 18)	Osteotomy (Group B) (n = 14)	p-value	TE
EAA	147 ± 40	138 ± 37	0.46	-
EAP	165 ± 26	156 ± 24	0.13	-
Active RL1	69 ± 11	61 ± 15	0.12	-
Passive RL1	69 ± 11	62 ± 16	0.21	-
Active RL2	77 ± 12	80 ± 13	0.34	-
Passive RL2	82 ± 9	81 ± 13	0.90	-
<b>Medial Rotation</b>				
T7 to T12	14 (78.0)	13 (93.0)	0.61	0.24
L1 to L5	2 (11.0)	0 (0.0)		
Gluteus	2 (11.0)	1 (7.0)		
<b>Lift-Off</b>				
Not performed	3 (17.0)	0 (0.0)	0.23	0.32
Negative	11 (61.0)	11 (86.0)		
Positive	4 (22.0)	3 (14.0)		
Belly Press (strength)	5.3 ± 2.0	5.0 ± 2.5	0.73	0.14
Bear Hug (strength)	4.9 ± 1.4	4.6 ± 2.8	0.72	0.14

Abbreviations: EAA, Active anterior elevation; EAP, passive anterior elevation; RE2, lateral rotation 2; RL1, lateral rotation 1; TE, size effect. Mean ± standard deviation for quantitative variables. Absolute frequency (%) for qualitative variables.

**Table 4** Total and weighted Constant score in patients submitted to tenotomy or osteotomy

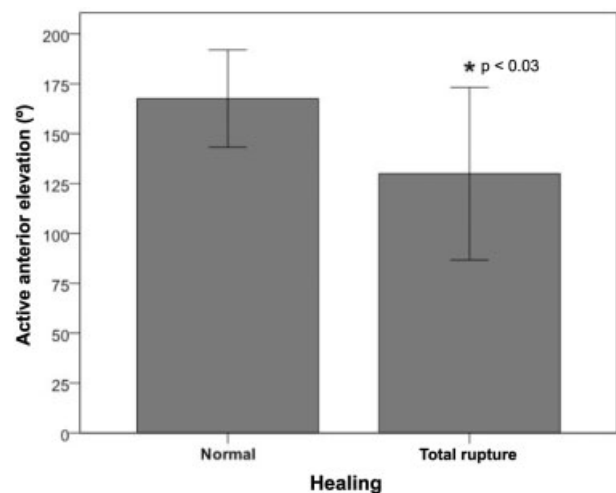
Variables	Tenotomy (Group A) (n = 18)	Osteotomy (Group B) (n = 14)	p-value	TE
Constant (total value)	72 ± 13	75 ± 15	0.56	0.21
Constant (total weighted value)	85 ± 13	90 ± 18	0.43	0.32

Abbreviation: TE, size effect. Mean ± standard deviation for quantitative variables. Absolute frequency (%) for qualitative variables.

**Table 5** Comparison of postoperative clinical and functional outcomes in patients submitted to tenotomy (Group A) with or without subscapularis tendon rupture

Variables	No Rupture (n = 8) (%)	Total Rupture (n = 10) (%)	p-value	TE
Visual Analog Scale for pain	1.0 ± 1.2	1.6 ± 2.9	0.39	-
Belly press	6.0 ± 3.0	5.0 ± 1.0	0.27	0.50
Bear Hug	5.0 ± 2.0	4.9 ± 1.0	0.89	0.07
<b>Lift-Off</b>				
Not performed	1 (13.0)	2 (20.0)	1.00	0.11
Negative	5 (62.0)	6 (60.0)		
Positive	2 (25.0)	2 (20.0)		
<b>Medial Rotation</b>				
T7 to T12	6 (75.0)	8 (80.0)	1.00	0.06
L1 to L5	1 (12.5.0)	1 (10.0)		
Gluteus	1 (12.5.0)	1 (10.0)		
EAA	168 ± 24	130 ± 43	0.03*	-
EAP	174 ± 14	158 ± 30	0.14	-
Active RL1	71 ± 8	67 ± 12	0.31	-
Passive RL1	71 ± 10	67 ± 12	0.38	-
Active RL2	80 ± 11	75 ± 13	0.38	-
Passive RL2	82 ± 10	82 ± 9	0.96	-
Constant-Murley (total value)	77 ± 15	68 ± 9	0.12	0.75
Constant-Murley (total weighted value)	91 ± 14	81 ± 10	0.12	0.83

Abbreviations: EAA, Active anterior elevation; EAP, passive anterior elevation; RE2, Lateral rotation 2; RL1, lateral rotation 1; TE, size effect. Mean ± standard deviation for quantitative variables. Absolute frequency (%) for qualitative variables.



**Fig. 5** Active anterior elevation in tenotomy patients with normal healing (n = 8) and total tendon rupture (n = 10). \*Statistically significant difference,  $p < 0.05$ .

only one patient had a complication, a subscapularis tendon rupture that resulted in humerus-acromial space reduction with no implant loosening.

## Discussion

Since 1982, when Neer<sup>17</sup> showed the excellent functional outcomes of shoulder arthroplasty for primary OA in patients without rotator cuff injury and with the subsequent development of the third generation of shoulder prostheses, surgical results significantly improved. Current models show that shoulder prosthesis survival is 97% in 10 years and 84% in 20 years, with < 10% complications in 10 years.<sup>17</sup> In our study, to minimize the risk of implant failure and to improve functional outcomes, all of the surgeries were performed with maximum technical rigor regarding prosthesis placement, with no difference between the groups.

The epidemiological profile observed in our study is similar to literature reports,<sup>8,18</sup> with a female predominance (67% of Group A patients and 86% of Group B patients were women), average age of 72 years old and mean follow up period of 3.5 years. Groups were similar regarding gender, age and side ( $p > 0.05$ ). However, the postoperative evaluation time was shorter in patients submitted to lesser tuberosity osteotomy, since this procedure was introduced after the subscapularis tenotomy, which can be considered an evaluation bias. Likewise, although the surgical technique is identical among the six surgeons, since they all work together and had the same technical training, this constitutes a possible bias for surgical outcome.

The low postoperative VAS score in our patients demonstrates the excellent result of arthroplasty for pain relief. In our study, the average VAS value was less than 1.2 points in both groups, in line with values reported in the world literature.<sup>18</sup>

In the present study, patients presented higher values of anterior elevation (tenotomy group) and lateral rotation close to the body (both groups) when compared to the findings from Jandhyala et al.<sup>19</sup> On the other hand, these same authors presented an average active elevation value for the osteotomy group superior to our study.

Regarding strength measurement, results from the belly press and bear hug tests were similar in both groups, as reported by other authors.<sup>20,21</sup> In the same way, Buckley et al.<sup>21</sup> observed that the strength in the belly press and bear hug tests tended to be higher in the osteotomy group, but with no statistical difference. In our study, all Group B patients were able to perform the lift off test, and two subjects were positive. Three Group A patients failed to perform the test due to medial rotation deficit, and four were positive. There was no statistical difference between the groups. Caplan et al.<sup>2</sup> evaluated 45 tenotomies and obtained negative results at the lift off test in 41 patients; in addition, the test was inconclusive in four subjects who could not out the hand at the lumbar region. The bear hug test was negative in all 45 shoulders.

In the present study, 56% of the shoulders submitted to tenotomy presented total subscapularis tendon rupture. This finding resembles reports from other authors<sup>18,20-22</sup> regard-

ing changes at the sonographic evaluation of the tendon. All Group B patients presented lesser tuberosity healing, following a trend in the literature.<sup>19,20,23</sup>

Three Group B patients had poor results during the clinical examination (positive lift off test and low strength at the belly press and bear hug tests). Therefore, we decided to request an ultrasound examination to evaluate the subscapularis muscle tendon integrity, which demonstrated a total rupture in two of these subjects and a partial rupture in another. Since the tendon was not addressed during surgery, we believe that the rupture occurred for other reasons not related to the technique, which may have worsened the group outcome. One of these patients with total rupture had a decrease in the humeral-acromial distance, suggesting an extensive cuff injury.

Constant-Murley functional assessment results were satisfactory and similar between the tenotomy (total value = 72, weighted value = 85) and osteotomy (total value = 75, weighted value = 90) groups. Buckley et al.<sup>21</sup> detected no difference between groups. Liem et al.<sup>22</sup> evaluated 23 patients operated for subscapularis disinsertion, and the Constant-Murley score was 43.8 in patients with positive lift off test and 62.7 in those with negative lift off test; both values are below those found in our sample. For Qureshi et al.<sup>23</sup> who evaluated 30 arthroplasties with lesser tuberosity osteotomy, the Constant-Murley score was 64, also below our values.

In Group A, patients with complete tendon rupture ( $n = 10$ ) were compared to those with intact tendon ( $n = 8$ ). There was no statistical difference at the Constant-Murley score. However, in patients with no rupture, the effect size (Cohen  $d$ ) was high ( $d = 0.83$ ). From a practical point of view, this demonstrates a high magnitude for better score results in subjects with intact tendon. Although there were no differences in the lift off, bear hug and belly press test results between these patients, the effect size was moderate ( $d = 0.50$ ) for the belly press test in subjects with intact tendons, indicating a moderate magnitude for greater strength in this test in patients with normal tendon at the ultrasound examination. Patients with intact subscapularis tendon presented significantly higher EAA than those with total lesion ( $p = 0.03$ ), a fact that may be explained by the loss of rotator cuff anterior and posterior forces balance.

Similar findings between groups in specific subscapularis muscle tests, even in view of the high incidence of total subscapularis tendon rupture at the tenotomy group, can be explained by the reportedly great variability regarding their sensitivity and specificity, which could justify the amount of false-negative results.<sup>15,24,25</sup>

## Conclusion

In the present study, patients undergoing total or partial anatomical shoulder arthroplasty through subscapularis muscle tenotomy or lesser tuberosity osteotomy have similar clinical, radiographic and functional results.

### Conflict of Interests

The authors declare that have no conflict of interests.

## References

- 1 Cofield RH. Total shoulder arthroplasty with the Neer prosthesis. *J Bone Joint Surg Am* 1984;66(06):899–906
- 2 Caplan JL, Whitfield B, Neviasser RJ. Subscapularis function after primary tendon to tendon repair in patients after replacement arthroplasty of the shoulder. *J Shoulder Elbow Surg* 2009;18(02):193–196, discussion 197–198
- 3 Miller SL, Hazrati Y, Klepps S, Chiang A, Flatow EL. Loss of subscapularis function after total shoulder replacement: A seldom recognized problem. *J Shoulder Elbow Surg* 2003;12(01):29–34
- 4 Miller BS, Joseph TA, Noonan TJ, Horan MP, Hawkins RJ. Rupture of the subscapularis tendon after shoulder arthroplasty: diagnosis, treatment, and outcome. *J Shoulder Elbow Surg* 2005;14(05):492–496
- 5 Gerber C, Yian EH, Pfirrmann CA, Zumstein MA, Werner CM. Subscapularis muscle function and structure after total shoulder replacement with lesser tuberosity osteotomy and repair. *J Bone Joint Surg Am* 2005;87(08):1739–1745
- 6 Van den Berghe GR, Nguyen B, Patil S, et al. A biomechanical evaluation of three surgical techniques for subscapularis repair. *J Shoulder Elbow Surg* 2008;17(01):156–161
- 7 Schrock JB, Kraeutler MJ, Houck DA, Provenzano GG, McCarty EC, Bravman JT. Lesser tuberosity osteotomy and subscapularis tenotomy repair techniques during total shoulder arthroplasty: A meta-analysis of cadaveric studies. *Clin Biomech (Bristol, Avon)* 2016;40:33–36
- 8 Louie PK, Levy DM, Bach BR Jr, Nicholson GP, Romeo AA. Subscapularis Tenotomy Versus Lesser Tuberosity Osteotomy for Total Shoulder Arthroplasty: A Systematic Review. *Am J Orthop* 2017;46(02):E131–E138
- 9 Choate WS, Kwapisz A, Momaya AM, Hawkins RJ, Tokish JM. Outcomes for subscapularis management techniques in shoulder arthroplasty: a systematic review. *J Shoulder Elbow Surg* 2018;27(02):363–370
- 10 Gerber C, Pennington SD, Yian EH, Pfirrmann CA, Werner CM, Zumstein MA. Lesser tuberosity osteotomy for total shoulder arthroplasty. Surgical technique. *J Bone Joint Surg Am* 2006;88 (Suppl 1 Pt 2):170–177
- 11 Jensen MP, Karoly P, Braver S. The measurement of clinical pain intensity: a comparison of six methods. *Pain* 1986;27(01):117–126
- 12 Constant CR, Gerber C, Emery RJ, Sjøbjerg JO, Gohlke F, Boileau P. A review of the Constant score: modifications and guidelines for its use. *J Shoulder Elbow Surg* 2008;17(02):355–361
- 13 Gerber C, Krushell RJ. Isolated rupture of the tendon of the subscapularis muscle. Clinical features in 16 cases. *J Bone Joint Surg Br* 1991;73(03):389–394
- 14 Gerber C, Hersche O, Farron A. Isolated rupture of the subscapularis tendon. *J Bone Joint Surg Am* 1996;78(07):1015–1023
- 15 Barth JR, Burkhart SS, De Beer JF. The bear-hug test: a new and sensitive test for diagnosing a subscapularis tear. *Arthroscopy* 2006;22(10):1076–1084
- 16 Cohen J. A power primer. *Psychol Bull* 1992;112(01):155–159
- 17 Walch G, Boileau P, Noël E. Shoulder arthroplasty: evolving techniques and indications. *Joint Bone Spine* 2010;77(06):501–505
- 18 Shafritz AB, Fitzgerald MG, Beynon BD, DeSarno MJ. Lift-off Test Results After Lesser Tuberosity Osteotomy Versus Subscapularis Peel in Primary Total Shoulder Arthroplasty. *J Am Acad Orthop Surg* 2017;25(04):304–313
- 19 Jandhyala S, Unnithan A, Hughes S, Hong T. Subscapularis tenotomy versus lesser tuberosity osteotomy during total shoulder replacement: a comparison of patient outcomes. *J Shoulder Elbow Surg* 2011;20(07):1102–1107
- 20 Scalise JJ, Ciccone J, Iannotti JP. Clinical, radiographic, and ultrasonographic comparison of subscapularis tenotomy and lesser tuberosity osteotomy for total shoulder arthroplasty. *J Bone Joint Surg Am* 2010;92(07):1627–1634
- 21 Buckley T, Miller R, Nicandri G, Lewis R, Voloshin I. Analysis of subscapularis integrity and function after lesser tuberosity osteotomy versus subscapularis tenotomy in total shoulder arthroplasty using ultrasound and validated clinical outcome measures. *J Shoulder Elbow Surg* 2014;23(09):1309–1317
- 22 Liem D, Kleeschulte K, Dedy N, Schulte TL, Steinbeck J, Marquardt B. Subscapularis function after transosseous repair in shoulder arthroplasty: transosseous subscapularis repair in shoulder arthroplasty. *J Shoulder Elbow Surg* 2012;21(10):1322–1327
- 23 Qureshi S, Hsiao A, Klug RA, Lee E, Braman J, Flatow EL. Subscapularis function after total shoulder replacement: results with lesser tuberosity osteotomy. *J Shoulder Elbow Surg* 2008;17(01):68–72
- 24 Itoi E, Minagawa H, Yamamoto N, Seki N, Abe H. Are pain location and physical examinations useful in locating a tear site of the rotator cuff? *Am J Sports Med* 2006;34(02):256–264
- 25 Leroux JL, Thomas E, Bonnel F, Blotman F. Diagnostic value of clinical tests for shoulder impingement syndrome. *Rev Rhum Engl Ed* 1995;62(06):423–428