Controversies in Cleft Rhinoplasty

Steven G. Hoshal, MD[1] Roberto N. Solis, MD[1] Travis T. Tollefson, MD, MPH[1]

[1] Division of Facial Plastic and Reconstructive Surgery, Department of Otolaryngology –Head and Neck Surgery, University of California Davis, Sacramento, California

Facial Plast Surg 2020;36:102–111.

Address for correspondence Travis T. Tollefson, MD, MPH, FACS, Division of Facial Plastic and Reconstructive Surgery, Department of Otolaryngology- Head and Neck Surgery, University of California Davis, 2521 Stockton Boulevard, Suite 7200, Sacramento, CA 95817 (e-mail: tttollefson@ucdavis.edu).

Abstract

Rhinoplasty for cleft lip nasal deformities challenges all cleft surgeons. There is great variability of phenotypical anatomy, but iatrogenic changes and scarring from the previous surgeries add another layer of complexity. Rhinoplasties on a patient with cleft lip–palate are technically and intellectually challenging to master requiring a patient-tailored approach. The shape and structure of the nose are changed to improve both function and aesthetic appearance. In the primary setting, nasoalveolar molding is a form of presurgical infant orthopaedics used for preparation before the cleft lip and nose repair. Intermediate stages should be conservative to minimize scarring, while the definitive cleft rhinoplasty utilizes cartilage grafts from septum, ear, or rib to sculpt the nose. Hereinto, we will outline the controversies, the evidence supporting certain techniques, and our preferences.

Keywords
- rhinoplasty
- cleft lip
- cleft nasal deformity
- cartilage graft
- definitive cleft rhinoplasty
- intermediate cleft rhinoplasty
- primary cleft rhinoplasty
- nasoalveolar molding

Rhinoplasty is a surgical procedure to improve the form or external appearance of the nose while preserving function of the nasal airway. Functional and aesthetic nasal deformities are considered one of the most challenging aspects of reconstruction in patients with cleft lip and palate.[1,2] The goal of this article is to review the recent literature on controversies in cleft rhinoplasty and to summarize the senior author's (T.T.T.) experience. This article will include illustrative cases to summarize some of the controversies in cleft rhinoplasty including (1) advantages and disadvantages of the extent and timing of primary rhinoplasty, (2) differences in grafting materials, and (3) the utility of presurgical infant orthopaedics (PSIO) and postoperative molding.

Background

Cleft lip and palate deformities occur in ~1 in 500 to 1 in 1000 live births that make it the most common congenital craniofacial abnormality.[3] Asians and Native Americans have the highest incidence of cleft deformities, whereas people of African descent have lower incidence.[4,5] There are well-established deformities noted with unilateral (►**Table 1**) and bilateral (►**Table 2**) cleft nasal deformities.[2]

Rhinoplasty techniques are designed to address these common anatomic dysmorphisms. The goal of the unilateral cleft rhinoplasty is to reposition the cleft side lower lateral cartilage (LLC), create dome symmetry, align the caudal septum, elongate the columella, correct alar webbing, medialize the cleft alar base, and build structural support.[6] Similar goals are implicated in bilateral cleft rhinoplasty; however, there is typically less asymmetry. PSIO, such as nasoalveolar molding (NAM) are effective at preparing the cleft alveolus and soft tissues of the lip–nose construct. NAM requires significant commitment by the family and cleft orthodontist with a variety of institution-dependent protocols.[7] Nasal stenting is used to mold the nasal contours for 1 to 6 weeks after the primary rhinoplasty, but data supporting its use is limited.

Over the past hundred years cleft surgeons have attempted to develop, revise, and perfect techniques for remedying these anatomically complex deformities. The senior author (T.T.T.) considers the timing and extent of rhinoplasty to be the unanswered dilemma, due to the

Issue Theme Challenges in Rhinoplasty; Guest Editor: Robin Lindsay, MD

DOI https://doi.org/10.1055/s-0040-1701477.
ISSN 0736-6825.

Table 1 Characteristics of unilateral cleft lip nasal deformity

Grossly asymmetric
Base of columella deviated toward noncleft side
Nostril is wider and retrodisplaced on cleft side
Nostril margin on cleft side buckles inward because of bowing by internal vestibular web
Deficient maxilla on cleft side (often absent nasal floor affecting piriform aperture)
Posterolaterally displaced alar base and piriform margin on cleft side
Deviated premaxilla, columella, and caudal septum toward noncleft side
Posterolaterally displaced cleft-side dome of lower lateral cartilage (LLC)
Increased angle between medial and lateral crura on cleft side
Short medial crus on cleft side
Long lateral crus on cleft side
Upper lateral cartilage and LLC on cleft side are side by side rather than normal overlap

Source: Adapted from Cuzalina A, Jung C. Rhinoplasty for the cleft lip and palate patient. Oral Maxillofac Surg Clin North Am 2016;28(2):189–202.

Table 2 Characteristics of bilateral cleft lip nasal deformity

Grossly symmetric
Wide nose with broad and depressed tip
Short columella
Wide nostrils with inward collapsing margins
Flared alae with bilateral vestibular webbing
Posterolaterally displaced alar domes
Increased angles of divergence between the medial and lateral crura
Shortened medial crura
Longer lateral crura
Protrusive premaxilla
Hypoplastic maxilla bilaterally
Anterior nasal spine and caudal septum are inferiorly displaced relative to the alar bases
Deficient or absent bony nasal floor

Source: Adapted from Cuzalina A, Jung C. Rhinoplasty for the cleft lip and palate patient. Oral Maxillofac Surg Clin North Am 2016;28(2):189–202.

variety of treatment paradigms. Timing of cleft rhinoplasty has remained a controversy for decades and has been divided into primary, intermediate, and definitive cleft rhinoplasty. Primary rhinoplasty is performed at the time of cleft lip repair and has gained popularity in the past several decades. Definitive rhinoplasty usually takes place once a patient reaches facial skeletal maturity; 14 to 16 years old for females and around 16 to 18 years old for males. There is a trend to address the cleft nasal deformity at younger ages based on the psychosocial effects of prolonged nasal deformities and the ability to correct the nasoseptal deviations in early teen years. This is supported by evidence of minimal impact on growth, which was the original reasoning behind recommending delay of the definitive rhinoplasty. Most surgeons continue to defer significant nasal osteotomies, and remain conservative in these settings.

Intermediate rhinoplasty is performed in between these time periods. Timing is not the only issue, but the degree of surgery performed at each stage. More extensive surgery will lead to greater scarring that can influence the difficulty of the definitive rhinoplasty. In addition, the need for grafting and type of graft to implement in this patient population is of particular debate.

Presurgical Infant Orthopaedics

PSIO is a controversial preoperative strategy that uses external appliances to reposition anatomic structures into more favorable positions before undergoing surgery. Reports date back to the sixteenth century, in which the premaxilla was repositioned prior to the cleft lip and palate repairs.[8] In the 1980s, the Latham (Leibinger Ltd.) device was introduced that uses a screw mechanism to shift the premaxilla and the lateral alveolar cleft segments.[9] The modern NAM appliance was introduced by Grayson et al in the 1990s.[10] After its introduction, Grayson and Cutting noted that NAM improved cosmetic outcomes with a reduction in the need for secondary nasal surgeries and alveolar bone grafting.[11] In a large survey of active cleft surgeons in North American regarding unilateral cleft lip repair, ~26% of respondents used active presurgical orthopaedics such as the Latham appliance and 38% used NAM.[12] In another large survey study of North American cleft surgeons regarding bilateral cleft lip repair, 39% used NAM, while only ~9% used an active device (e.g., Latham appliance).[13]

NAM involves molding of the maxillary segments by incremental adjustments of the oral appliance and nasal soft tissue expansion with nasal stents fixed to the appliance. This appliance allows the maxillary segments and the nasal alar cartilages to be brought to a more favorable position. Additionally, the nasal stents encourage approximation of the lip segments, elongation of the columella, and expansion of the nasal mucosal lining.[10] These changes have been objectively quantified as positive changes in nasal aesthetics.[14] This technique is supported by the demonstration of moldability of neonatal auricular deformities by Matsuo et al.[15] NAM is most effective shortly after birth to adapt the pliability of these tissues. Some believe that circulating maternal hormones in the newborn potentiate the molding of the nasal cartilages by making it more elastic.[16] Children treated with NAM within 1 month of life achieve more improvements compared with children treated later in life.[17] Using this modality requires substantial commitment and compliance from caregivers of a child, as the mold is worn full time with weekly or biweekly adjustments by an orthodontist until the cleft segments are narrowed to at least 5mm. Once this goal has been achieved, nasal prongs are added to the appliance to contact the dome to extend the columella. Parental compliance is improved by establishing trust and open shared

decision-making, so that they will be comfortable with dealing with difficulties like appliances causing irritation, ulcerations, and bleeding.[18]

Systematic reviews are equivocal on the effectiveness of NAM. Proponents[19] and opponents[20,21] have failed to reach a consensus, partially due to protocol and technical differences among institutions. Other factors involve the differences in baseline patient characteristics, limited number of high-level studies, and lack of clear objective outcome measures.

The major arguments against NAM are based on (1) the possible inhibition of midface growth and (2) the potential relapse of the nasal changes. A recent retrospective cohort study of 56 consecutively treated children with unilateral cleft lip and palate treated with NAM protocol (mean age 8.6 years) versus 56 children not treated with NAM (mean age 9.7 years) did not find NAM to impact skeletal or soft tissue growth in school-aged children after comparing seven midface measurements between each group.[22] Liou et al followed the progressive changes of nasal symmetry after NAM in a 3-year follow-up study of 25 children and found that nasal asymmetry partially relapsed after a year, but remained stable at 2 and 3 years after NAM and primary cheiloplasty.[23] Similarly, in a larger study of 57 children who were followed for a year after NAM found that there was a relapse rate of 10% in nostril width, 20% in nostril height, and 4.7% in angle of the columella.[24] Some surgeons choose to slightly overcorrect during rhinoplasty to compensate for these potential relapses.[25]

Although there is substantial controversy regarding its benefits, studies have demonstrated that NAM reduced the need for secondary nasal surgeries with an associated decrease in overall cost.[26] Currently, the senior author (T.T.T.) partners with a cleft orthodontist to conduct NAM for the wider unilateral and bilateral cleft lip deformities. Other than the severity of the cleft, other factors used to screen these infants for NAM include the additional burdens to the family that may affect their compliance (e.g., long travel distances). Pretreatment education for the family caregivers is imperative.

Surgical Timing and Techniques

There are differing opinions about how to balance the extent (how much surgery) and timing for rhinoplasty in these patients. Over half of cleft surgeons perform some form of primary rhinoplasty in infancy.[13] The basic premise of using rhinoplasty techniques in infancy is to utilize the malleability of the nasal cartilages and soft tissues.[27] Proponents of primary cleft rhinoplasty suggest that primary treatment reduces the severity of the nasal deformity, reduces the number of revision surgeries required in adulthood, and may lessen psychosocial impact of deformity during development.[28–30]

Historically, cleft surgeons were influenced by animal studies that suggested that rhinoplasty (before full skeletal maturity) could induce long-term nasal growth inhibition due to disruption of nasal growth centers.[31] There is a lack of rigorous evidence pertaining to this clinical question. Anecdotal experience of the senior author (T.T.T.) and other reports suggest rhinoplasty can be safely performed. Midface and nasal growth have not been shown to be grossly affected after septal repositioning. Other advantages include improvement in nasal tip symmetry and less complex secondary procedure required.[30,32]

Primary Cleft Rhinoplasty

The overall goals of the primary cleft rhinoplasty are accurate positioning of the ala and nasal sill, nasal floor closure, repositioning the LLC, alar base repositioning, and increasing tip support. In the bilateral deformity, elongation of the columella and symmetric projection of the nasal tip with correction of columellar lining deficiency are distinct challenges. The extent of the primary rhinoplasty is debated as more extensive surgery may lead to significant scarring at the time of definitive rhinoplasty; however, proponents suggest it may reduce the severity of the final deformity at facial maturity. A balance is sought and in most cases, we would support at least some rhinoplasty to be performed at the time of the unilateral or bilateral cleft lip repair. We prefer a graded surgical technique based on the severity of the nasal deformity.

Intermediate Cleft Rhinoplasty

Intermediate rhinoplasty was named as a more traditional approach by surgeons who limited the primary rhinoplasty and delayed rhinoplasty until 4 to 10 years of age. We do not use a treatment algorithm for a rhinoplasty between primary and definitive rhinoplasty, but do offer these revision procedures. The indications for intermediate rhinoplasty involve the following situations: (1) severe septal deviation resulting in functional nasal obstruction, (2) severe alar deformities, and (3) when a child is facing severe psychological distress from their peers due to their nasal deformity. Children with orofacial cleft suffer the highest incidence of depression, anxiety, and negative peer-relationships around the ages 8 to 10 years.[33] This supports a tiered-approach with psychosocial support, counselling, and surgery used together within a multidisciplinary cleft and craniofacial team.

Again, the amount of surgery performed should be balanced with a preponderance of benefit and minimal harm. Ayeroff et al demonstrated improvement in nasal photomorphometric relationships for up to 3 years after intermediate component restoration for unilateral cleft nasal deformity.[34] Two suggested intervals for intermediate rhinoplasty include (1) age ~4 to 6 years to coincide with lip revision and (2) 8 to 12 years once orthodontia has been addressed and alveolar bone grafting complete to allow for a stable maxillary skeletal foundation.[35]

Definitive Rhinoplasty

Definitive cleft lip rhinoplasty is most often performed at or after skeletal maturity has been achieved. The long-standing aesthetic and functional outcomes of this rhinoplasty rely on a stable maxillary skeletal foundation. Ideally, the dentofacial proportions will be first addressed with alveolar bone grafting, orthodontic and in some cases orthognathic surgery.[36] During definitive rhinoplasty, the cleft surgeon may be more assertive with cartilage grafting and soft tissue rearrangement. This will usually include a more extensive septoplasty, nasal bone

osteotomies, and cartilage grafting.[37] The ultimate goal of definitive rhinoplasty is creation of lasting symmetry, definition of the nasal tip and base, relief of nasal obstruction, and correction of nasal scarring and webbing.[38]

Techniques

Primary Rhinoplasty in the Unilateral Cleft Nasal Deformity

Our approach to the rhinoplasty performed at the time of the unilateral cleft lip repair has evolved over the past 15 years. An inexperienced surgeon should use techniques that limit inadvertent downstream sequela and soft tissue scarring. Observing your own patients over the decades of growth is key to understanding what effects your technical choices have on the nose. In all cases, the alar base width is set with an "cinching suture," which runs from the anterior nasal spine/caudal septum to the base of the ala (►**Fig. 1** with caliper). The key structures to address during unilateral cleft lip rhinoplasty include the columella, dome, cleft side LLC, alar rim, and alar base. The approaches are all endonasal without external skin incisions, which historically were popular. Incisions chosen by some surgeons can include the marginal incision, inter-cartilaginous incision, or a reverse-U incision, with medial extension over the point of maximal alar hooding. In rare cases of severe nasal hooding, a Tajima reverse U rim incision is created on the cleft side and elliptical incision of soft tissue hooding.[39]

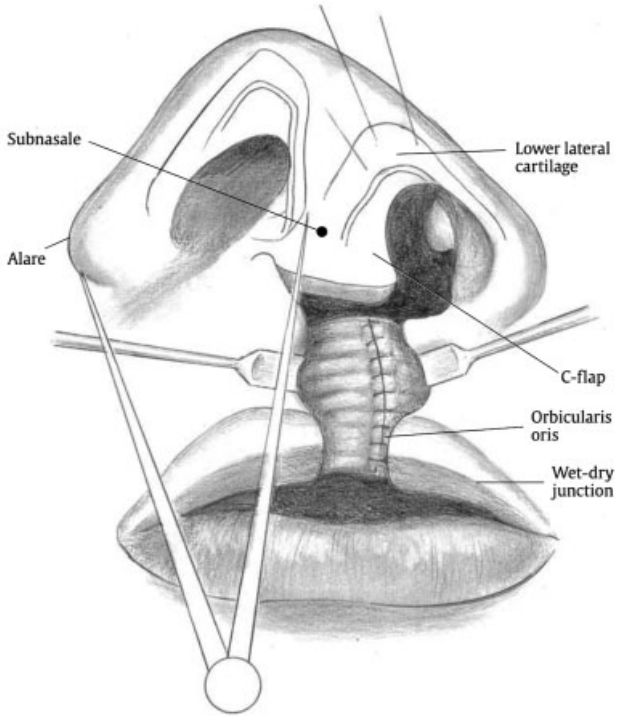

Fig. 1 Primary rhinoplasty showing the caliper that is used to measure the alar base width. The alar base suture and orbicularis oris muscle closure is imperative to create nasal symmetry. (Reproduced with permission from Tollefson TT, Sykes JM. Cleft lip repair: unilateral. In: Goudy SL, Tollefson TT, eds. Complete Cleft Care. New York: Thieme; 2015:55)

The senior author (T.T.T.) is a proponent of a conservative primary rhinoplasty during the cleft lip repair. In the unilateral lip repair, rounded tip scissors are placed under the columellar skin to meticulously dissect the LLCs from the skin soft tissue envelope of the nose (►**Fig. 2**). After release of the nasal cartilages from the overlying skin, retractors or forceps are used to push the cleft side LLC in a cephalad and medial position (►**Fig. 3**). While suspending these cartilages, two sets of sutures are placed through the vestibular lining of the nose to suspend the cartilage, which include (1) triangular fixation sutures of the ala and (2) interdomal sutures. These are placed from inside the nose using a resorbable 6–0 Monocryl suture (Ethicon Inc.) (►**Fig. 4**). Two or three of the triangular fixation sutures are placed by passing the needle from inside the nostril through the alar crease, and then back in the needle hole before tying inside the nose. The knots are cut short to

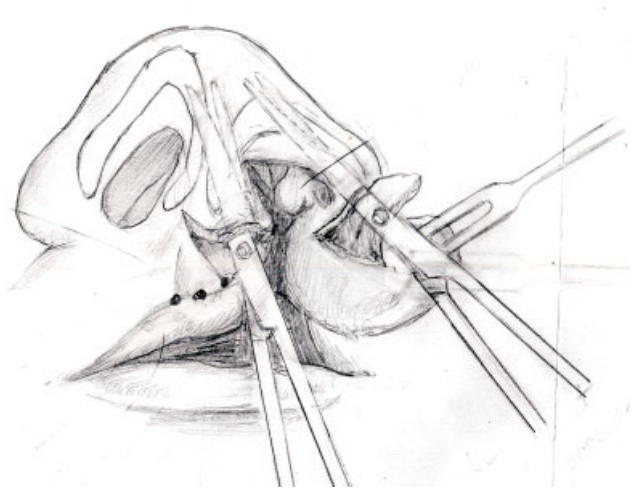

Fig. 2 Primary rhinoplasty rounded tip scissors placed under columellar skin to dissect the lower lateral cartilages from the skin soft tissue envelope of the nose. (Reproduced with permission from Tollefson TT, Sykes JM. Primary cleft rhinoplasty and gingivoperiosteoplasty. In: Goudy SL, Tollefson TT, eds. Complete Cleft Care. New York: Thieme; 2015:86)

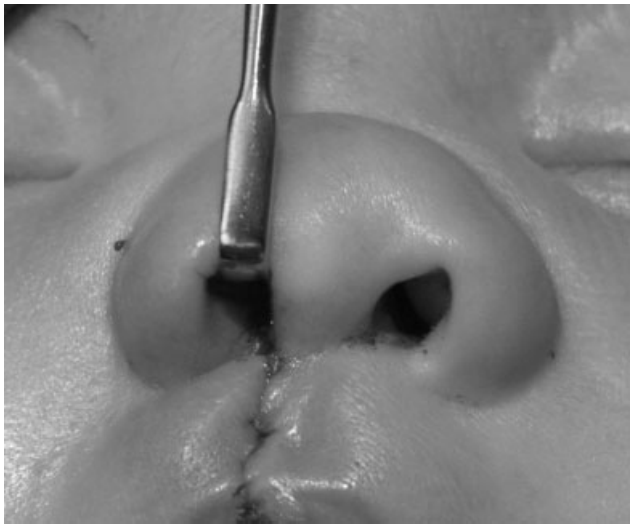

Fig. 3 After release of the nasal cartilages from the overlying skin, a Ragnal retractor or Brown forceps are used push the cleft side lower lateral cartilage (LLC) in a cephalad and medial position. The intradomal and alar resorbable sutures are placed while positioning the LLCs.

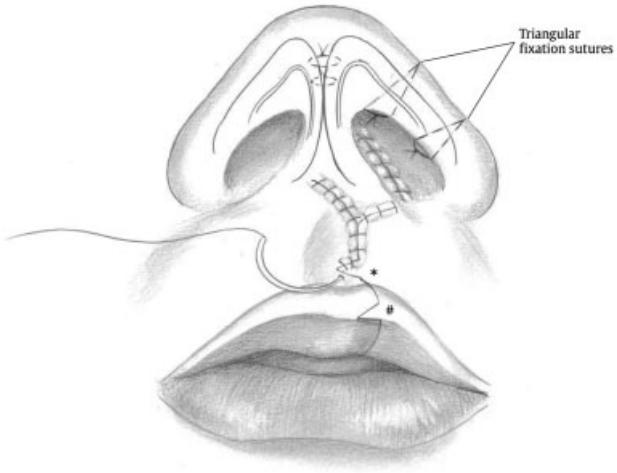

Fig. 4 Triangular fixation sutures (6–0 Monocryl) are placed through the ala and interdomal sutures are shown. The lip closure shown is a rotation-advancement technique with two small triangle flaps at the cutaneous roll and dry vermillion junction. (Reproduced with permission from Tollefson TT, Sykes JM. Cleft lip repair: unilateral. In: Goudy SL, Tollefson TT, eds. Complete Cleft Care. New York: Thieme; 2015:56)

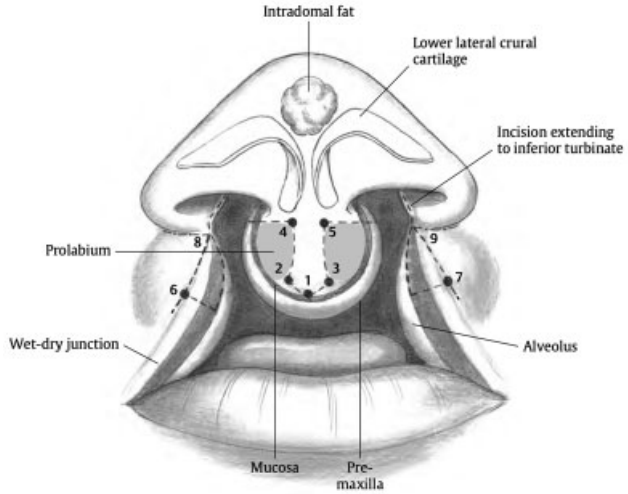

Fig. 5 Bilateral cleft lip nasal deformity showcasing maxillary bony deficiency, more inferiorly and posterolateral positioning of the alar bases, under-projected and broad nasal tip, and short columella. (Reproduced with permission from Tollefson TT, Senders CW. Cleft lip repair: bilateral. In: Goudy SL, Tollefson TT, eds. Complete Cleft Care. New York: Thieme; 2015:74)

promote early resorption and to minimize the relative frequency of suture abscesses that were more common when braided Vicryl (Ethicon Inc.) was used. The interdomal sutures can be placed in the same fashion through the nasal vestibular lining with the knot tied externally, or submucosally using a longer lasting 5–0 polydioxanone suture.[40]

Primary Rhinoplasty in the Bilateral Cleft Nasal Deformity

Bilateral cleft lip nasal deformity tends to be more symmetric but includes many of the similar features of the unilateral deformity. In bilateral cleft lip nasal deformity, it is important to consider the maxillary bony deficiency, more inferiorly and posterolateral positioning of the alar bases, under-projected and broad nasal tip, and short columella (►**Fig. 5**). Additionally, surgeons must be cognizant of the unique risk of pro-labium and columellar necrosis if there is extensive soft tissue dissection bilaterally that may compromise blood supply. For primary bilateral cleft nasal deformity, the senior author (T.T.T.) begins with bilateral partial marginal incisions to expose the nasal tip fat pad, which is freed and passed superiorly. The LLCs are subsequently sewn together in the midline with a 6–0 Monocryl to allow a lateral crural steal effect. The cephalic borders of the LLCs are secured cephalad onto the ULCs using a 5–0 polydioxanone suture on each side as described by Skoog.[41] In less than 10% of the cases, an elliptical excision of the soft tissue triangle hooding is performed using a Tajima's reverse U incision.

Postoperative Nasal Molding

Postoperative nasal stents are controversial, as there is a lack of high-level evidence to clearly demonstrate its role after cleft rhinoplasty. In a large survey study of cleft surgeons, ~54% of respondents incorporate postoperative molding into their practice.[12] It is hypothesized that nasal stents postoperatively oppose the memory of deformed cleft LLC and establishes an environment that gives the surgical wound the best chance of healing and less scar contracture thus resulting in improved nasal symmetry.[27,42] Yeow recommended use of a Koken postoperative nasal stents for at least 6 months after primary unilateral cleft rhinoplasty.[43] In this retrospective review, they reported improved nasal outcome after stenting as measured by nostril symmetry, alar cartilage slump, alar base level, and columellar tilt. However, to date no randomized clinical trials have supported efficacy. Currently, the senior author (T.T.T.) uses a silicone nasal conformer (size 3 or 4) for nearly all primary cleft lip repairs with rhinoplasty. These are secured with a 4–0 Prolene suture (Ethicon Inc.) placed through the stent and vestibular septum and the second pass coming anterior to the columella (for ease of cutting) when taking them out at 1 week (►**Fig. 6**).

Fig. 6 A silicone nasal conformer is shown secured with 4–0 Prolene suture placed through the stent and vestibular septum and the second pass coming anterior to the columella. (Note: tension on the columellar skin is minimized to prevent pressure necrosis.)

Grafting Materials for the Definitive Cleft Lip Rhinoplasty

The comprehensive management of the unilateral and bilateral cleft nose deformity inevitably requires cartilage grafting. Cartilaginous autografts (e.g., septal, ear, rib) may be harvested with their respective morbidity, and implemented as grafts such as the following: columellar strut, caudal septal extension graft, spreader graft, articulating rim graft, tip shield graft, lateral crural strut grafts, and onlay grafts for the middle and lower nasal thirds. The stability produced by these grafts increases when going from auricular cartilage to septal cartilage to septal bone (perpendicular plate) to rib grafts. Thus, the surgeon should choose the graft source wisely to fit the needs of the procedure.

In unilateral cleft lip and palate patients, Lu and Chen demonstrated that a primary septal cartilage rim graft resulted in better nostril height, height-to-width ratio, and nasal dome height compared with a nongrafted control patients without affecting future nasal growth.[44] While septal cartilage and auricular cartilage may allow for greater efficiency and minimizing number of surgical incisions (septal), autologous rib cartilage is abundant, resistant to the forces acting on the nose, and is often considered the gold standard cartilage graft due to its durability and strength.[45] Regardless of the donor site, cartilage of all forms is subject to unpredictable resorption, curling, and chance of dislocation. However, Lopez et al demonstrated that large costal cartilage grafts harvested from the central portion of the rib resulted in less warping in a porcine model.[45] Despite the durability of rib cartilage, complications may occur including pain, scarring, pneumothorax, infection, and increased surgical time. Allogeneic rib cartilage is an option in patients who warrant the strength of rib cartilage yet wish to avoid donor site morbidity.[46]

Shortcomings of rib cartilage grafts include calcification of cartilage that makes harvest and sculpting more challenging. Cartilage from younger patients has a propensity to warp, while older patients may be more calcified. In mild-to-moderate cleft nasal deformities cases, the LLC may be reasonably repaired with auricular or septal cartilage; however, major dorsal augmentation will likely require costal cartilage. Rim grafts improve appearance of the alar margin and prevent alar rim collapse. The final choice of graft donor site and placement depends on each patient's unique characteristics and a preoperative evaluation of patient factors and wishes. The following cases will emphasize some of these principles.

Cases

Case 1: Primary Unilateral Cleft Lip Rhinoplasty

The priorities of presurgical treatment of a child with unilateral cleft lip and palate are to expand the soft tissues of the nasal columella after contouring the maxillary arches with an orthodontic appliance. NAM began at 2 weeks of age. The family is screened with a detailed discussion to prepare them for the routine clinical visits and the importance of parental compliance. Prior to NAM, photographs are obtained (►**Fig. 7A** and **B**) and taping of the lip is taught to the parents. The oral appliance is created from an impression of the infant's maxilla (►**Fig. 8**). Our specialized cleft orthodontist conducts regular adjustments and fittings of the appliance. The nasal wires are added weeks later to shape the nostril. After several months of NAM treatment, the cleft lip repair (►**Fig. 9**) proceeds with a modified hybrid subunit technique with primary rhinoplasty. Bilateral LLCs are released from the skin-soft tissue envelope using rounded tip scissor dissection (►**Fig. 10** shown in highlighted area). The LLCs are then retracted (shown in ►**Fig. 3**) and several interdomal and alar triangular fixation sutures are placed. It has been our practice to use a silicone nostril conformer (usually size 3 or 4) in the nostrils at the end of the surgery. Parents tape the stent into place for 4 to 6 weeks after the surgery (►**Fig. 6**). The rhinoplasty outcome is reasonable (►**Fig. 11**) and will often be treated definitively after possible orthognathic surgery at full skeletal growth. These children's dentofacial appearances should be addressed with a multidisciplinary

Fig. 7 Primary rhinoplasty at the time of cleft lip repair is illustrated in this infant who presented with unilateral cleft lip and palate. (**A**) Frontal and (**B**) base view, showing a very wide unilateral cleft lip and palate with a severe nasal deformity.

Fig. 8 The impression of the maxilla is taken from the infant by our cleft orthodontist, who then delivers the nasoalveolar molding appliance to shape the nostril and elongate the columella.

Fig. 9 After several months of nasoalveolar molding treatment, cleft lip with repair is completed by modified hybrid subunit technique with primary rhinoplasty.

team with expertise in not only rhinoplasty but also maxillofacial surgery and dentistry.

Case 2: Definitive Cleft Lip Rhinoplasty

This 18-year-old patient with unilateral left cleft lip and palate had repair of the lip in infancy. She notes that the nostril on the cleft side is posteriorly displaced and the tip projection is inadequate. She has left alar hooding present as shown in ►**Fig. 12**. Orthognathic surgery and treatment of dentofacial abnormalities should be completed or ruled out prior to rhinoplasty. The LLC on the cleft side is dysmorphic but not usually hypoplastic. The caudal septum is deviated to the noncleft side contributing to tip and nostril asymmetry.

This patient shows poor tip projection with a dorsal profile that can appear to have a larger hump proportionally. Computer simulation software can be effective at improving patient communication regarding the profile changes (►**Fig. 13**). Conservative dorsal reduction and increased nasal tip projection can address this aspect.

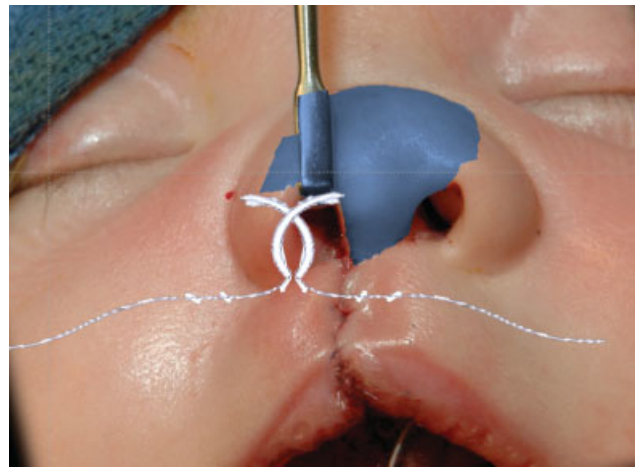

Fig. 10 The skin soft tissue is dissected from the underlying lower lateral cartilages (shown in highlighted blue area). Two needles are shown to illustrate the interdomal and triangular fixation sutures with the knots of the resorbable 6–0 Monocryl suture inside the nostrils. The retractor is used to position the lower lateral cartilages.

Fig. 11 Photograph of infant 3 months after the cleft lip repair and rhinoplasty.

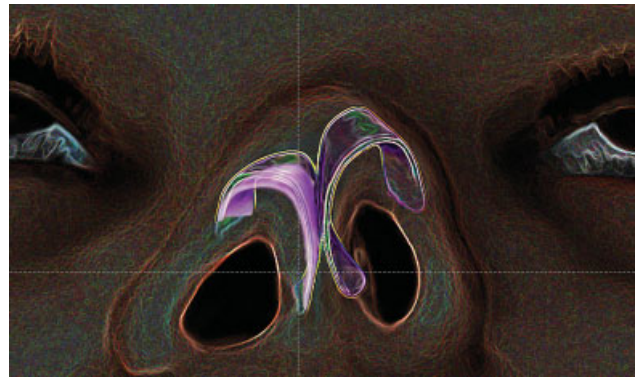

Fig. 12 A diagrammatic view of the right lower lateral cartilage as seen in the unilateral cleft lip nasal deformity (see ►**Table 1** for characteristics).

Symmetry of the lower third usually requires rigid cartilage grafting and suture suspension techniques (►**Fig. 14**). The upper lateral cartilages curve along with the dorsal-most septum. By dividing the upper lateral cartilages from the septum, two goals can be achieved: (1) the septum can be

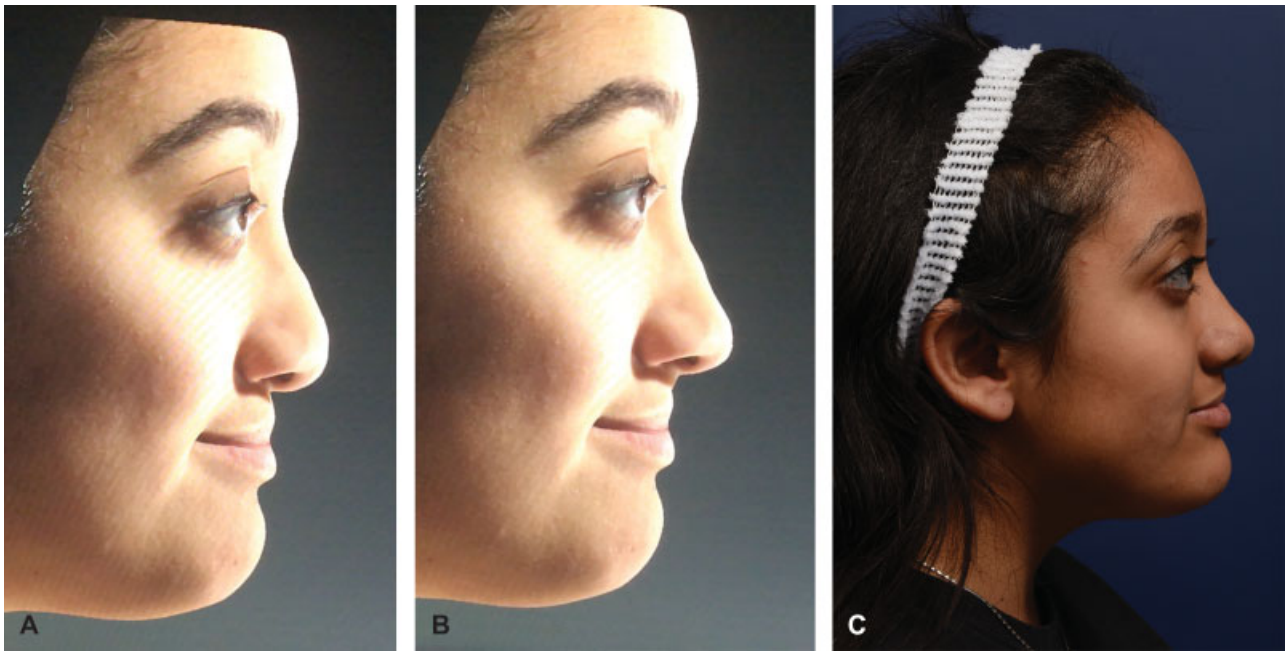

Fig. 13 Patient with repaired left unilateral cleft lip and palate showing the alar hooding, tip fullness, and lack of projection in computer morphing software: (**A**) preoperative profile, (**B**) computerized morphing of increased projection and dorsal reduction, (**C**) postoperative rhinoplasty outcome.

released from the mucoperiosteal flaps through the open septorhinoplasty approach and (2) asymmetric spreader grafts (►**Fig. 15**) can be applied into these spaces to correct the alignment of the middle nasal vault.

A thickened nasal tip soft tissue envelope can mask tip definition (►**Fig. 16**). The alar base on the cleft side is most-often deficient and inferior-laterally displaced. A variety of subnasal grafting materials can be used; however, the senior author (T.T.T.) prefers to use autologous materials from the septum, ear, rib, or autologous fat grafts (in that order). This case illustrates the difficulty of creating adequate tip definition and nasal straightening.

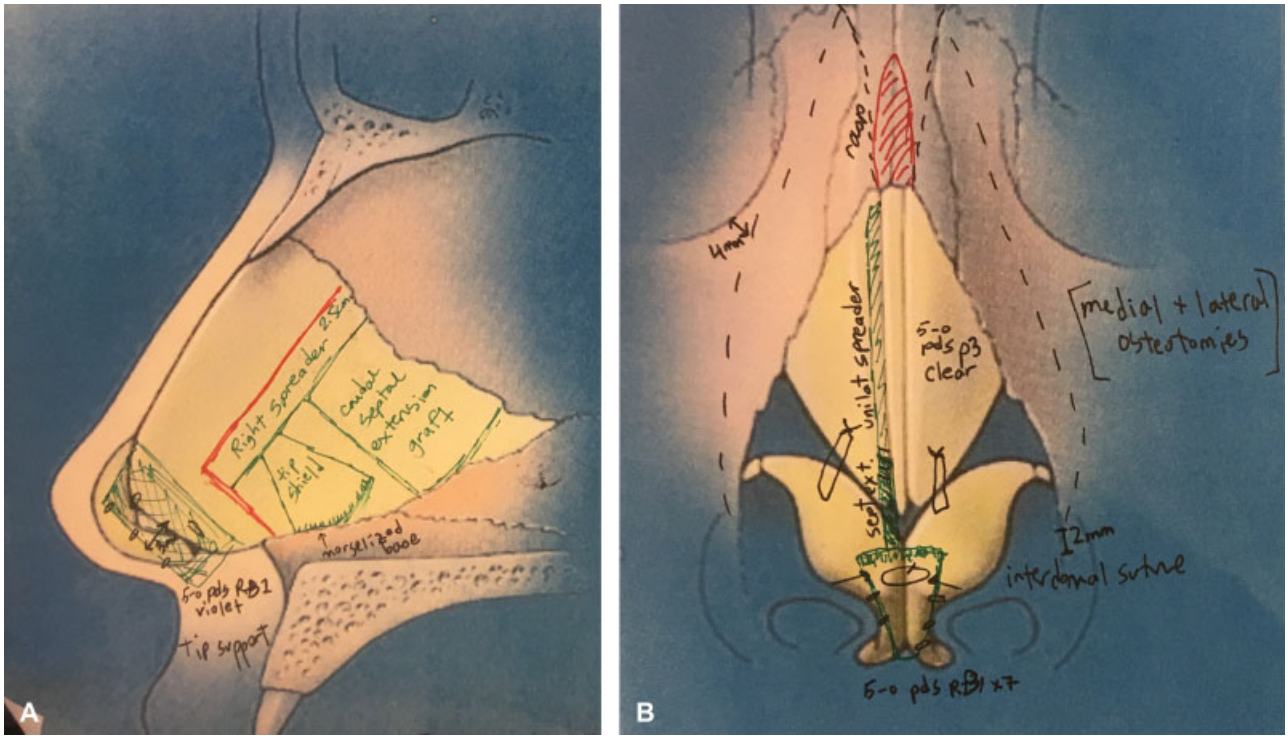

Fig. 14 The rhinoplasty plan is outlined in the (**A**) profile and (**B**) frontal view diagram showing the grafts from the septum marked for use in the rhinoplasty, the caudal septal extension graft and extended spreader grafting, and the premaxillary grafting with morcelized cartilage.

Fig. 15 Intraoperative view of the large extended spreader grafts placed between the upper lateral cartilage and septum. These are secured to the caudal septal extension graft (SEG) to create tip stability. The medial crus of the lower lateral cartilages are then secured to the SEG in a tongue-in-groove fashion to increase tip support symmetrically.

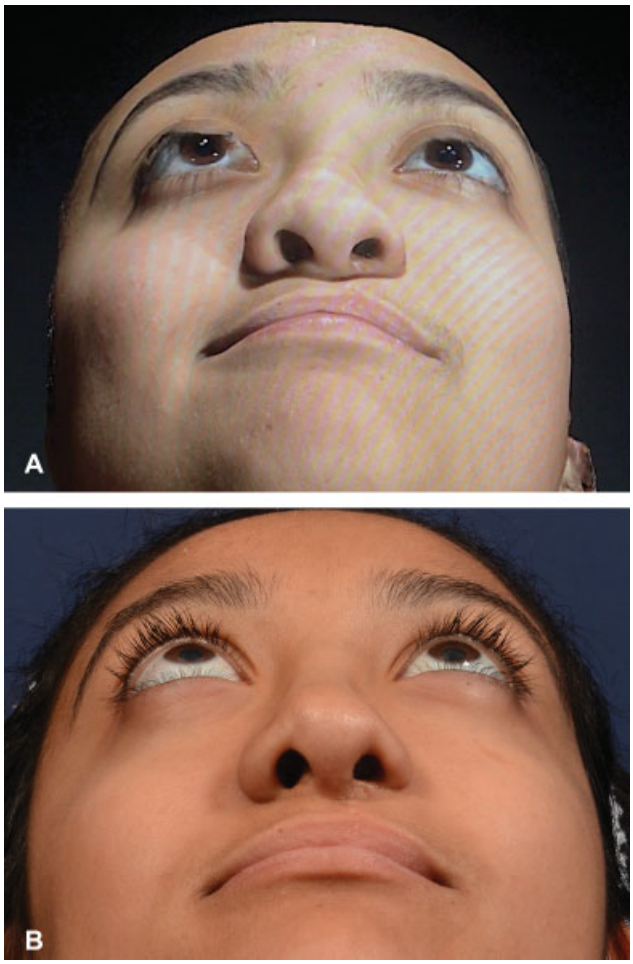

Fig. 16 Base view of the patient (**A**) preoperative and (**B**) postoperative, showing the alar base and premaxillary grafting, nasal tip projection, and added definition to the nasal tip and ala. **Note residual nasal deviation of the upper and middle 1/3 of the nose.

Conclusion

Cleft surgeons are challenged by variabilities of the anatomy, scarring, and soft tissue changes of the nose treated for a cleft lip–palate. Many consider these the most technically challenging rhinoplasty procedures. Fundamental anatomic features are present for the unilateral and bilateral cleft lip nasal deformity, which allow for surgical planning, but require adaptation for each patient. A multidisciplinary approach allows for the dentofacial aspects and soft tissue surgical strategy to be devised. Specialized cleft orthodontists can prepare the infant lip and nose prior to the primary lip and nose repair. Most surgeons perform a primary rhinoplasty at the time of the cleft lip repair. Postoperative molding is controversial due to a lack of high-level evidence, but several case series suggest that it is well tolerated, and may provide additional benefit with wound healing and scarring. Intermediate rhinoplasties are less common, but may be influenced by nasal obstruction or bullying in this sensitive age-group. Durable results after definitive rhinoplasty performed at the time of skeletal maturity usually require cartilage grafting from the septum, auricle, or rib to optimize form and function. It is often necessary to employ various techniques to achieve successful cosmetic and functional outcomes for patients with cleft lip and palate. There is a need for high-quality randomized controlled trials with standardized outcome measures to guide cleft surgeons in their pursuit of giving children the best results.

Disclosures
None.

Funding
None.

Conflicts of Interest
None.

References

1 Stark HL, Fries CA, Mercer NS. Translational techniques from cleft to cosmetic rhinoplasty. Arch Plast Surg 2019
2 Cuzalina A, Jung C. Rhinoplasty for the cleft lip and palate patient. Oral Maxillofac Surg Clin North Am 2016;28(02):189–202
3 Murray JC. Gene/environment causes of cleft lip and/or palate. Clin Genet 2002;61(04):248–256
4 Wyszynski DF, Beaty TH, Maestri NE. Genetics of nonsyndromic oral clefts revisited. Cleft Palate Craniofac J 1996;33(05):406–417
5 Tollefson TT, Shaye D, Durbin-Johnson B, Mehdezadeh O, Mahomva L, Chidzonga M. Cleft lip-cleft palate in Zimbabwe: estimating the distribution of the surgical burden of disease using geographic information systems. Laryngoscope 2015;125(Suppl 1):S1–S14
6 Cho BC, Baik BS. Correction of cleft lip nasal deformity in Orientals using a refined reverse-U incision and V-Y plasty. Br J Plast Surg 2001;54(07):588–596
7 Hsieh TY, Dedhia R, Del Toro D, Tollefson TT. Cleft septorhinoplasty: form and function. Facial Plast Surg Clin North Am 2017; 25(02):223–238
8 McNEIL CK. Orthodontic procedures in the treatment of congenital cleft palate. Dent Rec (London) 1950;70(05):126–132
9 Latham RA. Orthopedic advancement of the cleft maxillary segment: a preliminary report. Cleft Palate J 1980;17(03):227–233

10 Grayson BH, Cutting C, Wood R. Preoperative columella lengthening in bilateral cleft lip and palate. Plast Reconstr Surg 1993;92 (07):1422–1423
11 Grayson BH, Cutting CB. Presurgical nasoalveolar orthopedic molding in primary correction of the nose, lip, and alveolus of infants born with unilateral and bilateral clefts. Cleft Palate Craniofac J 2001;38 (03):193–198
12 Sitzman TJ, Girotto JA, Marcus JR. Current surgical practices in cleft care: unilateral cleft lip repair. Plast Reconstr Surg 2008;121 (05):261e–270e
13 Tan SP, Greene AK, Mulliken JB. Current surgical management of bilateral cleft lip in North America. Plast Reconstr Surg 2012;129 (06):1347–1355
14 Ahmed MK, Bui AH, Barnett R, Rousso JJ. Quantitative evaluation of nasolabial alterations following nasoalveolar molding (NAM) therapy in patients with unilateral cleft lip. Facial Plast Surg 2019; 35(01):73–77
15 Matsuo K, Hirose T, Tomono T, et al. Nonsurgical correction of congenital auricular deformities in the early neonate: a preliminary report. Plast Reconstr Surg 1984;73(01):38–51
16 Singh GD, Moxham BJ, Langley MS, Waddington RJ, Embery G. Changes in the composition of glycosaminoglycans during normal palatogenesis in the rat. Arch Oral Biol 1994;39(05):401–407
17 Shetty V, Vyas HJ, Sharma SM, Sailer HF. A comparison of results using nasoalveolar moulding in cleft infants treated within 1 month of life versus those treated after this period: development of a new protocol. Int J Oral Maxillofac Surg 2012;41(01):28–36
18 Levy-Bercowski D, Abreu A, DeLeon E, et al. Complications and solutions in presurgical nasoalveolar molding therapy. Cleft Palate Craniofac J 2009;46(05):521–528
19 Maillard S, Retrouvey JM, Ahmed MK, Taub PJ. Correlation between nasoalveolar molding and surgical, aesthetic, functional and socioeconomic outcomes following primary repair surgery: a systematic review. J Oral Maxillofac Res 2017;8(03):e2
20 Abbott MM, Meara JG. Nasoalveolar molding in cleft care: is it efficacious? Plast Reconstr Surg 2012;130(03):659–666
21 van der Heijden P, Dijkstra PU, Stellingsma C, van der Laan BF, Korsten-Meijer AG, Goorhuis-Brouwer SM. Limited evidence for the effect of presurgical nasoalveolar molding in unilateral cleft on nasal symmetry: a call for unified research. Plast Reconstr Surg 2013;131(01):62e–71e
22 Rubin MS, Clouston SAP, Esenlik E, Shetye PR, Flores RL, Grayson BH. Midface growth in patients with unilateral cleft lip and palate treated with a nasoalveolar molding protocol. J Craniofac Surg 2019;30(06):1640–1643
23 Liou EJ, Subramanian M, Chen PK, Huang CS. The progressive changes of nasal symmetry and growth after nasoalveolar molding: a three-year follow-up study. Plast Reconstr Surg 2004;114 (04):858–864
24 Pai BC, Ko EW, Huang CS, Liou EJ. Symmetry of the nose after presurgical nasoalveolar molding in infants with unilateral cleft lip and palate: a preliminary study. Cleft Palate Craniofac J 2005;42(06): 658–663
25 Chang CS, Por YC, Liou EJ, Chang CJ, Chen PK, Noordhoff MS. Long-term comparison of four techniques for obtaining nasal symmetry in unilateral complete cleft lip patients: a single surgeon's experience. Plast Reconstr Surg 2010;126(04):1276–1284
26 Patel PA, Rubin MS, Clouston S, et al. Comparative study of early secondary nasal revisions and costs in patients with clefts treated with and without nasoalveolar molding. J Craniofac Surg 2015;26(04):1229–1233
27 Matsuo K, Hirose T, Otagiri T, Norose N. Repair of cleft lip with nonsurgical correction of nasal deformity in the early neonatal period. Plast Reconstr Surg 1989;83(01):25–31
28 Brussé CA, Van der Werff JF, Stevens HP, et al. Symmetry and morbidity assessment of unilateral complete cleft lip nose corrected with or without primary nasal correction. Cleft Palate Craniofac J 1999;36(04):361–366
29 Anderl H. Unilateral cleft lip nose. Plast Reconstr Surg 1987;79 (04):661–662
30 Haddock NT, McRae MH, Cutting CB. Long-term effect of primary cleft rhinoplasty on secondary cleft rhinoplasty in patients with unilateral cleft lip-cleft palate. Plast Reconstr Surg 2012;129(03): 740–748
31 Sarnat BG, Wexler MR. Growth of the face and jaws after resection of the septal cartilage in the rabbit. Am J Anat 1966;118(03): 755–767
32 McComb HK, Coghlan BA. Primary repair of the unilateral cleft lip nose: completion of a longitudinal study. Cleft Palate Craniofac J 1996;33(01):23–30, discussion 30–31
33 Volpicelli EJ, Pfaff MJ, Hakimi K, Bradley JP, Solem RC, Lee JC. Age-related differences in psychosocial function of children with craniofacial anomalies. Plast Reconstr Surg 2017;140(04):776–784
34 Ayeroff JR, Volpicelli EJ, Mandelbaum RS, et al. Component restoration in the unilateral intermediate cleft tip rhinoplasty: technique and long-term outcomes. Plast Reconstr Surg 2019;143 (03):572e–580e
35 Wang TD. Secondary rhinoplasty in unilateral cleft nasal deformity. Clin Plast Surg 2010;37(02):383–387
36 Cutting CB. Secondary cleft lip nasal reconstruction: state of the art. Cleft Palate Craniofac J 2000;37(06):538–541
37 Pawar SS, Wang TD. Secondary cleft rhinoplasty. JAMA Facial Plast Surg 2014;16(01):58–63
38 Shih CW, Sykes JM. Correction of the cleft-lip nasal deformity. Facial Plast Surg 2002;18(04):253–262
39 Tajima S, Maruyama M. Reverse-U incision for secondary repair of cleft lip nose. Plast Reconstr Surg 1977;60(02):256–261
40 Bhuskute AA, Tollefson TT. Cleft lip repair, nasoalveolar molding, and primary cleft rhinoplasty. Facial Plast Surg Clin North Am 2016;24(04):453–466
41 Skoog T. A method of hump reduction in rhinoplasty. A technique for preservation of the nasal roof. Arch Otolaryngol 1966; 83:283–287
42 Greives MR, Camison L, Losee JE. Evidence-based medicine: unilateral cleft lip and nose repair. Plast Reconstr Surg 2014; 134(06):1372–1380
43 Yeow VK, Chen PK, Chen YR, Noordhoff SM. The use of nasal splints in the primary management of unilateral cleft nasal deformity. Plast Reconstr Surg 1999;103:1347–1354
44 Lu X, Chen G. Primary septal cartilage graft for the unilateral cleft rhinoplasty. Plast Reconstr Surg 2017;140:832e–835e
45 Lopez MA, Shah AR, Westine JG, O'Grady K, Toriumi DM. Analysis of the physical properties of costal cartilage in a porcine model. Arch Facial Plast Surg 2007;9(01):35–39
46 Read-Fuller AM, Yates DM, Radwan A, Schrodt AM, Finn RA. The use of allogeneic cartilage for grafting in functional and reconstructive rhinoplasty. J Oral Maxillofac Surg 2018;76(07):1560. e1–1560.e7