

Dual mobility cup in total hip arthroplasty. The experience of the university hospital

Acetábulo de dupla mobilidade na artroplastia total do quadril. A experiência de um hospital universitário

Raul Frankllim Carvalho Almeida¹ 

¹ Hip and Knee Surgery Group, Orthopedic and Traumatology Service, Hospital Universitário, Universidade Federal do Maranhão, São Luís, Maranhão, Brazil

Rev Bras Ortop 2020;55(6):708–714.

Address for correspondence Raul Frankllim Carvalho Almeida, Master, Chefe do Grupo de cirurgia do quadril e joelho, Serviço de Ortopedia e Traumatologia do Hospital Universitário da Universidade Federal do Maranhão (HU-UFMA), Rua Barão de Itapary, 270, 65020-070, Centro, São Luís, Maranhão, Brazil (e-mail: dr.raulalmeida@gmail.com).

Abstract

Keywords

- ▶ arthroplasty
- ▶ hip
- ▶ hip prosthesis
- ▶ dual mobility cup
- ▶ dislocation rate
- ▶ joint instability

Resumo

Objective To evaluate the incidence of prosthetic instability in a consecutive series of 42 cases of total hip arthroplasty using dual mobility cup.

Methods A retrospective study of 38 patients undergoing primary or revision total hip arthroplasty (THA) using the acetabular dual-mobility cup (DMC) implant between January 2012 and January 2018. The rates of complications and instability after surgery were evaluated.

Results In total, 42 arthroplasties were performed in 38 patients, with a minimum follow-up of 16 months. The mean age of the sample was 60 years. In 38 cases, we used a cementless DMC, and, in the other 4 cases, a cemented DMC. There were no cases of early or late instability.

Conclusion The present case series proves the good results of the DMC in primary THA and rTHA. The excellent survival rate and the absence of episodes of prosthetic instability increase the confidence in this concept.

Objetivo Avaliar a incidência de instabilidade protética em uma série consecutiva de 42 casos de artroplastia total do quadril com uso do acetábulo de dupla mobilidade (ADM).

Métodos Estudo retrospectivo de 39 pacientes que passaram por artroplastia total de quadril (ATQ) primária ou de revisão usando taça de dupla mobilidade dupla (TDM) acetabular entre janeiro de 2012 e janeiro de 2018. Foram avaliadas as taxas de complicações e de instabilidade após a cirurgia.

received
August 20, 2019
accepted
December 12, 2019

DOI <https://doi.org/10.1055/s-0040-1702951>.
ISSN 0102-3616.

Copyright © 2020 by Sociedade Brasileira de Ortopedia e Traumatologia. Published by Thieme Revinter Publicações Ltda, Rio de Janeiro, Brazil

License terms



Palavras-chave

- ▶ artroplastia
- ▶ quadril
- ▶ prótese de quadril
- ▶ taça de dupla mobilidade
- ▶ taxa de luxação
- ▶ instabilidade articular

Resultados Foram feitas 42 artroplastias em 38 pacientes, com um seguimento mínimo de 16 meses. A média de idade da amostra foi de 60 anos. Em 38 casos, usamos TDM sem cimento, e nos outros 4 casos, TDM cimentada. Não houve instabilidade precoce ou tardia.

Conclusão A série aqui apresentada prova os bons resultados do ADM em casos de ATQ primária ou rATQ. A excelente taxa de sobrevida e a ausência de episódios de instabilidade aumentam a nossa confiança nesse conceito.

Introduction

Total hip arthroplasty (THA) is one of the most clinically-successful and cost-effective interventions in health care of the last century.^{1,2} However, despite the continuous improvement in surgical technique and implant development, the overall revision THA (rTHA) rate remains unchanged, with instability review as the main cause.^{1,3}

Instability occurs in ~ 1% of cases of THA in the first month after surgery, and, after 1 year, the risk of dislocation increases at a linear rate to a cumulative risk of 7% after 20 years.^{4,5} The literature suggests that more than a half of all dislocations occur within the first 3 postoperative months,⁶ and more than 75% occur within 1 year.⁷ Instability after THA has a considerably negative effect on the quality of life, especially if it is recurrent.⁸

Several factors have been proposed to influence the stability of THA, but many questions remain unsolved.^{3,5,9} The instability may be classified according to the predisposing cause: factors related to the patient, to the surgical act, and factors intrinsic to the implant. Among the factors related to the patient, we can mention advanced age,^{3,7} American Society of Anesthesiologists (ASA) score ≥ 3 ,^{9,10} the female gender,^{9,11} femoral-neck fracture (FNF),^{3,9} osteonecrosis of the femoral head (ONFH),^{3,9,12} developmental dysplasia of the hip (DDH),⁹ neuromuscular disorders,^{6,9}

previous hip surgery,^{9,13} and rTHA.^{5,6} Among the factors related to the surgery are the orientation of the components,^{11,13} the surgical posterolateral approach,^{3,13-15} and the surgical volume.^{7,12,15} Among the factors intrinsic to the implant are the diameter of the femoral head and the head-neck ratio^{3,16} (► **Table 1**).

There is a little consensus on the best method to prevent and treat instability, particularly in high-risk patients.⁴

More than 40 years ago, Gilles Bousquet and his engineer André Rambert^{19,25} had the genius idea of marrying the concept of low-friction arthroplasty (LFA), developed by Sir John Charnley in 1972,¹⁷ and its longevity benefits to the large heads (metal-metal) of MacKee and Watson-Farrar,¹⁸ providing greater stability. In 1976, based on this concept, the idea of the dual-mobility cup (DMC) came to be¹⁹ (► **Fig. 1**).

The objective of the present study was to describe our experience with the use of the DMC in a series of cases, with a minimum follow-up of 16 months.

Materials and Methods

We performed a retrospective study of 38 patients undergoing THA or rTHA, in which acetabular DMC was used in the prevention or treatment of postoperative instability. The present study was approved by the Ethics in Research Committee of our Institution under the number 1,786,868.

Table 1 Risk factors for total hip arthroplasty instability

Patient	Surgeon	Implant
Advanced age ≥ 75 years	Orientation of the components	Femoral-head diameter
Female gender ≥ 70	Surgical volume	Head-neck ratio
American Society of Anesthesiologists score ≥ 3	Posterolateral approach	
Femoral-neck fracture		
Osteonecrosis of the femoral head		
Developmental dysplasia of the hip		
Neuromuscular disorders		
Prior hip surgery		
Revision total hip arthroplasty		

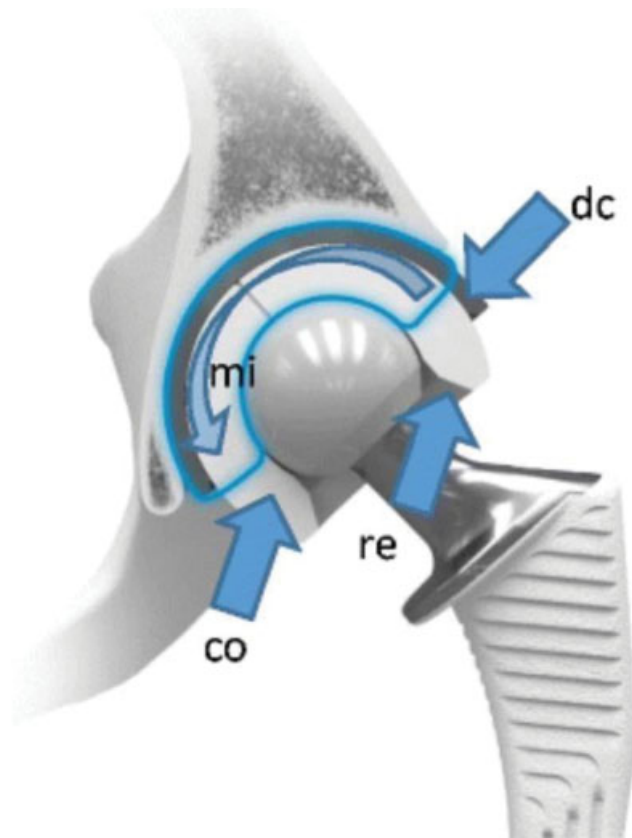


Fig. 1 Three-joint system: a socket, a free polyethylene liner and a head. Source: <https://link.springer.com/article/10.1007/s00264-017-3420-7>.

The study included consecutive cases of DMC implant performed at our institute from January 2012 to January 2018. All cases were submitted to the same surgery, through the posterolateral approach and under spinal an-

esthesia. We do not use a suction drain in the postoperative. All patients undergoing primary THA or rTHA with DMC were included.

The preoperative patient data were collected retrospectively and prospectively during the regular follow-up.

Results

Between January 2012 and January 2018, 42 arthroplasties were performed in 38 patients, with a minimum follow-up of 16 months. The mean age of the sample was 60 years old (range: 17–90 years). There were 21 (55.2%) males and 17 (44.8%) females. As for etiology, there were 14 (36.8%) procedures due to primary osteoarthritis, and 28 (73.2%) due to a variety of causes – 12 due to ONFH (2 due to alcohol abuse, 2 due to FNF, 3 posttraumatic, 2 due to sickle-cell anemia, 2 due to corticoid use, 1 due to radiotherapy); 5 due to an acute FNF in the elderly; 2 for rheumatoid arthritis; 2 for failure of the osteosynthesis in proximal femur fracture; 2 for pseudarthrosis of the femoral neck; 2 due to DDH; and 1 due to proximal femoral epiphysiolysis (PFE). There also were 3 cases of rTHA (1 case of instability; 1 case of aseptic loosening ;and 1 case of conversion of failed hemiarthroplasty to THA).

In 38 (90.4%) cases, we used cementless DMC (►Fig. 2), and in 4 (9.6%) cases, cemented DMC (►Fig. 3).

The preoperative demographic data are listed in ►Table 2.

The postoperative data collection included surgical side, surgical type of THR, cemented or cementless DMC, postoperative intensive care unit (ICU), length of stay (LOS) (in nights) after surgery, and average follow-up (►Table 3).

In the routine controls, we performed radiographs in the immediate postoperative period in all cases. In total, 2 patients (5.5%) were identified with stable periprosthetic fractures of the femur (Vancouver type B1), which were treated conservatively and successfully (►Fig. 4).

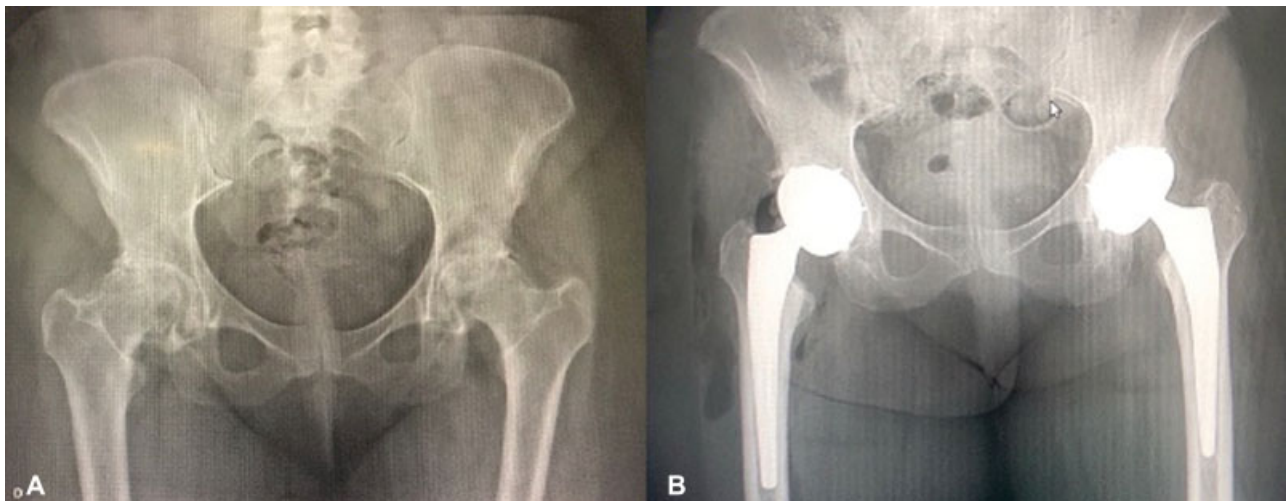


Fig. 2 Anteroposterior pelvic radiograph of a 45-year-old female, with bilateral osteonecrosis of the femoral head (ONFH) (A), and postoperative cementless bilateral dual-mobility cup (DMC) (B).

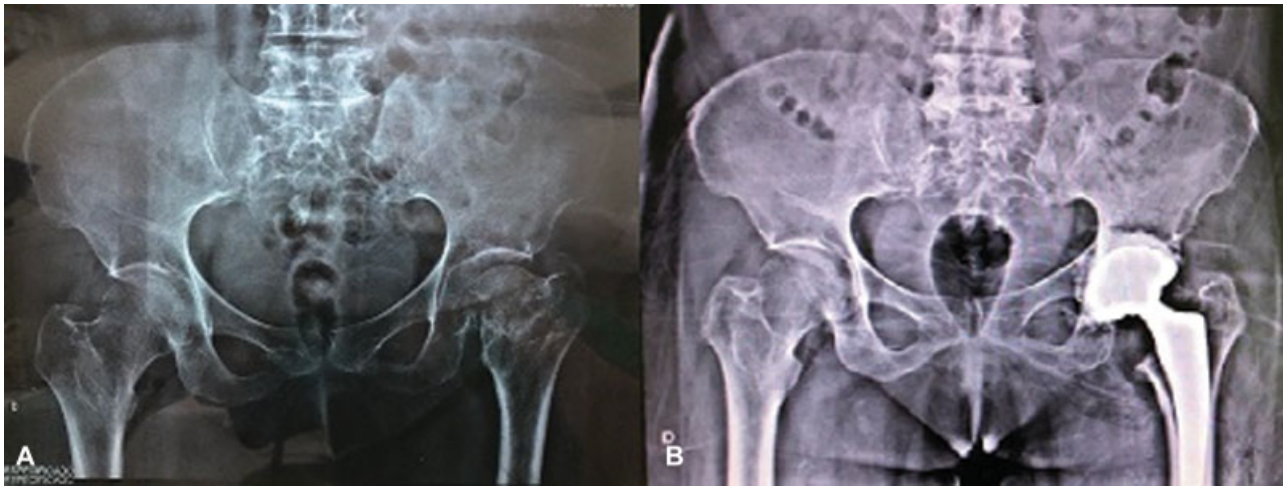


Fig. 3 Preoperative anteroposterior pelvic radiograph of a 69-year-old female with femoral neck pseudarthrosis (A), and postoperative cemented DMC (B).

Table 2 Preoperative patient demographics

Age	17–90 years
Gender	Male: 21 Female: 17
American Society of Anesthesiologists score	I: 5 II: 16 III: 19
Preoperative diagnosis	Primary osteoarthritis: 14 Osteonecrosis of the femoral head: 12 Acute femoral-neck fracture: 4 Osteosynthesis failure: 2 Revision total hip arthroplasty: 3 Rheumatoid arthritis: 2 Pseudoarthrosis of the femoral neck: 1 Developmental dysplasia of the hip: 1 Proximal femoral epiphysiolysis: 1

Table 3 Postoperative data

Surgical side	Right: 15 Left: 21 Bilateral: 3
Dual-mobility cup	Cemented: 4 Cementless: 38
Total hip arthroplasty	Primary: 39 Revision: 3
Blood transfusion	Yes: 19 No: 23
Intensive care unit	Yes: 20 No: 22
Length of stay (nights after surgery)	4
Average follow-up	12–74 months

Another patient presented partial paralysis of the fibular nerve, evolving with complete resolution after 8 postoperative weeks. There were no cases of postoperative deep venous thrombosis or infection.

There was a case of death after 2 years of surgery in a patient submitted to THR due to FNF. He was well since the surgery until the last evaluation.

Discussion

Total hip arthroplasty has been performed since the 1960s, and has significantly improved the quality of life of patients suffering from osteoarthritis of the hip.¹ However, despite the high success rate, instability after THA remains a problem that is difficult to manage for the patient and the surgeon.^{2–5}

Bozic et al.⁴ evaluated device failures in 51,345 rTHA procedures performed in the United States October 1, 2005, and December 31, 2006. The most common cause of rTHA was instability (22.5%). Revision due to dislocation accounted for 9% of all revisions of primary THAs in the Swedish Hip Arthroplasty Register. It is the second most common reason for revision.³ The Australian National Joint Replacement Registry reported a proportion of 26% rTHA due to dislocation in 2011.³ In contrast to the literature, the incidence of THA instability in France is the fifth cause of rTHA.^{9,20,21}

Dislocation after THA is multifactorial (► **Table 1**). The factors related to the patient are unchanging. However, the factors related to the choice of surgical approach and the type of implant involve the surgeon. Avoiding hip dislocation after THA is the best strategy. Over the past decade, we have seen an exponential increase in published articles on the use of THA with DMC. Many of these articles show very low dislocation rates, or even the absence of this complication.^{3,5,9,19–24} The DMC device was created in France in 1976 to increase the stability and enhance joint mobility with low-friction.¹⁹

We have been using the DMC since January 2012. Initially, we used it only in elderly patients with FNF and in patients at high risk for instability after THA. However, as we became more familiar with the technique, and acquired more knowledge on biomechanics and DMC principles, the indications were gradually extended. We currently

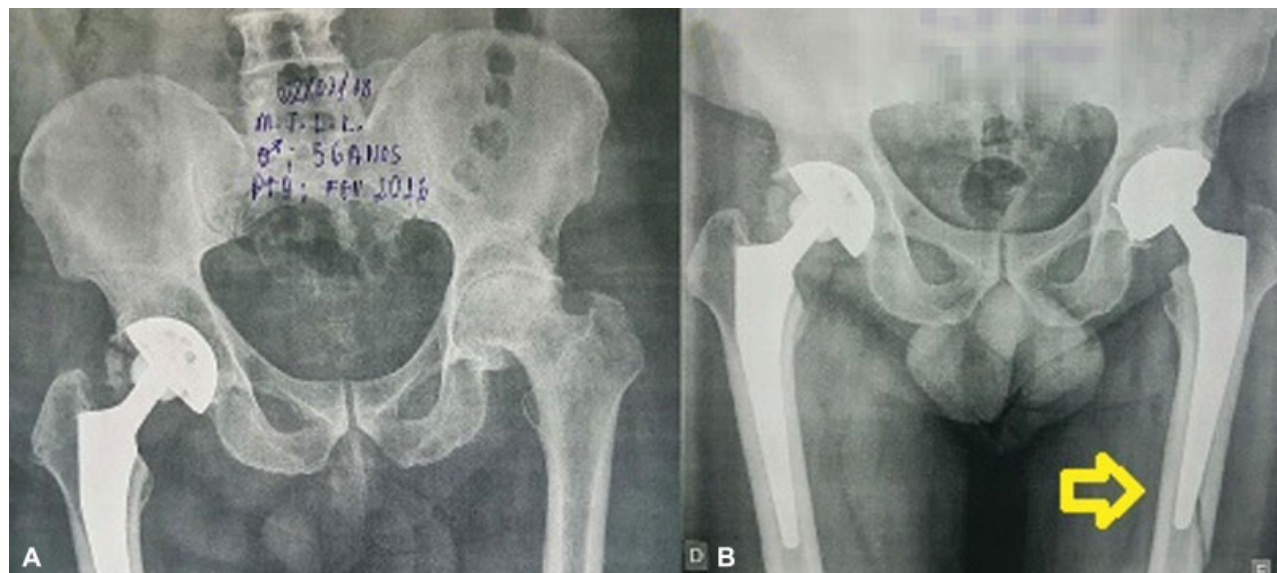


Fig. 4 Preoperative anteroposterior pelvic radiograph of a 56-year-old male with left-sided ONFH (A) and postoperative cemented DMC with stable Vancouver-type-B1 periprosthetic fracture of the femur (B). The fractures were conservatively and successfully treated.

recommend the DMC for patients of any age or with any diagnosis, as we have not observed any problems at follow-up. The absence of instability is confirmed by the results of the literature.^{16,24}

For Woo and Morrey,¹⁴ the risk of dislocation is 2 times greater for women when compared with men. Coventry¹¹ observed that this rate was 3 times greater for women when compared with men 5 years after surgery. For Bozic et al.,⁴ rTHA procedures were most commonly reported in the age group between 75 and 84 years (27.0%). For Guyen et al.,⁹ gender alone is not enough to indicate the systematic use of the DMC device. They considered the female gender a risk factor for dislocation, when associated with ages 70 years or older. In this study, there were 17 females. The ASA score has been identified as a good risk for the dislocation variable, because it is closely-related to multisystem disease that increases with age and complicates muscle recovery. The authors observed that scores ≥ 3 meant a significant risk for dislocation.¹⁰ In the present study, 42.8% (19) of the patients had ASA scores ≥ 3 . All patients had a good evolution.

In 10,500 conventional THAs performed at the Mayo Clinic, 331 (3.2%) cases of instability were observed. Cross correlations of the data were performed, using multivariate analysis. The dislocation rate was of 2.3% after an anterolateral approach, and of 5.8 percent after a posterolateral approach.¹⁴ The demographic factors, the operative approach, and the femoral-head diameter were analyzed to determine their effect on the risk of a first-time dislocation in 21,047 primary THAs. The cumulative 10-year rate of dislocation was of 3.1% following anterolateral approaches, and of 6.9% following posterolateral approaches.¹⁶ In a case-control study of 213 hips, no dislocations were found in primary THAs using a posterior approach, whereas 5 dis-

locations occurred in patients operated with a conventional 28-mm metal head.²⁰ All cases in these series were treated by the posterolateral approach with DMC and 28-mm metal heads. There were no cases of instability.

Another group with risk of instability are the patients previously operated on the hip.^{4,9,12,14} In the case of complex THAs, the dislocation rate ranged from 5% to 30% because of the bone loss and the compromised muscles and soft tissues around the hips.¹⁶ The use of DMC in cases of complex THA has shown a dislocation rate from 1% to 10% at an 8-year follow-up.²⁵ In the present study, there were 7 (16.6%) cases of THA in patients with previous hip surgery, including 2 cases (5.5%) of osteosynthesis failure in proximal femur fractures. In all cases, there was a good evolution.

The reported incidence of dislocation after rTHA is as high as 22.5% to 39%,⁴⁻⁶ and in some cases a new revision surgery is an inevitable procedure, particularly in patients with multiples risk factors for instability. The best strategy is the adequate choice of surgical approach and implants for the prevention of trouble in the future.⁵ In the present study, there was only one case of rTHA due to instability. However, this patient had several risk factors to evolve with instability after the new rTHA procedure. The patient was female, had rheumatoid arthritis, was using corticosteroids, had a history of alcohol abuse, had already been operated on three times, and had a low muscle reserve and low bone stock. A metal DMC was cemented into a well-fixed acetabular shell. This is another advantage of the DMC device: it is versatile. The patient had a good evolution, without instability.

In many studies, the diagnosis of FNF is associated with an increased risk of rTHA due to dislocation.^{3,9,12} Lu-Yao et al. found a dislocation rate of 10.7% in patients with FNF treated

with THA.²⁶ Tarasevicius et al.²³ compared DMC implants with conventional THA for FNF treatment. After 1 year of postoperative follow-up, no dislocations were reported in the DMC group, compared with 8 (14.3%) dislocations in the conventional THA group. In a similar study, Adam et al.²⁷ reported 3 (1.4%) dislocations at a 9-month follow-up in 214 patients treated with DMC due to FNF. There were no cases of instability in this sample.

Although the medical literature presents robust evidence regarding the safety of the DMC system in the prevention of instability, we have observed two major problems: Intra-prosthetic dislocation (IPD) and implant survival in younger patients. Dislocation is a specific complication found in cases of DMC implantation, and it is induced by the loss of the polyethylene retaining edge, resulting in the separation of the femoral head from the polyethylene lining. However, the articles^{9,19,28} show that this complication occurred with the first-generation 22-mm head implants and traditional polyethylene. Based on the design of the implant, the IPD rates may vary from 1.9% to 5.2% regarding the older generation of DMC models, with a median follow-up of 4 to 17 years.²⁸ Currently, this complication is rare with the use of cross-linked polyethylene associated with the use of 28-mm heads.^{24,29} Regarding implant survival in younger patients, there are numerous studies showing similar survival rates as those of conventional implants.^{3,5,19,20,22,24,25,27} There were no cases of dislocation or wear in the present case series.

The statistical power of the present study is certainly limited by the small sample size.

Conclusion

The present case series proves the good results of the DMC in primary THA and rTHA. The excellent survival rate and the absence of episodes of prosthetic instability increase the confidence in this concept.

Conflict of Interests

The authors have none conflict of interests to declare.

References

- Learmonth ID, Young C, Rorabeck C. The operation of the century: total hip replacement. *Lancet* 2007;370(9597):1508–1519
- Kurtz S, Ong K, Lau E, Mowat F, Halpern M. Projections of primary and revision hip and knee arthroplasty in the United States from 2005 to 2030. *J Bone Joint Surg Am* 2007;89(04):780–785
- Hailer NP, Weiss RJ, Stark A, Kärrholm J. The risk of revision due to dislocation after total hip arthroplasty depends on surgical approach, femoral head size, sex, and primary diagnosis. An analysis of 78,098 operations in the Swedish Hip Arthroplasty Register. *Acta Orthop* 2012;83(05):442–448
- Bozic KJ, Kurtz SM, Lau E, Ong K, Vail TP, Berry DJ. The epidemiology of revision total hip arthroplasty in the United States. *J Bone Joint Surg Am* 2009;91(01):128–133
- Faldini C, Stefanini N, Fenga D, et al. How to prevent dislocation after revision total hip arthroplasty: a systematic review of the risk factors and a focus on treatment options. *J Orthop Traumatol* 2018;19(01):17
- Daly PJ, Morrey BF. Operative correction of an unstable total hip arthroplasty. *J Bone Joint Surg Am* 1992;74(09):1334–1343
- Meek RM, Allan DB, McPhillips G, Kerr L, Howie CR. Epidemiology of dislocation after total hip arthroplasty. *Clin Orthop Relat Res* 2006;447(447):9–18
- Enocson A, Pettersson H, Ponzer S, Törnkvist H, Dalén N, Tidermark J. Quality of life after dislocation of hip arthroplasty: a prospective cohort study on 319 patients with femoral neck fractures with a one-year follow-up. *Qual Life Res* 2009;18(09):1177–1184
- Guyen O, Chen QS, Bejui-Hugues J, Berry DJ, An KN. Unconstrained tripolar hip implants: effect on hip stability. *Clin Orthop Relat Res* 2007;455(455):202–208
- Jolles BM, Zangger P, Leyvraz PF. Factors predisposing to dislocation after primary total hip arthroplasty: a multivariate analysis. *J Arthroplasty* 2002;17(03):282–288
- Coventry MB. Late dislocations in patients with Charnley total hip arthroplasty. *J Bone Joint Surg Am* 1985;67(06):832–841
- Bourne RB, Mehin R. The dislocating hip: what to do, what to do. *J Arthroplasty* 2004;19(04, Suppl 1):111–114
- Biedermann R, Tonin A, Krismer M, Rachbauer F, Eibl G, Stöckl B. Reducing the risk of dislocation after total hip arthroplasty: the effect of orientation of the acetabular component. *J Bone Joint Surg Br* 2005;87(06):762–769
- Woo RY, Morrey BF. Dislocations after total hip arthroplasty. *J Bone Joint Surg Am* 1982;64(09):1295–1306
- Sanchez-Sotelo J, Haidukewych GJ, Boberg CJ. Hospital cost of dislocation after primary total hip arthroplasty. *J Bone Joint Surg Am* 2006;88(02):290–294
- Berry DJ, von Knoch M, Schleck CD, Harmsen WS. Effect of femoral head diameter and operative approach on risk of dislocation after primary total hip arthroplasty. *J Bone Joint Surg Am* 2005;87(11):2456–2463
- Charnley J. The long-term results of low-friction arthroplasty of the hip performed as a primary intervention. *J Bone Joint Surg Br* 1972;54(01):61–76
- McKee GK, Watson-Farrar J. Replacement of arthritic hips by the McKee-Farrar prosthesis. *J Bone Joint Surg Br* 1966;48(02):245–259
- Chughtai M, Mistry JB, Diedrich AM, et al. Low Frequency of Early Complications With Dual-mobility Acetabular Cups in Cementless Primary THA. *Clin Orthop Relat Res* 2016;474(10):2181–2187
- Bouchet R, Mercier N, Saragaglia D. Posterior approach and dislocation rate: a 213 total hip replacements case-control study comparing the dual mobility cup with a conventional 28-mm metal head/polyethylene prosthesis. *Orthop Traumatol Surg Res* 2011;97(01):2–7
- Combes A, Migaud H, Girard J, Duhamel A, Fessy MH. Low rate of dislocation of dual-mobility cups in primary total hip arthroplasty. *Clin Orthop Relat Res* 2013;471(12):3891–3900
- Prudhon JL, Ferreira A, Verdier R. Dual mobility cup: dislocation rate and survivorship at ten years of follow-up. *Int Orthop* 2013;37(12):2345–2350
- Tarasevicius S, Robertsson O, Dobožinskas P, Wingstrand H. A comparison of outcomes and dislocation rates using dual articulation cups and THA for intracapsular femoral neck fractures. *Hip Int* 2013;23(01):22–26
- Darrith B, Courtney PM, Della Valle CJ. Outcomes of dual mobility components in total hip arthroplasty: a systematic review of the literature. *Bone Joint J* 2018;100-B(01):11–19
- De Martino I, Triantafyllopoulos GK, Sculco PK, Sculco TP. Dual mobility cups in total hip arthroplasty. *World J Orthop* 2014;5(03):180–187
- Lu-Yao GL, Keller RB, Littenberg B, Wennberg JE. Outcomes after displaced fractures of the femoral neck. A meta-analysis of one hundred and six published reports. *J Bone Joint Surg Am* 1994;76(01):15–25

- 27 Adam P, Philippe R, Ehlinger M, et al. French Society of Orthopaedic Surgery and Traumatology (SoFCOT). Dual mobility cups hip arthroplasty as a treatment for displaced fracture of the femoral neck in the elderly. A prospective, systematic, multicenter study with specific focus on postoperative dislocation. *Orthop Traumatol Surg Res* 2012;98(03):296–300
- 28 Philippet R, Boyer B, Farizon F. Intraprosthetic dislocation: a specific complication of the dual-mobility system. *Clin Orthop Relat Res* 2013;471(03):965–970
- 29 Vielpeau C, Lebel B, Ardouin L, Burdin G, Lautridou C. The dual mobility socket concept: experience with 668 cases. *Int Orthop* 2011;35(02):225–230