

PRIMARY ANORECTAL MELANOMA- A RARE CASE REPORT WITH REVIEW OF LITERATURE

Harish S. Permi¹, Michelle Mathias², Kishan Prasad¹, Sunilkumar Y¹,
Jayaprakash Shetty K³, J.H. Makannavar⁴,

¹Assistant Professor, ²Associate Professor, ¹Assistant Professor, ¹Assistant Professor, ³Professor & HOD, ⁴Professor,
Department of Pathology, K.S. Hegde Medical Academy, Nitte University,
Deralakatte, Mangalore, Karnataka, India.

Correspondence:

Harish S. Permi,

Assistant Professor, Dept of Pathology, K.S. Hegde Medical Academy, Nitte University, Deralakatte,
Mangalore, KARNATAKA (State), INDIA

Mobile No. : 99641 31827 E-mail : drharish01@gmail.com

Abstract:

Malignant melanoma is very rare accounting for 1% of all anorectal malignancies. Long term survival is rare, as most patients die of disseminated disease. A 64-year old female presented with the history of bleeding per rectum and constipation since 2 months with recto-sigmoidoscopy showing an exophytic growth measuring 4x3 cms obstructing the lumen of the rectum. Biopsy showed malignant spindle cell tumor, with possibilities of spindle cell variant of squamous cell carcinoma, leiomyosarcoma and malignant melanoma. The tumor cells were immunoreactive for S-100 and HMB-45, confirming malignant melanoma. MRI showed a tumor just behind the anal verge, without evidence of invasion in the sphincter or enlarged lymph nodes. An abdominal perineal resection was performed with colostomy. On four years of follow up, the patient is doing well without recurrence or metastasis. We report this case because of its rarity, diagnostic dilemmas, early diagnosis and treatment of this aggressive malignancy for better outcome and long term survival.

Keywords : primary, anorectal melanoma, HMB-45.

Introduction

Primary malignant melanoma of the anus and rectum is rare and highly lethal neoplasm constituting less than 1% of all melanomas and 4% of anorectal tumors other than adenocarcinoma. [1, 2] The delayed clinical manifestations and lack of clinical suspicion contributes to delayed diagnosis. [2] Owing to its rarity and histologic variability, misdiagnosis as carcinoma, sarcoma and lymphoma is common. [1] Sometimes this can be mistaken for benign conditions like hemorrhoids or rectal polyp as they present with rectal bleeding. The melanocytes as demonstrated by HMB 45 are usually located in the anal squamous zone, but are also seen in transitional and colorectal zone. Thus the demonstration of melanocytes in all the three zones of the anal canal substantially supports the observation that malignant melanoma of the anal canal may originate not only below but also above the dentate line. [3] We report a case of

anorectal melanoma in a 64 year old woman who underwent surgery with complete recovery without any recurrence or metastasis after 4 years of follow up. We highlight the diagnostic dilemmas, importance of early diagnosis and treatment of this aggressive malignancy for better outcome with long term survival.

Case Report

A 64-year old female presented with the history of bleeding per rectum and constipation since 2 months with recto-sigmoidoscopy showing an exophytic growth measuring 4x3 cms obstructing the lumen of the rectum. Biopsy from the growth showed clusters of tumor cells arranged in sheets, clusters and fascicles. The cells were round to oval to spindle shaped consisted of vesicular nucleus with prominent eosinophilic nucleoli. Many abnormal mitotic figures were seen. The possibilities of spindle cell variant of squamous cell carcinoma, leiomyosarcoma and malignant melanoma were

considered. The tumor cells were immunoreactive for S-100 and HMB-45, confirming malignant melanoma. MRI showed a tumor just behind the anal verge, without evidence of invasion in the sphincter or enlarged lymph nodes. Abdominal ultrasonography, CT-thorax showed no evidence of distant metastasis. An abdomino-perineal resection was performed with permanent colostomy. The postoperative period was uneventful. Histopathology of the resected specimen confirmed the diagnosis of malignant melanoma with tumor limiting only to the submucosa and at places showing melanin pigmentation. The resected margins and lymph nodes were free from tumor. The patient is on regular follow up since 4 years without any evidence of recurrence or metastasis.

Discussion

Primary anorectal melanoma is a rare disorder accounting for 4% of anorectal malignancies other than adenocarcinoma. [4] It usually affects women in the fifth or sixth decade and presents with rectal bleeding or altered bowel habits. [5] Our patient was a 64 year female presented with bleeding per rectum and constipation. Patients presenting with rectal bleeding and sensation of a mass is usually attributed to hemorrhoids or polyp. The epithelial lining of the anal canal is glandular in the upper part and squamous in the lower part. The middle zone also known as anal

transitional zone is characterized by an epithelium which bears resemblance to that of anal glands, but show little mucous secretion.[3] The absence of early clinical manifestations and the lack of clinical suspicion contributes for delayed diagnosis. Up to 60% have metastasis at the time of diagnosis. [7].In our case the disease was limited to rectum and anal canal without evidence of metastasis. The factors for poor prognosis include, advanced disease at the time of diagnosis and rich vascularity which increases the risk of hematogenous metastasis. [8] Abdomino-perineal resection (APR) is the treatment of choice for patients with <2 mm wide lesion.[9] Radiotherapy is palliative in locally extensive tumors while combined with chemotherapy is used for metastasis. APR appears to have some effect in controlling symptoms caused by local and regional disease but has minimal impact on prognosis. [10] However in our case only APR with permanent colostomy was done without chemoradiotherapy. Extended follow up for 4 years showed no recurrence or metastasis.

Conclusion

Although anorectal melanomas are rare, this should be considered as one of the differential diagnosis in malignancies other than adenocarcinoma, so that early diagnosis with histological features confirmed with immunohistochemistry will help in appropriate management and long term survival of the patient.

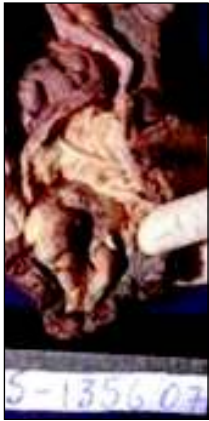

Figure 1

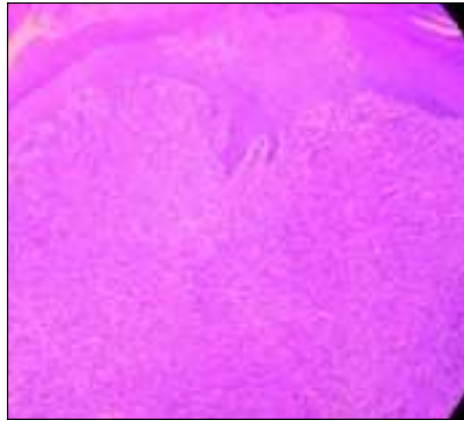


Figure 2

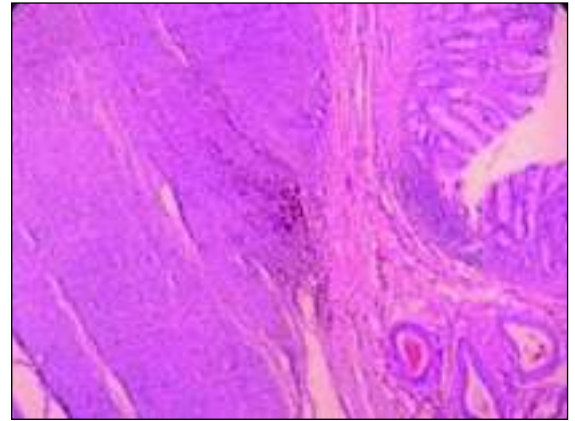


Figure 3

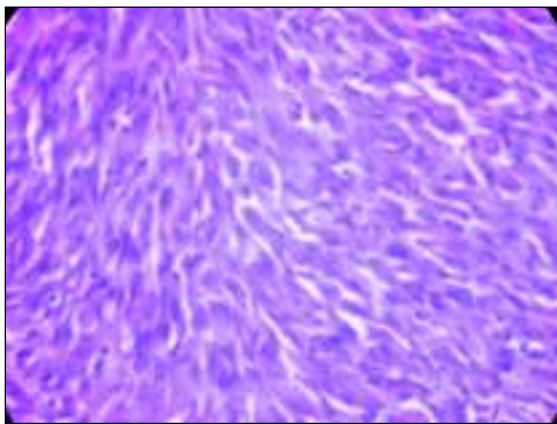


Figure 4

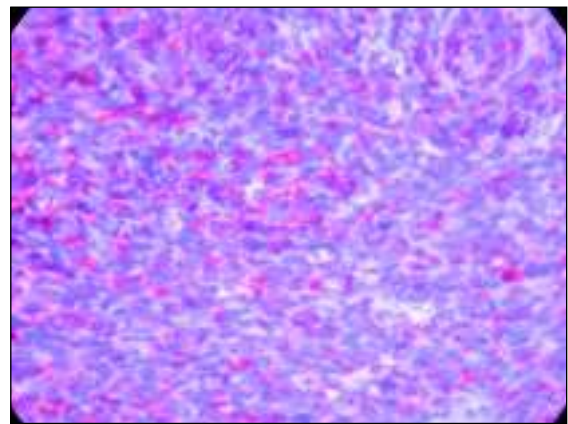


Figure 5

LEGENDS

Figure 1 -Gross photo showing nodulo proliferative growth with blackish pigmentation in the anorectal region.

Figure 2 - Microscopy showing tumor beneath the stratified squamous epithelium (Anal canal). (H&E X100)

Figure 3 -Showing tumor with melanin pigment in the rectum. (H&E X100)

Figure 4 -Showing spindle shaped tumor cells having vesicular nucleus with prominent eosinophilic nucleoli (H&E X400)

Figure 5 -Showing tumor cells immunoreactive for HMB-45.

References:

- 1) Deborah J. Chute, John B. Cousar, Stacey E. Mills. Anorectal Malignant Melanoma: Morphologic and Immunohistochemical Features. *Am J Clin Pathol*: 2006; 126:93-100.
- 2) Takeshi Takahashi, Liliana Velasco, Xeily Zarate, Heriberto Medina-Franco, Ruben Cortes, Lorenzo de la Garza et al. Anorectal Melanoma: Report of Three Cases with Extended Follow-up. *South Med J*: 2004; 97:3.
- 3) Vamseedhar Annam, C.Panduranga, C.R.Kodandaswamy. Primary anorectal malignant melanoma – A case report and review of literature. *Journal of Gastrointestinal Cancer*: 2008; 39: 1-3.
- 4) Roviello F, Cioppa T, Marrelli D, Nastri G, De Stefano A, Hako L, et al. Primary ano-rectal melanoma: considerations on a clinical case and review of the literature. *Chir Ital*. 2003; 55:575–80.
- 5) Fratesi L, Alhusayen R, Walker J. Case report of primary rectal melanoma and review of the etiology of melanoma. *J Cutan Med Surg*: 2008; 12, 3:117–120.
- 6) Ozguroglu, Mustafa, Ozaras, Resat. Anorectal Melanoma Metastatic to the Breast. *J Clin Gastroenterol*: 1999; 29:2: 197.
- 7) Cooper PH, Mills SE, Allen MS Jr. Malignant melanoma of the anus: Report of 12 patients and analysis of 255 additional cases. *Dis Colon Rectum*: 1982; 25: 693-703.
- 8) Pantolone D, Taruffi F, Paolucci R, et al. Malignant melanoma of the rectum. *Eur J Surg* 2000; 166: 583-4.
- 9) Brady MS, Kavolius JP, Quan SH. Anorectal melanoma. A 64-year experience at Memorial Sloan-Kettering Cancer Center. *Dis Colon Rectum*. 1995; 38:146-151
- 10) Korenkov M, Gönner U, Dünschede F, Junginger T. Rectal melanoma: the value of modern treatment in German. *Zentralbl Chir*. 2008; 133:564–7.