

RARE ASSOCIATION OF DOWN SYNDROME WITH DANDY WALKER MALFORMATION

Suresh Goyal¹, Vignesh Nayak H.² & Reeta Meena³

¹Professor & HOD, ³Resident, Department of Pediatrics, R.N.T Medical College, Udaipur.

²Senior Resident, Department of Pediatrics, K.S. Hegde Medical College, Nitte University, Deralakatte, Mangalore - 575 018, Karnataka, India.

Correspondence

Vignesh Nayak H.

Senior Resident, Department of Pediatrics, Room no S-3/09, Samrudhi Residents Hostel, K.S. Hegde Medical College, Deralakatte, Mangalore - 575 018, Karnataka, India. E-mail : viggy2006@yahoo.com

Abstract :

We report on a patient with Down syndrome and a multi-systemic condition comprising congenital heart disease (ASD) and neurological malformation (Dandy walker malformation). The co-occurrence of Down syndrome (DS) and Dandy walker malformation is relatively uncommon.

Keywords : Down syndrome, Dandy walker malformation.

Introduction :

Trisomy 21, leading to Down syndrome (DS), is the most common genetic cause of mental retardation (1). The CDC estimates that about one of every 691 babies born in the United States each year is born with Down syndrome(2). The coexistence of DS and Dandy-Walker syndrome (DWS) has been previously reported in few cases, suggesting that it is relatively uncommon for both conditions to occur simultaneously [3, 5, and 8]. While the case reported by Constantini et al. [3] died at 2 week of age, Estroff et al. [8] described a 4-month-old infant with trisomy 21 and Dandy-Walker variant (DWV) as severely handicapped, and Kaitlin love et al. (5) described developmental outcomes of down syndrome and dandy walker malformation; we would like to report a similar association, as it would help in better understanding of both these conditions.

Case Report :

A 4 month old male child, born out of non-consanguineous marriage to 18 year old mother (G4, P4) and 20 year old father, got admitted to our hospital with complaints of progressive enlargement of head since 2 months. The pregnancy was uncomplicated, mother

being antenatally registered, gave birth to the child at 9 months by normal vaginal delivery. The birth weight of the child was 2.5 kg. Developmental milestones of the child were delayed (social smile was achieved at 3 months, he started recognizing his mother at 4 months and partial neck holding was achieved at 4 months).

Anthropometric measurements of the child are as follows, weight of the child 4.8 kg (< 3rd percentile), length 62cm (<3rd percentile), head circumference 48cm (>97th percentile). Anterior fontanelle and posterior fontanelle-wide open (9*6 cm and 2*2 cm, respectively).

On general physical examination, features of down syndrome- upward slanting of eyes, epicanthal folds, hypertelorism, fissured tongue, flat nasal bridge, simian crease, clinodactyly, saddle gap and Mongolian spot over lumbo-sacral area were present. The child also had undescended testis on the left side.

Karyotype analysis confirmed Trisomy 21.

ECHO revealed ostium secundum ASD of 0.6 cm and CT scan of the brain showed communicating hydrocephalus with VSI > 70% with hypoplastic cerebellum and absent vermis, with a large posterior fossa cyst communicating with 4th ventricle, likely representing dandy walker malformation.

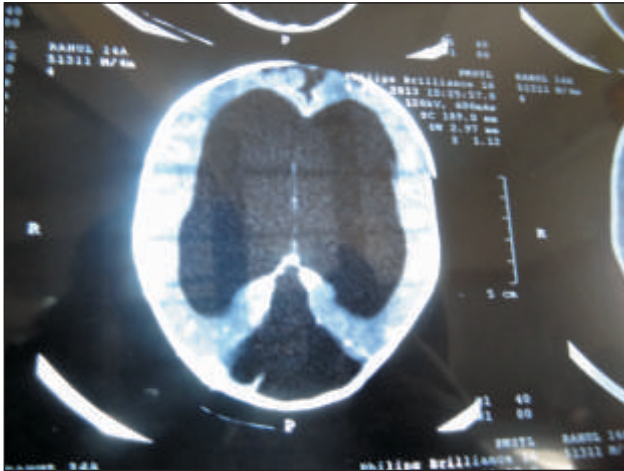
Access this article online

Quick Response Code



USG Abdomen was normal.

The child was operated for hydrocephalus and VP (ventriculo-peritoneal) shunt was placed.



CT scan of brain showing communicating hydrocephalus with VSI > 70% with hypoplastic cerebellum and absent vermis, with a large posterior fossa cyst communicating with 4th ventricle, likely representing dandy walker malformation.

Discussion :

Down syndrome is a well-known congenital malformation and is usually associated with microcephaly; only few cases have been reported with hydrocephalus. The coexistence of DS and Dandy-Walker syndrome (DWS) has been previously reported in few cases, suggesting that it is relatively uncommon for both conditions to occur

simultaneously [3, 5,8].

DWS is characterized by triad of, a) partial or total vermian agenesis; b) cystic dilatation of the fourth ventricle; c) an enlarged posterior fossa. This syndrome usually presents before late childhood, typically during infancy. It is often associated with hydrocephalus and usually requires surgery. Variable neurological abnormalities associated with DWS include hydrocephalus, microcephaly, ventriculomegaly, and agenesis of the corpus callosum [4, 6]. Anomalies outside of the central nervous system described in association with DWS include cardiac defects, craniofacial abnormalities, gastrointestinal abnormalities, genitourinary abnormalities, respiratory aberrations, and musculoskeletal dysmorphisms (9).

Although there is no direct estimate of isolated DWS incidence, it has an estimated incidence of one in every 30,000 live births [7]. Both teratogenic and genetic factors have been implicated as the cause of this cerebellar developmental disorder, consistent with a multifactorial inheritance pattern [10]. Genetic causes are variable, and various abnormalities of chromosomes 3, 5, 8, 9, 13, and 18 have been associated with DWS [8-12]. Grinberg et al. [13] isolated a region on 3q24-25.1 commonly deleted in individuals with DWM.

References :

1. "Amniocentesis - American Pregnancy Association". Americanpregnancy.org. Retrieved 2013-02-23.
2. CDC - Birth Defects, Down Syndrome - NCBDDD. Cdc.gov. 2011-06-08. Retrieved 2013-02-23.
3. Constantini S, Pomeranz S, Hoffman B, Martin O, Rappaport ZH. Coexistence of Dandy-Walkersyndrome and Down's syndrome. Neurochirurgia (Stuttg). 1989; 32:56–57. [PubMed: 2524010]
4. Ha Has R, Ermis H, YükselYüksel A, Ibrahimoglu L, Yildirim A, Sezer HD, Basaran S.et al. Dandy-Walker Malformation: A Review Ofmalformation: a review of 78 Cases Diagnosed By Prenatal Sonography.cases diagnosed by prenatal sonography. Fetal Diagn Ther. 2004; 19:342–347. [PubMed: 15192294]
5. Kaitlin Love, Lillie Huddleston, Pat Olney, David Wrubel and Jeannie Visootsak. Developmental outcomes of Down syndrome and Dandy-Walker malformation. JPediatr Neurol. 2011; 9(3): 405–408.
6. Bolduc ME, Limperopoulos C. Neurodevelopmental outcomes in children with cerebellar malformations: a systematic review. Dev Med Child Neurol. 2009; 51:256–267. [PubMed:19191827]
7. Osenbach RK, Menezes AH (1992). "Diagnosis and management of the Dandy-Walker malformation: 30 years of experience." *Pediatr Neurosurg* 18 (4): 179–89. PMID 1472430.
8. Estroff JA, Scott MR, Benacerraf BR. Dandy-Walker variant: prenatal sonographic features and clinical outcome. Radiology. 1992; 185:755–758. [PubMed: 1438757]
9. Sasaki-Adams D, Elbabaa SK, Jewells V, Carter L, Campbell JW, Ritter AM. The Dandy-Walker variant: a case series of 24 pediatric patients and evaluation of associated anomalies, incidence of hydrocephalus, and developmental outcomes. J Neurosurg Pediatr. 2008; 2:194–199. [PubMed:18759601]
10. Imataka G, Yamanouchi H, Arisaka O. Dandy-Walker syndrome and chromosomal abnormalities. Congenit Anom (Kyoto). 2007; 47:113–118. [PubMed: 17988252]
11. Ulm B, Ulm MR, Deutinger J, Bernaschek G. Dandy-Walker malformation diagnosed before 21 weeks of gestation: associated malformations and chromosomal abnormalities. Ultrasound Obstet Gynecol. 1997; 10:167–170. [PubMed: 9339523]
12. Witters I, Vandecruys H, Devlieger R, Fryns JP. Dandy-Walker malformation in a male fetus with mosaic 45,X/46,X,del(Y)(q11). Genet Couns. 2008; 19:439–441. [PubMed: 19239090]
13. Grinberg I, Millen KJ. The ZIC gene family in development and disease. Clin Genet. 2005; 67:290–296. [PubMed: 15733262]
14. Chang MC, Russell SA, Callen PW, Filly RA, Goldstein RB. Sonographic detection of inferior vermian agenesis in Dandy- Walker malformations: prognostic implications. Radiology 1994; 193: 765-70. Fet