

A RARE CASE OF CYANOSIS AND CLUBBING –LIVER INDUCED VASCULAR DISORDER OF LUNG

Pothukuchi Venkata Krishna¹, Manasa Manne² & Venkata Ravikumar Chepuri³

¹Professor, ^{2,3}P. G. Students, Department of General Medicine

Guntur Medical College, Government General Hospital, Guntur, Andhra Pradesh, India.

Correspondence :

Pothukuchi Venkata Krishna

57-9-15, New Postal Colony, Patamata, Vijayawada - 520 010, Andhra Pradesh, India.

Mobile : +91 98481 34088 E-mail : krishnapothukuchi@gmail.com

Abstract:

The hepatopulmonary syndrome (HPS) is under recognized complication of chronic liver disease. The Hepatopulmonary syndrome has three components: liver disease, pulmonary vascular dilatation, and a defect in oxygenation. If hypoxemia and dyspnea develop in these patients in the absence of known intrinsic cardiopulmonary disorder, the hepatopulmonary syndrome must be considered. Clinical features include digital clubbing, cyanosis, spider nevi. It is a rare complication of liver disease of varied etiology and indicates a poor prognosis. We are reporting a case of severe clubbing of fingers associated with severe cyanosis and chronic liver disorder in a very young girl to highlight that other causes also should be thought of in addition to cyanotic congenital heart disease in such a young age.

Keywords: Liver disease, cyanosis, clubbing, dyspnea, hepatopulmonary syndrome

Introduction:

Hepatopulmonary syndrome is characterized by a defect in arterial oxygenation induced by pulmonary vascular dilatation in the setting of liver disease.^[1] It is a rare complication of liver disease of varied etiology and indicates a poor prognosis. If hypoxemia and dyspnea develop in these patients in the absence of known intrinsic cardiopulmonary disorder, the hepatopulmonary syndrome must be considered.^[2] Relationship between cirrhotic liver disease and lung was first described by Flukiger in 1884^[3] in a woman with liver cirrhosis and digital clubbing. In the year 1997, Kennedy and Knudsen coined the term 'Hepatopulmonary Syndrome'.^[4] Clinical features include digital clubbing, cyanosis, spider nevi.^[5] The hepatopulmonary syndrome is characterized by platypnea and orthodeoxia.^[6] Hepatopulmonary syndrome is a rare

disease that affects patients of any age with acute or chronic liver disease. Hepatopulmonary syndrome should be included in the differential diagnosis of unexplained

hypoxemia with an evaluation of possible portal hypertension or liver disease even in the absence of other clinical symptoms.^[7] Here we are reporting a case of hepatopulmonary syndrome presented with severe clubbing and cyanosis.

Case History:

A 17 year old female was presented with cyanosis and clubbing since 4 years. There was a history of chronic liver disease with portal hypertension and esophageal varices for which banding was done. There was no history of cardiac or pulmonary disease. Physical examination revealed central cyanosis and grade 3 finger clubbing [FIGURE.1]. Abdominal examination revealed splenomegaly. Cardiovascular examination and respiratory examination revealed no positive findings for primary cardiac or pulmonary disease. Her oxygen saturation was maintained at 75%. Laboratory studies showed that her complete blood picture was within normal limits. Liver function tests and renal function tests were within normal range. No abnormality was found in ECG and chest X ray. Ultrasound abdomen revealed coarse echotexture of liver with splenomegaly. Upper gastrointestinal endoscopy revealed grade 3 varices[FIGURE.2]. Cardiac

Access this article online

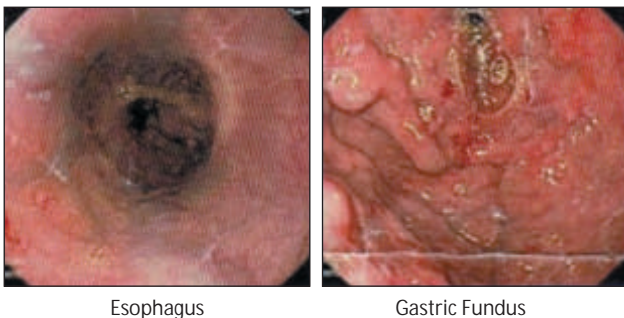
Quick Response Code



echocardiography and computerised tomogram of chest revealed no abnormality in the heart and lungs. Contrast echocardiography revealed intrapulmonary shunts [FIGURE.3, 4].

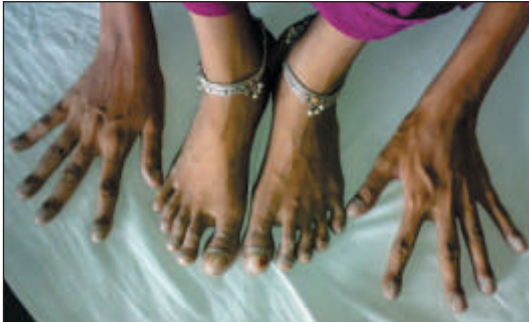

Figure 1 : Cyanosis and Clubbing of digits in both limbs.



Esophagus

Gastric Fundus

Figure 2 : Upper GI endoscopy showing esophageal and fundus varices.

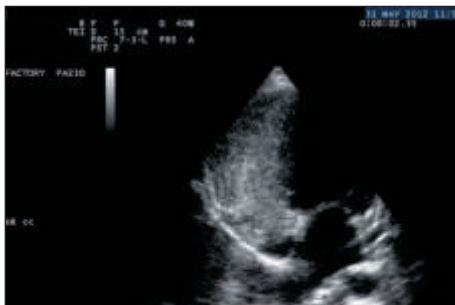


Figure 3 : 2D echo after injection of agitated normal saline showing bubbles in Right heart.

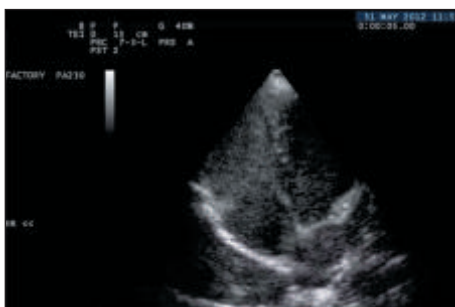

Figure 4 : 2D echo after few cardiac cycles showing bubbles in Left heart.

Discussion:

Patients with HPS may be asymptomatic. Etiology of this syndrome remains unknown. Most commonly accepted hypothesis postulates that there is inadequate synthesis or metabolism of pulmonary vasoactive substance by impaired liver, leading to functional vasodilatation of the pulmonary vasculature producing hypoxemia. To date, however, no particular substances have been implicated in causing this dilatation, but possibilities include prostaglandins, nitric oxide, vasoactive intestinal peptide, calcitonin, glucagons, substance P, and atrial natriuretic factor.^[2]

Severity of hypoxemia does not correlate with the severity of underlying liver disease.^[2] There is no relationship between the presence or severity of hepatopulmonary syndrome and the severity of liver disease.^[1]

There are four criteria of HPS 1) Chronic liver disease 2) Pulmonary gas exchange abnormalities with an increased alveolar arterial gradient 3) Evidence of intra pulmonary shunting and 4) Absence of other significant cardio pulmonary disease. We have not tested pulmonary gas exchange abnormalities but all other three criteria were present in our patient. ^[2] Measurement of oxygen saturation by pulse oximetry is a reliable screening test for the presence of hepatopulmonary syndrome.^[6, 8] Contrast-enhanced transthoracic echocardiography with saline (shaken to produce microbubbles >10 µm in diameter) is the most practical method to detect pulmonary vascular dilatation.^[1, 8]

It can be treated with oxygen but it is potentially correctable only with reversal of underlying disease or with liver transplantation.^[2]

Conclusion:

The hepatopulmonary syndrome is under recognized complication of chronic liver disease. It must be considered in every patient with advanced liver disease manifesting symptoms of dyspnea and hypoxemia ^[2] and also in patients with severe clubbing and cyanosis when the intrinsic cardiopulmonary disorders were ruled out.^[2]

Acknowledgements:

We sincerely thank Dr.Sk.Moulali, M.D., D.M. and Dr. N. Srikanth, M.D., D.M., Assistant Professors of Cardiology, Government General Hospital, Guntur and Guntur Medical College, Guntur for their technical help in investigations (2D Echo Cardiogram and Contrast Echo Cardiograph).

References:

1. Rodriguez-Roisin R, Krowka MJ. Hepatopulmonary syndrome—a liver-induced lung vascular disorder. *N Engl J Med* 2008;358:2378-87.
2. G Agrawal, N Kumar, D Roshia. Hepatopulmonary Syndrome. *Journal of Association of Physicians of India* 2008;56:265-7.
3. Flückiger M. Vorkommen von trommelschlägelförmigen Fingerendphalangen ohne chronische Veränderungen an den Lungen oder am Herzen. *Wien Med Wnschr* 1884;34:1457.
4. Kennedy TC, Knudson RJ. Exercise-aggravated hypoxemia and orthodeoxia in cirrhosis. *Chest* 1997;72:305-9.
5. J.D. Collier, G. Webster. Liver and biliary tract disease. In: Nicki R. Colledge, Brian R. Walker, Stuart H. Ralston, editors. *Davidson's Principles & Practice of Medicine*, 21st ed. Edinburgh: Churchill Livingstone; 2010. p.973.
6. Marc Ghany, Jay H. Hoofnagle. Approach to the Patient with Liver Disease. In: Dan L. Longo, Anthony S. Fauci, Dennis L. Kasper, Stephen L. Hauser, J. Larry Jameson, Joseph Loscalzo, editors. *Harrison's Principles of Internal Medicine* 18th edn. USA: McGraw Hill; 2012. p.2524.
7. Unexplained cyanosis revealing hepatopulmonary syndrome in a child with asymptomatic congenital hepatic fibrosis: a case report. Wahab AA, Al-Mansoori M, El-Hawli M, Kini V. *J Med Case Rep* 2013;7:120.
8. Rollán MJ, Muñoz AC, Pérez T, Bratos JL. Value of contrast echocardiography for the diagnosis of hepatopulmonary syndrome. *Eur J Echocardiogr* 2007;8:408-10.