



Adult Degenerative Scoliosis

Escoliose degenerativa do adulto

Alexandre Fogaça Cristante¹ Ricardo Teixeira e Silva¹ Guilherme Henrique Ricardo da Costa¹
Raphael Martus Marcon¹

¹ Department of Orthopedics and Traumatology, Hospital das Clínicas, Faculdade de Medicina, Universidade de São Paulo, São Paulo, SP, Brazil

Address for correspondence Ricardo Teixeira e Silva, Departamento de Ortopedia e Traumatologia, Hospital das Clínicas HCFMUSP, Faculdade de Medicina, Universidade de São Paulo, R. Dr. Ovídio Pires de Campos, 333, Cerqueira César, São Paulo, SP, 05403-010, Brazil (e-mail: ricardo.teixeira.silva@gmail.com).

Rev Bras Ortop 2021;56(1):1–8.

Abstract

Keywords

- ▶ scoliosis/physiopathology
- ▶ scoliosis/therapy
- ▶ intervertebral disc degeneration
- ▶ adult

Populational aging increases the incidence of musculoskeletal degenerative processes, such as adult scoliosis (AS). Adult scoliosis is defined as a spinal deformity in the coronal plane with a Cobb angle $> 10^\circ$. Adult scoliosis may be iatrogenic or result from a degenerative process (scoliosis *de novo*) or a pre-existing scoliosis.

Adult scoliosis is a potentially limiting condition that affects a heterogeneous group of patients. Clinical treatment proved to be ineffective and surgery is often indicated. The present paper reviews AS pathophysiology, clinical presentation and diagnosis, in addition to surgical indications and the main techniques currently used.

Resumo

Palavras-chave

- ▶ escoliose/fisiopatologia
- ▶ escoliose/terapia
- ▶ degeneração do disco intervertebral
- ▶ adulto

O envelhecimento da população aumenta a incidência dos processos degenerativos osteomusculares, como a escoliose do adulto (EA). A EA é definida como uma deformidade da coluna no plano coronal com ângulo de Cobb $> 10^\circ$ e pode ocorrer devido a um processo degenerativo (escoliose *de novo*), evolução de uma escoliose pré-existente ou de forma iatrogênica.

A EA é uma doença potencialmente limitante que acomete um grupo heterogêneo de pacientes. O tratamento clínico se mostrou pouco efetivo e a indicação cirúrgica é frequente. No presente artigo, é apresentada uma revisão sobre a fisiopatologia, a manifestação clínica e o diagnóstico da EA. Também são apresentadas as indicações cirúrgicas e as principais técnicas utilizadas atualmente.

Introduction

Brazil is in the midst of a demographic transition due to populational aging.¹ The proportion of people >65 years old went from 3.5% in 1970 to 5.5% of the population in 2000. It is estimated that the elderly will account for 19% of the Brazilian population in 2050.²

This phenomenon has significant implications for health care; most importantly, it increases the incidence and the

prevalence of musculoskeletal degenerative processes, including adult scoliosis (AS). In different studies, the prevalence of vertebral deformities in people >65 years old ranges from 32 to 68%.³

Adult scoliosis is defined as a spinal deformity featuring a Cobb angle $> 10^\circ$ in the coronal plane in a skeletally mature patient.⁴ Adult scoliosis may result from a spinal degenerative condition (referred to as scoliosis *de novo*), progression of a pre-existing scoliosis during childhood/adolescence

received
September 5, 2019
accepted
January 10, 2020
published online
July 22, 2020

DOI <https://doi.org/10.1055/s-0040-1709736>.
ISSN 0102-3616.

© 2020. Sociedade Brasileira de Ortopedia e Traumatologia. All rights reserved.

This is an open access article published by Thieme under the terms of the Creative Commons Attribution-NonDerivative-NonCommercial-License, permitting copying and reproduction so long as the original work is given appropriate credit. Contents may not be used for commercial purposes, or adapted, remixed, transformed or built upon. (<https://creativecommons.org/licenses/by-nc-nd/4.0/>)

Thieme Revinter Publicações Ltda., Rua do Matoso 170, Rio de Janeiro, RJ, CEP 20270-135, Brazil

(adult idiopathic scoliosis [AIS]), systemic diseases and previous spine surgery.⁵

Its debilitating effect on the general health of the patients must be highlighted. Bess et al⁶ observed that patients with vertebral deformity present a higher prevalence of psychiatric conditions and worse quality of life in comparison to same-age counterparts or people with general chronic diseases, such as diabetes and high blood pressure. The limitation imposed by the severe coronal and sagittal imbalances similar to that associated with cancer, visual impairment or restricted use of the upper and lower limbs.

The number of patients with AS submitted to surgery increases every year; today, AS correction presents the highest proportional growth among spine surgical procedures.⁷ The treatment of AS becomes a challenge due to its high surgical complexity, clinically compromised patients and high health costs.

Pathophysiology

It is believed that disc degeneration triggers AS. As people age, the intervertebral disc loses proteoglycans due to the increased activity of proteases, leading to a decrease in osmotic pressure and disc hydration.⁸ It has been shown that, starting at 15 years old, annular lesions are common and compromise disc biomechanics. This process results in disc height loss and disc inability to perform its stabilizing role, leading to facet joints overload.⁹

Facet joints overload is often asymmetrical, which contributes to the progressive deformity and increases the likelihood of associated central and foraminal stenosis. Axial rotation is especially known to compromise the spinal ligamentous complex, resulting in laterolisthesis.^{9,10}

A number of factors are related to AS development, including liposubstitution of paravertebral muscles, disc impairment due to smoking, obesity, genetic inheritance, development of neurodegenerative conditions and senile changes in balance and mobility.^{3,10,11}

Osteoporosis was thought to be implicated in AS development; however, this assumption has been refuted by most current studies, which suggest that the prevalence of osteoporosis is similar among AS patients and the general population. There was no correlation between the degree of osteopenia and curve magnitude. It was revealed that bone mineral density is higher on the concave side of the curve and on the ipsilateral femur when compared with the other side.¹²

Clinical Presentation

Clinical presentation is variable due to the heterogeneity of patients. Symptoms of central stenosis with neurogenic claudication are reported in up to 90% of patients. Patients with adult degenerative scoliosis also experience symptom relief when they sit and support the trunk with the upper limbs.^{9,13}

Low back pain is present in 60 to 80% of patients, mainly on the convex side of the curve, and it is caused by degenerative changes and muscle fatigue resulting from sagittal/coronal imbalance. Radiculopathy at one or multiple levels affects 47 to

78% of the patients, and it results from facet hypertrophy at the concave side of the curve and laterolisthesis.¹⁴

Postural changes resulting from a fixed deformity or compensatory mechanisms are frequent and must be evaluated routinely. Trunk inclination, pelvic and scapular asymmetries, hypo-/hyperkyphosis, hips, knees and ankles flexion and extension degree when standing and walking, in addition to horizon line evaluation, are the main points of analysis.¹⁵

Pain, neurological complaints and limitations in daily living activities are more commonly reported in AS patients compared to adolescent patients, in whom the aesthetic deformity and curve progression are the main reasons for dissatisfaction.¹⁶

Adult scoliosis due to a degenerative process, referred to as *scoliosis de novo*, affects both genders similarly; it often starts at 50 years old and has relevant clinical repercussions when the patient is ~ 70.5 years old. The condition affects 32 to 68% of individuals >65 years old.^{10,11} It typically involves the lumbar spine with a Cobb angle < 40°. The association with laterolisthesis is frequent, and a compensatory thoracic curve is occasionally seen.¹⁰ Compared to adult idiopathic scoliosis, curves resulting from scoliosis de novo present less angulation, but greater progression (1.64°/year versus 0.82°/year).¹⁷

Adult idiopathic scoliosis is observed in patients with pre-existing scoliosis, mainly females, and it occurs in two main patterns. One group shows steady progression after skeletal maturity; in the other group, however, the curve starts to progress around the 4th and 5th decades of life, after menopause.¹⁷ Compared to scoliosis de novo, AIS presents less central stenosis, larger Cobb angles (mean value, > 50°) and more frequent compensatory thoracic curves, but laterolisthesis/spondylolisthesis rates and coronal/sagittal imbalance are less common.¹⁴

Rotational deformity is observed throughout the lumbar spine in AIS, but it is limited to the apex of the curve and accompanied by laterolisthesis in scoliosis de novo.¹⁴

Radiological evaluation

An orthostatic spinal panoramic radiography is the primary test for AS diagnosis and classification. Although the evaluation of such cases has been mainly performed on the coronal plane, sagittal balance has been deemed important in recent decades, and its routine study is essential.¹⁸

Adequate radiographic images are crucial; they must include the region from the skull base, proximally, to the femoral heads, distally. Whenever possible, the patient should be in orthostasis with no support, allowing the evaluation of any compensatory mechanism. Patients unable to walk must be radiographed while sitting down.

Deformity flexibility or the presence of structured curves can be assessed using dynamic radiographs under inclination or traction. This information can help preoperative planning, predicting which techniques will be required for proper deformity correction and any intraoperative challenges.

At the coronal plane, it is recommended to measure the Cobb angle measurement in all curves, identify terminal, stable and neutral vertebrae and assess coronal balance (through the distance between a plumb line in C7 and a

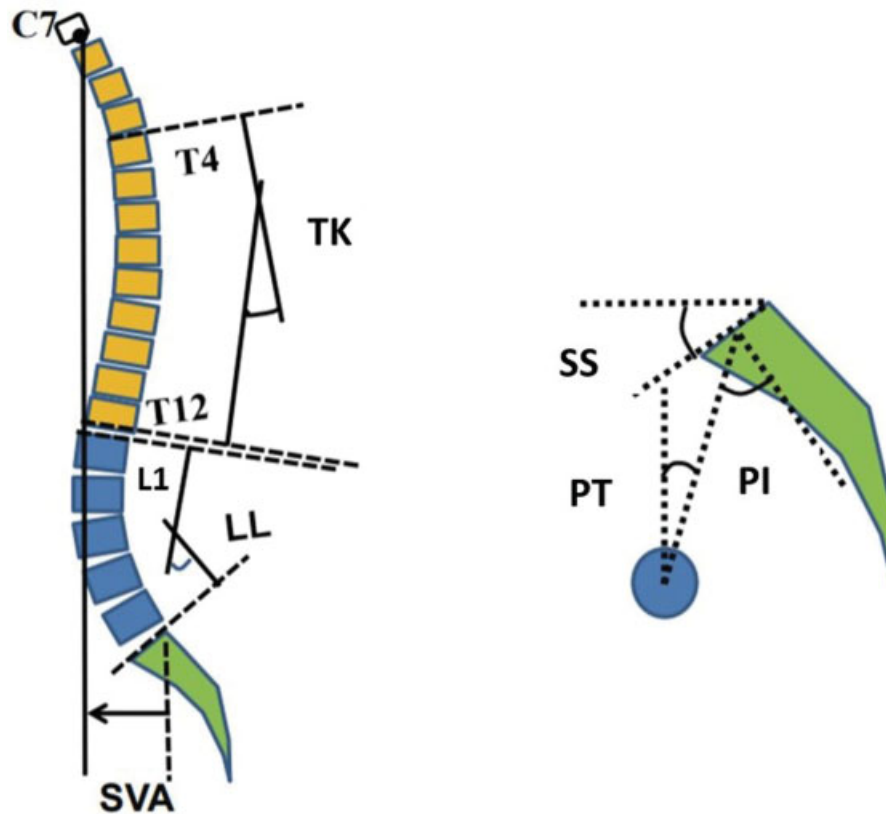


Fig. 1 SVA, Sagittal vertical axis; LL, Lumbar Lordosis; TK, Thoracic Kyphosis; SS, Sacral slope; PT, Pelvic Tilt; PI, Pelvic incidence.

central sacral vertical line) and pelvic obliquity (if present, rule out a potential lower limb discrepancy).¹⁰

At the sagittal plane (→**Figure 1**), the global sagittal balance must be evaluated using the distance between a plumb line in C7 and another vertical line passing through the posterosuperior border of S1. Spinopelvic parameters, lumbar lordosis and thoracic kyphosis must also be assessed.¹⁰

On radiographic analysis, the increased apical vertebra rotation (\geq grade 3 according to the Nash-Moe method) Cobb angles $> 30^\circ$, intervertebral discs asymmetry above and below apical vertebra, laterolisthesis > 6 millimeters and interiliac line (line between the upper aspects of both iliac crests) sectioning L5 instead of L4 are predictive of curve progression. The presence of anterior osteophytes increases spinal stability.¹⁹

Table 1 Radiographic Parameter Thresholds Predictive of an Oswestry Disability Index Score of 40²⁰

Radiographic parameter	Radiographical Threshold	r
PI-LL	11°	0.45
PT	22°	0.38
SVA	46mm	0.47

Abbreviations: PI, pelvic incidence; LL, lumbar lordosis; PT, pelvic tilt; SVA, sagittal vertical axis.

The evaluation of spinopelvic parameters is essential for the classification and determination of the best surgical strategy (→**Table 1**). According to the Oswestry Disability Index (ODI), a pelvic tilt (PT) of 22°, sagittal vertical axis (SVA) of 46 mm and pelvic incidence minus lumbar lordosis (PI-LL) of 11° are predictive of disability (ODI > 40) and considered sagittal modifiers for the SRS-Schwab classification.²⁰

A supplementary study using computed tomography (CT) and magnetic resonance imaging (MRI), even though unable to identify dynamic orthostatic factors, is beneficial because it allows three-dimensional (3D) image reproduction and shows details of bone components and intra and extravertebral soft tissues. Computed tomography is better to detail bone features, including facet arthrosis, vertebral rotation and pedicle diameter. On the other hand, MRI provides information on disc involvement, central and foraminal stenosis and paravertebral muscles liposubstitution.¹⁵

Biplane imaging devices with 3D capacity are relatively new and promising diagnostic methods with lower radiation rates. This equipment provides whole-body images, including the head, the spine, the pelvis and the lower limbs, optimizing the analysis of the overall balance of the patient.²¹

Classification Systems

The SRS-Schwab is the classification method currently used due to its descriptive power, reproducibility and correlation with quality of life (→**Figure 2**).²⁰ Initially, the Cobb angle must be measured at the coronal plane and the deformity is

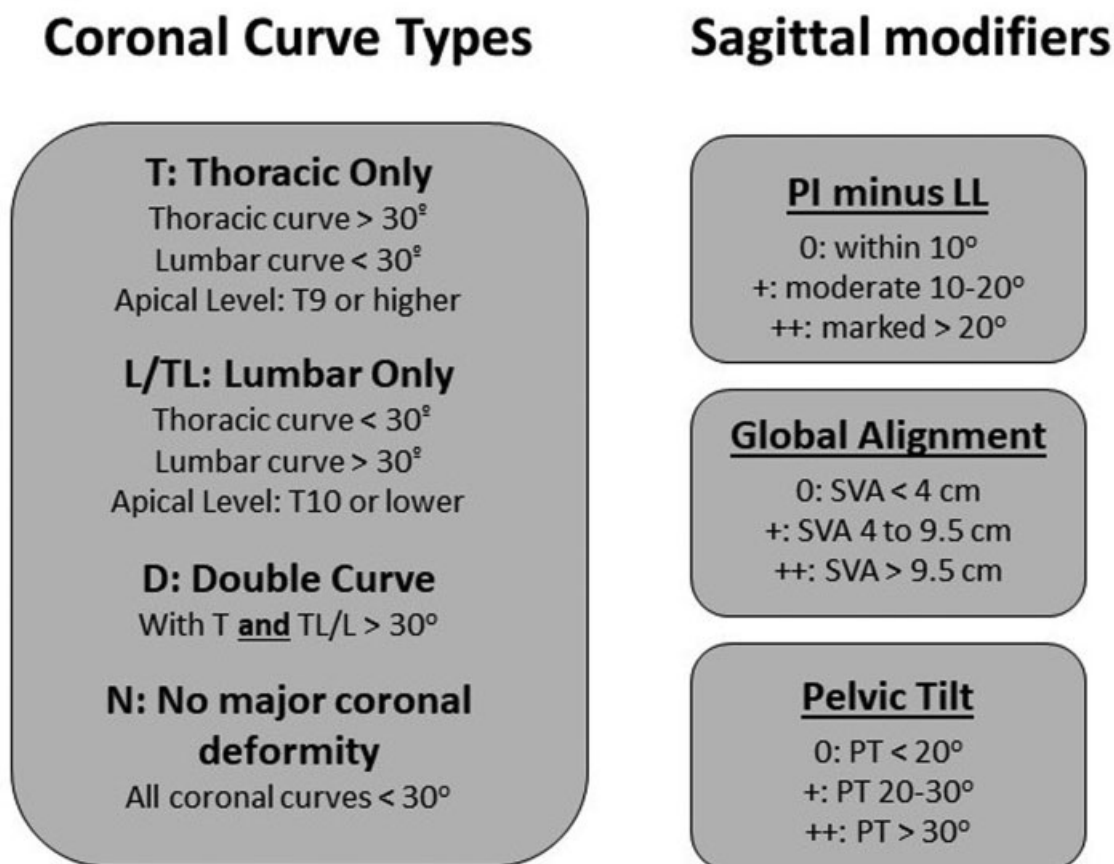


Fig. 2 SRS-Schwab Classification.²⁰ PI, Pelvic incidence; LL, Lumbar lordosis; SVA, Sagittal vertical axis; PT, Pelvic Tilt.

characterized. Next, the sagittal plane is assessed through three sagittal modifiers.

As previously mentioned, the presence of a “+” or “++” score in any sagittal modifier is predictive of worse clinical performance.

Comparison of results obtained with different techniques is severely limited due to the wide variety of osteotomies and terminologies for AS treatment. To overcome this problem, Schwab et al proposed an anatomical classification of osteotomies based on the resection site (► **Figure 3**).²²

Anterolateral interbody fusion has gained popularity in the last decade. Although it was initially used for indirect decompression, anterolateral interbody fusion became part of the therapeutic arsenal for adult deformities. In anterior column realignment (ACR) procedures, a section of the anterior longitudinal ligament (ALL) is added to increasing their corrective power.²³

Since ACR procedures provide mobility to the three Denis columns, it is a minimally invasive technique to correct adult deformities that were previously exclusively treated with osteotomies.²³

To facilitate the communication between surgeons and standardize ACR interventions in clinical research, Uribe et al proposed a new classification based on an anatomical classification for osteotomies (► **Figure 4**).²³

Grade A is unique since it is corrected through an anterior or lateral approach, with no posterior osteotomies.

In these cases, angular correction is achieved with all section and a 20° or 30° hyperlordotic cage is used. Approximately 7.8° of lordosis per segment is achieved with 30° cages.²³ Further grades are based on the performance of posterior osteotomies (Schwab modifier) and ACR route (approach modifier).

Treatment

Clinical Treatment

Despite the absence of consistent scientific evidence to warrant their indication, nonsurgical methods often are the first line of treatment. Studies recommending physical therapy, stretching, manual therapy and local heat application for AS patients are scarce, with evidence level IV.²⁴ Acupuncture and cognitive behavioral therapy may be considered in cases of chronic pain. The use of vests was not deemed effective.²⁵

Medical treatment is based on analgesics, non-steroidal anti-inflammatory drugs, anticonvulsants and antidepressants. The assessment of bone mineral density must be performed routinely, and specific treatment must be instituted if osteoporosis is diagnosed. Epidural and trigger point infiltrations or peripheral nerve blocks are beneficial as therapeutic evidence and provide short and medium-term pain relief, although further studies on their long-term effects are required.²⁶

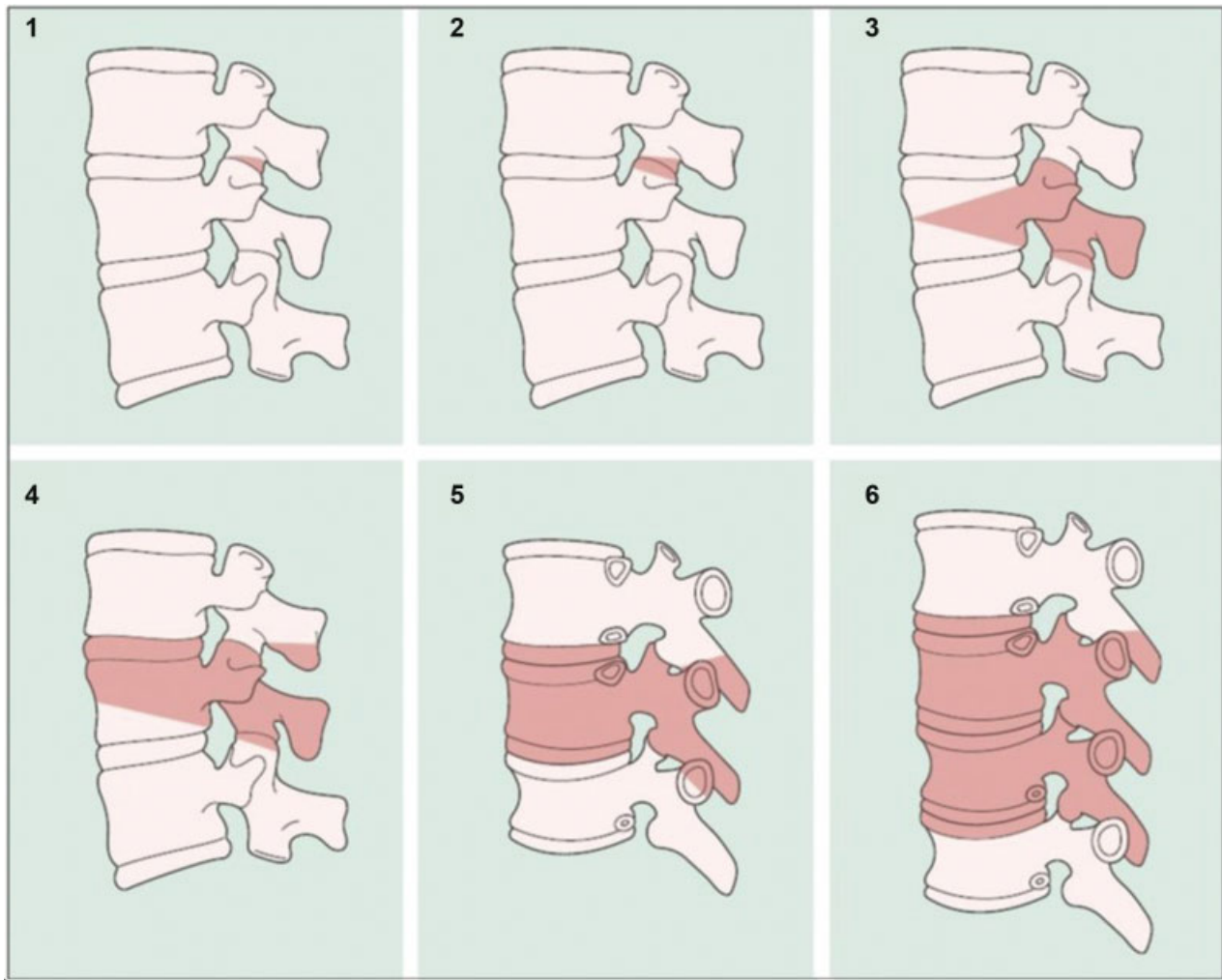


Fig. 3 A graduated and simplified anatomically based osteotomy classification system by Schwab et al.²² Grade 1: partial facet joint; Grade 2: complete facet joint; Grade 3: pedicle and partial body; Grade 4: pedicle, partial body, and disc; Grade 5: complete vertebra and discs; Grade 6: multilevertebrae and discs.

Clinical treatment has better results in patients with mild, nonprogressive deformities and few symptoms. In a multicenter study, Passias et al²⁷ compared clinical, surgical and clinical-to-surgical (crossover) treatments and observed that participants who opted for surgery had more limitations and worse performance in pain/quality of life scores.

Surgical Treatment

The main indications for surgery are daily living activity limitations, pain, neurological symptoms, confirmed curve progression and conservative treatment failure²⁵ In radiographic terms, surgical intervention is recommended in lumbar curves $>30^\circ$ to 40° , 6 mm laterolisthesis, curve progression $>10^\circ$ or subluxation $>3\text{ mm}$ ⁹

The main points to consider for surgical indication are the reestablishment of global (mostly sagittal) balance parameters and neurological decompression. The high prevalence of comorbidities in this population, surgical complexity and expectations of the patients about their treatment must also be considered.

Most studies comparing clinical and surgical adult deformity treatment favor surgical intervention. Operated patients show statistically significant improvement in quality of life, pain, performance and less chance of clinical deterioration compared to those submitted to the conservative treatment.²⁸

Surgical treatment may be performed using several techniques, which were hierarchically subdivided by Silva and Lenke⁹ in six groups: I, decompression alone; II, decompression and limited instrumented posterior spinal fusion; III, decompression and lumbar curve instrumented fusion; IV, decompression with anterior and posterior spinal instrumented fusion; V, thoracic instrumentation and fusion extension; and VI, inclusion of osteotomies for specific deformities.

Decompression alone is best indicated in patients with neurological symptoms, stable lumbar curves (Cobb $<30^\circ$, $<2\text{ mm}$ laterolisthesis and anterior osteophytes) and no axial pain.¹⁴ In similar cases with potential instability and requiring extensive decompression, arthrodesis only of the addressed segment must be considered if sagittal and coronal balance are spared.²⁹













ACR Classification	Construct	Schwab Modifier	Approach Modifier
Grade A		 0	Lateral or Anterior
Grade 1		 1	Lateral or Anterior or Posterior
Grade 2		 2	
Grade 3		 3	
Grade 4		 4	
Grade 5		 5	

Fig. 4 Anterior column realignment classification.²³

In patients at risk of pseudoarthrosis and at long lumbar fusion planning, the association of interbody arthrodesis is beneficial, especially at lower lumbar levels, when lumbosacral fusion is performed⁹ Anterior and lateral approach techniques, in addition to providing direct and indirect decompression by foraminal distraction, allow the use of

larger cages with lower risk of plateau fracture (subsidence) and potential for angular correction insagittal and coronal planes.^{10,29}

Arthrodesis extension to the thoracic spine may be required in the presence of significant global imbalance associated with increased thoracic kyphosis to reduce the

chance of proximal junctional kyphosis. T10 or cephalic fusion is preferred due to the stability conferred by the articulation of the respective (true) ribs to the sternum at such levels, which is not observed with floating ribs (T11 and T12).^{9,30}

Cases with rigid deformities (<30% correction on dynamic radiographs) or previous arthrodesis with significant sagittal imbalance are eligible for osteotomies. Osteotomies restore vertebral balance and decrease the burden on bone/hardware interface and the chance of mechanical failure.⁹ Even though these procedures increase surgical time, bleeding and perioperative morbidity, sagittal balance correction proved to be the single factor with best impact on postoperative outcomes.¹⁹

The following principles are recommended for choosing arthrodesis levels:¹⁰

- § *Do not stop at the apex of the curve*
- § *Do not stop at an area of kyphosis*
- § *Include severe lateral subluxation*
- § *Include spondylolisthesis or retrolisthesis*
- § *Upper instrumented vertebra should ideally be horizontal*
- § *Iliac fixation should be strongly considered in long fusions*

Surgical Techniques

Posterolateral fusion (PLF) has shorter surgical time, bleeding and postoperative complications compared to transforaminal interbody lumbar fusion (TLIF). However, TLIF showed better sagittal correction and better clinical outcomes regarding pain and satisfaction.³¹ In general, surgeries with interbody arthrodesis for AS have better clinical outcomes than strict PLF³²

Anterior lumbar interbody fusion (ALIF) has the advantage of anterior release and decompression optimization due to the placement of larger intervertebral implants, enabling greater sagittal corrections and lower subsidence rates when compared to posterior techniques.³³ It is suitable for L4-L5 and especially L5-S1 levels due to the local vascular anatomy. Vascular and visceral injury, as well as retrograde ejaculation, are potential complications³²

Lateral lumbar interbody fusion (LLIF) has gained popularity in recent years and allows T12-L1 to L4-L5 correction in the sagittal and coronal planes with robust implants, such as ALIF; in addition, it is surgically easier in patients with previous abdominal surgeries or who are obese. Its disadvantages are the difficult access to the L5-S1 disc due to the iliac crest, the long learning curve and the risk of psoas weakening and lumbar plexus damage.¹⁹

In a prospective multicenter study with 107 patients undergoing LLIF due to adult degenerative scoliosis, Phillips et al³⁴ reported improvement in ODI score, visual analog scale (VAS) and SF-36 quality of life questionnaire. The average Cobb angle corrected from 20.9° to 13.5° in the postoperative period and remained at 15.2° after 2 years of follow-up. In patients with reduced lumbar lordosis, the average Cobb angle went from 27.7° to 33.6° in 2 years.

The prolonged surgical time and high perioperative morbidity rate associated with classic procedures led to the

current effort to develop minimally invasive (MIS) techniques, which had encouraging preliminary results.

Complications

In a case review conducted by the Scoliosis Research Society (SRS), the rate of surgical complications in AS is 13.4%, although other studies reported rates up to 40%. Dura-mater damage, implant failure, superficial and deep wound infection and neurological deficits are the most frequent injuries.³⁵ Obese, smoking, osteoporotic and elderly patients (> 65 years) are at additional risk.¹¹

Proximal junctional kyphosis occurs in 20 to 40% of patients; its presentation may be early or late. Current techniques are associated with lower pseudoarthrosis rates, ranging from 4 to 24% according to recent studies. Reoperation rates range from 16.7% within 90 days to 40% in 11 years.¹¹

Given the clinical characteristics of this group, systemic complications such as acute myocardial infarction, pneumonia, adynamic ileum, deep vein thrombosis and urinary tract infection are not uncommon.

Final Considerations

Adult degenerative scoliosis is a potentially limiting disease that affects a heterogeneous group of patients with important clinical limitations. Clinical treatment proved to be ineffective and surgical indication is frequent. It represents a challenge to spine surgeons due to its complexity and increased prevalence.

Clinical and radiological evaluation must carefully determine the real origin of the symptoms. Decompression of neurological structures and maintenance of sagittal and coronal balance, whenever possible, must be the main therapeutic goals.

Minimally invasive techniques are being developed and their improvement might reduce the incidence of postoperative complications and provide better results. As such, further studies are required to attest the real benefit of these procedures in AS treatment.

Note

This is an "Update Article", with no requirement for approval by the Research Ethics Committee.

The authors attest that the present study was carried out without the direct participation of human beings.

Study developed at the Division of Vertebral Spine Surgery, Department of Orthopedics and Traumatology of the Hospital das Clínicas HCFMUSP, Faculdade de Medicina, Universidade de São Paulo, São Paulo, SP, BR.

Conflict of Interests

The authors have no conflict of interests to declare.

References

- 1 Wong LL, Carvalho JA. O rápido processo de envelhecimento populacional do Brasil: sérios desafios para as políticas públicas. *Rev Bras Estud Popul* 2006;23(01):5-26

- 2 Nasri F. O envelhecimento populacional no Brasil. *Einstein* (Sao Paulo) 2008;6(Suppl 1):S4-S6
- 3 Schwab F, Dubey A, Gamez L, et al. Adult scoliosis: prevalence, SF-36, and nutritional parameters in an elderly volunteer population. *Spine (Phila Pa 1976)* 2005;30(09):1082-1085
- 4 Aebi M. The adult scoliosis. *Eur Spine J* 2005;14(10):925-948
- 5 Youssef JA, Orndorff DO, Patty CA, et al. Current status of adult spinal deformity. *Global Spine J* 2013;3(01):51-62
- 6 Bess S, Line B, Fu KM, et al; International Spine Study Group. The Health Impact of Symptomatic Adult Spinal Deformity: Comparison of Deformity Types to United States Population Norms and Chronic Diseases. *Spine (Phila Pa 1976)* 2016;41(03):224-233
- 7 McCarthy I, Hostin R, O'Brien M, Saigal R, Ames CP. Health economic analysis of adult deformity surgery. *Neurosurg Clin N Am* 2013;24(02):293-304
- 8 Vernon-Roberts B, Moore RJ, Fraser RD. The natural history of age-related disc degeneration: the influence of age and pathology on cell populations in the L4-L5 disc. *Spine (Phila Pa 1976)* 2008;33(25):2767-2773
- 9 Silva FE, Lenke LG. Adult degenerative scoliosis: evaluation and management. *Neurosurg Focus* 2010;28(03):E1
- 10 York PJ, Kim HJ. Degenerative Scoliosis. *Curr Rev Musculoskelet Med* 2017;10(04):547-558
- 11 Diebo BG, Shah NV, Boachie-Adjei O, et al. Adult spinal deformity. *Lancet* 2019;394(10193):160-172
- 12 Routh RH, Rumancik S, Pathak RD, Burshell AL, Nauman EA. The relationship between bone mineral density and biomechanics in patients with osteoporosis and scoliosis. *Osteoporos Int* 2005;16(12):1857-1863
- 13 Grubb SA, Lipscomb HJ, Suh PB. Results of surgical treatment of painful adult scoliosis. *Spine (Phila Pa 1976)* 1994;19(14):1619-1627
- 14 Cho KJ, Kim YT, Shin SH, Suk SI. Surgical treatment of adult degenerative scoliosis. *Asian Spine J* 2014;8(03):371-381
- 15 Smith JS, Shaffrey CI, Fu KM, et al. Clinical and radiographic evaluation of the adult spinal deformity patient. *Neurosurg Clin N Am* 2013;24(02):143-156
- 16 Bess S, Boachie-Adjei O, Burton D, et al. International Spine Study Group. Pain and disability determine treatment modality for older patients with adult scoliosis, while deformity guides treatment for younger patients. *Spine (Phila Pa 1976)* 2009;34(20):2186-2190
- 17 Marty-Poumarat C, Scattin L, Marpeau M, Garreau de Loubresse C, Aegerter P. Natural history of progressive adult scoliosis. *Spine (Phila Pa 1976)* 2007;32(11):1227-1234
- 18 Schwab FJ, Blondel B, Bess S, et al; International Spine Study Group (ISSG). Radiographical spinopelvic parameters and disability in the setting of adult spinal deformity: a prospective multicenter analysis. *Spine (Phila Pa 1976)* 2013;38(13):E803-E812
- 19 Kim W, Porrino JA, Hood KA, Chadaz TS, Klauser AS, Taljanovic MS. Clinical Evaluation, Imaging, and Management of Adolescent Idiopathic and Adult Degenerative Scoliosis. *Curr Probl Diagn Radiol* 2019;48(04):402-414
- 20 Schwab F, Ungar B, Blondel B, et al. Scoliosis Research Society-Schwab adult spinal deformity classification: a validation study. *Spine (Phila Pa 1976)* 2012;37(12):1077-1082
- 21 Somoskeöy S, Tunyogi-Csapó M, Bogyó C, Illés T. Accuracy and reliability of coronal and sagittal spinal curvature data based on patient-specific three-dimensional models created by the EOS 2D/3D imaging system. *Spine J* 2012;12(11):1052-1059
- 22 Schwab F, Blondel B, Chay E, et al. The comprehensive anatomical spinal osteotomy classification. *Neurosurgery* 2014;74(01):112-120
- 23 Uribe JS, Schwab F, Mundis GM, et al. The comprehensive anatomical spinal osteotomy and anterior column realignment classification. *J Neurosurg Spine* 2018;29(05):565-575
- 24 Teles AR, Mattei TA, Righesso O, Falavigna A. Effectiveness of Operative and Nonoperative Care for Adult Spinal Deformity: Systematic Review of the Literature. *Global Spine J* 2017;7(02):170-178
- 25 Haldeman S, Nordin M, Chou R, et al. The Global Spine Care Initiative: World Spine Care executive summary on reducing spine-related disability in low- and middle-income communities. *Eur Spine J* 2018;27(Suppl 6):776-785
- 26 DePalma MJ, Slipman CW. Evidence-informed management of chronic low back pain with epidural steroid injections. *Spine J* 2008;8(01):45-55
- 27 Passias PG, Jalai CM, Line BG, et al. International Spine Study Group. Patient profiling can identify patients with adult spinal deformity (ASD) at risk for conversion from nonoperative to surgical treatment: initial steps to reduce ineffective ASD management. *Spine J* 2018;18(02):234-244
- 28 Sengupta D. Adult Spinal Deformity. In: Rao R, Smuck M, editors. *Orthopaedic knowledge update: spine*. 4th ed. Rosemont, IL: American Academy of Orthopaedic Surgeons; 2012:349-367
- 29 Cho KJ, Suk SI, Park SR, et al. Short fusion versus long fusion for degenerative lumbar scoliosis. *Eur Spine J* 2008;17(05):650-656
- 30 Fu X, Sun XL, Harris JA, et al. Long fusion correction of degenerative adult spinal deformity and the selection of the upper or lower thoracic region as the site of proximal instrumentation: a systematic review and meta-analysis. *BMJ Open* 2016;6(11):e012103
- 31 Li FC, Chen QX, Chen WS, Xu K, Wu QH, Chen G. Posterolateral lumbar fusion versus transforaminal lumbar interbody fusion for the treatment of degenerative lumbar scoliosis. *J Clin Neurosci* 2013;20(09):1241-1245
- 32 Mobbs RJ, Phan K, Malham G, Seex K, Rao PJ. Lumbar interbody fusion: techniques, indications and comparison of interbody fusion options including PLIF, TLIF, MI-TLIF, OLIF/ATP, LLIF and ALIF. *J Spine Surg* 2015;1(01):2-18
- 33 Rao PJ, Loganathan A, Yeung V, Mobbs RJ. Outcomes of anterior lumbar interbody fusion surgery based on indication: a prospective study. *Neurosurgery* 2015;76(01):7-23
- 34 Phillips FM, Isaacs RE, Rodgers WB, et al. Adult degenerative scoliosis treated with XLIF: clinical and radiographical results of a prospective multicenter study with 24-month follow-up. *Spine (Phila Pa 1976)* 2013;38(21):1853-1861
- 35 Sansur CA, Smith JS, Coe JD, et al. Scoliosis research society morbidity and mortality of adult scoliosis surgery. *Spine (Phila Pa 1976)* 2011;36(09):E593-E597