

# Cross-Hand Replantation

S. Raja Sabapathy<sup>1</sup> Hari Venkatramani<sup>1</sup> Sanjai Ramkumar<sup>1</sup> Monusha Mohan<sup>1</sup> Dafang Zhang<sup>2</sup>

<sup>1</sup>Department of Plastic, Hand and Reconstructive Microsurgery, Ganga Hospital, Coimbatore, Tamil Nadu, India

<sup>2</sup>Department of Orthopaedic Surgery, Brigham and Women's Hospital, Boston, Massachusetts, United States

**Address for correspondence** S. Raja Sabapathy, MS, MCh, DNB, Department of Plastic, Hand and Reconstructive Microsurgery, Ganga Hospital, 313, Mettupalayam Road, Coimbatore 641043, Tamil Nadu, India (e-mail: rajahand@gmail.com)

Indian J Plast Surg 2020;53:124–130

## Abstract

Combined major injury to both upper extremities, in which one hand is amputated and structurally intact but not replantable, and the other hand is unsalvageable, is a rare setting in which cross-hand replantation may be considered. We report a case of an emergency cross-hand replantation performed at the wrist level. In our case, insertions of the wrist flexor and extensor tendons at the second and third metacarpal bases were retained at the recipient, allowing for early active wrist motion and finger motion by tenodesis. Fascicle-specific nerve coaptations were performed. The patient achieved satisfactory functional results, allowing him independence with daily living activities and return to gainful employment. At the time of telemedicine follow-up at 5 years, he was employed full-time, reported no difficulty or mild difficulty with most daily activities, and preferred the use of his replanted hand over a contralateral prosthesis.

## Keywords

- ▶ cross-hand replantation
- ▶ replantation
- ▶ mangling injury

## Introduction

Bilateral major upper extremity trauma presents challenges in management. Rare circumstances may arise, in which one hand is intact, amputated, and not replantable, while the other hand is mangled and unsalvageable. In this setting, cross-hand replantation may be considered to restore one sensate, functional hand and avoid bilateral upper extremity prostheses.<sup>1-4</sup>

We present a rare case of emergency cross-hand replantation following a blast injury, in which an intact right hand amputated at the metacarpal base level was microsurgically replanted onto the contralateral carpal stump. We report good postoperative outcomes at 1-year clinical follow-up and 5-year telemedicine follow-up.

## Case Report

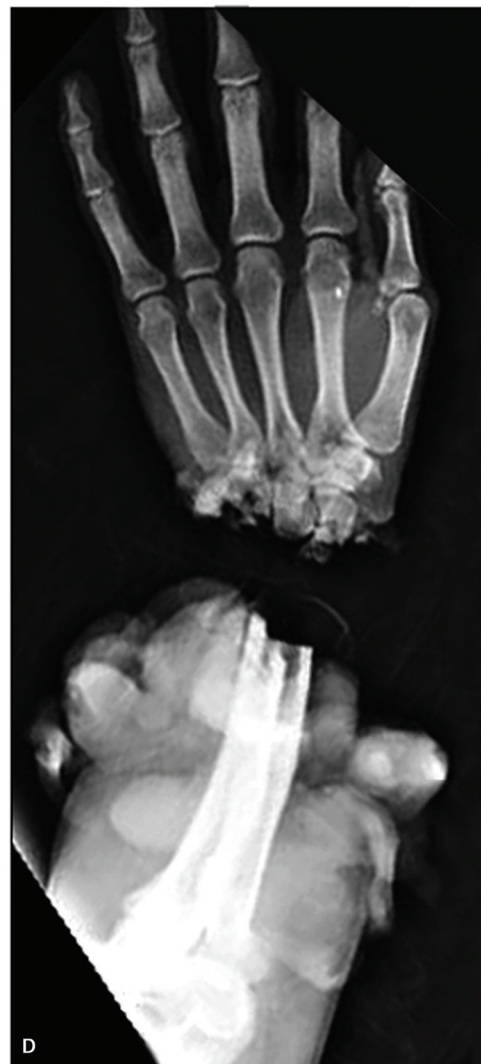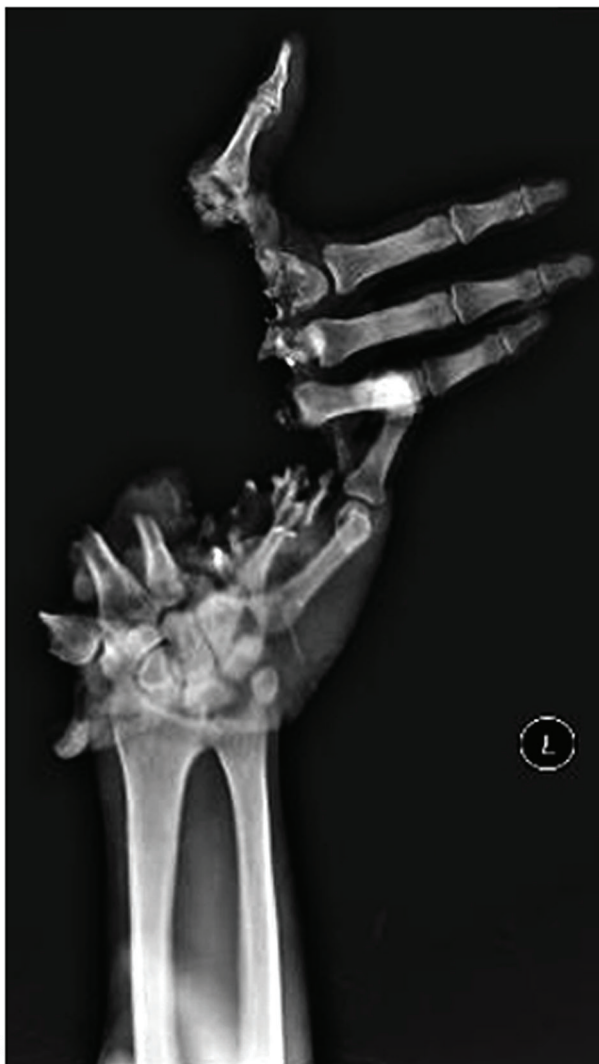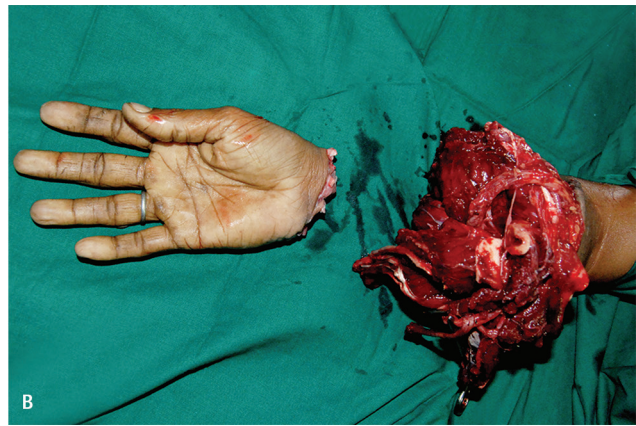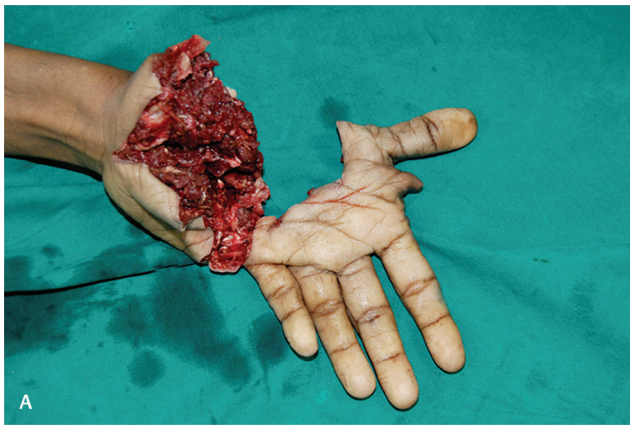
A 41-year-old man, right hand dominant, was transferred to our emergency department from an outside hospital 4 hours after a blast injury at a cordite factory. He was working at the factory as a carpenter on a contract basis. Examination of the extremities showed a subtotal amputation of the left hand at the metacarpal level, with mangling of the intrinsic

hand muscles, metacarpal comminution and bone loss, and dysvascular digits. The right upper extremity was completely amputated at the level of the proximal forearm, with an irretrievable segment of distal forearm, and an intact right hand; orthotopic replantation would not have been feasible (▶ Fig. 1).

In view of the unsalvageable left hand with an intact carpus, and intact right hand with loss of the right forearm, the decision was made to proceed with cross-hand replantation to avoid bilateral upper extremity amputations.

Surgery was performed under general anesthesia and tourniquet control. Bony debridement was performed in the amputated right hand, leaving the metacarpals and trapezium, and tendons, nerves, and vessels were identified, taking care to preserve adequate lengths. Completion of amputation of the left hand was performed. Devitalized intrinsic hand muscles were debrided, and the metacarpals were shortened.

The right hand was transferred to the left carpus and fixed using 3 K-wires. Bony fixation and tendon repairs were performed accordance to the scheme shown in ▶ Table 1. The proximal radial artery was anastomosed to the distal ulnar artery using an interpositional vein graft. The venae



**Fig. 1** Clinical photographs of the injured (a) left upper extremity with segmental loss of metacarpals and near total loss of palmar soft tissue and (b) right upper extremity with amputation through the proximal third of forearm with loss of middle and distal third of forearm. Preoperative radiographs (c), (d) displaying the same.

**Table 1** Structures connected in cross-hand replantation

Structure	Proximal (left wrist)	Distal (right hand)
Bones	Second metacarpal base	Fifth metacarpal
	Third metacarpal base	Fourth metacarpal
	Fifth metacarpal base	Trapezium
Tendons	FCU	APL, EPB
	FDS index	FPL
	FDS middle	FDS ring, FDS small
	FDS ring	FDS index, FDS middle
	FDP	FDP
	EIP	EDM
	EDC	EDC
	EDM	EPL
Nerves	Median nerve (180°rotated)	Median nerve
	Ulnar nerve motor branch	Ulnar nerve motor branch
	Ulnar nerve sensory branch	Ulnar nerve sensory branch
Vessels	Radial artery	Ulnar artery
	Radial artery venae comitantes	Ulnar artery venae comitantes
	Cephalic vein	Cephalic vein

Abbreviations: APL, abductor pollicis longus; EDC, extensor digitorum communis; EDM, extensor digitorum minimi; EIP, extensor indicis proprius; EPB, extensor pollicis brevis; EPL, extensor pollicis longus; FCU, flexor carpi ulnaris; FDS, flexor digitorum superficialis; FDP, flexor digitorum profundus; FPL, flexor pollicis longus.

comitantes of the proximal radial artery were anastomosed to those of the distal ulnar artery, and the cephalic vein was anastomosed. The new hand pinked up immediately following tourniquet release. Total ischemia time was 8 hours. The respective motor and sensory branches of the ulnar nerve were primarily coapted by crossing to the other side of the wrist. The proximal median nerve was rotated 180° and coapted to the distal median nerve, to better match the topography of the motor and sensory fascicles (►Fig. 2). The skin was primarily closed. Below-elbow amputation of the right forearm was performed. The left arm was placed into above-elbow plaster immobilization. Total procedural time was 7 hours.

At 2 weeks postoperatively, the patient was transitioned to a below-elbow dorsal blocking splint, finger mobilization was started with wrist tenodesis, and elbow mobilization *ad lib* was begun. The K-wires were removed serially in clinic from 4 to 8 weeks, and finger mobilization was progressed (►Fig. 3). At 5 months, grip strength was 2 kg, and key pinch strength was 0.5 kg. He was provided a high-end

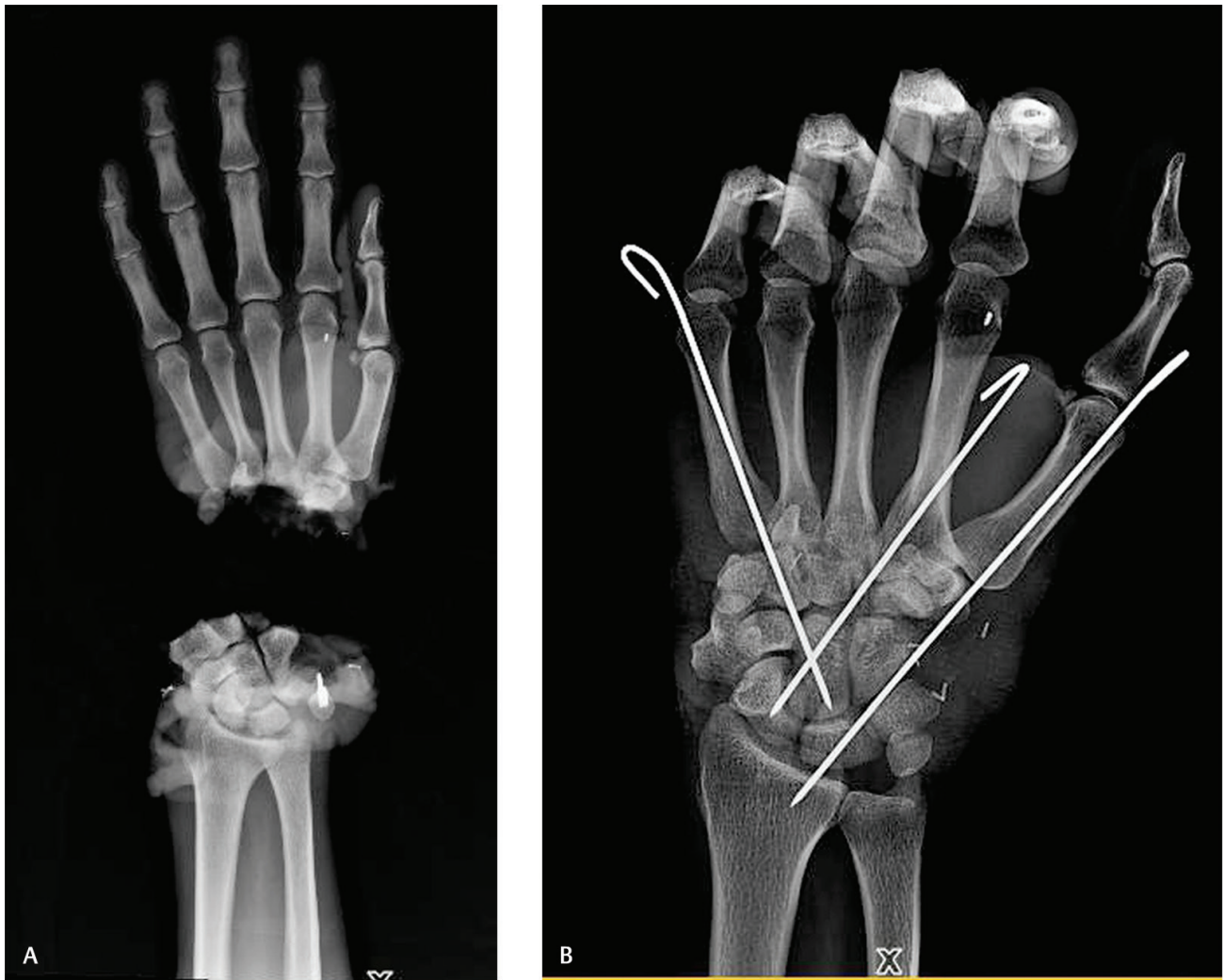myoelectric below-elbow prosthesis costing Rs. 2.5 lakhs, at 6 months from surgery, but he preferred the use of his replanted hand and not the prosthesis-fitted right limb. At 8 weeks, resisted exercises for the flexors were initiated. At 4 months, outrigger splints were given to improve passive range of motion of the metacarpophalangeal joints. At the 1-year clinical follow-up, the patient had no pain, had intact protective sensation, and returned to a new occupation. The last in-person follow-up was at 2 years from surgery, when the final photographs and video were taken. Telemedicine follow-up at 5 years postoperatively showed Disability of the Arm, Shoulder, and Hand (DASH) score of 20. The patient remained employed full time and used his cross-hand for many of his activities (►Fig. 4, ►Video. 1). His activities of daily living (ADLs) and instrumental activities of daily living (IADLs) have been summarized in ►Table 2.

## Discussion

Major traumatic amputations to bilateral upper extremities present challenges to treatment. A comparison of unilateral major replantation versus revision amputation and prosthetic fitting has demonstrated superior functional outcomes in patients with replantation, especially younger patients with more distal injuries.<sup>5</sup> Bilateral upper extremity amputations more than doubles the level of functional impairment.<sup>6</sup> Combined injury to both upper extremities, in which one hand is intact but not replantable and the other hand is unsalvageable, presents a rare opportunity in which cross-hand replantation may be considered.

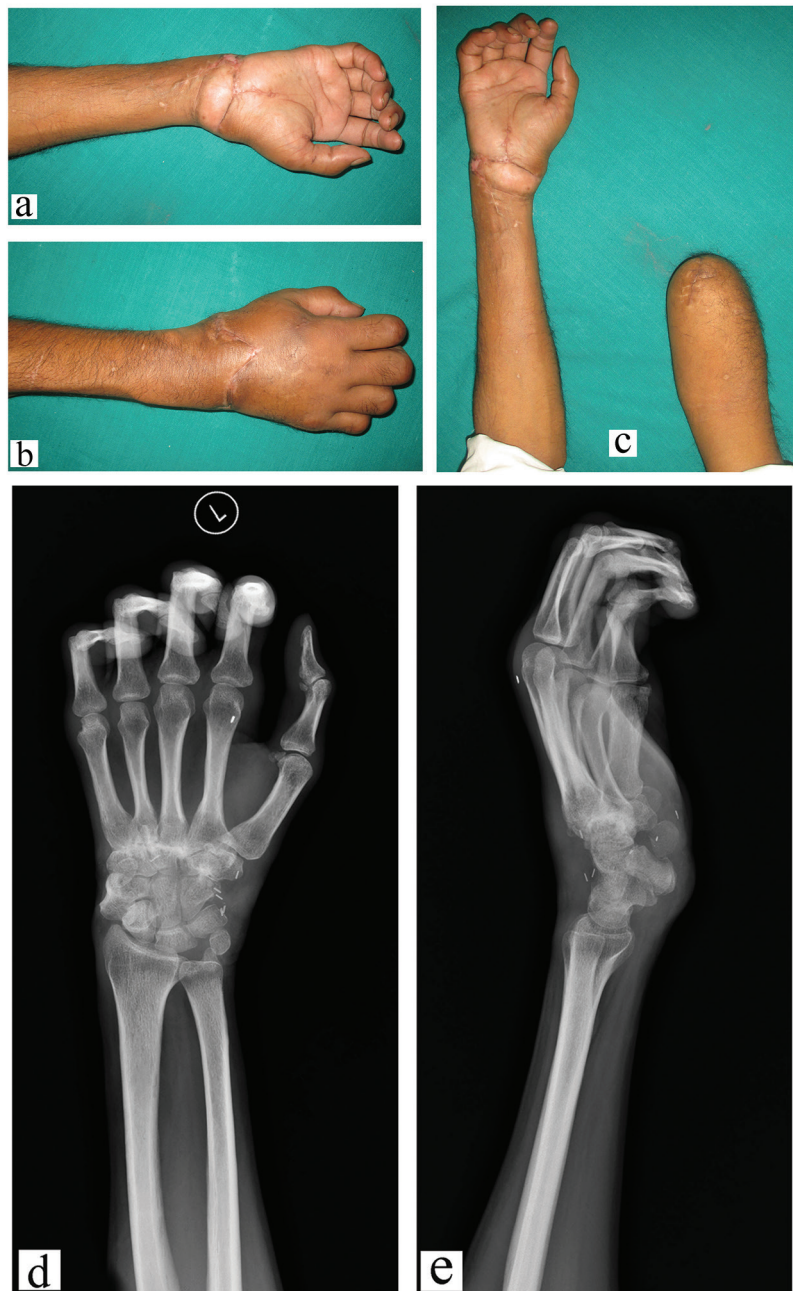The first cross-limb replantation was performed for the lower limbs by Chinese surgeons in the 1970s.<sup>1</sup> Wang et al<sup>2</sup> and Kutz et al<sup>3</sup> first described cross-hand replantation at the level of the distal forearm, and Graham et al.<sup>4</sup> reported a subsequent 9-year follow-up. Since that time, cross-limb replantations have been reported at the distal forearm level,<sup>7</sup> carpometacarpal joint level,<sup>8</sup> and transmetacarpal level.<sup>9</sup> Generally, after cross-hand replantation, patients obtain gross motor ability to grasp and pinch large objects, but have difficulty with manipulation of smaller objects. Protective sensation may be expected, but with poor two-point discrimination. We have presented a successful case of a cross-hand replantation at the level of the metacarpal bases.

There are several advantages to cross-hand replantation at our proposed level. Bony fixation is technically straightforward. By performing the replantation distal to the carpus, the congruity of the proximal and distal radioulnar joints are maintained, and forearm rotation is possible.<sup>3</sup> By maintaining the second and third metacarpal bases, the insertions of flexor carpi radialis (FCR), extensor



**Fig. 2** (a) Intraoperative plain radiograph showing the proposed transfer of the right hand onto the left wrist prior to replantation. (b) Postoperative plain radiograph showing the K-wire fixation after cross-hand replantation. (c) Intraoperative clinical photograph showing the proposed transfer of the right hand onto the left wrist prior to replantation. (d) Intraoperative clinical photograph showing anastomosis of the proximal radial artery to the distal ulnar artery with an interpositional vein graft (white arrow), coaptation of the respective motor and sensory branches of the ulnar nerve (black arrow), and coaptation of the median nerve (yellow arrow).





**Fig. 3** Postoperative clinical photographs (a–c) and plain radiographs of the cross-hand replantation (D, E).



**Fig. 4** Postoperative clinical photographs showing the patient brushing his teeth, combing his hair, using a cell phone, and eating.

#### Video 1

This video illustrates return to function after cross-hand replantation. The patient is seen brushing his teeth, eating with a spoon, combing his hair, writing, and eating with his hand. Online content including video sequences viewable at: <https://www.thieme-connect.com/products/ejournals/html/10.1055/s-0040-1709951>.

carpi radialis longus (ECRL), and extensor carpi radialis brevis (ECRB) are retained on the recipient wrist, allowing for immediate postoperative active wrist motion and finger mobilization through tenodesis. Long lengths of median and ulnar nerves are crucial for tensionless nerve coaptations in cross-hand replantation. The proximal median nerve should be rotated 180° to better match the topography of the motor and sensory fascicles, and the proximal ulnar nerve fascicles must be brought across the wrist to match their respective recipient fascicles.

#### Conclusion

At final follow-up, our patient had no pain, returned to gainful employment, and performed most of his daily living activities independently, despite a “thumb down” position. Thumb transposition in cross-hand transfer has been reported,<sup>10</sup> and may improve aesthetic results of cross-hand transfer, but the added functional benefits of thumb transposition are unclear. Our patient adapted well to the “thumb down” position, and he preferred the function of his replanted cross-hand and chose not to use his contralateral prosthesis. Reconstructive surgeons should remain cognizant of cross-hand replantation as a viable option in these rare situations where bilateral upper extremity prostheses can be avoided.

#### Disclosure

The authors have no sources of financial or material funding to disclose. No portion of this work has been previously presented or published. SRS, HV, and SR were involved in the clinical care of this patient. All authors were involved in the design and conception of this article and

**Table 2** Activities of daily living (ADLs) and instrumental activities of daily living (IADLs)

ADLs/IADLs	Requires no assistance	Some assistance needed	Complete assistance needed	Not applicable
Bathing	✓			
Dressing	✓			
Grooming	✓			
Oral care	✓			
Toileting	✓			
Transferring	✓			
Walking	✓			
Climbing stairs	✓			
Eating	✓			
Shopping		✓		
Cooking			✓	
Managing medications	✓			
Uses the mhone	✓			
Housework	✓			
Laundry	✓			
Driving			✓	
Managing finances	✓			

the writing and revising process. This study was exempt from institutional board review per our institutional policy on small case reports. Our study was performed in accordance with and conforming to the Declaration of Helsinki.

#### Conflict of Interest

None declared.

#### References

- Malt RA, McDowell F. Cable from Cathay. *N Engl J Med* 1973;288(25):1353–1354
- Wang SH, Young KF, Wei JN. Replantation of severed limbs—clinical analysis of 91 cases. *J Hand Surg Am* 1981;6(4):311–318
- Kutz JE, Sinclair SW, Rao V, Carlier A. Cross-hand replantation: preliminary case report. *J Microsurg* 1982;3(4):251–254
- Adkins P, Graham B, Kutz JE. Functional evaluation of an emergency cross-hand replantation: a 9-year follow-up. *J Hand Surg Am* 1992;17(2):214–216
- Baumgartner R. Management of bilateral upper limb amputees. *Orthop Clin North Am* 1981;12(4):971–976
- Graham B, Adkins P, Tsai TM, Firrell J, Breidenbach WC. Major replantation versus revision amputation and prosthetic fitting in the upper extremity: a late functional outcomes study. *J Hand Surg Am* 1998;23(5):783–791
- Reagan DS, Reagan JM. Emergency cross-arm transfer. *Plast Reconstr Surg* 2000;106(3):648–652
- May JW Jr, Rothkopf DM, Savage RC, Atkinson R. Elective cross-hand transfer: a case report with a five-year follow-up. *J Hand Surg Am* 1989;14(1):28–34
- Zhang YL, Yang KF, Li C, Wei JN. Transmetacarpal replantation of the right hand onto the left. *J Hand Surg [Br]* 1991;16(4):392–394
- Cavadas PC, Ibañez J, Landin L. Elective cross-hand transfer with thumb transposition: case report. *J Hand Surg Am* 2008;33(10):1813–1819