



# Extremities Soft Tissue Sarcomas, more Common and as Dangerous as Bone Sarcomas\*

## *Sarcomas de partes moles nos membros, mais comuns e tão graves quanto os sarcomas ósseos*

Karen Voltan<sup>1</sup> André Mathias Baptista<sup>2</sup> Maurício Etchebehere<sup>1</sup>

<sup>1</sup> Department of Orthopedics and Traumatology, Faculdade de Ciências Médicas, Universidade Estadual de Campinas, Campinas, SP, Brazil

<sup>2</sup> Institute of Orthopedics and Traumatology, Hospital das Clínicas, Faculdade de Medicina, Universidade de São Paulo, São Paulo, SP, Brazil

Address for correspondence Karen Voltan, MD, Department of Orthopedics and Traumatology, Faculdade de Ciências Médicas da Universidade Estadual de Campinas (FCM-UNICAMP), Rua Tessália Vieira de Camargo, 126, Cidade Universitária, Campinas, SP, 13083-887, Brazil (e-mail: karenvoltan@hotmail.com; karenvoltan@gmail.com; kvoltan@icloud.com).

Rev Bras Ortop 2021;56(4):419–424.

### Abstract

Musculoskeletal sarcomas are rare diseases that require attention. They often present high degree of malignancy at diagnosis and, if underestimated, they can evolve aggressively locally and systemically. They present as soft tissue sarcoma and bone sarcomas, with soft tissue being four to five times more common. Most soft tissue sarcomas occur in the extremities. The most common subtypes in children and adolescents are rhabdomyosarcoma and synovial sarcoma; in adults, undifferentiated pleomorphic sarcoma, liposarcoma, leiomyosarcoma, myxofibrosarcoma and synovial sarcoma; all with a high degree of histological malignancy. Many soft tissue sarcomas are confused with benign soft tissue tumors, 100 times more common, so they are resected without the necessary planning, resulting in amputation of a limb that could have been preserved. As in all cancers, the most important prognostic factor is metastatic disease. When it is present, the overall survival rate falls around 20 to 30%. Survival rates are generally similar between bone and soft tissue sarcomas. So soft tissue sarcomas, in addition to being more prevalent, are as aggressive as bone sarcomas, deserving a lot of attention from orthopedic surgeons, who are often the first line of care of carriers of these tumors.

### Keywords

- ▶ epidemiology
- ▶ early detection of cancer
- ▶ metastasis
- ▶ neoplasm
- ▶ bone tissue
- ▶ prognostic factors
- ▶ soft tissue sarcoma

### Resumo

Os sarcomas musculoesqueléticos são doenças raras que exigem atenção. Frequentemente, apresentam alto grau de malignidade ao diagnóstico e se subestimados podem evoluir de forma agressiva local e sistemicamente. Apresentam-se como sarcoma de partes moles e sarcomas ósseos, sendo os de partes moles quatro a cinco vezes mais comuns. A maioria dos sarcomas de partes moles ocorre nos membros. Os subtipos mais comuns nas crianças e adolescentes são o rhabdomyosarcoma e o sarcoma

\* Work developed in the Department of Orthopedics and Traumatology, Faculdade de Ciências Médicas da Universidade Estadual de Campinas (FCM-UNICAMP), SP, Brazil.

received  
September 24, 2019  
accepted  
February 20, 2020  
published online  
September 25, 2020

DOI <https://doi.org/10.1055/s-0040-1712136>.  
ISSN 0102-3616.

© 2020. Sociedade Brasileira de Ortopedia e Traumatologia. All rights reserved.  
This is an open access article published by Thieme under the terms of the Creative Commons Attribution-NonDerivative-NonCommercial-License, permitting copying and reproduction so long as the original work is given appropriate credit. Contents may not be used for commercial purposes, or adapted, remixed, transformed or built upon. (<https://creativecommons.org/licenses/by-nc-nd/4.0/>)  
Thieme Revinter Publicações Ltda., Rua do Matoso 170, Rio de Janeiro, RJ, CEP 20270-135, Brazil

**Palavras-chave**

- ▶ epidemiologia
- ▶ detecção precoce de cancer
- ▶ metástase
- ▶ neoplasia
- ▶ tecido ósseo
- ▶ fatores prognósticos
- ▶ sarcoma de tecidos moles

sinovial, nos adultos o sarcoma pleomórfico indiferenciado, lipossarcoma, leiomiomasarcoma, mixofibrossarcoma e sarcoma sinovial; todos de alto grau de malignidade histológica. Muitos sarcomas de partes moles são confundidos com tumores benignos de partes moles, 100 vezes mais comuns, por isso são ressecados sem o planejamento necessário, acarretando amputação de um membro que poderia ter sido preservado. Como em todos os cânceres, o fator prognóstico mais importante é a doença metastática. Na sua vigência, a taxa de sobrevida global cai em torno de 20 a 30%. As taxas de sobrevida no geral são parecidas entre os sarcomas ósseos e de partes moles. Portanto o sarcoma de partes moles, além de mais prevalente, mostra-se tão agressivo quanto os sarcomas ósseos. Por isso merece muita atenção dos ortopedistas, que frequentemente são a primeira linha de atendimento dos portadores destes tumores.

**Introduction**

Musculoskeletal sarcomas are rare diseases of mesenchymal origin that may appear at any age and that may develop anywhere in the body. These neoplasms are classified as soft tissue sarcomas (STS) or bone sarcomas.

In 2013, the World Health Organization (OMS) described more than 50 types of soft tissue sarcomas and about 30 types of bone sarcomas.<sup>1</sup> Sarcomas are a heterogeneous group of more than 100 tumors.<sup>2</sup>

**Epidemiology**

Despite this great variety, musculoskeletal sarcomas account for less than 1% of adult malignant tumors and around 15% of pediatric malignant tumors<sup>1,3-5</sup>; therefore, STS account for less than 1% if all malignant tumors. Bone sarcomas are even more rare and account for around 0.2%.<sup>1,6</sup> Therefore, STS occur 4 to 5 times more often than bone sarcomas. The worldwide incidence rate of STS varies from 1.8 to 5.0 per 100,000 persons/year.<sup>7</sup> They may appear at any age, although over 65% of these sarcomas occur in patients over the age of 65.<sup>5</sup> According to the Scandinavian Sarcoma Group (SSG) from 1987 to 2011, 6,027 cases of soft tissue sarcoma were registered, that is, a rate of 1.5 to 2.0 per 100,000 inhabitants/year.<sup>8</sup> In Japan, the Bone and Soft Tissue Tumor Registry (BSTT), the specific cancer registration body throughout the country for bone and soft tissue tumors registered, from 2006 to 2012, 44,709 patients with benign and malignant musculoskeletal tumors. Out of these cases, 2,773 were of malignant bone tumors and 8,228 were of malignant soft tissue tumors.<sup>9,10</sup> In 2004, around 8,700 new STS cases were diagnosed in the US and 1,500 in the United Kingdom.<sup>5</sup> In Europe, the incidence of sarcomas in general is 6 cases per 100,000, with 28,000 cases per year. In 2008, STS accounted for almost 87% of all sarcomas.<sup>11</sup> The American Cancer Society estimates that in 2019 there will be approximately 1,762,450 new cases of cancer diagnosed in the US, leading to 606,880 deaths.<sup>4</sup> Out of these cases, around 3,500 will affect bones and joints and 1,660 will lead to death; the incidence of soft tissue tumors will be 12,750 cases, with approximately 5,270 deaths.<sup>4</sup>

A general orthopedic surgeon will find during his or her career at least one osteosarcoma or Ewing sarcoma.<sup>12</sup> Because there is a higher prevalence of STS, a general orthopedist will probably see four or more of these neoplasms.

**Clinical Aspects**

Musculoskeletal sarcomas are a heterogeneous group of tumors with different clinical manifestations, locations, evolutions and managements. Approximately 75% of STS are located in the extremities and girdles. The thigh is the most commonly affected location.<sup>1</sup> About 10% of the cases affect the trunk and retroperitoneum.<sup>1</sup>

The most frequent malignant soft tissue tumors in children and adolescents are rhabdomyosarcoma and synovial sarcoma.<sup>13</sup> The most frequent STS in adults are the undifferentiated pleomorphic sarcoma, liposarcoma, leiomyosarcoma, myxofibrosarcoma and synovial sarcoma.<sup>1,6</sup> Metastatic disease is the major cause of death related to sarcomas. Metastasis of soft tissue sarcomas and high grade bone sarcomas disseminate to the lungs through the blood.<sup>14</sup> As around three quarters of STS are histologically classified as having a high grade of malignancy,<sup>1</sup> during the diagnosis investigation and staging, it is expected that 10% of patients will have metastasis, predominantly to the lungs.<sup>1</sup> During the follow up period, about 50% of STS patients develop distant metastasis with an average global survival of 12 to 18 months. From the patients with metastasis, less than 20% will be alive in two years.<sup>15</sup> In addition to the presence of metastases, the surgical margins of these sarcomas have a great impact on the prognosis.<sup>16,17</sup>

Although less frequent in the pediatric group, STS may affect this age range. Approximately 50% of the cases of STS in the pediatric group are rhabdomyosarcomas, of which the subtypes embryonic (head, neck and genitourinary tract) and alveolar (thorax and extremities) are the most common. Rhabdomyosarcoma botryoid and other subtypes are less frequent.<sup>18</sup> The main characteristic of embryonic rhabdomyosarcoma is its bimodal presentation, that is, it has its peaks of incidence in patients with ages 2 to 6 and 15 to 19.<sup>18,19</sup> The alveolar subtype is the most common in adolescents.<sup>18</sup>

The greatest problems related to the approach to STS result from mistaken concepts that are still part of clinical

medical practice. One of them is that malignant soft tissue tumors should be painful, grow rapidly and be deep. Actually, they may grow slowly, be painless and located on the surface.<sup>20</sup> For this reason, the clinical condition may go on for a long time and, even in developed countries, referral to reference services may take from 6 to 14 months.<sup>21</sup>

## Diagnosis and staging

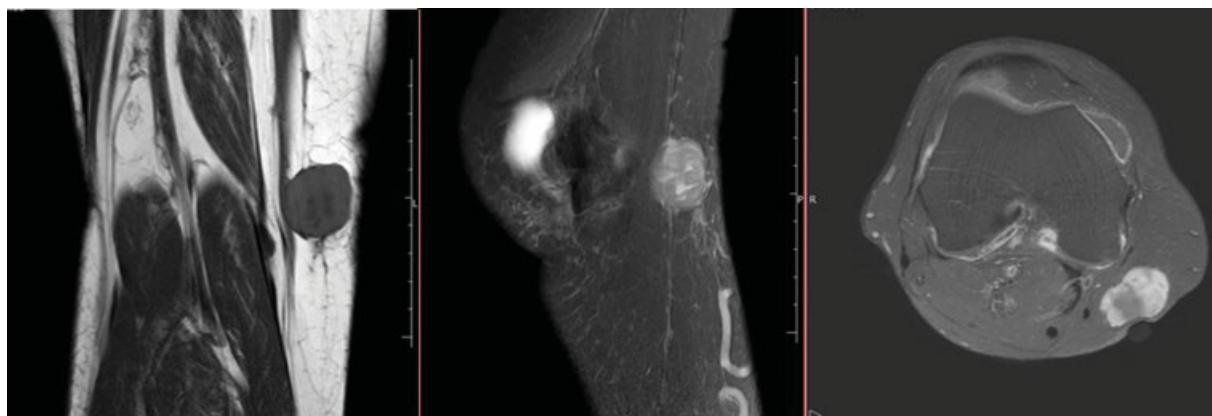
In oncology centers of reference, patients are cared by different teams of highly specialized professionals. The same service will carry out tests for local and distant staging. For this, magnetic resonance imaging (MRI) is mandatory. Most patients still need a biopsy. However, biopsies cannot be performed in soft tissue tumors that show clearly fatty content on MRI. In 2018, the 8th edition of the Cancer Manual Staging of the American Joint Committee on Cancer (AJCC) updated the staging system for evaluation of soft tissue tumors (TNM system). This system considers the histologic grade of the tumor, its extent, the presence of lymph nodes and the presence of metastases. There is no longer any differentiation between superficial and deep tumors. The extent (T) has four levels (T1 to T4): the tumor is smaller than 5 cm (T1), the tumor is larger than 5 cm but not more than 10 cm (T2), the tumor is larger than 10 cm but not more than 15 cm (T3) and the tumor is larger than 15 cm (T4), the spread to nearby lymph nodes (N) and the spread to distant sites (M). In sarcomas, the involvement of lymph nodes is defined as systemic involvement by the neoplasm and has the same importance as a distant metastasis. Therefore, N0 and M0 means no systemic involvement, but N1 or M1 is considered systemic involvement. Patients are classified in 4 stages, from I to IV, with some subdivisions. Tumors that present N1 or M1 are classified in stage IV, the most advanced.<sup>22</sup>

The Birmingham group described a criterion that estimates the probability of malignancy in soft tissue tumors: the tumor is larger than 4.3 cm (the size of a golf ball), progressively increases in size, is located under the fascia and is painful.

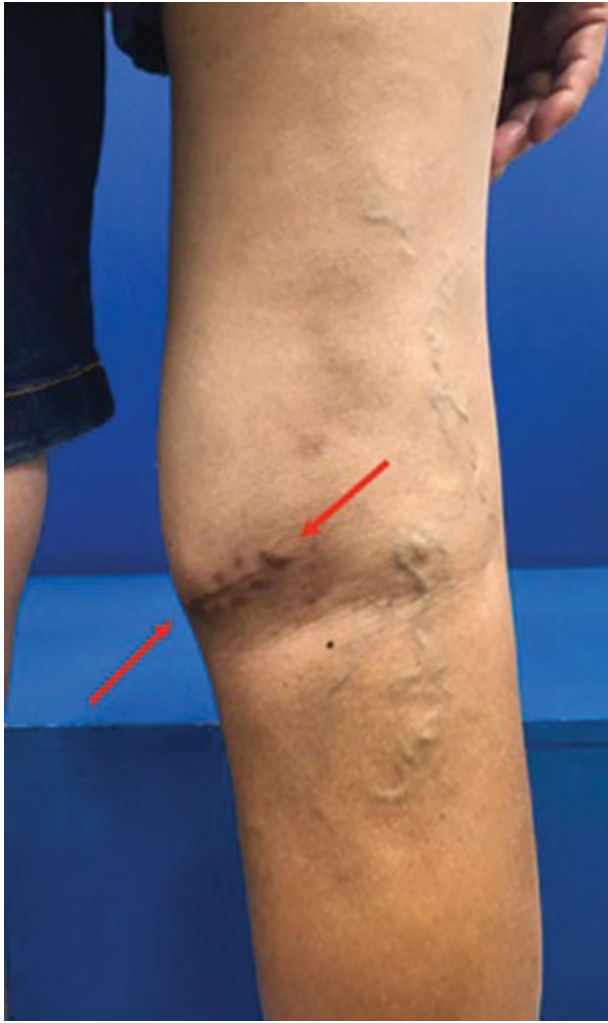The two first of these criteria are the most important.<sup>23</sup> If three or four criteria are positive, there is a possibility of more than 80% of the soft tissue lesion's being malignant.<sup>24</sup>

The imaging test of choice to evaluate a soft tissue lesion is the MRI of the affected segment after a gadolinium contrast injection. The MRI enables us to evaluate the features of the tumor, its extent and define the best location to carry out the biopsy. The main characteristics to be considered in an MRI are: whether the tumor is solid and if there is fat tissue. Therefore, any soft tissue lesion that is not cystic and does not show any sign of homogeneous fat in the MRI should be potentially treated as a sarcoma (→ **Figure 1**). The surgeon must plan the surgical approach and biopsy technique to allow for resection of the entire tract in block, together with the tumor. Consequently, procedures with transversal incision techniques or following lines of force should be avoided when performing biopsies on extremities. The biopsy incision must follow the line of the muscle fibers and violate the smallest possible number of compartments (→ **Figure 2**). Currently, many biopsies are performed with needles and guided by ultrasound or computerized tomography (TC) imaging. This demands a rapport between the surgeon and interventionist radiologist to guarantee that the procedure be performed through the proper access.

Staging must be conducted before resection of the tumor, and the physician must request at least a thoracic computerized tomography to track any lung metastasis.<sup>25</sup> Several services of reference in oncology offer PET-CT scans using 18F-fluorodeoxyglucose (18F-FDG) for staging. The PET-CT scan evaluates the glucose metabolism and the more aggressive the tumor the more glucose it will absorb. Because it evaluates the entire body, in addition to the lungs, the PET-CT scan changes the staging grade when it detects metastases of doubtful diagnosis inside or outside the lungs. In addition, the standard uptake value (SUV max) showed in the PET-CT may predict not only the biological activity but also the grade of the tumor. This has become a useful prognostic factor in reviewing the survival rate of patients with STS. The PET-CT scan also plays an important role in the evaluation of the response to chemotherapy and in planning the amount of radiotherapy. Because it allows for early evaluation of the aggressiveness of the tumor, the PET-CT scan may indicate more aggressive resections with proper margins while at the same time avoiding unnecessary biopsies.<sup>3,11,26</sup>



**Fig. 1** Knee magnetic resonance imaging cuts. ((A) coronal sequence T1, ((B) Sagittal SPAIR T2, ((C) axial T1 post GD. Note that the lesion is solid, relatively small, size close to that of a golf or table tennis ball. This is a high-grade soft tissue sarcoma.



**Fig. 2** Photo of the same patient in ► **Figure 1**. Posterior region of the right knee of a patient submitted to an open biopsy with inadequate access route. It's possible to observe a transverse scar that will need to be completely resected. Skin closure may be compromised.

Despite the attempts to avoid unnecessary biopsies, this procedure is still indicated for the vast majority of patients. The material for anatomopathological examination must be evaluated by a pathologist with experience in musculoskeletal tumors. Currently, pathologists supplement their histopathology analysis with a panel of immunohistochemical markers. Molecular tests have been used to supplement the diagnosis. Regardless of the need to molecular testing to support certain diagnoses, the detailed genetic analysis of the tumor tissue of a patient may have important implications in the therapy.<sup>27</sup> Techniques such as Fluorescent In Situ Hybridization (FISH) and Next Generation Sequencing (NGS) are slowly showing the existence, within the same diagnosis, of different subtypes of tumor, with patterns which are often similar and which will probably need target therapies for their treatment, probably generating a positive impact on survival.<sup>2,27</sup>

## Treatment

Treatment of STS depends essentially on histological grading, tumor's location and its extent. Protocols use neoadjuvant

(preoperative) or adjuvant chemotherapy and combine surgical treatment with radiotherapy before or after surgery. Resection of soft tissue sarcomas seeks to achieve microscopic surgical margins, free of tumor cells.<sup>16</sup> The resection margins of sarcomas are currently defined as R0 (negative microscopic margin), R1 (positive microscopic margin), R2 positive macroscopic positive margin, that is, evident residual tumor remaining). The extent of the R0 margin is not important provided that there is no residual tumor,<sup>16</sup> that is, there is no difference between a slim margin and three-centimeter margin. Despite the incessant search to preserve the extremity with STS, amputation is still indicated in cases where the free microscopic surgical margins (R0) cannot be reached without the resection of the tumor affecting critical structures such as the large neurovascular bundles. As mentioned before, patients submitted to unplanned resection of a STS using transversal access have greater possibility of having to undergo amputation. It is essential to expand the surgical margins in patients submitted to unplanned resections of sarcomas. This second procedure will bring the survival prognosis of patients submitted to unplanned procedures close to that of patients submitted to a planned treatment.<sup>28</sup>

Patients with rhabdomyosarcoma frequently have metastasis when diagnosed, and for such reason need neoadjuvant systemic treatment. Polychemotherapy is the foundation for treatment of rhabdomyosarcoma and should be used in all patients. Normally, STS respond well (80–90%) to chemotherapy and radiotherapy. As a consequence, resection becomes a more conservative procedure and the radiotherapy doses are reduced to limit the risk of sequelae.<sup>13</sup>

## Prognosis

Benign soft tissue tumors, such as lipomas, are 100 times more frequent than soft tissue sarcomas.<sup>23</sup> Because they are rare, many physicians and patients do not recognize STS, which contributes to delays in the investigation and diagnosis. This leads to an increase in the extent of the lesions. Tumors of less than 5 cm and depth are bad prognostic factors.<sup>29</sup> In addition, the greater incidence of benign soft tissue tumors frequently leads to unplanned resections of sarcomas, which leave residual tumor. Hanasilo et al. report that services of reference receive up to 50% of new cases of patients with STS who were submitted to unplanned resections, and 90% of these patients have a residual tumor.<sup>28</sup> After an unplanned resection, there is a greater risk of complications and an amputation may be needed to obtain a margin free of tumor cells.<sup>23,30,31</sup>

Global survival of patients with musculoskeletal tumors depends on several factors, such as the tumor's histological subtype, degree of malignancy, age of the patient, location, extent, surgical margins achieved, the presence of metastasis, adjuvant/neoadjuvant chemotherapy and radiotherapy.

Baptista et al.<sup>32</sup> report that in patients diagnosed with non-metastatic synovial sarcoma the prognostic factors unfavorable to survival were the high histological grade, location (tumors close to the knee or elbow) and spontaneous necrosis

of the tumor greater than 25%. Local relapse had no influence on survival rates. Zumarraga et al.<sup>33</sup> reported that in patients with myxofibrosarcoma a worse global survival prognosis was related to the histological grade of the tumors, compromised margins, local relapse and distant metastasis. Wu et al.<sup>34</sup> report that myxoid liposarcomas age (over 30), male sex, tumor grade (high grade) and size of the tumor (greater than 10 cm) were independent prognostic factors for global survival and in the specific disease in patients with STS in the extremities. Tsuda et al.<sup>35</sup> reported that in patients aged 65 and over negative surgical margins were related to a greater survival rate. Nakamura et al.<sup>36</sup> reported that the presence of a systemic inflammation is associated with a worse prognosis. Increase in the levels of C-Reactive Protein (CRP), hypoalbuminemia and anemia reflect the tumor's aggressive behavior. The first two serum markers may be useful to predict the survival of patients with metastatic disease at the time of diagnosis. Ishihara et al. reported that the histological grade of malignancy (high grade), the extent of the tumor (greater than 10 cm) and metastases change the prognosis. Local relapse is not actually related to the occurrence of metastases, extent of the tumor, histological grade and death.<sup>37</sup>

Patients with rhabdomyosarcoma have, in general, a global survival of 70% in 5 years. In several pediatric series, patients older than 10 years of age were reported as having a worse prognosis than that of younger children.<sup>13</sup> In bone tumors (osteosarcoma and Ewing sarcoma), metastatic disease reduced global survival rate to between 20% and 30%. About 15 to 20% of the patients with osteosarcomas and 15% to 35% of the patients with Ewing sarcoma already had macroscopic evidence of metastasis when diagnosed.<sup>38-42</sup> Literature shows that soft tissue tumors are tumors with a high metastatic potential and great chance of local relapse if not properly resected.<sup>16,17</sup> Approximately 10% of the patients present metastasis when diagnosed and about 50% of the patients with STS will develop them. Less than 20% of these patients will be alive in 2 years. Therefore, as most STS occur in the extremities, orthopedists are likely to the first professionals to approach these lesions.

## Final Considerations

In conclusion, it is important that any soft tissue tumor be submitted to proper imaging evaluation and, in the tumor is solid and non-fatty, it must be biopsied with a proper technique before undergoing a resection without planning, which may compromise the patient's treatment and prognosis.

### Conflict of Interests

The authors have no conflict of interests to declare.

## References

- Fletcher CDM, Gronchi A. Tumors of soft tissue: Introduction. In: Fletcher CDM, Bridge JA, Hogendoorn PCW, Mertens F, editors. WHO Classification of Tumors of Soft Tissue and Bone. Fourth Edition. Geneva: The International Agency for Research on Cancer (IARC); 2013:14-18
- Groisberg R, Roszik J, Conley A, Patel SR, Subbiah V. The Role of Next-Generation Sequencing in Sarcomas: Evolution From Light Microscope to Molecular Microscope. *Curr Oncol Rep* 2017;19(12):78
- Kirane A, Crago AM. The importance of surgical margins in retroperitoneal sarcoma. *J Surg Oncol* 2016;113(03):270-276
- Siegel RL, Miller KD, Jemal A. Cancer statistics, 2019. *CA Cancer J Clin* 2019;69(01):7-34
- Clark MA, Fisher C, Judson I, Thomas JM. Soft-tissue sarcomas in adults. *N Engl J Med* 2005;353(07):701-711
- Brown HK, Schiavone K, Gouin F, Heymann MF, Heymann D. Biology of Bone Sarcomas and New Therapeutic Developments. *Calcif Tissue Int* 2018;102(02):174-195
- Wibmer C, Leithner A, Zielonke N, Sperl M, Windhager R. Increasing incidence rates of soft tissue sarcomas? A population-based epidemiologic study and literature review. *Ann Oncol* 2010;21(05):1106-1111
- Trovik C, Bauer HCF, Styring E, et al. The Scandinavian Sarcoma Group Central Register: 6,000 patients after 25 years of monitoring of referral and treatment of extremity and trunk wall soft-tissue sarcoma. *Acta Orthop* 2017;88(03):341-347
- Ogura K, Higashi T, Kawai A. Statistics of bone sarcoma in Japan: Report from the Bone and Soft Tissue Tumor Registry in Japan. *J OrthopSci* 2017;22(01):133-143
- Ogura K, Higashi T, Kawai A. Statistics of soft-tissue sarcoma in Japan: Report from the Bone and Soft Tissue Tumor Registry in Japan. *J OrthopSci* 2017;22(04):755-764
- Leal AL, Etchebehere M, Santos AO, et al. Evaluation of soft-tissue lesions with (18)F-FDG PET/CT: initial results of a prospective trial. *Nucl Med Commun* 2014;35(03):252-259
- Widhe B, Widhe T. Initial symptoms and clinical features in osteosarcoma and Ewing sarcoma. *J Bone Joint Surg Am* 2000;82(05):667-674
- Ferrari A, Dirksen U, Bielack S. Sarcomas of Soft Tissue and Bone. *Prog Tumor Res* 2016;43:128-141
- Kubo T, Furuta T, Johan MP, Ochi M. Prognostic significance of (18) F-FDG PET at diagnosis in patients with soft tissue sarcoma and bone sarcoma; systematic review and meta-analysis. *Eur J Cancer* 2016;58:104-111
- Carbonnaux M, Brahmi M, Schiffler C, et al. Very long-term survivors among patients with metastatic soft tissue sarcoma. *Cancer Med* 2019;8(04):1368-1378
- Harati K, Goertz O, Pieper A, et al. Soft Tissue Sarcomas of the Extremities: Surgical Margins Can Be Close as Long as the Resected Tumor Has No Ink on It. *Oncologist* 2017;22(11):1400-1410
- Hasley I, Gao Y, Blevins AE, Miller BJ. The Significance of a "Close" Margin in Extremity Sarcoma: A Systematic Review. *Iowa Orthop J* 2018;38:123-130
- Egas-Bejar D, Huh WW. Rhabdomyosarcoma in adolescent and young adult patients: current perspectives. *Adolesc Health Med Ther* 2014;5:115-125
- Thway K. Sarcomas. In: Low KB. *Brenner's Encyclopedia of Genetic*. 2nd ed. Philadelphia: Elsevier; 2013:327-331
- Park JH, Kang CH, Kim CH, Chae IJ, Park JH. Highly malignant soft tissue sarcoma of the extremity with a delayed diagnosis. *World J Surg Oncol* 2010;8:84
- Brouns F, Stas M, De Wever I. Delay in diagnosis of soft tissue sarcomas. *Eur J Surg Oncol* 2003;29(05):440-445
- Cates JMM. The AJCC 8<sup>th</sup> edition staging system for soft tissue sarcoma of the extremities or trunk: A Cohort study of the SEER database. *J Natl Compr Canc Netw* 2018;16(02):144-152
- Nandra R, Forsberg J, Grimer R. If your lump is bigger than a golf ball and growing, think Sarcoma. *Eur J Surg Oncol* 2015;41(10):1400-1405
- Grimer RJ, Briggs TWR. Earlier diagnosis of bone and soft-tissue tumours. *J Bone Joint Surg Br* 2010;92(11):1489-1492
- Taieb S, Ceugnart L, Gauthier H, Penel N, Vanseymortier L. [Soft tissue sarcoma: role of imaging for initial diagnosis and treatment]. *Cancer Radiother* 2006;10(1-2):22-33

- 26 Etchebehere EC, Hobbs BP, Milton DR, et al. Assessing the role of <sup>18</sup>F-FDG PET and <sup>18</sup>F-FDG PET/CT in the diagnosis of soft tissue musculoskeletal malignancies: a systematic review and meta-analysis. *Eur J Nucl Med Mol Imaging* 2016;43(05):860–870
- 27 Dancsok AR, Asleh-Aburaya K, Nielsen TO. Advances in sarcoma diagnostics and treatment. *Oncotarget* 2017;8(04):7068–7093
- 28 Hanasilo CE, Casadei MS, Auletta L, Amstalden EM, Matte SR, Etchebehere M. Comparative study of planned and unplanned excisions for the treatment of soft tissue sarcoma of the extremities. *Clinics (São Paulo)* 2014;69(09):579–584
- 29 Jernigan EW, Esther RJ. Soft tissue masses for the general orthopedic surgeon. *OrthopClin North Am* 2015;46(03):417–428, xixi
- 30 George A, Grimer R. Early symptoms of bone and soft tissue sarcomas: could they be diagnosed earlier? *Ann R CollSurgEngl* 2012;94(04):261–266
- 31 Pisters PWT, Leung DHY, Woodruff J, Shi W, Brennan MF. Analysis of prognostic factors in 1,041 patients with localized soft tissue sarcomas of the extremities. *J ClinOncol* 1996;14(05):1679–1689
- 32 Baptista AM, Camargo OP, Croci AT, et al. Synovial sarcoma of the extremities: prognostic factors for 20 nonmetastatic cases and a new histologic grading system with prognostic significance. *Clinics (São Paulo)* 2006;61(05):381–386
- 33 Zumárraga JP, Batista FAR, Baptista AM, Caiero MT, Martino LPR, de Camargo OP. Prognostic factors in patients with appendicular myxofibrosarcoma. *ActaOrtop Bras* 2018;26(05):320–324
- 34 Wu J, Qian S, Jin L. Prognostic factors of patients with extremity myxoidliposarcomas after surgery. *J OrthopSurg Res* 2019;14(01):90
- 35 Tsuda Y, Ogura K, Kobayashi E, et al. Impact of geriatric factors on surgical and prognostic outcomes in elderly patients with soft-tissue sarcoma. *Jpn J ClinOncol* 2017;47(05):422–429
- 36 Nakamura T, Katagiri H, Shido Y, et al. Analysis of Factors for Predicting Survival in Soft-tissue Sarcoma with Metastatic Disease at Initial Presentation. *Anticancer Res* 2017;37(06):3137–3141
- 37 Ishihara H, Garcia-Filho R, Korukian M, Ponte F. Sarcoma de tecidos moles: fatoresprognosticos. *Rev Bras Ortop* 2004;39(11–12):637–647
- 38 Anderson ME. Update on Survival in Osteosarcoma. *OrthopClin North Am* 2016;47(01):283–292
- 39 Duchman KR, Gao Y, Miller BJ. Prognostic factors for survival in patients with high-grade osteosarcoma using the Surveillance, Epidemiology, and End Results (SEER) Program database. *Cancer Epidemiol* 2015;39(04):593–599
- 40 Kager L, Tamamyan G, Bielack S. Novel insights and therapeutic interventions for pediatric osteosarcoma. *Future Oncol* 2017;13(04):357–368
- 41 Meazza C, Scanagatta P. Metastatic osteosarcoma: a challenging multidisciplinary treatment. *Expert Rev Anticancer Ther* 2016;16(05):543–556
- 42 Macedo CR, Petrilli AS. Tumoresósseosmalignosnacriança e no adolescente. *Pediatr Mod* 1999;35(08):600–608