

Letter to the Editor

Tinea pseudoimbricata

*Abhishek Bhardwaj^{*1}, Bandhala Rajan¹, Ravikumar SM¹*
¹Department of Dermatology, Venereology & Leprology,
All India Institute of Medical Sciences, Jodhpur

Sir,

Among all branches of Medicine, Dermatology is unique. Nowhere else does physical examination holds precedence over history. Professor Peter Mortimer, Professor of Dermatological Medicine at University of London, in his foreword to the first edition of Oxford Handbook of Medical Dermatology has astutely opined that, "Dermatology is arguably the most clinical of all Medical specialities because it relies less on investigation and more on good old fashioned observation and interpretation of symptoms and signs for diagnosis."

We therefore present an important facet of clinical observation. A teenage boy came to the Dermatology OPD with complaints of itching and raised, spreading lesions on the skin of chest and abdomen for the past two months. The problem began from the groin first, when he started applying creams that were kept in home. The itching diminished but the skin lesions started to develop at other spots on the trunk. We showed him samples of commonly abused combination creams, out of which he identified two. Both the preparations contained Clobetasol, which is a super potent steroid.

The examination of lesions revealed multiple annular plaques of various sizes, mostly seen over chest and abdomen with few plaques over back. The groin on both sides had similar plaques, which were showing tendency to spread downwards towards the thigh (Fig. 1). On close inspection in most plaques multiple 'rings within

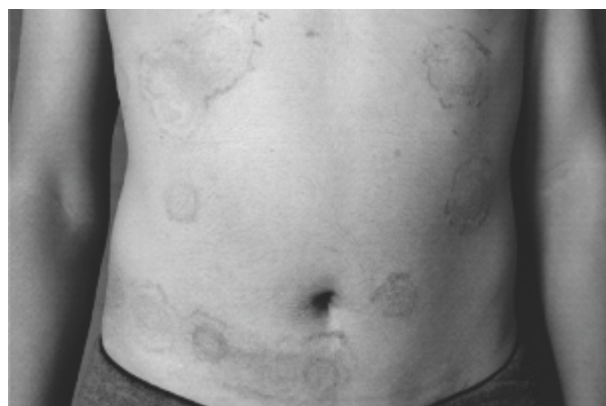


Fig. 1: Multiple, annular plaques of various sizes over chest and abdomen.

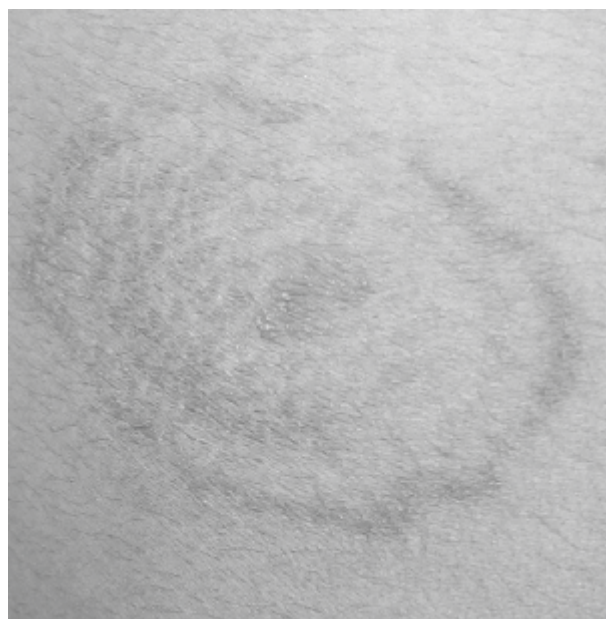


Fig. 2: Close up of 'Rings within Ring'

ring' were seen (Fig. 2). Also noted, was mild scaling and epidermal atrophy, the latter attributable to steroid abuse.

Correspondence: *Dr. Abhishek Bhardwaj, Associate Professor, Department of Dermatology, Venereology & Leprology, AIIMS, Jodhpur -342005.

A diagnosis of *Tinea pseudoimbricata* was made and the blood sugar of the boy was sent along with scraping for KOH mount. The blood sugar was within normal limits and the scraping showed multiple septate, hyaline hyphae arranged at acute angles.

It is noteworthy that, *Tinea imbricata* is a rare, superficial fungal infection caused by *Trichophyton concentricum*. It is endemic to the South Pacific and regions of Central and South America (1). It has many more concentric circles and is usually generalized. *Tinea pseudoimbricata* on the other hand refers to usually two or rarely, three concentric circles within a lesion of a 'Ring worm'. 'Rings within the ring' and 'double-edged tinea' are

descriptions to familiarize non-dermatologists with its presentation. Its importance is that it should immediately raise the suspicion of topical corticosteroid abuse (2). Other causes of immunosuppression, which are clinically appropriate, should also be ruled out.

References

1. Burns C, Valentine J (2016). *Tinea Imbricata*- images in clinical medicine. *N Engl J Med* **375**:2272.
2. Verma S (2017). *Tinea pseudoimbricata*. *Indian J Dermatol Venereol Leprol* **83**:344-345.