




# Endoscopic Transnasal Odontoidectomy

Cesare Zoia<sup>1</sup>  Daniele Bongetta<sup>2,3</sup> Sabino Luzzi<sup>1,2</sup>

<sup>1</sup>Neurosurgery Unit, Fondazione IRCCS Policlinico San Matteo, Pavia, Italy

<sup>2</sup>Neurosurgery Unit, Department of Clinical-Surgical, Diagnostic and Pediatric Sciences, Università degli Studi di Pavia, Pavia, Italy

<sup>3</sup>Neurosurgery Unit, Ospedale Fatebenefratelli e Oftalmico, ASST Fatebenefratelli Sacco, Piazzale Principessa, Milano, Italy

**Address for correspondence** Cesare Zoia, MD, PhD, Neurosurgery Unit, Fondazione IRCCS Policlinico San Matteo, viale Golgi 19, 27100, Pavia, Italy (e-mail: gioiaoffice@gmail.com).

J Neurol Surg B 2021;82(suppl S1):S10–S11.

## Abstract

### Keywords

- ▶ odontoidectomy
- ▶ endoscopic transnasal surgery
- ▶ endoscopic cervical decompression
- ▶ craniovertebral junction

**Background** Odontoidectomy may represent the treatment of choice for symptomatic ventral craniovertebral junction stenosis in selected cases. An endoscopic transnasal approach has been proposed as an alternative to a classic transoral approach.

**Method** We report a case of a patient with a craniovertebral junction stenosis due to the ossification of the posterior ligament. The clinical and radiological records of the patient and a step-by-step description of the surgical technique are presented (▶ **Fig. 1**).

**Conclusion** Endoscopic transnasal odontoidectomy provides a direct access to the dens and adjacent structures of the anterior upper cervical spine with a less invasive burden on the oropharyngeal structures.

The link to the video can be found at: <https://youtu.be/Ofrk1sFTV9I>.

### Conflict of Interest

None declared.



[www.thieme.com/skullbasevideos](http://www.thieme.com/skullbasevideos)

[www.thieme.com/jnlsbvideos](http://www.thieme.com/jnlsbvideos)

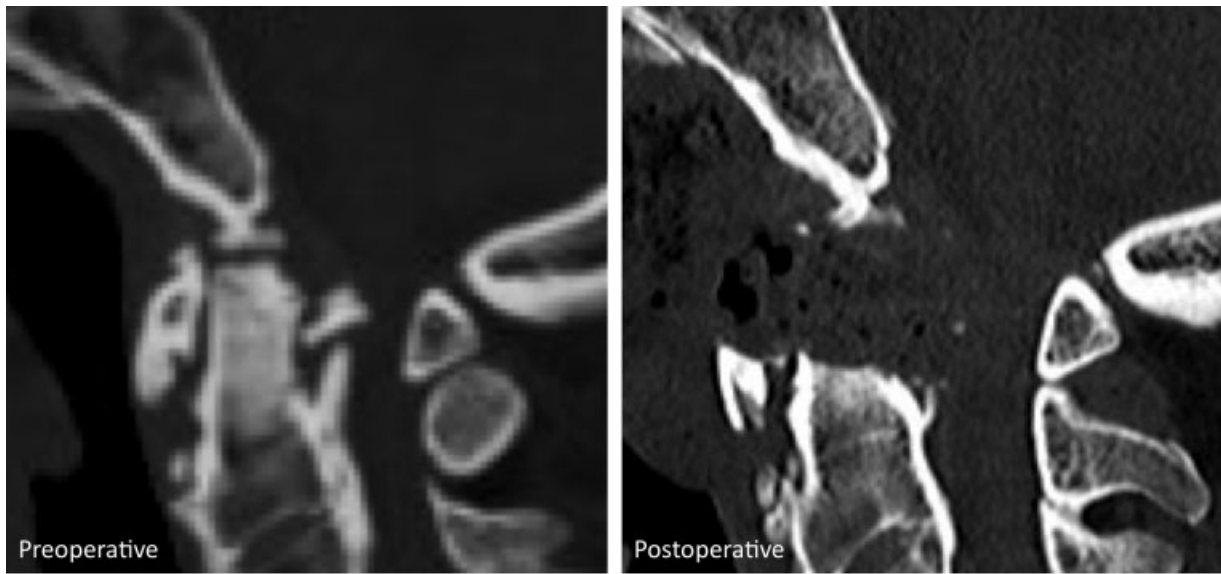
received  
January 10, 2019  
accepted  
March 8, 2020  
published online  
November 23, 2020

DOI <https://doi.org/10.1055/s-0040-1714409>.  
ISSN 2193-6331.

© 2020. The Author(s).

This is an open access article published by Thieme under the terms of the Creative Commons Attribution-NonDerivative-NonCommercial-License, permitting copying and reproduction so long as the original work is given appropriate credit. Contents may not be used for commercial purposes, or adapted, remixed, transformed or built upon. (<https://creativecommons.org/licenses/by-nc-nd/4.0/>)

Georg Thieme Verlag KG, Rüdigerstraße 14, 70469 Stuttgart, Germany



**Fig. 1** Pre- and postoperative sagittal CT.