

# Total Palmar Arch Reconstruction with Saphenous Vein Graft Following Gunshot Injury

Bilsev Ince<sup>1</sup> Majid Ismayilzade<sup>1</sup> Arda Soylu<sup>1</sup> Orkun Uyanik<sup>1</sup> Mehmet Dadaci<sup>1</sup>

<sup>1</sup>Department of Plastic & Reconstructive and Aesthetic Surgery, Faculty of Meram Medicine, Necmettin Erbakan University, Konya, Turkey

**Address for correspondence** Majid Ismayilzade, MD, Department of Plastic & Reconstructive and Aesthetic Surgery, Meram Faculty of Medicine, Necmettin Erbakan University, Meram, Konya, 42080, Turkey (e-mail: mecidismayilzade@hotmail.com).

Indian J Plast Surg:2020;53:447–449

Soft-tissue defects, and osteotendinous and neurovascular injuries, can occur at various levels in major traumatic events of the hand. Vein graft application can be required for neurovascular tissue defects, depending on the characteristics of injury. It is likely that high-energy injuries at the level of palmar arch and bifurcations of vessels create a need for vessel graft. The study describes the reconstruction process and surgical management of a patient who presented with a total loss of deep and superficial palmar arches and dorsal arches following gunshot injury.

The patient with a hypothenar defect and total limb amputation in his right hand following gunshot injury underwent surgery after an initial intervention in the emergency room (►Fig. 1). Replantation was considered inappropriate for the fifth finger due to hypothenar loss and injury pattern of an amputated part, so the proximal phalanx of the fifth digit was excised and used as a bone graft to construct a scaffold for the fourth metacarpal bone. Fixation of metacarpal bones and bone graft were done to the carpal bones

and radioulnar joint by K wires, followed by suturation of the tendon lacerations. As distance between the remained digital arteries and ulnar and radial arteries was calculated, 10 cm saphenous vein was harvested from the left leg to reconstruct a new palmar arch. Valvular resistance was minimized by subjecting the saphenous vein graft to irrigation with high-pressure physiologic saline solution. The vein graft was placed in the shape of a loop, and end-to-end anastomoses were performed with the radial and ulnar arteries. End-to-side anastomoses were performed between the re-created arch and the second and third common digital arteries, digital arteries of the first and second digits (►Figs. 2 and ►Figs. 3).

Further, because the circulation could not be provided in the first digit, an additional anastomosis was performed between the radial artery and digital artery on the radial surface of the first digit by the vein graft. Coaptations were obtained between the first, second, and third common digital nerves and median nerve.

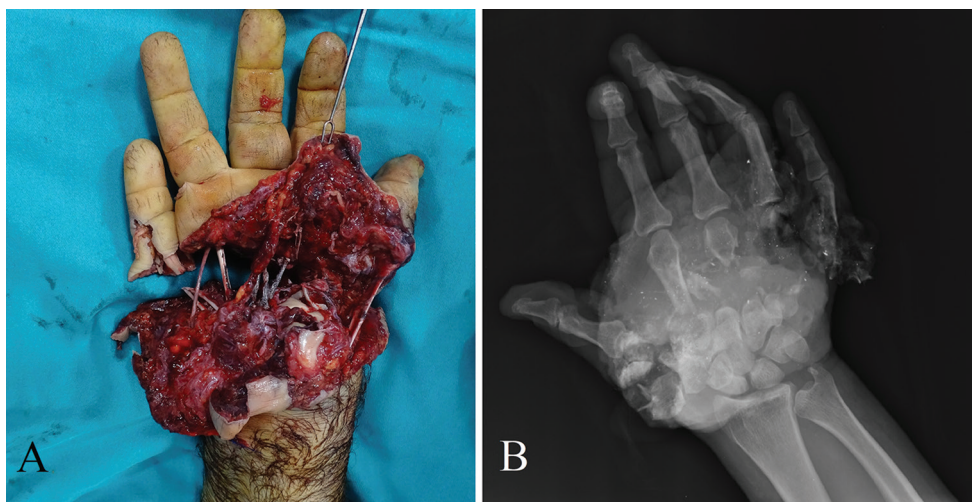


Fig. 1 (a) preoperative view of hand injury. (b) X-ray image of hand.

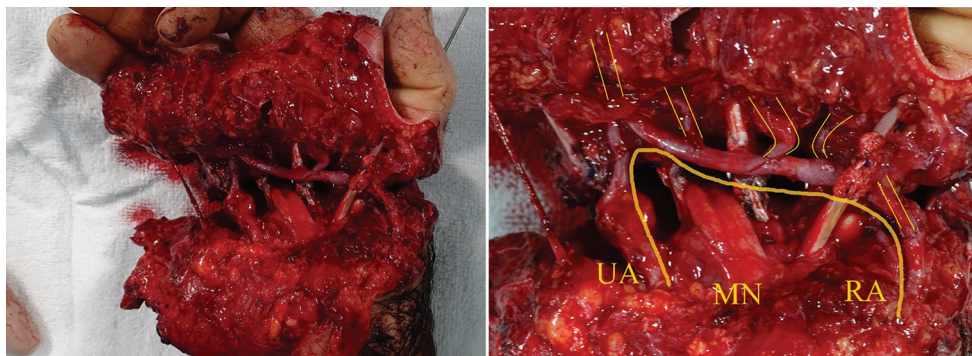
published online  
August 10, 2020

DOI <https://doi.org/10.1055/s-0040-1715263>  
ISSN 0970-0358.

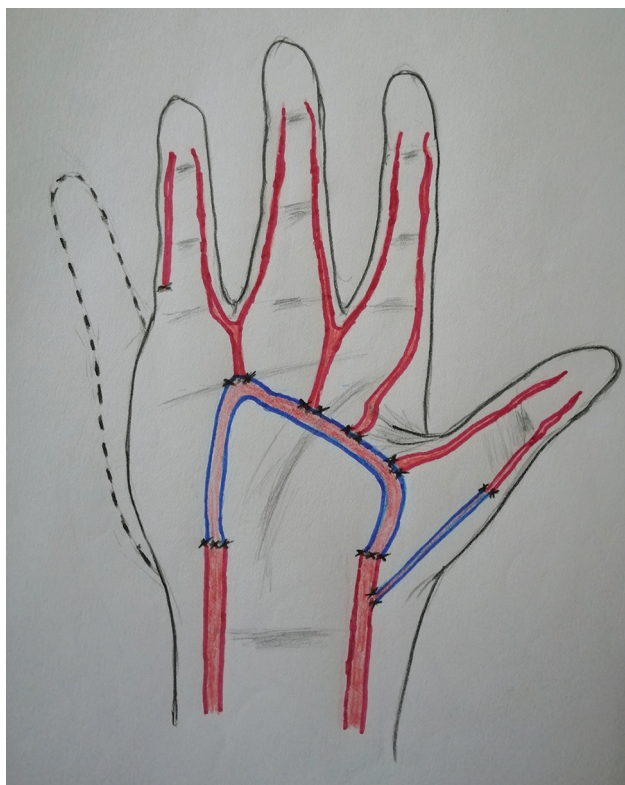
©2020. Association of Plastic Surgeons of India.

This is an open access article published by Thieme under the terms of the Creative Commons Attribution-NonDerivative-NonCommercial-License, permitting copying and reproduction so long as the original work is given appropriate credit. Contents may not be used for commercial purposes, or adapted, remixed, transformed or built upon. (<https://creativecommons.org/licenses/by-nc-nd/4.0/>).

Thieme Medical and Scientific Publishers Pvt. Ltd. A-12, 2nd Floor, Sector 2, Noida-201301 UP, India



**Fig. 2** Design of total palmar arch. Thick yellow line indicates the adaptation of saphenous vein graft between ulnar and radial arteries. Thin yellow lines indicate the end-to-side anastomoses between common digital arteries and recreated palmar arch (MN, median nerve; RA, radial artery; UA, ulnar artery).

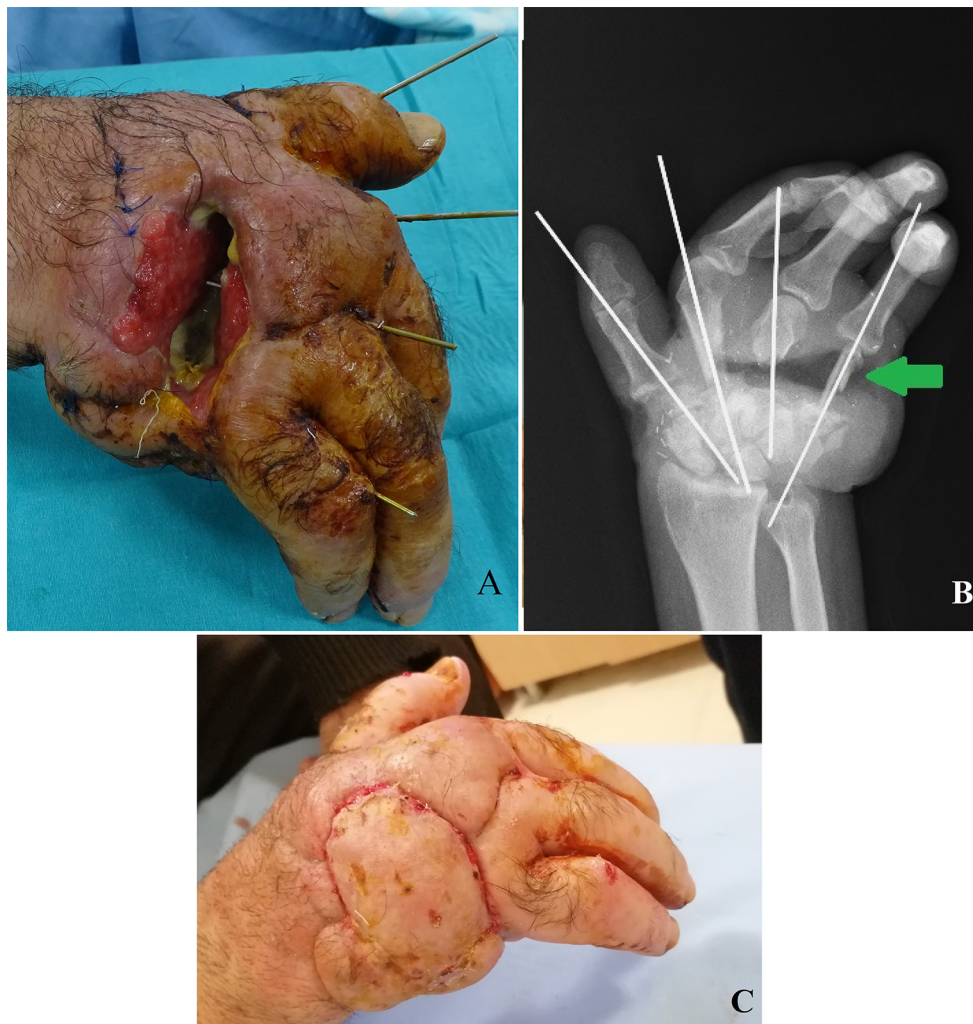


**Fig. 3** Illustration of the palmar arch reconstruction. Dashed line describes the amputated parts of hand. Blue colored vessels: saphenous vein graft for arch reconstruction and a vein graft for supporting circulation in the first digit.

Due to occurrence of open wound measuring  $4 \times 5$  cm in size and characterized by soft-tissue loss exposing an underlying bone, the defect area was reconstructed with a free gracilis muscle flap (►Fig. 4). The flap artery was anastomosed end-to-side to ulnar artery at the level of wrist, and flap veins were anastomosed end-to-end to ulnar concomitant veins. Physical rehabilitation courses are still being conducted.

The management and treatment of palmar arch injuries are complicated because it is likely to be encountered in complex traumas including multiple tissue defects, besides some

chronic pathologies. Marques used a saphenous vein graft to reconstruct a certain portion of the thrombosed superficial arch.<sup>1</sup> Liu et al used a dorsal venous arch of the foot for arch reconstruction.<sup>2</sup> Similarly, Krishnakumar et al created a complete arch between the radial and ulnar arteries and common digital arteries using a dorsal venous arch of the foot.<sup>3</sup> The present study is the only case demonstrating a complete arch reconstruction procedure between the ulnar and radial arteries and common digital arteries using a saphenous vein graft.



**Fig. 4** (a) Postoperative 45th day: wound exposing underlying bones. (b) Postoperative X-ray image of hand. Green arrow indicates the proximal phalanx bone graft excised from the fifth finger. (c) Postoperative 17th day view of the gracilis free muscle flap transfer.

#### Author Contributions

Conceptualization: Bilsev

Data curation: Bilsev, Arda, Majid

Visualization: Majid

Project administration: Bilsev, Mehmet

Writing–review and editing: Orkun, Arda

#### Ethical Review Committee Statement

This study conformed to the Helsinki Declaration.

#### Conflicts of Interest

The research was not sponsored by an outside organization. We (all the authors) have agreed to allow full access to the primary data and also allow the journal to review the data if requested.

None of the authors has a financial interest in any of the products, devices, or drugs mentioned in this manuscript.

#### References

- 1 Marques E. Ulnar artery thrombosis: hypothenar hammer syndrome. *J Am Coll Surg* 2008;206(1):188–189
- 2 Liu S, Liu JJ, Liu SH, Cai ZD, Chung K, Fan CY. Arcus venosus dorsalis pedis graft to restore the superficial palmar arch in devascularized hands. *J Reconstr Microsurg* 2012;28(4):251–256
- 3 Krishnakumar KS, Petkar K, Lateef S, Rasalkar J, Arun TJ, Suresh V. Palmar arch reconstruction using dorsal venous arch of foot for revascularisation of multiple digits. *Indian J Plast Surg* 2014;47(1):120–123