



# A Simple Bone Cyst of the Acromion: Case Report\*

## *Cisto ósseo simples do acrômio: Relato de caso*

Recep Öztürk<sup>1</sup> Emin Kürşat Bulut<sup>1</sup> Ömer Faruk Ateş<sup>2</sup> Bedii Şafak Güngör<sup>1</sup>

<sup>1</sup> Department of Orthopedics and Traumatology, Dr. Abdurrahman Yurtaslan Ankara Oncology Training and Research Hospital, Ankara, Turkey

<sup>2</sup> Department of Radiology, Sakarya University, Training and Research Hospital, Sakarya, Turkey

Address for correspondence Recep Öztürk, MD, Dr. Abdurrahman Yurtaslan Ankara Oncology Training and Research Hospital, Demetevler Mahallesi, Vatan Cad., Yenimahalle, Ankara, 06200, Turkey (e-mail: ozturk\_recep@windowslive.com).

Rev Bras Ortop 2021;56(2):263–267.

### Abstract

Simple bone cysts rarely occur in the scapula, and, to our knowledge, they have not been reported in the acromion. In the present report, we present the case of a 24-year-old female patient who was successfully treated by curettage and grafting using xenografting. No recurrence findings were observed during the follow-up six months postoperatively, the patient had recovered full range of motion, and she was able to perform all routine activities satisfactorily.

### Keywords

- ▶ bone cysts
- ▶ acromion
- ▶ scapula

### Resumo

Cistos ósseos simples são raros na escápula, e, pelo que sabemos, não foram relatados no acrômio. Aqui, apresentamos uma paciente do sexo feminino, de 24 anos, submetida com sucesso ao tratamento composto por curetagem e xenoenxerto. Não foram observados achados de recidiva no acompanhamento pós-operatório de seis meses, quando a paciente apresentou amplitude total de movimento e foi capaz de realizar todas as atividades rotineiras de maneira satisfatória.

### Palavras-chave

- ▶ cistos ósseos
- ▶ acrômio
- ▶ escápula

## Introduction

Unilateral bone cysts (UBCs), which are also known as simple bone cysts, are benign lesions filled with fluid that involve the metaphyses of long bones.<sup>1</sup> On plain radiographs, they are well-contoured lytic lesions with a cyst wall covered by a fibrous membrane containing some yellow serous fluid.<sup>2</sup> They are lesions of unknown etiology, which are most frequently observed in the age range of 5 to 15.<sup>3</sup> Even though

they have been reported in all bones, these cysts are quite common in the proximal humerus and proximal femur.<sup>4–6</sup>

The roentgenographic differential diagnosis of a cystic lesion in the scapula of an adolescent includes fibrous dysplasia, aneurysmal bone cyst, eosinophilic granuloma, osteoblastoma, or an infectious process.<sup>7,8</sup>

There is no standard approach for the treatment. Apart from follow-up without treatment, injection of local corticosteroids, multiple drill holes, and curettage plus grafting, many other treatment modalities have been described.<sup>6,7</sup>

Herein, we report a case of simple bone cyst located in the acromion. We could not find in the literature any other case of symptomatic single radiolucent lesion located in the

\* Study conducted at the Department of Orthopedics, Dr. Abdurrahman Yurtaslan Ankara Oncology Training And Research Hospital, Ankara, Turkey.

received

March 19, 2020

accepted

June 1, 2020

published online

September 22, 2020

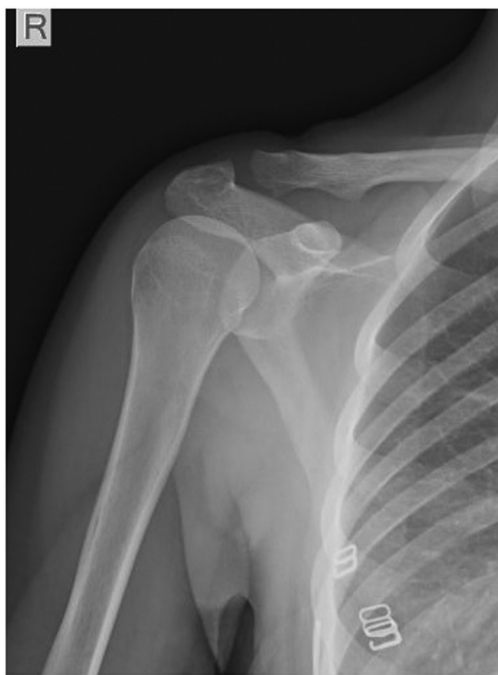DOI <https://doi.org/10.1055/s-0040-1715516>.

ISSN 0102-3616.

© 2020. Sociedade Brasileira de Ortopedia e Traumatologia. All rights reserved.

This is an open access article published by Thieme under the terms of the Creative Commons Attribution-NonDerivative-NonCommercial-License, permitting copying and reproduction so long as the original work is given appropriate credit. Contents may not be used for commercial purposes, or adapted, remixed, transformed or built upon. (<https://creativecommons.org/licenses/by-nc-nd/4.0/>)

Thieme Revinter Publicações Ltda., Rua do Matoso 170, Rio de Janeiro, RJ, CEP 20270-135, Brazil



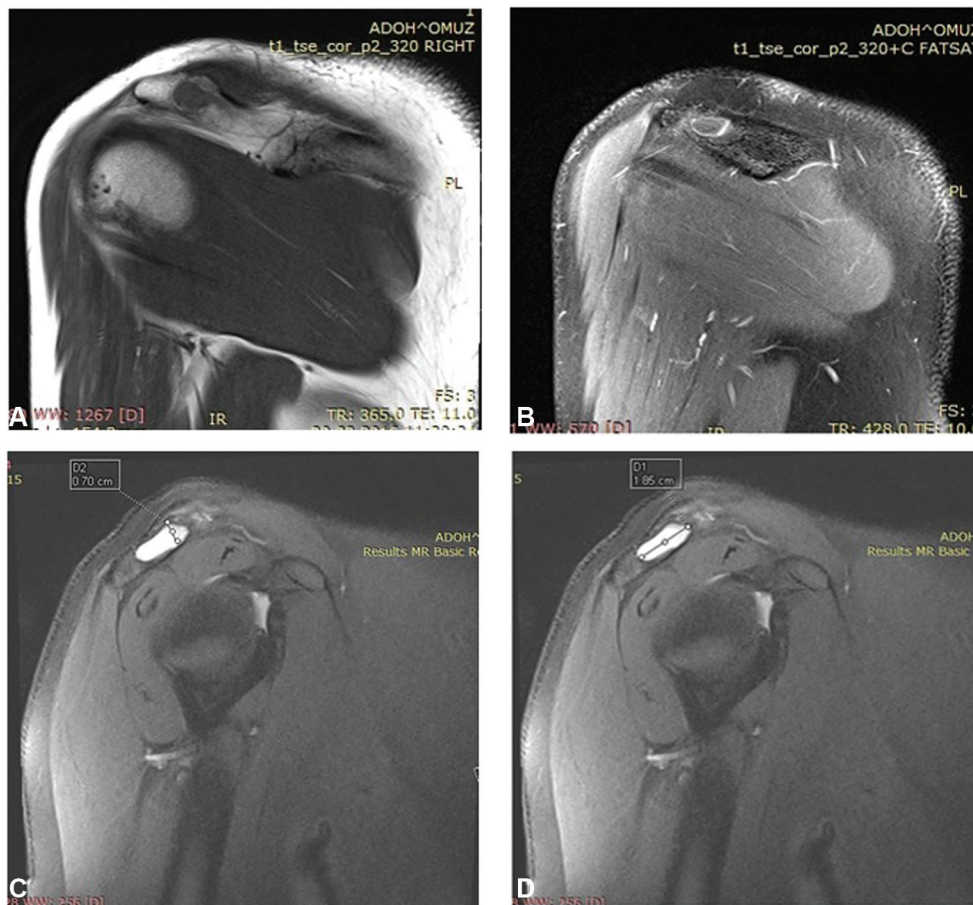
**Fig. 1** Anteroposterior (AP) radiograph of the right shoulder showing a well-circumscribed, lytic lesion, with no expansion in the acromion.

acromion. Our patient was successfully treated by curettage and grafting.

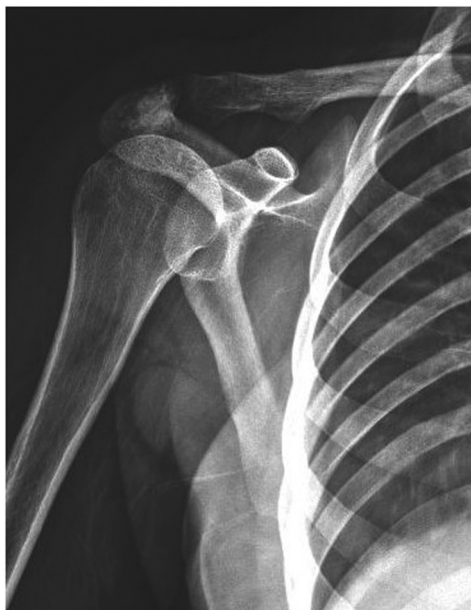### Case Report

A 24-year-old female patient presented to our orthopedic outpatient clinic with pain on the lateral side of the right shoulder. The patient reported that she had been having occasional pain for about one year, but the pain had exacerbated recently. She had no history of trauma or overuse. There was no systemic disease. On the physical examination, there was no edema or hyperemia on the lateral side of the shoulder. Her pain was associated with limitation in the movement of the right shoulder. There was pain on palpation on the anterior acromion. The patient was asked if data concerning the case could be submitted for publication, and she consented.

The simple two-plane radiograph of the right shoulder revealed a well-circumscribed lytic benign lesion, with minimal sclerotic margins and narrow transition zone, which did not lead to expansion in the acromion. Suppressed T2-weighted magnetic resonance images showed a non-suppressed homogenous, hypointense cystic lesion, with the same intensity as the fluid; on the T1-weighted series, after the injection



**Fig. 2** (A) Coronal T1-weighted preoperative magnetic resonance imaging (MRI) scan of the right shoulder showing a well-circumscribed homogenous hypointense lesion with no expansion in the acromion. (B) Coronal postcontrast T1-weighted preoperative MRI with peripheral thin contrast, but absence of the material in the center of the lesion. (C-D) Coronal lipid-suppressed T2-weighted preoperative MRI showing a homogenous hyperintense well-circumscribed lesion with a thin sclerotic wall in the acromion.

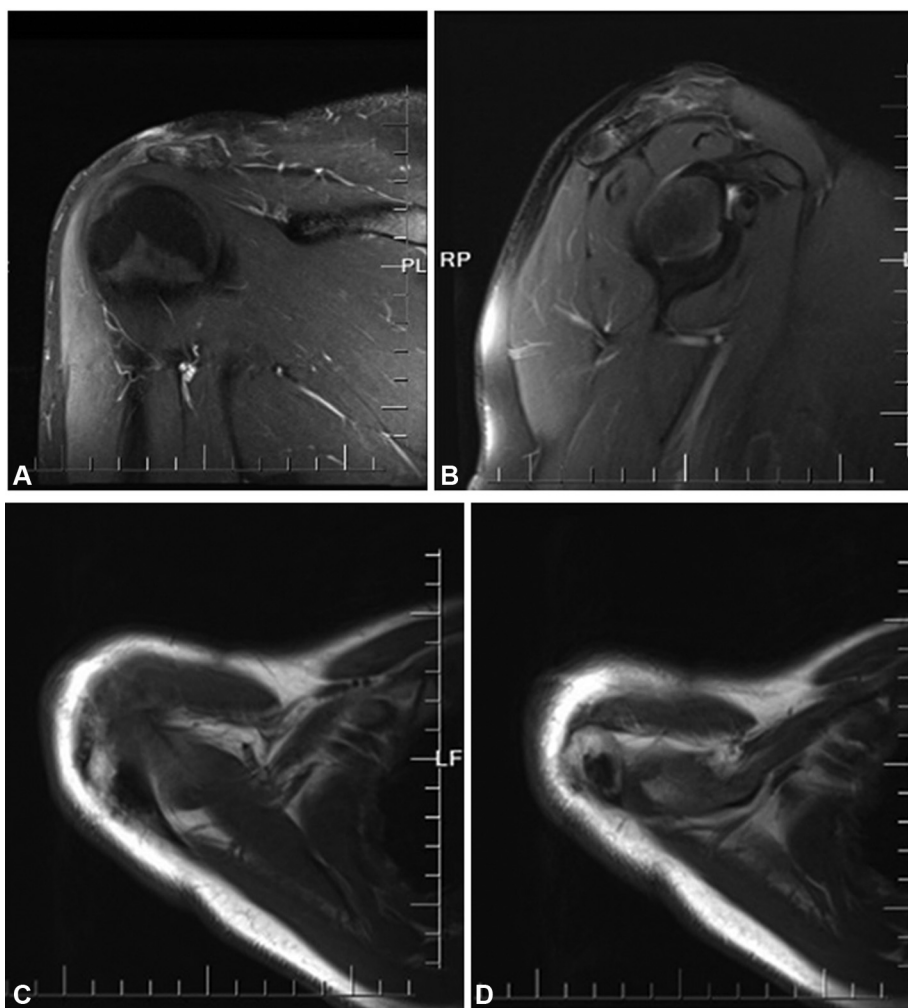


**Fig. 3** Right-shoulder AP radiograph showing, the postoperative changes in the acromion, absence of a lytic lesion, and dense areas with rough contour related to the graft material.

of a contrast agent, there was a slight contrast enhancement in the wall, but no enhancement in the central region or the septa (► **Figures 1 and 2**).

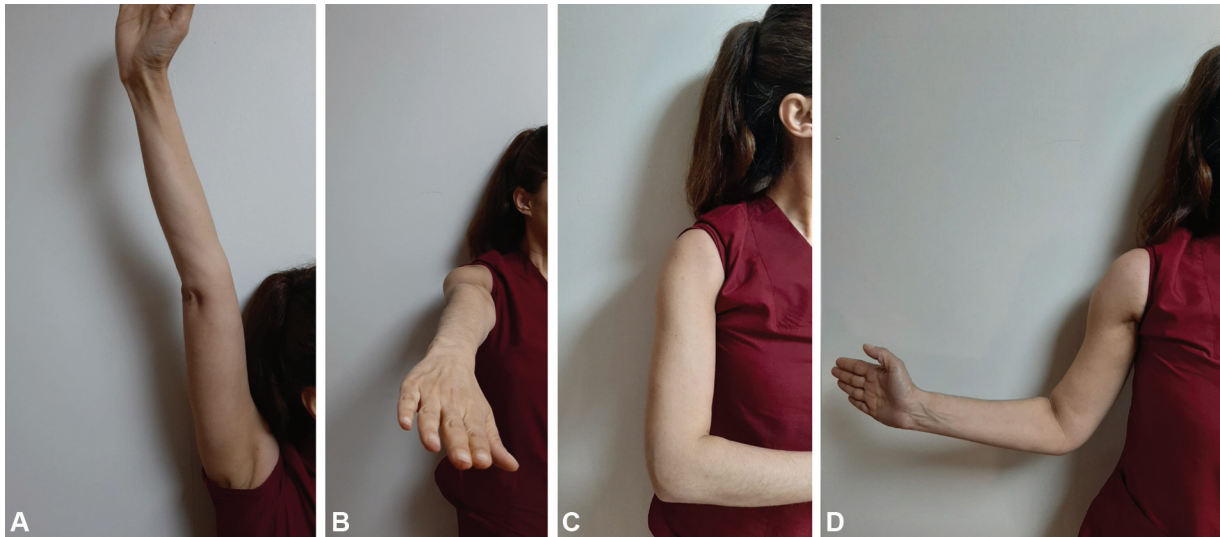
An incisional biopsy was planned. On the intraoperative evaluation, a frozen section was obtained, since the macroscopic findings suggested a benign cystic lesion, as did the radiographs, which indicated a simple bone cyst; therefore, curettage of the cavity with high-speed burring of the wall was performed in the same session. The lesion was grafted with a 10-cm<sup>3</sup> xenograft (► **Figure 3**). The curretted material sent for histopathological examination confirmed the diagnosis of simple bone cyst.

The exercises of active range of motion of the shoulder were started three weeks postoperatively, and the patient recovered the full range of motion without pain. There was no recurrence in the magnetic resonance imaging scans and on the simple radiograph six months postoperatively (► **Figure 4**). During the follow-up at six months, there were no additional complications or pain. The patient was performing all routine activities satisfactorily (► **Figure 5**).



**Fig. 4** (A-D) Magnetic resonance imaging scans of the 6th postoperative month: axial T1-weighted images showing an area with partial absence of a heterogenous hypointense signal related to the postoperative changes in the acromion. Coronal and sagittal lipid-suppressed T2-weighted images showing the postoperative granulation tissue, sclerosis, and a heterogenous hyperintense image with rough contour, secondary to the surgical graft material.





**Fig. 5** (A-D) Clinical photographs showing the full range of motion of the shoulder at the final follow-up.

## Discussion

Scapula tumors are rare and are frequently malignant. The benign and malignant lesions that may occur in the scapula are frequently observed during childhood.<sup>7,9</sup> Males are affected twice as often as females.<sup>1</sup> Unlike all of these symptoms, the case herein presented, a benign tumour in an adult woman, is rare.

Simple bone cysts were described for the first time by Virchow in 1876.<sup>10</sup> Most simple bone cysts are frequently observed during childhood, and they are defined as a developmental/reactive lesions. The etiology is unknown.<sup>3,6</sup>

Simple bone cysts usually involve the metaphysis of long bones, and have a predilection for the proximal humerus and proximal femur. In older patients, the ilium and the calcaneus are also regions where cysts are frequently observed.<sup>6</sup> The involvement of the scapula is infrequent. The lesion in the present case was located in the acromion.

The patients usually present with pathological fractures or mild pain.<sup>11</sup>

According to other case reports in the literature,<sup>12-15</sup> benign and malignant tumours in the acromion are rare. Other cases have been reported in the past, such as cases of aneurysmal bone cyst, giant-cell tumors, chondroblastoma, and multiple myeloma.<sup>12-15</sup>

There is still no consensus on whether there is a need for treatment (because there may be spontaneous resolution) and on which treatment is the most appropriate for cases of simple bone cyst.<sup>11</sup> The main goal of the treatment is to prevent pathological fracture, provide cyst eradication, and relieve the pain. Local corticosteroid injections, autologous bone-marrow transplantation or demineralized bone-matrix injections, cortical-cancellous bone auto- and allografts, and many other procedures have been described in the literature.<sup>6,7,10</sup>

There are no defined principles on how to treat simple bone cysts, and each treatment method has its own specific success rates and complications.<sup>11</sup> The indications for surgery in the present case were the radiographic findings implying cystic lesion in the acromion and the clinical history related to the lesion.

To the best of our knowledge, no other unicameral bone cyst in the acromion has been reported in the literature.

## Conflict of Interests

The authors have no conflict of interests to declare.

## References

- 1 Campanacci M, Enneking WF. Bone and soft tissue tumors. 2nd ed. New York: Springer Verlag; 1999:791-811
- 2 Tey IK, Mahadev A, Lim KB, Lee EH, Nathan SS. Active unicameral bone cysts in the upper limb are at greater risk of fracture. *J Orthop Surg (Hong Kong)* 2009;17(02):157-160
- 3 Yilmaz G, Aksoy MC, Alanay A, Yazici M, Alpaslan AM. [Treatment of simple bone cysts with methylprednisolone acetate in children]. *Acta Orthop Traumatol Turc* 2005;39(05):411-415
- 4 Öztürk R, Arıkan ŞM, Bulut EK, Kekeç AF, Çelebi F, Güngör BŞ. Distribution and evaluation of bone and soft tissue tumors operated in a tertiary care center. *Acta Orthop Traumatol Turc* 2019;53(03):189-194
- 5 Elmadağ M, Ceylan HH, Erdil M, Bilsel K. Apophyseal avulsion fracture of the anterior inferior iliac spine due to a simple bone cyst. *Acta Orthop Traumatol Turc* 2015;49(02):213-216
- 6 Singh S, Dhammi IK, Arora A, Kumar S. Unusually large solitary unicameral bone cyst: case report. *J Orthop Sci* 2003;8(04):599-601
- 7 Jain SK, Nathan SS. An unusual presentation of a simple bone cyst in the scapula. *Musculoskelet Surg* 2012;96(03):227-231
- 8 Atalay İB, Yapar A, Öztürk R. Primary aneurysmal bone cyst of the scapula in adult patient: two case reports and a review of the literature. [published online ahead of print, 2019 Dec 20] *Arch Orthop Trauma Surg* 2019. Doi: 10.1007/s00402-019-03327-z
- 9 Öztürk R, Arıkan ŞM, Toğral G, Güngör BŞ. Malignant tumors of the shoulder girdle: Surgical and functional outcomes. *J Orthop Surg*

- (Hong Kong) 2019;27(02):2309499019838355. Doi: 10.1177/2309499019838355
- 10 Erol B, Onay T, Çalışkan E, Aydemir AN, Topkar OM. Treatment of pathological fractures due to simple bone cysts by extended curettage grafting and intramedullary decompression. *Acta Orthop Traumatol Turc* 2015;49(03):288–296
  - 11 Gündeş H, Şahin M, Alici T. Unicameral bone cyst of the lunate in an adult: case report. *J Orthop Surg Res* 2010;5(05):79
  - 12 Mavrogenis AF, Rossi G, Rimondi E, Ruggieri P. Aneurysmal bone cyst of the acromion treated by selective arterial embolization. *J Pediatr Orthop B* 2011;20(05):354–358
  - 13 Sherwani RK, Zaheer S, Sabir AB, Goel S. Giant cell tumor along with secondary aneurysmal bone cyst of scapula: A rare presentation. *Int J Shoulder Surg* 2008;2(03):59–61
  - 14 Arıkan M, Toğral G, Yıldırım A, Irkkan Ç. A rare case of chondroblastoma of the acromion. *Acta Orthop Traumatol Turc* 2016;50(06):691–693
  - 15 Mahajan A, John B, John MJ. Acromion tumour as the primary presentation of multiple myeloma: case report. *Int J Basic Appl Sci* 2014;3(02):134–136