



Knee MR Using a Body Coil is Equivalent to CT in Measuring the TT-TG Distance: Removing the Systematic Bias*

A ressonância magnética do joelho usando a bobina de corpo é equivalente à TC na medição da distância TT-ST: Removendo o viés sistemático

Laís Uyeda Aivazoglou¹ Mariana Kei Toma¹ Pedro Henrique Coelho Arruda¹
Alipio Gomes Ormond Filho¹ Julio Brandão Guimarães¹ Flávio Duarte Silva¹

¹Department of Radiology, Grupo Fleury Medicina e Saúde, São Paulo, SP, Brazil

Address for correspondence Laís Uyeda Aivazoglou, MD, Department of Radiology, Grupo Fleury Medicina e Saúde, Rua Mato Grosso 306, SL1, São Paulo, SP, 01239-040, Brazil
(e-mail: lais.aivazoglou@grupofleury.com.br).

Rev Bras Ortop 2022;57(1):82–88.

Abstract

Objective To compare magnetic resonance imaging (MRI) using a body coil with computed tomography (CT) in measuring the tibial tubercle-trochlear groove distance (TT-TG) and the patellar tendon-cartilaginous trochlear groove (PT-CTG) distances, and evaluate interrater reliability.

Methods The study group consisted of 34 knees from 17 asymptomatic subjects with no history of knee pathology, trauma or surgery. A low-dose CT scan and an axial T1-weighted MRI sequence of the knees were performed with rigorous standardization of the positioning with full extension of the knees and parallel feet. Two musculoskeletal radiologists performed the measurements independently. The reliability of the TT-TG and PT-CTG distances on CT (17.1 ± 4.2 mm and 17.3 ± 4.2 mm) and of MRI (16.2 ± 3.7 mm and 16.5 ± 4.1 mm) was assessed by intraclass correlation coefficient (ICC [2,1]) and Bland-Altman graphs, as well as the interrater reliability for both methods.

Results Good reliability and agreement was observed between CT and MRI measurements for TT-TG and PT-CTG, with an ICC of 0.774 ($p < 0.001$) and 0.743 ($p < 0.001$), respectively, and no systematic bias was observed. The interrater reliability was excellent for all measurements on both imaging methods.

Conclusion This was the first study that compared MRI using a body coil with CT in measuring the TT-TG distance, with the potential clinical implication that the CT in this clinical setting could be avoided.

Keywords

- knee
- magnetic resonance imaging
- patellar instability
- tomography, x-ray computed

* Work developed at the Department of Radiology, Grupo Fleury Medicina e Saúde, São Paulo, SP, Brazil.

received
April 4, 2020
accepted
July 6, 2020
published online
March 22, 2021

DOI <https://doi.org/10.1055/s-0040-1718511>.
ISSN 0102-3616.

© 2021. Sociedade Brasileira de Ortopedia e Traumatologia. All rights reserved.

This is an open access article published by Thieme under the terms of the Creative Commons Attribution-NonDerivative-NonCommercial-License, permitting copying and reproduction so long as the original work is given appropriate credit. Contents may not be used for commercial purposes, or adapted, remixed, transformed or built upon. (<https://creativecommons.org/licenses/by-nc-nd/4.0/>)

Thieme Revinter Publicações Ltda., Rua do Matoso 170, Rio de Janeiro, RJ, CEP 20270-135, Brazil

Resumo

Objetivo Comparar a ressonância magnética (RM) usando uma bobina corporal e tomografia computadorizada (TC) na medição da distância tubérculo tibial-sulco troclear (TT-ST) e as distâncias tendão patelar-sulco troclear cartilaginoso (TP-STC), e avaliar a confiabilidade interavaliador.

Métodos O grupo de estudo consistiu em 34 joelhos de 17 indivíduos assintomáticos sem história de patologia, trauma ou cirurgia no joelho. Uma tomografia computadorizada (TC) de baixa dose e uma sequência axial de RM ponderada em T1 dos joelhos foram realizadas com padronização rigorosa do posicionamento com extensão total dos joelhos e pés paralelos. Dois radiologistas musculoesqueléticos realizaram as medidas de forma independente. A confiabilidade das distâncias TT-ST e TP-STC na TC ($17,1 \pm 4,2$ mm e $17,3 \pm 4,2$ mm) e RM ($16,2 \pm 3,7$ mm e $16,5 \pm 4,1$ mm) foi avaliada pelo coeficiente de correlação intraclass (CCI [2,1]) e gráficos Bland-Altman, bem como a confiabilidade entre avaliadores para ambos os métodos.

Resultados Boa confiabilidade e concordância foram observadas entre as medidas de TC e RM para TT-ST e TP-STC com um CCI de 0,774 ($p < 0,001$) e 0,743 ($p < 0,001$), respectivamente, e nenhum viés sistemático foi observado. A confiabilidade entre avaliadores foi excelente para todas as medições em ambos os métodos de imagem.

Conclusão Este foi o primeiro estudo que comparou a RM usando uma bobina corporal com a TC na medição da distância TT-ST, com a implicação clínica potencial de que a TC neste cenário clínico poderia ser evitada.

Palavras-chave

- joelho
- imagem de ressonância magnética
- instabilidade patelar
- tomografia computadorizada de raios x

Introduction

Patellar instability represents a common and significant health condition that affects young subjects and can lead to early osteoarthritis,¹ with an incidence as high as 12.98/100,000 person-years in males between 15 and 19 years old.² Its etiology is multifactorial, requiring a precise diagnosis, since treatment options range from conservative therapies to different surgical interventions.³

One of the most recognized risk factors for patellar instability is the increased tibial tubercle-trochlear groove distance (TT-TG); when greater than 15 to 20 mm, it is generally considered pathologic and has been proposed as a threshold for considering a tibial tubercle osteotomy or distal realignment procedure.^{4,5} The gold-standard imaging method for performing this measurement is computed tomography (CT), that has proven to be reliable.⁶ On the other hand, many of the patellar instability patients undergo magnetic resonance imaging (MRI) of the knee to assess soft-tissue injuries such as ligament tears and chondral defects, so it would be desirable to reliably assess the TT-TG distance in the same imaging study and thus avoid the need of an extra CT study. Besides, many patients with patellar instability are young and avoiding radiation exposure would be considerably beneficial.

Many authors have found that CT and MRI TT-TG measurements are not equivalent, and that MRI measurements are systematically underestimated,^{3,4,7-9} which suggests it would be inaccurate to use the same threshold in MRI and CT in diagnosis and surgical planning.

The TT-TG distance is highly sensitive to changes in knee positioning^{4,10} and while CT is performed with the legs in full extension, the dedicated knee coil in MRI surrounds the knee in a way it assumes variable grades of flexion ($\sim 25^\circ$) and varus deviation.⁴ The literature is scarce and controversial about the influence of feet positioning in knee measurements.

Another controversial topic in the literature is which landmarks to use for the measurement of the TT-TG distance. Given the high soft-tissue contrast resolution of MRI, some authors used soft-tissue parameters instead of bony parameters to measure the lateralization of the tibial tubercle (TT): the nadir of the cartilaginous trochlear groove (CTG) instead of the bony trochlear groove and the tibial insertion of the patellar tendon (PT) instead of the TT.

To this date, no study has compared the TT-TG and PT-CTG measurement in MRI using a body coil and CT to test interchangeability. Therefore, the aims of the present study are to compare these measurement values between MRI using a body coil with CT in asymptomatic volunteers, and to evaluate intermethods and interobserver agreement. Our hypothesis is that warranting the same knee and feet positioning in MRI and CT, the measurements would result similar.

Methods

Ethical committee approval was obtained (Plataforma Brasil number 3136833), as well as informed consent of all participants. The sample size was calculated according to Zou,¹¹ considering an effect size of 0.65, a 2-tailed significance level

(α) of 5% and a power (β) of 80%. This calculation resulted in a minimum of 30 knees.

Volunteers without any clinical knee symptoms were enrolled. The study group consisted of 34 knees (17 subjects; 13 male and 4 female), with a mean age and standard deviation (SD) of 38.6 ± 6.4 years, range between 29 and 50 years old. The inclusion criterion was the absence of knee symptoms and the exclusion criteria were: previous knee surgery, previous knee trauma, history of patellar instability or any other known knee pathologies.

A low-dose CT-scan and an axial T1-weighted MRI sequence of the knees were performed in all subjects. Positioning was the same in both studies: the volunteers were scanned in the supine position with full extension of the knees, using an acrylic supporting device that kept the orientation of the medial faces of the feet parallel to each other, with a distance of 3 to 5 cm between them (►Fig. 1).

Computed tomography studies were performed on a 64-detector Siemens CT scanner (SOMATOM Definition Edge, Siemens Medical Solutions, Munich, Germany), and the CARE Dose control system was selected to achieve radiation dose reduction. For the ethics committee evaluation, we performed radiation dose calculation on standard phantoms and the effective dose resulted in ~ 0.01 mSv (half the dose of a posteroanterior chest X-ray).¹² The images were reformatted to 3 mm thickness using soft-tissue and bone windows. Magnetic resonance imaging studies were performed on a GE/Optima 450w 1.5T MRI Scanner (GE, Boston, MA, USA) with a body coil and consisted in an axial T1-weighted sequence (TR: 375 ms/TE: 8,32 ms) of both knees, 5 mm thickness, 1 mm spacing, 320×256 matrix. Also, both

examinations included the femoral trochlea and the tibial tuberosity to allow measurements.

After a training session, two board-certified musculoskeletal radiologists (5 and 2 years of experience) evaluated the CT and MRI images independently and chose these specific slices:

1. The most cranial slice that depicted complete cartilaginous coverage of the femoral trochlea in MRI and CT (soft-tissue and bone window), allowing the determination of the deepest point of the bony trochlea groove (TG) and the cartilaginous trochlea groove (CTG);
2. The slice that showed the complete attachment of the patellar tendon at the tibial tuberosity in MR and CT (soft-tissue window), and the midpoint of that enthesis was defined as the patellar tendon (PT) landmark;
3. The most anterior point of the tibial tuberosity in MRI and CT (bone window), which corresponded to the TT bony landmark.

After this first independent session, as our main interest was to study the relationship between the knee position and the measurements, any differences in the slices chosen were corrected by consensus. Then, they were superimposed and the TT-TG and PT-CTG distances were measured independently in both methods (►Fig. 2). The TT-TG distance was assessed between two parallel lines drawn through the bony parameters: the most anterior point of the tibial tuberosity and the deepest point of the bony TG, perpendicular to a line drawn tangent to the posterior aspect of the femoral condyles.¹³ The PT-CTG distance was measured similarly, but

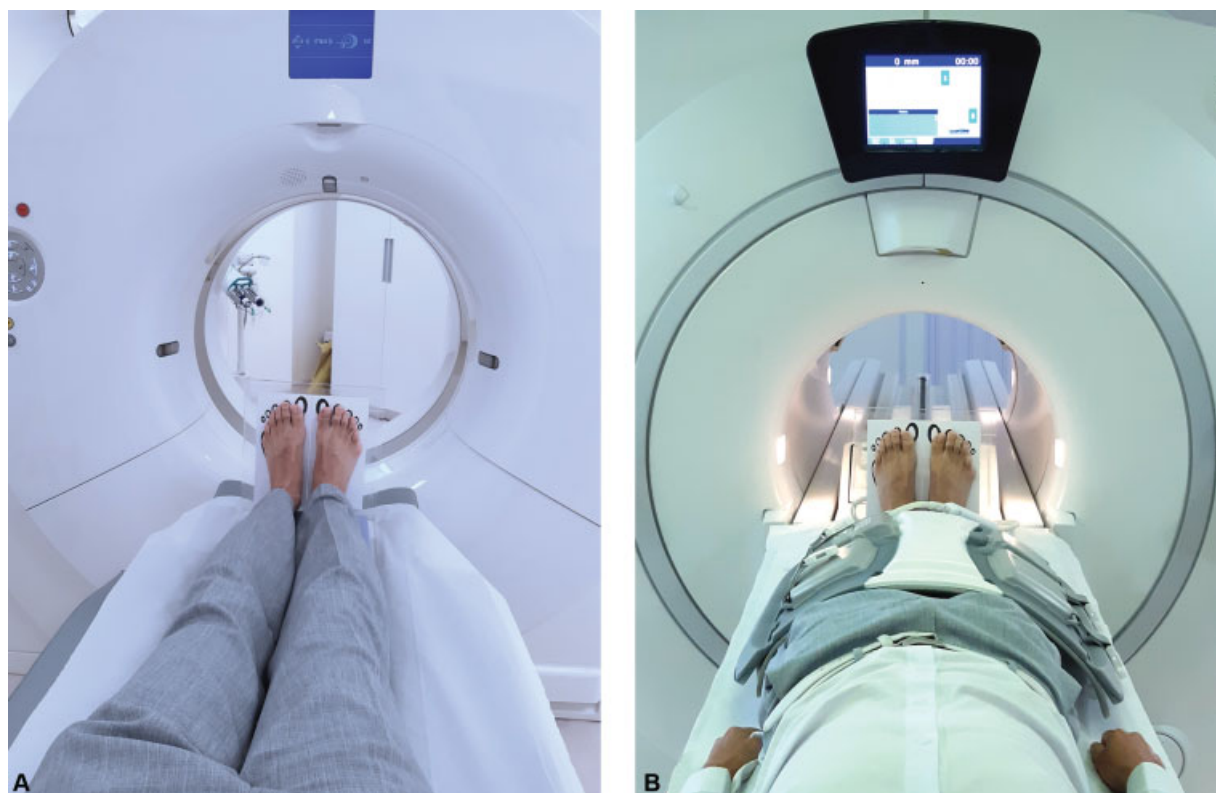

Fig. 1 (A and B) Positioning in the CT and MRI with body coil, both with the acrylic supporting device.

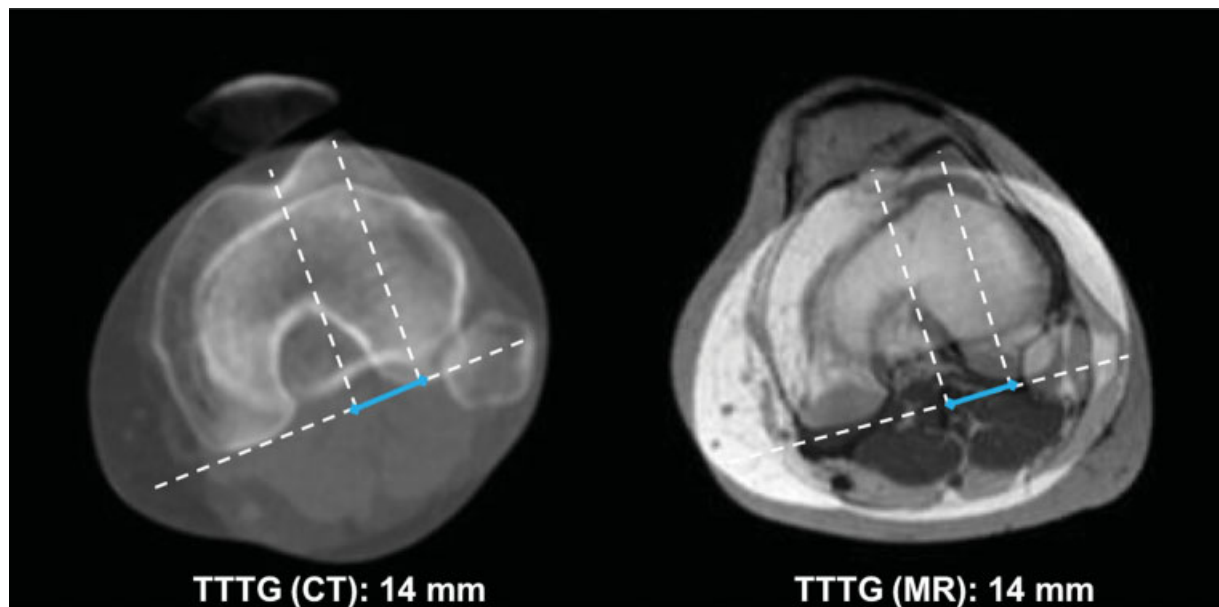


Fig. 2 The image shows the superimposed CT (left) and MRI (right) slices and depicts the TT-TG measurement in the left knee of a 29-year-old female asymptomatic volunteer.

using the soft-tissue parameters: the PT attachment to the tibia and the deepest point of the CTG.¹⁴

Statistical analysis was made using SPSS Statistics for Windows, Version 20.0 (IBM Corp., Armonk, NY, USA), STATA 12 (Stata Software, College Station, TX, USA) and R software (R Foundation, Vienna, Austria). Normality distribution was assessed by the Kolmogorov-Smirnov test. The interrater reliability of slices chosen, TT-TG and PT-CTG measurements on CT and MRI were evaluated for all measures studied using intraclass correlation coefficient (ICC [2,1]) and Bland-Altman graphs. The type of ICC chosen was based on the Koo et al. guidelines,¹⁵ and the level of significance (α) = 0.05 was adopted.

Results

Normality assessed by the Kolmogorov-Smirnov test being the null hypothesis a normal distribution resulted in a $p > 0.05$ for all variables. The ICC for all the slices chosen were excellent, except for PT on MRI, which was good (► **Table 1**). ► **Table 1**

Table 1 Interrater reliability for each slice

Slice	ICC(2,1) (95%CI)	Same slice	The same or the next slice
1 on CT	0.993 (0.985–0.997)	73.5%	97.1%
2 on CT	0.996 (0.989–0.998)	64.7%	100%
3 on CT	0.989 (0.928–0.996)	32.4%	76.5%
1 on MRI	0.967 (0.934–0.984)	70.6%	100%
2 on MRI	0.896 (0.796–0.947)	64.7%	94.1%
3 on MRI	0.961 (0.882–0.984)	52.9%	91.2%

Abbreviations: CI, confidence interval; CT, computed tomography; ICC, intraclass correlation coefficient; MRI, magnetic resonance imaging.

shows the percentage of knees in which the same or the next slice was chosen by both observers. Good reliability and agreement was observed between CT and MRI measurements for TT-TG and PT-CTG measurements with an ICC of 0.774 (0.659–0.854, $p < 0.001$) and 0.743 (0.615–0.833, $p < 0.001$), respectively. The distribution is shown in the Bland-Altman graphs (► **Figs. 3** and **4**). The presence of < 6% of the observations outside the limits of agreement can be observed (confidence interval [CI] of 95%). The TT-TG and PT-CTG measurements were randomly scattered near the zero value of the difference and no systematic bias was observed. The mean TT-TG on CT and MRI were 17.1 ± 4.2 mm and 16.2 ± 3.7 mm, respectively. The mean PT-CTG distance were respectively 17.3 ± 4.2 mm and 16.5 ± 4.1 mm. The interrater reliability was excellent for all measurements (► **Table 2**).

Discussion

Our most important finding was the good reliability and agreement of the TT-TG and PT-CTG measurements between MRI (using a body coil) and CT. Since the grade of knee flexion influences the tibiofemoral rotation and hence the distances,¹⁶ the rigorous standardization in the positioning of the knees was essential to achieve that result. When TT-TG measurement is necessary, the CT study can be substituted by an axial T1-weighted sequence of the knees using the body coil, removing the need of unnecessary radiation exposure in this setting and, most importantly, allowing the use of the same threshold (15–20 mm) classically used in CT. Our study also confirms the excellent interrater reliability of MRI measurements, which had already been shown in previous studies.^{14,17,18}

Schoettle et al.¹⁹ compared knee CT and MRI (with a routine knee protocol) and found an excellent intermethods reliability, stating that additional CT scans were not

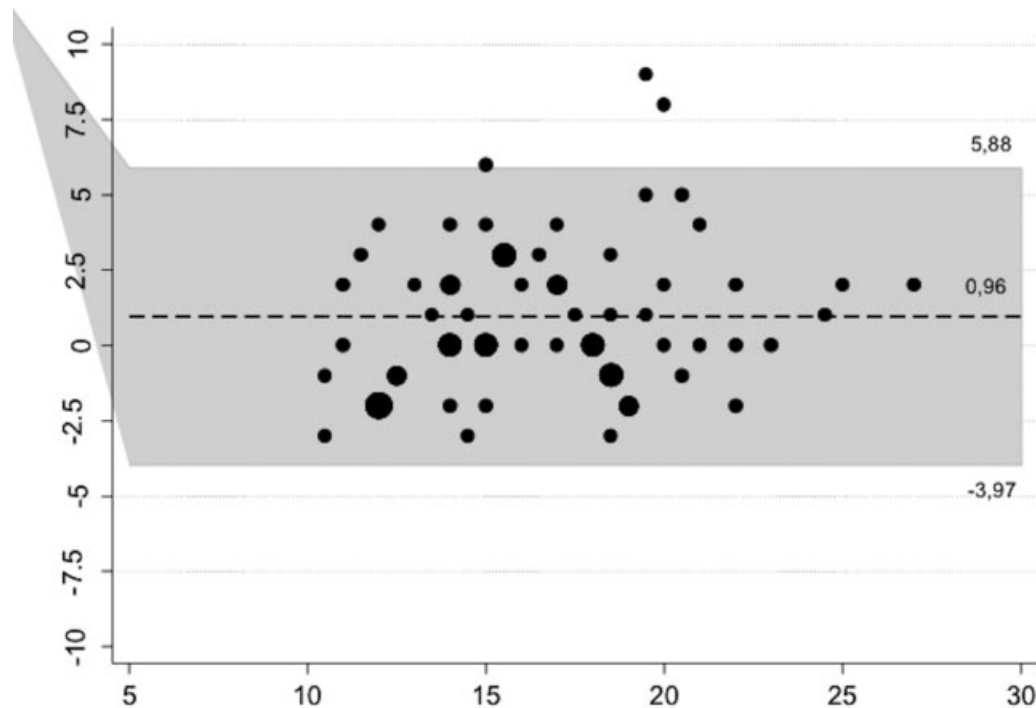


Fig. 3 Bland-Altman graph shows the TT-TG measurements randomly scattered inside the CI. Only 4,4% (3/68) of the cases are outside the limits of agreement.

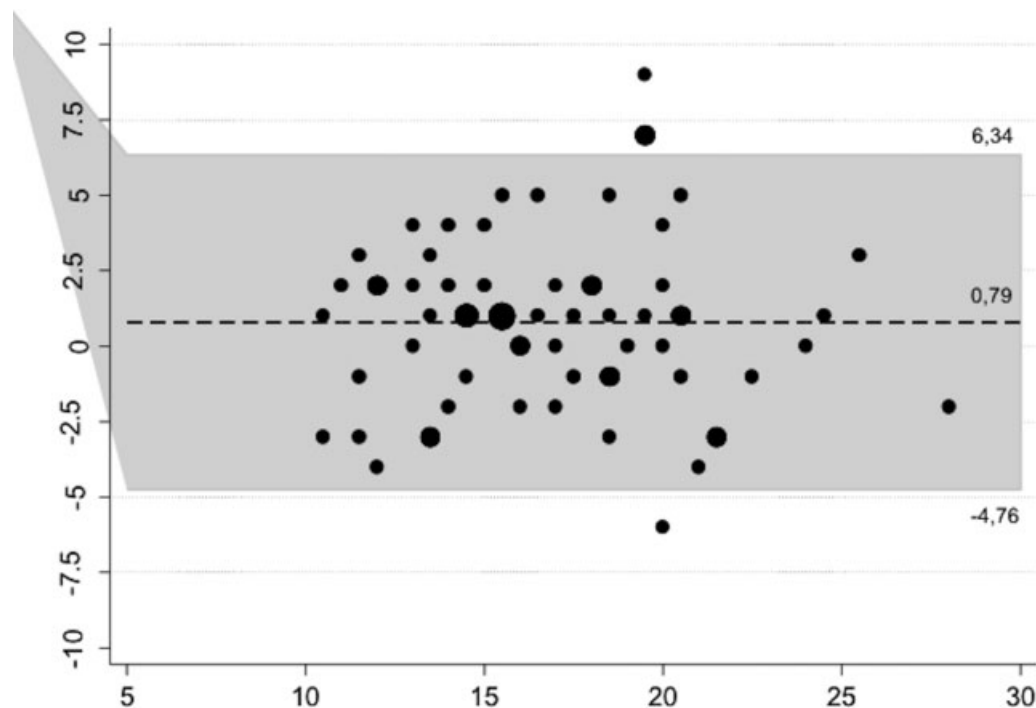


Fig. 4 Bland-Altman graph shows the PT-CTG measurements randomly scattered inside the CI. Only 5.9% (4/68) of the cases are outside the limits of agreement.

necessary. However, many later studies have not been able to reproduce these results, concluding that CT and MRI TT-TG measurements are not equivalent, and that MRI measurements are systematically underestimated,^{3,4,7-9} which suggests it would be inaccurate to use the same threshold in MRI and CT in diagnosis and surgical planning.

The TT-TG distance is highly sensitive to changes in knee positioning,^{4,10} and while CT is performed with the legs in full extension, the dedicated knee coil in MRI surrounds the knee in a way it assumes variable grades of flexion ($\sim 25^\circ$) and varus deviation.⁴ A partially flexed position of the knee reduces the TT-TG measurements⁷ due to the progressive

Table 2 Interrater reliability for computed tomography and magnetic resonance imaging measurements

	Intraclass correlation coefficient	
	(95%CI)	p-value
CT		
TT-TG	0.872 (0.760–0.934)	< 0.001
PT-CTG	0.918 (0.844–0.958)	< 0.001
MR		
TT-TG	0.833 (0.693–0.912)	< 0.001
PT-CTG	0.907 (0.824–0.952)	< 0.001

Abbreviations: CI, confidence interval; CT, computed tomography; MRI, magnetic resonance imaging; PT-CTG, patellar tendon-cartilaginous trochlear groove distance; TT-TG tibial tubercle-trochlear groove distance.

internal rotation of the tibia in relation to the femur during flexion. Seitlinger et al.¹⁶ studied the TT-TG distance in extension and in different grades of flexion in MRI and found that the TT-TG distance decreased significantly during flexion in knees with patellofemoral instability and in healthy volunteers. Aarvold et al.⁷ compared the TT-TG distance in symptomatic patients measured in MRI studies using a body coil to guarantee full extension of the knees and in MRI using a dedicated knee coil, finding that the latter underestimates the measurements (mean difference: 8.6 mm).

In none of these studies, the positioning of the feet was mentioned. Galland et al.²⁰ performed the CT studies using a plantar support device to avoid quadriceps contraction, and although they mention a recommendation of placing the feet in the angle of step, they considered feet positioning would not affect patellofemoral measurements (but unfortunately did not present data to support it). We decided to standardize the positioning of the feet for two theoretical reasons. One is the possibility of an undesired oblique alignment of the examined lower extremity in relation to the longitudinal axis of the machine, and the second is that the gravity acting on the feet of a lying supine patient could produce a torque on the knee and rotation of the tibia in relation to the femur.

The slice selection might be a source of a disagreement of the final TT-TG or PT-CTG on both methods. Even though the ICC was excellent or good for all the slices, the agreement over the same slice may be considered poor for slice 3 on CT (32.4%) and MRI (52.9%). We believe the long TT cranio-caudal diameter may cause trouble to decide which slice to choose. Regarding the use of bony or soft-tissue parameters, although both were reliable between CT and MRI, there was a tendency for higher correlation coefficients when using soft-tissue parameters, in accordance to what was observed in MRI measurements by Wilcox et al.¹⁴ These findings point us to recommend the use of the PT as the distal landmark instead of the TT.

The only systematic review and meta-analysis on the topic⁵ suggests the use of different thresholds for CT and MRI (15.5 ± 1.5 mm for TT-TG distance measured on CT and 12.5 ± 2 mm for MRI), with the limitation that there was no

standardization of the positioning and flexion of the knees and the landmarks used.

Ho et al.⁴ concluded that establishing a controlled, reproducible positioning of the patient would be vital to allow the interchangeability of the use of CT and MRI in measuring the TT-TG distance, and that was the main goal of our study.

Precluding the CT use in this setting would avoid radiation exposure in a mostly young population, thus reducing its potential risks throughout life, and also reduce overall costs, though adding a sequence to the knee MRI would increase the MRI study time.

The main limitations of our study include a small sample and the exclusive evaluation of asymptomatic volunteers. Future research should assess the interchangeability in patients with patellar instability.

Another limitation would be that we could not assess the isolated importance of the feet positioning, given that we chose to rigorously standardize positioning of both the knees and feet and did not test different positioning of the feet.

In conclusion, this was the first study that compared MRI using a body coil with the gold-standard CT in measuring the TT-TG and PT-CTG distances, with a good agreement between those methods and an excellent interrater reliability, with the potential clinical implication that the knee CT could be substituted by MRI using the body coil in this clinical setting.

Financial Support

There was no financial support from public, commercial, or not-for-profit sources.

Conflict of Interests

The authors have no conflict of interests to declare.

Acknowledgment

We thank Dr Marcelo Astolfi Caetano Nico for taking the time and effort necessary to revise the manuscript.

References

- Thakkar RS, Del Grande F, Wadhwa V, et al. Patellar instability: CT and MRI measurements and their correlation with internal derangement findings. *Knee Surg Sports Traumatol Arthrosc* 2016; 24(09):3021–3028
- Waterman BR, Belmont PJ Jr, Owens BD. Patellar dislocation in the United States: role of sex, age, race, and athletic participation. *J Knee Surg* 2012;25(01):51–57
- Camp CL, Stuart MJ, Krych AJ, et al. CT and MRI measurements of tibial tubercle-trochlear groove distances are not equivalent in patients with patellar instability. *Am J Sports Med* 2013;41(08):1835–1840
- Ho CP, James EW, Surowiec RK, et al. Systematic technique-dependent differences in CT versus MRI measurement of the tibial tubercle-trochlear groove distance. *Am J Sports Med* 2015;43(03):675–682
- Tan SHS, Lim BY, Chng KSJ, et al. The Difference between Computed Tomography and Magnetic Resonance Imaging Measurements of Tibial Tubercle-Trochlear Groove Distance for Patients with or without Patellofemoral Instability: A Systematic Review and Meta-Analysis. *J Knee Surg* 2020;33(08):768–776
- Smith TO, Davies L, Toms AP, Hing CB, Donell ST. The reliability and validity of radiological assessment for patellar instability. A

- systematic review and meta-analysis. *Skeletal Radiol* 2011;40(04):399–414
- 7 Aarvold A, Pope A, Sakthivel VK, Ayer RV. MRI performed on dedicated knee coils is inaccurate for the measurement of tibial tubercle trochlear groove distance. *Skeletal Radiol* 2014;43(03):345–349
 - 8 Hinckel BB, Gobbi RG, Filho EN, et al. Are the osseous and tendinous-cartilaginous tibial tuberosity-trochlear groove distances the same on CT and MRI? *Skeletal Radiol* 2015;44(08):1085–1093
 - 9 Anley CM, Morris GV, Saithna A, James SL, Snow M. Defining the Role of the Tibial Tubercle-Trochlear Groove and Tibial Tubercle-Posterior Cruciate Ligament Distances in the Work-up of Patients With Patellofemoral Disorders. *Am J Sports Med* 2015;43(06):1348–1353
 - 10 Marquez-Lara A, Andersen J, Lenchik L, Ferguson CM, Gupta P. Variability in patellofemoral alignment measurements on MRI: Influence of knee position. *AJR Am J Roentgenol* 2017;208(05):1097–1102
 - 11 Zou GY. Sample size formulas for estimating intraclass correlation coefficients with precision and assurance. *Stat Med* 2012;31(29):3972–3981
 - 12 Ait-Ali L, Andreassi MG, Foffa I, Spadoni I, Vano E, Picano E. Cumulative patient effective dose and acute radiation-induced chromosomal DNA damage in children with congenital heart disease. *Heart* 2010;96(04):269–274
 - 13 Dejour H, Walch G, Nove-Josserand L, Guier C. Factors of patellar instability: an anatomic radiographic study. *Knee Surg Sports Traumatol Arthrosc* 1994;2(01):19–26
 - 14 Wilcox JJ, Snow BJ, Aoki SK, Hung M, Burks RT. Does landmark selection affect the reliability of tibial tubercle-trochlear groove measurements using MRI? *Clin Orthop Relat Res* 2012;470(08):2253–2260
 - 15 Koo TK, Li MY. A Guideline of Selecting and Reporting Intraclass Correlation Coefficients for Reliability Research. *J Chiropr Med* 2016;15(02):155–163
 - 16 Seitlinger G, Scheurecker G, Högl R, Labey L, Innocenti B, Hofmann S. The position of the tibia tubercle in 0°-90° flexion: comparing patients with patella dislocation to healthy volunteers. *Knee Surg Sports Traumatol Arthrosc* 2014;22(10):2396–2400
 - 17 Pandit S, Frampton C, Stoddart J, Lynskey T. Magnetic resonance imaging assessment of tibial tuberosity-trochlear groove distance: normal values for males and females. *Int Orthop* 2011;35(12):1799–1803
 - 18 Sobhanardekani M, Sobhan MR, Nafisi Moghadam R, Nabavinejad S, Razavi Ratki SK. The Normal Value of Tibial Tubercle Trochlear Groove Distance in Patients With Normal Knee Examinations Using MRI. *Acta Med Iran* 2017;55(09):573–577
 - 19 Schoettle PB, Zanetti M, Seifert B, Pfirrmann CWA, Fucentese SF, Romero J. The tibial tuberosity-trochlear groove distance; a comparative study between CT and MRI scanning. *Knee* 2006;13(01):26–31
 - 20 Galland O, Walch G, Dejour H, Carret JP. An anatomical and radiological study of the femoropatellar articulation. *Surg Radiol Anat* 1990;12(02):119–125